ACG CASE REPORTS JOURNAL

IMAGE | ENDOSCOPY

Cylindrical Batteries in the Stomach: Should We Wait 48 Hours for Removal?

Tariq A. Hammad, MD[1], Yaseen Alastal, MD[1], Muhammad Z. Bawany, MD[2], Ali Nawras MD[2], Mohammad Hammad, MD[3], and Osama Alaradi, MD[2]

[1]*Department of Internal Medicine, University of Toledo Medical Center, Toledo, OH*
[2]*Division of Gastroenterology and Hepatology, Department of Internal Medicine, University of Toledo Medical Center, Toledo, OH*
[3]*Jenin Governmental Hospital, Jenin, Palestine*

Case Report

A 31-year-old woman presented with witnessed ingestion of multiple cylindrical batteries to deliberately self-harm 2 hours prior to admission. The patient denied any symptoms. Physical exam was normal. Abdominal series showed 7 cylindrical batteries (5 AAA and 2 AA) in the upper abdomen (Figure 1). Esophagogastroduodenoscopy (EGD) under conscious sedation revealed food remnants in the stomach. Despite extensive irrigation and suctioning only 2 batteries were visualized in the stomach and both were successfully retrieved using a Roth net. No mucosal damage was apparent. The next morning, she complained of mild abdominal pain with mild epigastric tenderness. Abdominal x-ray revealed 4 batteries in the stomach, and another in the small bowel. The patient underwent repeat EGD under general anesthesia within 12 hours of the ingestion time. Stomach exam revealed 3 batteries in the body with 3 deep ulcerations (2 in the antrum and 1 in the incisura) and multiple erosions (Figure 2). Duodenal exam showed superficial mucosal erosions, and another battery was seen beyond the ligament of Treitz.

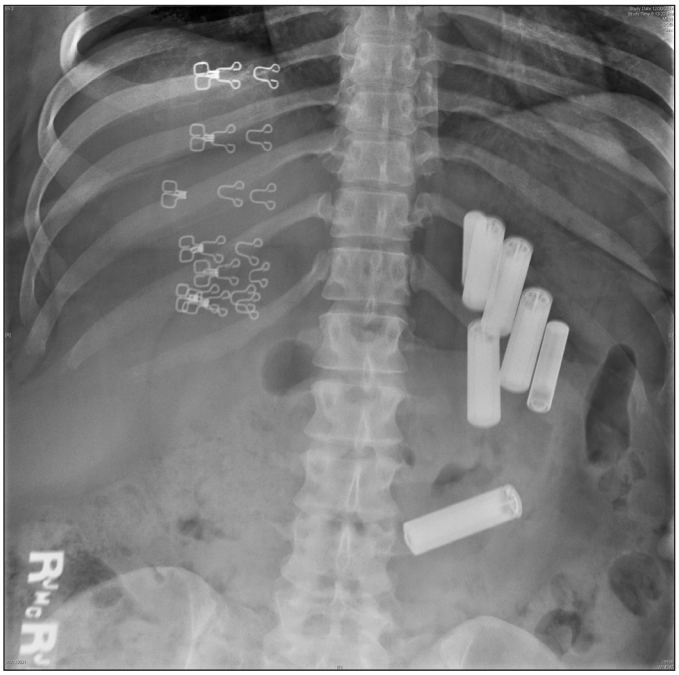

Figure 1. Abdominal x-ray showing 7 cylindrical batteries (5 AAA and 2 AA) in the upper abdomen.

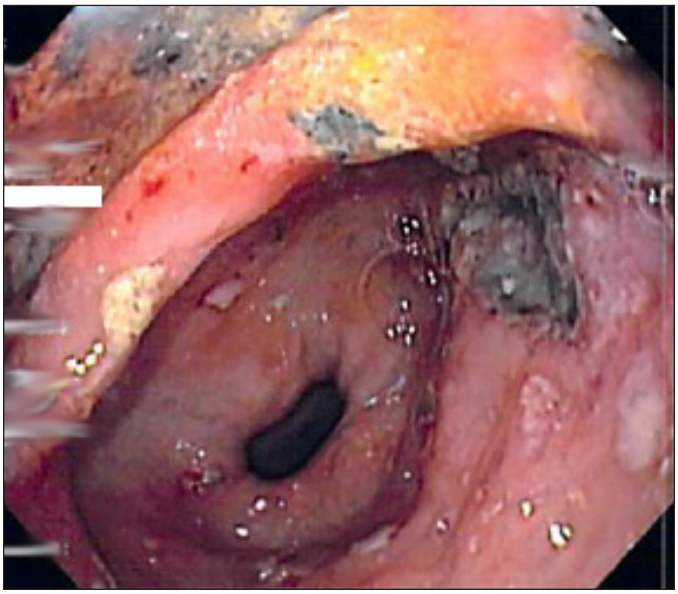

Figure 2. Endoscopic view showing severe gastric ulceration and erosions in the stomach.

ACG Case Rep J 2015;3(1):3-4. doi:10.14309/crj.2015.80. Published online: October 9, 2015.

Correspondence: Osama Alaradi, Department of Gastroenerology and Hepatology, University of Toledo Medical Center, 3000 Arlington Avenue, Toledo, OH 43614 (Osama.Alaradi@UToledo.edu).

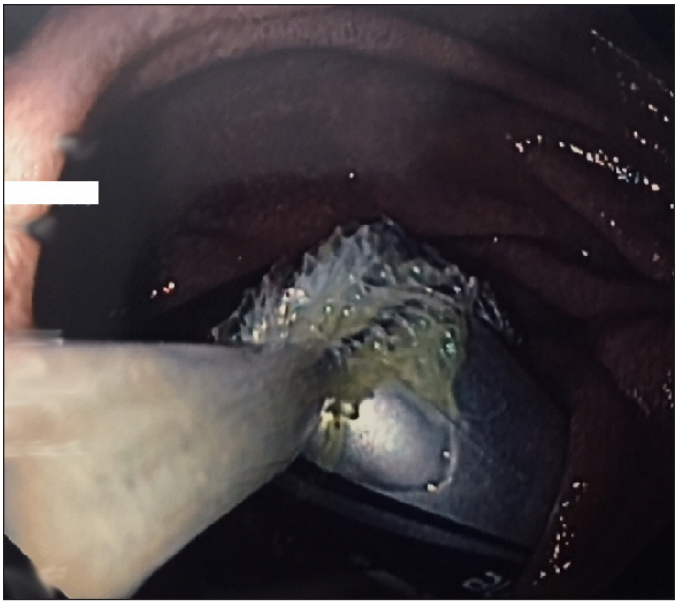

Figure 3. Endoscopic view showing a cylindrical battery in the proximal jejunum retrieved using a Roth net.



Figure 4. Retrieved batteries with evidence of seal erosions and alkaline leakage.

The 4 batteries were retrieved successfully using Roth net (Figure 3). The seal of the batteries was eroded and leakage of chemical contents was evident on the pole of the batteries (Figure 4). The final battery passed per rectum 3 days later without complications.

Our patient's battery ingestion resulted in severe gastric ulcerations and erosions caused by the corrosive alkaline spilled from the eroded batteries.[1] The amount of alkaline was large enough to cause a corrosive injury even though the batteries were in the stomach less than 12 hours. Cyrany et al reported a case of a single A23 cylindrical battery ingestion that resulted in 2 gastric ulcers within 26 hours of ingestion.[2] Current guidelines recommend removing a cylindrical battery if it remains in the stomach for longer than 48 hours.[3] However, considering the severity of the injury within 12 hours in our case, we propose that cylindrical batteries should be removed endoscopically as soon as possible if reachable by the endoscope.

Disclosures

Author contributions: TA Hammad, Y. Alastal, and M. Hammad wrote the manuscript and reviewed the literature. MZ Bawany and A. Nawras critically revised the manuscript for important intellectual content. O. Alaradi supervised the process, critically revised the article for important intellectual content, and approved the final draft. TA Hammad is the article guarantor.

Financial disclosure: None to report.

Informed consent was obtained for this case report.

Received: April 20, 2015; Accepted: June 8, 2015

References

1. Litovitz T, Whitaker N, Clark L,et al. Emerging battery-ingestion hazard: Clinical implications. *Pediatrics*. 2010;125(6):1168–77.
2. Cyrany J, Melek J, Dedek P, et al. Cylindrical battery ingested by a 1-year-old baby: Does the voltage matter? *Endoscopy*. 2014;46(suppl 1):UCTN:E543–4.
3. Ikenberry SO, Jue TL, Anderson MA, et al; ASGE Standards of Practice Committee. Management of ingested foreign bodies and food impactions. *Gastrointest Endosc*. 2011;73(6):1085–91.