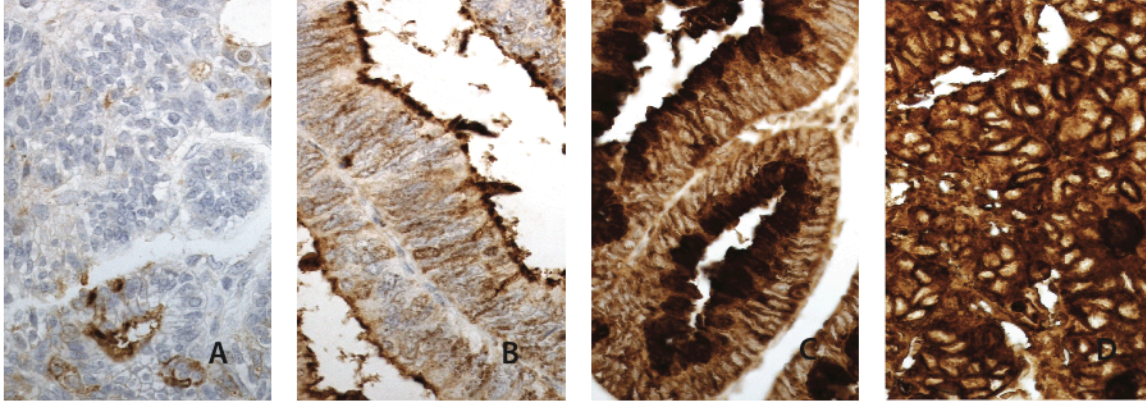


Supplementary figure 1 Immunohistochemical staining pattern of sialyl Lewis a in colorectal cancer



Representative images of sialyl Lewis a expression in colorectal cancer. (A) Sialyl Lewis a negative, (B) weak cytoplasmic positivity, (C) moderate cytoplasmic positivity, and (D) strong cytoplasmic positivity. Original magnification x 40.

Supplementary figure 1