

# A Retrospective Study of Narrowband-UVB Phototherapy for Treatment of Vitiligo in Malaysian Patients

J Adauwiyah, MMed, AdvMDerm; H H Suraiya, FRCP

Pusat Perubatan Universiti Kebangsaan Malaysia

## SUMMARY

Psoralen and ultraviolet light A (PUVA) was the mainstay of vitiligo treatment before the introduction of narrowband UVB (NB-UVB). Eighteen patients treated with NB-UVB in Hospital Kuala Lumpur were retrospectively analyzed. Eight patients had Fitzpatrick skin phototype III and 10 with phototype IV. The mean duration of disease was  $7.3 \pm 5.4$  years, and the mean body surface area affected was  $19.3 \pm 16.2\%$ . Mean duration of treatment was  $14.3 \pm 9.6$  months, number of session  $113.5 \pm 88.6$  times and cumulative dose  $111.7 \pm 108.5$  J/cm<sup>2</sup>. Concomitant topical steroid was used in 88.9% patients. Repigmentation was moderate in 6(40%) patients, good in 3(20%), while 3(20%) achieved excellent results. One patient (6.6%) showed no response and 2(13.3%) showed poor repigmentation. Three patients developed side effects. NB-UVB phototherapy results in satisfactory repigmentation in our vitiligo patients and should be offered as a treatment option.

## KEY WORDS:

*vitiligo, narrowband UVB, phototherapy*

## INTRODUCTION

Vitiligo is an acquired disorder of depigmentation characterized by loss of functional melanocytes from the epidermis. Its prevalence ranges from 0.3 -1.1% worldwide<sup>1</sup>. There is no racial or gender predilection. In Hospital Kuala Lumpur between 2003 and 2007, 791 patients were treated for vitiligo. Four hundred and eighty four (61%) of these were new cases. This represents 2.2% of all new cases referred to the Dermatology Clinic within the same period<sup>2</sup>.

The disease runs an unpredictable natural course. Spontaneous repigmentation occurs in 10-20% of patients<sup>3</sup>. However, depigmentation is often progressive. Depigmentation on the Asian skin may result in a tremendous cosmetic and psychosocial impact on the sufferer. In our predominantly brown-skinned population, vitiligo is a stigma. Thus, an effective and safe treatment is desirable to help these patients.

Various management options are available for vitiligo, however there is no single most effective treatment. UVA phototherapy with topical or systemic psoralen has been the mainstay of treatment worldwide until the introduction of NB-UVB in 1997<sup>4</sup>. A landmark study by Westerhof et al<sup>4</sup> compared NB-UVB and topical PUVA in patients with skin phototype III. Sixty seven percent patients who received NB-UVB developed repigmentation compared to 46% in patients treated with topical PUVA. Similar results were observed by Bhatnagar et al<sup>5</sup>

in comparing systemic PUVA with NB-UVB in patients with skin phototype IV and V. NB-UVB has a few advantages over PUVA: it is safe in pregnant women and children, there is less xerosis and erythema effects, and less perilesional hyperpigmentation. Post treatment eye protection is not required and the side effects of psoralen like photosensitivity, nausea, vomiting, headache and cataracts can be avoided with NB-UVB.

In Hospital Kuala Lumpur, NB-UVB has been available and utilized for treatment of various dermatological conditions including vitiligo since 2003. Other treatment modalities for vitiligo are potent topical steroids, topical calcipotriol, topical tacrolimus, topical pimecrolimus, excimer laser and surgical therapies where melanocyte containing specimens from normal skin are grafted into the depigmented areas. This article aimed to review our results and experience in treating patients with vitiligo using NB-UVB.

## MATERIALS AND METHODS

This is a retrospective analysis of adult vitiligo patients treated with NB-UVB phototherapy in Hospital Kuala Lumpur between 2003 to 2007. Patients who received NB-UVB were identified from the Dermatology Department Phototherapy Unit. The patients' phototherapy and clinic records were screened. Patients with complete treatment and response assessment were included. Patients whose treatment records were missing or incomplete and patients who defaulted treatment were excluded. Data were collected from clinic visit and phototherapy records. Response to treatment in terms of repigmentation was based on physician's global assessment: none when there is no repigmentation, poor when repigmentation is less than 25%, moderate 25% to 50%, good 51% to 75% and excellent 76% to 100% repigmentation.

## RESULTS

Forty five vitiligo patients treated with NB-UVB were identified from the Phototherapy Unit. Data from 18 patients who fulfilled the inclusion criteria were selected for analysis. Patients received treatment twice per week in Daavlin Spectra 311/350<sup>®</sup> phototherapy cabin. The dose regimen was determined by Fitzpatrick skin phototype. Patients with skin phototype III were started on 180mJ/cm<sup>2</sup>, while skin phototype IV patients received 150mJ/cm<sup>2</sup>. Phototherapy dose was increased at each session until formation of mild erythema. The irradiation dose for subsequent sessions was maintained if the patient was not able to tolerate higher doses. The maximum dose per session was 1275mJ/cm<sup>2</sup>. The patient demographics and disease characteristics are shown in Table 1.

*This article was accepted: 7 February 2011*

*Corresponding Author: Dr Adawiyah Jamil, Jabatan Perubatan, Pusat Perubatan Universiti Kebangsaan Malaysia, Jalan Yaacob Latif, Bandar Tun Razak, 56000 Cheras, Kuala Lumpur. Email: adda\_jamil@yahoo.com*

Table 1. Demographic, disease and treatment characteristics of patients.

Parameters n=18	
Age (mean)years	46.4±12.2
Gender, n(%)	
Male	7(39%)
Female	11(61%)
Ethnic, n(%)	
Malay	9(50%)
Chinese	5(28%)
Indian	4(22%)
Classification of vitiligo, n(%)	
Vulgaris	14(77%)
Focal	2(11%)
Acrofacial	1(6%)
Mixed	1(6%)
Fitzpatrick skin phototype	
Type III	8(44%)
Type IV	10(56%)
Mean duration of disease, years	7.3±5.4
Mean body surface area involvement, %	19.3±16.2%
Concomitant topical steroid therapy, n(%)	16(88.9%)
Previous treatment, n(%)	
Oral PUVA	6(33%)
Topical PUVA	2(11%)
Topical meladinine with sunlight	3(17%)
Topical steroid only	1(6%)
None	6(33%)

Three patients were excluded from treatment response analyses as treatment was prematurely discontinued due to development of side effects. In the remaining 15 patients, the mean number of phototherapy sessions was 113.5±88.6 times and the mean duration of treatment was 14.3±9.6 months. The mean cumulative dose was 111.7±108.5J/cm<sup>2</sup>. In our evaluation of repigmentation response to NB-UVB, six patients had moderate response, three had good response and another three had excellent response. Two patients responded poorly while one did not show any repigmentation. Six or 40% of patients had more than 50% repigmentation while twelve (80%) achieved moderate, good or excellent repigmentation. Figure 1 summarizes the repigmentation response observed in our patients.

Figure 2 showed the repigmentation response according to the anatomical sites affected. The best result was seen on the face. The acral areas were more resistant. The limbs showed mainly moderate to good response while the trunk responded fairly.

Follicular repigmentation was observed in 60% of patients, peripheral repigmentation in 13% and 27% of patients developed both pattern of repigmentation. Three patients developed adverse effects to NB-UVB which required discontinuation of therapy. All patients had erythema and burning sensation while one developed dryness. The side effects were transient and reversible upon discontinuation of treatment.

**DISCUSSION**

Previous studies on the use of NB-UVB in vitiligo generally yielded good results. Westerhof et al<sup>4</sup> demonstrated 60% patients achieved more than 75% repigmentation after receiving NB-UVB for 12 months. Five out of seven patients (71%) treated over a 13 months period by Scherschun et al<sup>6</sup> attained the same degree of repigmentation. Kanwar et al<sup>7</sup>

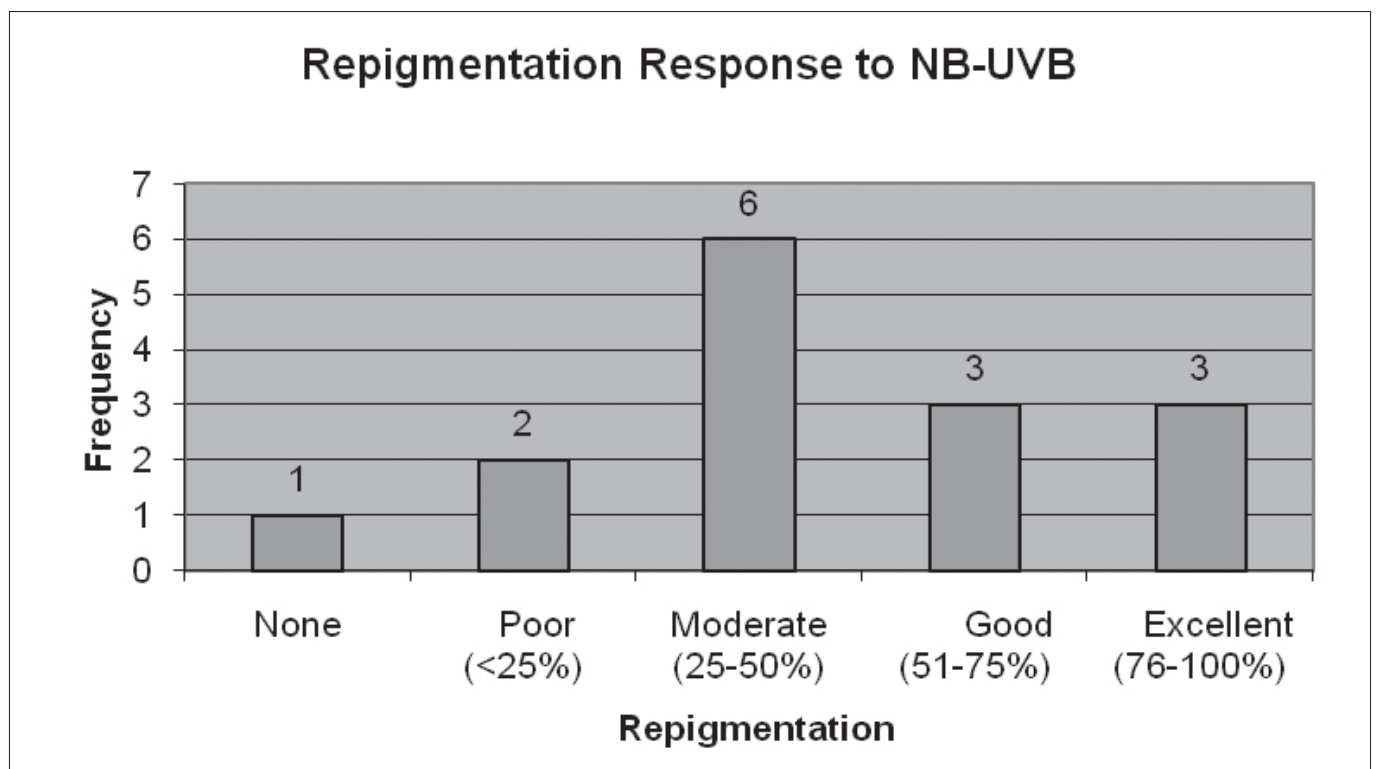


Figure 1. Repigmentation response to NB-UVB.

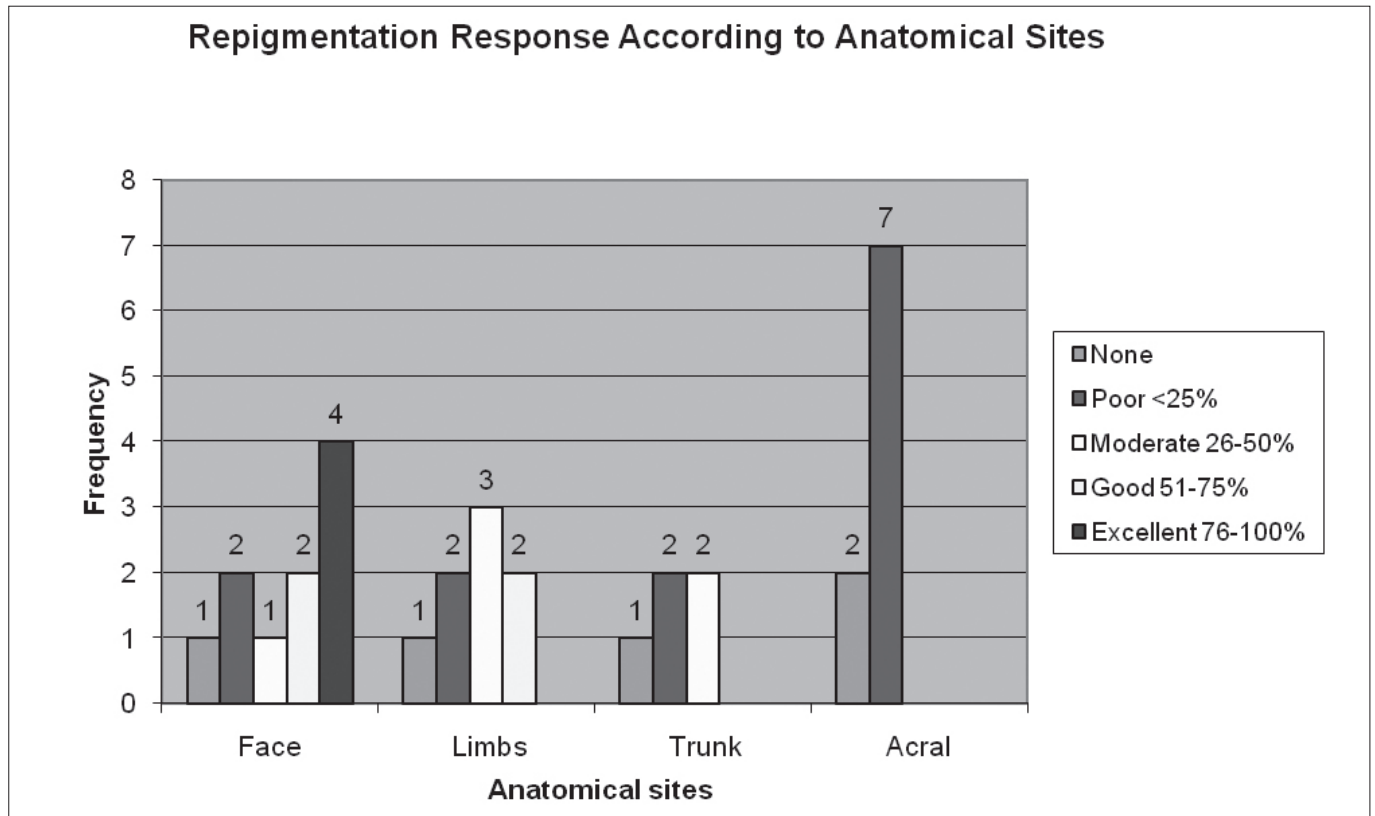


Figure 2. Repigmentation response according to anatomical sites.

observed similar results in 71.4% patients. However, only 35% of patients evaluated by Sitek et al<sup>8</sup> achieved more than 75% repigmentation. Nicolaidou et al<sup>9</sup> reported a result of 34.4% for repigmentation on the face. These study populations include patients with various skin phototypes ranging from phototype II to V. The influence of skin phototypes on treatment response is not clear. The only available data from Sitek et al<sup>8</sup> for skin phototypes II, III and IV did not show significant relationship between responders and non responders. Our repigmentation result in skin phototype III and IV patients is similar to Sitek et al<sup>8</sup>. Twenty percent of our patients achieved more than 75% repigmentation. A few factors possibly influenced the results observed in our patients. Most of our patients (44%), were patients who had failed treatment with oral or topical PUVA prior to the initiation of NB-UVB, these are likely the group of patients that are resistant to treatment. The mean duration of disease is also longer at 7.3±5.4 years and patients were older with mean age 46.4±12.2 years. Repigmentation response has been demonstrated to be better in younger patients aged less than 20, and vitiligo of recent onset<sup>10</sup>.

In our series of patients, the best repigmentation response was seen on the face while the acral areas responded poorly. The limbs and trunk demonstrated moderate to good response. This finding is consistent with previous reports where response to therapy correlated with the anatomical sites of involvement<sup>7,10</sup>.

In our previous review of 116 vitiligo patients treated with oral and topical PUVA in Hospital Kuala Lumpur, 35.3% achieved more than 50% repigmentation<sup>11</sup>. The result observed in this review with NB-UVB is 40%. This may suggest that

both treatment modalities are comparable in our population although a larger, prospective, randomized trial is necessary to confirm this observation.

In conclusion, NB-UVB phototherapy in our vitiligo patients with Fitzpatrick skin phototype III and IV results in satisfactory repigmentation. This treatment modality should be offered as a treatment option especially in patient who failed topical therapy and those who cannot tolerate PUVA therapy.

**REFERENCES**

1. Kovacs S. Vitiligo. *J Am Acad Dermatol* 1998;38:647-66.
2. Dermatology Department Hospital Kuala Lumpur Data.
3. Castanet J, Ortonne JP. Pathophysiology of vitiligo. *ClinvDermatol*1997;15:845-51.
4. Westerhof W, Nieuweboer-Krobotova L. Treatment of vitiligo with UV-B radiation vs topical psoralen plus UV-A. *Arch Dermatol* 1997;133:1525-8.
5. Bhatnagar A, Kanwar AJ, Parsad D et al. Comparison of systemic PUVA and NB-UVB in the treatment of vitiligo: an open prospective study. *J EADV* 2997;21:638-42.
6. Scherschun L, Kim JJ, Lim HW. Narrow-band ultraviolet B is useful and well tolerated treatment for vitiligo. *J Am Acad Dermatol* 2001;44:999-1003.
7. Kanwar AJ, Dogra S, Parsad D et al. narrowband UVB for the treatment of vitiligo: an emerging effective and well tolerated therapy. *Int J Dermatol* 2005;44:57-60.
8. Sitek JC, Loeb M, Ronnevig. Narrowband UVB therapy for vitiligo: does the repigmentation last? *J EADV* 2007;21:891-6.
9. Nicolaidou E, Antoniou C, Stratigos AJ et al. Efficacy, predictors of response, and long-term follow-up in patients with vitiligo treated with narrowband UVB phototherapy. *J Am Acad Dermatol* 2007;56:274-8.
10. Brazelli V, Antoninetti M, Palazzini S et al. Critical evaluation of the variants influencing the clinical response of vitiligo; study of 60 cases treated with ultraviolet B narrowband phototherapy. *J EADV* 2007;21:1369-774.
11. Low PG, Hussein SH. PUVA treatment of vitiligo. *Malaysian J Dermatol* 2000;13:13-9.