

Nasal valve surgery

La chirurgia della valvola nasale

I. TASCA, G. CERONI COMPADRETTI, F. SORACE

Department of Otorhinolaryngology, Imola Hospital, Imola, Italy

SUMMARY

The nasal valve region plays a key role in nasal breathing. In the international literature, a variety of techniques have been described to rectify nasal valve compromise, but based on the present evidence it is impossible to counsel a patient as to which technique is most effective. The aim of this study was to evaluate the results of surgery of the nasal valve through a hemitransfixion incision objectively with nasal endoscopy and rhinomanometry. The study group consisted of 54 males and 15 females with a mean age of 41.8 ± 14.4 years, (range: 21-72 years). After a mean follow-up of 8 ± 4.1 months, nasal endoscopy demonstrated the favourable effects of surgical treatment with a normalization of the nasal valve angles. Only 5 patients showed persistent nasal valve stenosis, and were scheduled for revision surgery. Preoperatively, total decongested inspiratory NARs were 0.245 ± 0.091 Pa/cm³/s and decreased significantly after the operation ($p < 0.0005$) to 0.154 ± 0.059 Pa/cm³/s. Similarly, preoperatively total decongested expiratory NARs were 0.188 ± 0.068 Pa/cm³/s and decreased significantly after the operation ($p < 0.0005$) to 0.142 ± 0.059 Pa/cm³/s. Moreover, total dilated inspiratory and expiratory NARs resulted significantly ($p < 0.0005$) lower than the preoperatively total decongested NARs, with a mean value of 0.120 ± 0.059 Pa/cm³/s and 0.102 ± 0.057 Pa/cm³/s, respectively. Statistical analysis did not reveal any influence of sex and age in rhinomanometric measurements. Hemitransfixion incision allowed a wide access to the whole valve area for inspection and correction of the various components. Rhinomanometry, performed in a decongested condition and after dilation test, was thus a useful diagnostic tool for the preoperative diagnosis of nasal valve obstruction and permitted to assess quantitatively the favourable effect of surgical procedures.

KEY WORDS: Rhinoplasty • Nasal valve • Rhinomanometry

RIASSUNTO

La valvola nasale svolge un ruolo chiave nell'ambito della respirazione del naso. In letteratura sono state descritte una grande varietà di tecniche per la correzione delle alterazioni valvolari, ma, a tutt'oggi, non vi è chiara evidenza che consenta di informare il paziente su quale sia la procedura più efficace. Lo scopo di questo studio è valutare i risultati della chirurgia valvolare eseguita attraverso l'incisione emitrasfissa con metodica oggettiva attraverso studio endoscopico e rinomanometrico. Il gruppo di studio è rappresentato da 54 maschi e 15 femmine di età media pari a $41,8 \pm 14,4$ anni, (range: 21-72 anni). Dopo un periodo di osservazione di $8 \pm 4,1$ mesi, l'endoscopia nasale ha consentito di apprezzare gli effetti favorevoli del trattamento chirurgico con una normalizzazione degli angoli valvolari. Solo 5 pazienti hanno manifestato una stenosi valvolare persistente e per tale motivo sono stati programmati per una chirurgia di revisione. Preoperatoriamente, le resistenze inspiratorie totali dopo decongestione sono risultate pari a $0,245 \pm 0,091$ Pa/cm³/s e si sono ridotte in modo significativo dopo l'intervento ($p < 0,0005$), risultando pari a $0,154 \pm 0,059$ Pa/cm³/s. Allo stesso modo, preoperatoriamente, le resistenze espiratorie totali dopo decongestione sono risultate pari a $0,188 \pm 0,068$ Pa/cm³/s e si sono ridotte in modo significativo dopo l'intervento ($p < 0,0005$), risultando pari a $0,142 \pm 0,059$ Pa/cm³/s. Anche le resistenze inspiratorie ed espiratorie totali dopo dilatazione sono risultate significativamente ($p < 0,0005$) più basse rispetto a quelle preoperatorie dopo decongestione con un valore medio di $0,120 \pm 0,059$ Pa/cm³/s e $0,102 \pm 0,057$ Pa/cm³/s, rispettivamente. L'analisi statistica non ha inoltre rilevato alcuna influenza del sesso e dell'età sui risultati finali. L'incisione emitrasfissa ha consentito un ampio accesso all'intera regione valvolare per l'ispezione e la correzione delle varie componenti. La rinomanometria eseguita in condizioni di decongestione e dopo test di dilatazione ha dimostrato di essere uno strumento diagnostico utile per la diagnosi preoperatoria dell'ostruzione valvolare e ha permesso di valutare quantitativamente gli effetti favorevoli delle procedure chirurgiche effettuate.

PAROLE CHIAVE: Rinoplastica • Valvola nasale • Rinomanometria

Acta Otorhinolaryngol Ital 2013;33:196-201

Introduction

The nasal valve region plays a key role in nasal breathing¹. Physiological studies demonstrate that this complex region significantly regulates both nasal airflow and nasal resistance. In fact, the nasal valve is responsible for 70% of nasal respiratory resistances² and 44% of the

total inspiratory resistance³. Even small deformities of this region can turn into relevant increments in inspiratory resistance, thus compromising the performance of the subject, above all during physical effort, and sometimes causing disturbances during sleep⁴. In the international literature, a variety of techniques have been described to rectify nasal obstruction caused by nasal valve impair-

ment⁵, but there are no randomized trials to compare the outcome of different procedures to date. Most studies are based on heterogeneous groups of patients with a mixture of pathologies, and, furthermore, interventions are often multiple. Based on the present evidence, it is impossible to counsel a patient as to which technique is most effective⁶.

The primary goals of surgery of the nasal valve are essentially to restore normal anatomy of the nasal valve and improve airflow without increasing either rigidity or collapsibility of the nasal valve. A systematic approach to surgery requires that the surgeon be aware of the possible sites and types of abnormalities that may be present. The surgeon must have the technical ability to explore the various regions and to deal with any mucocutaneous disturbance that may be present. Any systematic surgery of the valve area should therefore adopt an approach allowing wide access for inspection and correction of the various components. Such procedures should carry a minimum risk of respiratory complications and aesthetic defects. In light of these principles, we are experienced in performing surgery of the nasal valve exclusively through the hemitransfixion incision^{7,8}. Long-term outcome measurement is an essential aspect in the assessment of all surgical techniques. Spielmann et al.⁶, in a recent review, state that functional nasal surgery studies that examine whether there is sustained long-term benefit at 1 or 2 years after intervention are greatly needed, while an objective measurement of airflow would also make a necessary contribution. The aim of this study is to evaluate objectively the results of surgery of the nasal valve through the hemitransfixion incision using rhinomanometry in the long term.

Materials and methods

For the purpose of this study, clinical records of patients who had undergone nasal valve surgery at Imola Hospital between January 2011 and June 2011 were retrospectively revised to evaluate the effect of surgical treatment. Inclusion criteria were all types of nasal valve compromise with complete rhinomanometric documentation at the end point follow-up. Exclusion criteria were referred postoperative nasal trauma and those cases in which valve surgery was performed as an ancillary procedure to rhinoplasty. Patients who fulfilled inclusion criteria were recruited for the present investigation and were analyzed with nasal endoscopy and rhinomanometry.

Nasal endoscopy was performed by a rigid, 0° nasal endoscope with a diameter of 4 mm in order to evaluate nasal valve function in the static condition and during respiration. Both preoperatively and postoperatively nasal resistances and flow were measured in the resting state by anterior active rhinomanometry according to the recommendations of SCOANA⁹ and using the RhinoPocket® device. A facemask was used to ensure a good seal and

to avoid distortion of the nose. Only decongested nasal airway resistance (NAR) values were taken into consideration to avoid mucosal resistive changes and evaluate uniquely the effect of surgery on structural components of the nasal valve area. Decongestion was accomplished by the application of three sprays of 0.1% xylometazoline to each nostril. A dilation test was also performed preoperatively using the DAN Air® dilator to confirm the impairment of nasal valve function. Total inspiratory and expiratory NARs were calculated using the reference pressure at 150 Pascal.

A paired *t*-test was performed to assess differences between preoperative decongested and dilated NAR values and decongested NAR values before and after the operation. The unpaired *t*-test was used to check for differences according to sex, while Pearson's correlation was used to analyze the influence of age and sex on final results. All continuous data were presented in terms of means and standard deviation of the mean. For all tests, a value of $p < 0.05$ was considered significant. All analyses and graphs were realized using Statistical Package for the Social Science (SPSS) 15.0 for Windows (SPSS, Inc, Chicago, IL)

Patients were treated surgically according to the following techniques:

*Septal surgery*¹⁰: conventional septoplasty was achieved by making a vertical incision in the quadrangular cartilage anterior to the perpendicular plate of the ethmoid, freeing the caudal end of the septum from its crest. If, by uncovering the septum and freeing it of its posterior and inferior attachments, the deflection was reduced and the septum swung to the midline, relieving the nasal valve obstruction, the operation was concluded. In case of marked deviation of anterior septum, an extracorporeal septoplasty was performed¹¹.

*Internal nasal valve correction*⁷: starting from the hemitransfixion incision, extramucosal skeletonization of the endonasal section of the middle vault allowed for the exposure of supero-medial, superior and lateral aspect of the valve area (Fig. 1). Deformities of the caudal margin of the upper lateral cartilages (ULCs) were corrected, as well as thickening or deflections of the superior segment of the septum, thickening of the septal space caused by post-traumatic or postsurgical scar connective tissue. The septum-upper lateral cartilage complex was contoured to restore a normal anatomic relationship and a physiologic valve angle. Using the same maxilla-premaxilla approach, the anterior nasal spine was adequately exposed along with the piriform apertures and the caudal septal cartilage. In this way, anomalous positioning and structural defects were corrected. In case of particularly restricted nasal valves, spreader grafts were fixed to the exerted quadrangular cartilage and repositioned sub-perichondrially with the septum in order to enlarge the valve angles¹² (Fig. 2).

*External nasal valve correction*¹³: morphologic colu-

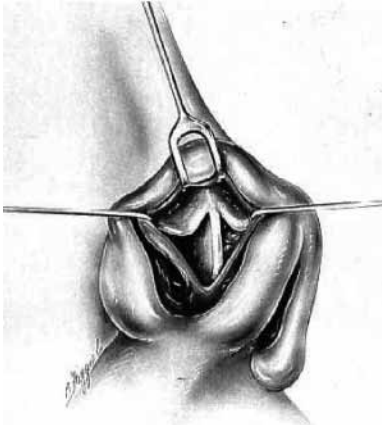


Fig. 1. Schematic representation of the internal nasal valve exposed through the hemitransfixion incision approach.



Fig. 2. Suturing of spreader grafts to the exerted cartilaginous septum in extracorporeal septoplasty.

mellar anomalies were corrected by columelloplasty. The acute naso-labial angle was adjusted by placing an intracolumellar strut. Lobule surgery was performed adopting a dome-preserving technique and a retrograde raising of the lower lateral cartilages (LLCs).

*Turbinate surgery*¹³: inferior turbinate hypertrophy causing the obstruction of the nasal valve area was treated by the submucous resection technique according to Sulstenti.

Results

The group of patients consisted of 54 males and 15 females with a mean age of 41.8 ± 14.4 years, (range: 21-72 years). All patients were operated on through a hemitransfixion incision. A total of 161 procedures were carried out. In particular, conventional and extracorporeal septoplasty were performed, respectively, in 32 and 34 cases, turbinate surgery in 52 cases, and columelloplasty in 11 cases. Spreader grafts were positioned in 11 patients. Moreover,

14 patients had correction of the ULCs, 7 patients had an intracolumellar strut, 5 patients had retrograde raising of the LLCs, 3 patients had correction of the anterior nasal spine and 2 patients had correction of the piriform crests. In one case, revision surgery was performed following a previous unsatisfactory rhinoseptoplasty procedure. Only 11 patients had one exclusive treatment, whereas 32 patients were treated by 2 procedures. The remaining patients received 3 or more procedures.

The mean follow-up was 8 ± 4.1 months (range: 1-15 months). Nasal endoscopy, performed at last follow-up, permitted to appreciate the favourable effects of the surgical treatment with a normalization of the nasal valve angles. Only 5 patients manifested a persistent nasal valve stenosis and were scheduled for a revision surgery.

Preoperatively total decongested inspiratory NARs was 0.245 ± 0.091 Pa/cm³/s and decreased significantly after the operation ($p < 0.0005$) to 0.154 ± 0.059 Pa/cm³/s. Similarly, preoperatively total decongested expiratory NARs resulted 0.188 ± 0.068 Pa/cm³/s and decreased significantly after the operation ($p < 0.0005$) to 0.142 ± 0.059 Pa/cm³/s. Also, total dilated inspiratory and expiratory NARs were significantly ($p < 0.0005$) lower than the preoperatively total decongested NARs, with a mean value of 0.120 ± 0.059 Pa/cm³/s and 0.102 ± 0.057 Pa/cm³/s, respectively. Statistical analysis did not reveal any influence of sex and age over the rhinomanometric measurements.

Discussion

Knowledge of the structure and function of the nasal valve region is required by all those who operate on the nose¹⁴. The nasal valve can be divided into the internal nasal valve and external nasal valve. The internal nasal valve, as described by Mink¹⁵ in 1903, corresponds to the slit-like opening between the caudal end of the ULCs and the nasal septum. However, this region is only a portion of the more extended nasal valve area, which is the narrowest three-dimensional segment of the entire pathway. This area is in fact delimited^{16,17} supero-laterally, from the caudal end of the ULCs; laterally, from the "empty triangle", an approximately triangular region, without cartilaginous support structures made of fibrous-adipose tissue up to the margin of the piriform aperture, where the accessory cartilages can be found; medially, from the cartilaginous septum; inferiorly, from the inferior margin of the piriform aperture; infero-medially, from the wings of the spine and from the premaxilla; posteriorly, from the head of the inferior turbinate. The external nasal valve is described as the cross-sectional area caudal to the internal valve under the alar lobule, bounded supero-laterally by the caudal edge of the UCLs, laterally by the nasal alar and ligamentous attachment of the lateral crus, medially by the caudal septum and columella and inferiorly by the nasal sill. Both internal and external nasal valves can be

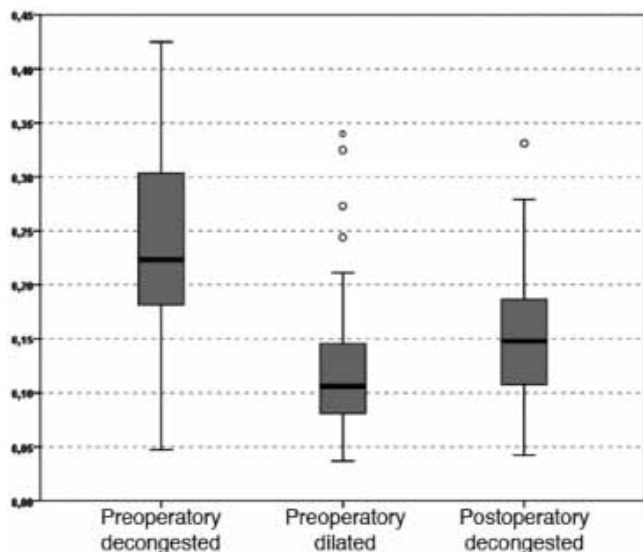


Fig. 3. The graph shows that preoperative total inspiratory decongested NARs would decrease significantly after the surgical treatment; similarly, preoperative dilated NARs decrease significantly compared to preoperative decongested NARs.

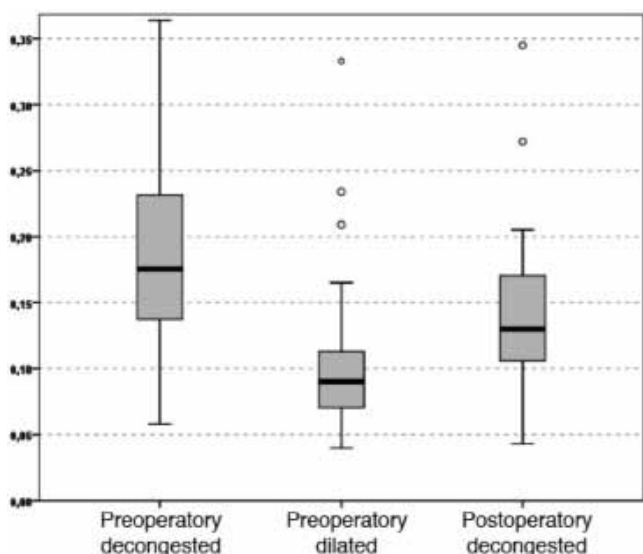


Fig. 4. The graph shows that preoperative total expiratory decongested NARs would decrease significantly after the surgical treatment; similarly, preoperative dilated NARs decrease significantly compared to preoperative decongested NARs.

affected by static structural deformities and/or dynamic abnormalities. In particular, static alterations of the internal nasal valve can be caused by inferomedially displaced ULCs, narrowed pyriform aperture, scarring at the intercartilaginous junction, deviated nasal septum and inferior turbinate hypertrophy. Dynamic deformities are often secondary to destabilization of the septum and LLCs, resulting in ULC collapse¹⁸. Static external valve compromise can be caused by scars on the nasal vestibule due to iatrogenic or post-traumatic amputations of the internal covering, or by circular stenosing scars from incorrect

placement or closing of vestibular incisions. Dynamic incompetence may be due to nasal musculature alterations due to paralysis of the facial nerve¹⁹. In most cases, however, the muscular disease of the valve is congenital or a phenomenon induced by age. In the latter case, combined phenomena of muscular atrophy, weakening of the intrinsic tension of the cartilaginous ring, and loss of the telescopic relationship between ULCs and LLCs produce the characteristic functional-aesthetic stigmata of the lateral wall collapse and fall of the tip.

Among the various aetiologies, rhinoplasty can be a frequent cause of valve function impairment. In 1995, Grymer²⁰, in a prospective study by acoustic rhinometry, verified a 25% decrease in cross-sectional area at the nasal valve after aesthetic reduction rhinoplasty. In the past years, several techniques have been described to avoid nasal valve compromise after rhinoplasty, often with high success rates. In a recent systematic review, Rhee et al.²¹ found that there is substantial level evidence to support the efficacy of modern-day rhinoplasty techniques for treatment of nasal obstruction due to nasal valve collapse. An initial contribution to this issue was given by the introduction of the spreader grafts²² and by the variations on the theme^{23,24}, whereas the alar batten grafts²⁵, nasal valve suspension²⁶, flaring suture technique²⁷ and splay graft²⁸ are further procedures that address to the normalization of nasal function in case of nasal valve compromise.

In another recent systematic review aimed to critically evaluate the surgical treatment strategies for nasal valve collapse, Spielmann et al.⁶ found that, among a variety of surgical techniques, there are no randomized controlled trials on nasal valve surgery; in this investigation, the general impression was that research in nasal valve surgery is frequently driven by technical description of surgical techniques rather than the establishment of evidence of long-term patient benefit. Because of this relative paucity of strong primary studies in the literature, Rhee et al.²⁹ recently proposed a clinical consensus statement to address ambiguities and disparities in the diagnosis and management of nasal valve compromise. The panel generally agreed that nasal valve compromise is a distinct clinical entity that is best evaluated with history and physical examination finding. Also, Apaydin³⁰ stressed the importance of a thorough analysis that should understand the cause for nasal obstruction so that one or multiple procedures can be chosen according to each individual problem. The key, as in much nasal surgery, is to select the appropriate management for each individual patient.

Hence, preoperative nasal valve analysis needs to be done carefully. Physical examination is best accomplished with a nasal endoscope³¹, since the introduction of the nasal speculum in the nasal vestibule deforms the septum-lateral cartilage complex and thus is not suited to evaluate the nasal valve correctly. Clinical inspection can be also associated with the Cottle test that consists of an improve-

ment in ipsilateral nasal patency after pulling laterally on the cheeks. Alternatively, a small ear curette can be used to perform a modified Cottle test that permits separate examination of specific deficiencies in ULCs and LLCs.

An objective method to assess nasal valve stenosis is rhinomanometry with the help of topical vasoconstrictor agent and nasal dilators^{32,33}. Rhinomanometry is a dynamic means to examine nasal cavity patency and nasal function; it aims at establishing nasal resistance, which is the difficulty of passing air through the nose through measurement of transnasal pressure and air flow. In the presence of nasal valve compromise, rhinomanometry, performed in a decongested condition, presents a very typical curve: in fact, the curve shows a reduction in air-flow even with an increase in negative pressure⁶. In this case, the application of a nasal dilator determines normalization of the curve and objectively represents the presence of valve stenosis (Fig. 5). In our rhinologic laboratory, we routinely perform the dilation test during clinical practice to document nasal valve stenosis. In particular, we have adopted the DAN Air® which is an internal nasal dilator that has shown to be a reliable device for diagnosis of nasal valve compromise. In fact, compared to external nasal dilators, it is not influenced by the inevitable variations due to the different elasticity of the tissues since it has the advantage of maintaining the opening of the nasal cavity constant with a physiologic valve angle of 15°. We think that this characteristic is particularly useful, above all, for the investigation of external lateral wall collapse.

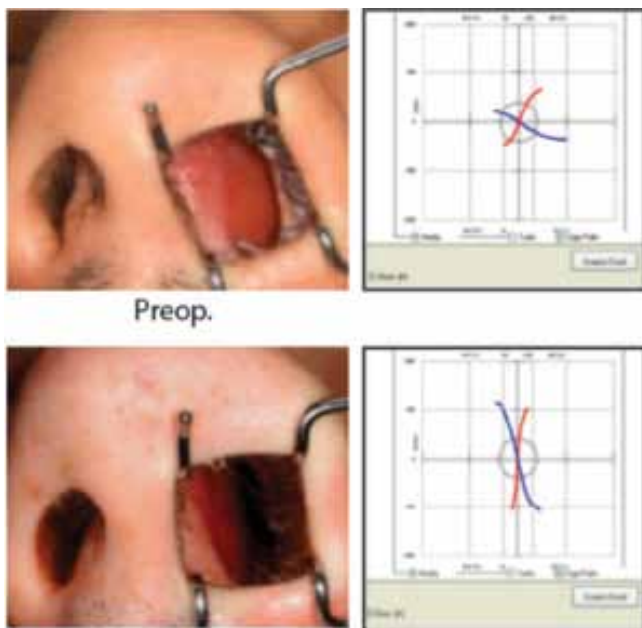


Fig. 5. Rhinomanometric documentation of left nasal valve compromise due to obstructive septum deviation on the left side. In the preoperative condition, the sigmoid representation of decongested NARs manifests a very typical curve. Postsurgery, the favourable outcome is confirmed by normalization of rhinomanometric testing, even in the basal condition.

In operating on the nasal valve region, septal surgery should be considered first since septal abnormalities represent the most frequent cause of nasal valve obstruction. Even in case of anterior septal deviation associated with contralateral alar collapse, septoplasty alone, without the necessity of surgery involving the external nasal valve, is able to resolve nasal obstructive impairment³⁴. A straight septum is important for unimpaired nasal valve function³⁵. Accordingly, the most part of the procedures reported in the present study also consisted of nasal septum repair. If surgery on the septum does not remove nasal valve obstruction, the UCLs should be explored next and eventually corrected. Furthermore, again through hemitransfixion incision, different types of grafts may be positioned. An intracolumellar strut is able to correct an acute nose-labial angle, that usually plays the role to move the main inspiratory flow toward the highest portion of the nasal cavity, producing vortexes with an increase in nasal resistance. Spreader grafts are capable to reconstruct the internal nasal valve and also recontour the middle nasal vault. In the event of structural valve collapse due to loss of the lateral cartilages, cartilaginous batten grafts can be introduced through the same route and positioned above the remnants of the lateral cartilages, thereby creating a more resistant wall that will not collapse during inspiration¹³.

Conclusions

The hemitransfixion incision allowed performing a range of corrections on the various anatomic sub-units of the nasal valve thanks to wide access of the entire valve area. Rhinomanometry, performed in a decongested condition and after dilation test, is a useful diagnostic tool for preoperative diagnosis of nasal valve obstruction and permits quantitative assessment of the favourable effects of surgical procedures. Accordingly, pre- and post-operative objective measurement of nasal airflow should not remain a research tool since it is useful in the assessment and counselling of patients and for measuring the outcomes of surgery.

References

- 1 Haight JS, Cole P. *The site and function of the nasal valve.* Laryngoscope 1983;93:49-55.
- 2 Uddstromer M. *Nasal respiration: a critical survey of some current physiological and clinical aspects on the respiratory mechanism with a description of a new method of diagnosis.* Acta Otolaryngol 1940;(Suppl. 42):3-146.
- 3 Mann DG, Sasaki CT, Suzuki M, et al. *Dilator nasi muscle.* Ann Otol 1977;86:362-72.
- 4 Irvine BWH, Dayal WS, Philippon EA. *Sleep apnea due to nasal valve obstruction.* J Otolaryngol 1984;13:37-8.
- 5 Yarlagadda BB, Dolan RW. *Nasal valve dysfunction: diagnosis and treatment.* Curr Opin Otolaryngol Head Neck Surg 2011;19:25-9.

- ⁶ Spielmann PM, White PS, Hussain SS. *Surgical techniques for the treatment of nasal valve collapse: a systematic review*. Laryngoscope 2009;119:1281-90.
- ⁷ Sulsenti G, Palma P. *A new technique for functional surgery of the nasal valve area*. Rhinology 1989;(Suppl. 10):3-19.
- ⁸ Sulsenti G, Palma P. *Nasal valve surgery through hemitransfixion incision: Functional results assessed by rhinomanometry*. Facial Plastic Surgery 1990;7:315-26.
- ⁹ Clement PAR, Gordts F. *Consensus report on acoustic rhinometry and rhinomanometry*. Rhinology 2005;43:169-79.
- ¹⁰ Cottle MH, Loring RL, Fischer GF, et al. *The maxilla-premaxilla approach to extensive nasal septum surgery*. Arch Otolaryngol 1958;68:301-13.
- ¹¹ Gubisch W. *Extracorporeal septoplasty for the markedly deviated septum*. Arch Facial Plast Surg 2005;7:218-26.
- ¹² André RF, Paun SH, Vuyk HD. *Endonasal spreader graft placement as treatment for internal nasal valve insufficiency: no need to divide the upper lateral cartilages from the septum*. Arch Facial Plast Surg 2004;6:36-40.
- ¹³ Sulsenti G, Palma P. *Tailored nasal surgery for normalization of nasal resistance*. Facial Plast Surg 1996;12:333-45.
- ¹⁴ Kasperbauer JL, Kern EB. *Nasal valve physiology. Implications in nasal surgery*. Otolaryngol Clin North Am 1987;20:699-719.
- ¹⁵ Mink PJ. *Physiologie der Oberen Luftwege*. Leipzig. Germany: Vogel;1920.
- ¹⁶ Sulsenti G, Palma P. *The nasal valve area: structure, function, clinical aspects and treatment. Sulsenti's technic for correction of valve deformities*. Acta Otorhinolaryngol Ital 1989;9(Suppl. 22):1-25.
- ¹⁷ Kern EB, Wang TD. *Nasal valve surgery*. In: Daniel RK, editor. *Aesthetic Plastic Surgery: Rhinoplasty*. Boston: Little, Brown; 1993. pp. 613-630.
- ¹⁸ Lee J, White WM, Constantinides M. *Surgical and nonsurgical treatments of the nasal valves*. Otolaryngol Clin North Am 2009;42:495-511.
- ¹⁹ May M, West JJ, Hinderer KK. *Nasal obstruction from facial palsy*. Arch Otolaryngol 1977;103:389-91.
- ²⁰ Grymer LF. *Reduction rhinoplasty and nasal patency: change in the cross-sectional area of the nose evaluated by acoustic rhinometry*. Laryngoscope 1995;105:429-31.
- ²¹ Rhee JS, Arganbright JM, McMullin BT, et al. *Evidence supporting functional rhinoplasty or nasal valve repair: A 25-year systematic review*. Otolaryngol Head Neck Surg 2008;139:10-20.
- ²² Sheen JH. *Spreader graft: a method of reconstructing the roof of the middle nasal vault following rhinoplasty*. Plast Reconstr Surg 1984;73:230-9.
- ²³ Sciuto S, Bernardeschi D. *Upper lateral cartilage suspension over dorsal grafts: a treatment for internal nasal valve dynamic incompetence*. Facial Plast Surg 1999;15:309-16.
- ²⁴ Boccieri A, Macro C, Pascali M. *The use of spreader grafts in primary rhinoplasty*. Ann Plast Surg 2005;55:127-31.
- ²⁵ Toriumi DM, Josen J, Weinberger M, et al. *Use of alar batten grafts for correction of nasal valve collapse*. Arch Otolaryngol Head Neck Surg 1997;123:802-808.
- ²⁶ Paniello RC. *Nasal valve suspension. An effective treatment for nasal valve collapse*. Arch Otolaryngol Head Neck Surg 1996;122:1342-6.
- ²⁷ Park SS. *The flaring suture to augment the repair of the dysfunctional nasal valve*. Plast Reconstr Surg 1998;101:1120-2.
- ²⁸ Guyuron B, Michelow BJ, Englehardt C. *Upper lateral splay graft*. Plast Reconstr Surg 1998;102:2169-77.
- ²⁹ Rhee JS, Weaver EM, Park SS, et al. *Clinical consensus statement: Diagnosis and management of nasal valve compromise*. Otolaryngol Head Neck Surg 2010;143:48-59.
- ³⁰ Apaydin F. *Nasal valve surgery*. Facial Plast Surg 2011;27:179-91.
- ³¹ Keck T, Leiacker R, Kühnemann S, et al. *Video-endoscopy and digital image analysis of the nasal valve area*. Eur ArchOtorhinolaryngol 2006;263:675-9.
- ³² Grützenmacher S, Günther M, Robinson DM, et al. *Investigations for the diagnostic recording of nasal wing collapse*. Laryngoscope 2005;115:1763-7.
- ³³ Roithmann R, Chapnik J, Cole P, et al. *Role of the external nasal dilator in the management of nasal obstruction*. Laryngoscope 1998;108:712-5.
- ³⁴ Schalek P, Hahn A. *Anterior septal deviation and contralateral alar collapse*. B-ENT 2011;7:185-8.
- ³⁵ Urquhart AC, Bersalona F. *Septoplasty: correcting the nasal valve*. Laryngoscope 1997;107:537-9.

Received: December 15, 2012 - Accepted: January 7, 2013