

## Refrigeration-induced skull base fracture: three autopsy cases

Man Liang<sup>1,a</sup>, Liu Yan<sup>1,a</sup>, Ananda Sunnasee<sup>1</sup>, Na Zheng<sup>1</sup>, Zhang Haidong<sup>2</sup>, Luo Zhuo<sup>1</sup>, Liu Liang<sup>2\*</sup>

**Abstract:** Three cases of death are described where all the refrigerated skull of corpses showed cranial base fracture. A question arose whether these fractures were caused by head injury. As the details were clear and both autopsy and relative pathological findings displayed nothing positive, it was presumed that the cranial base fracture was due to the expansion of brain volume and increased intracranial pressure after refrigeration. And the evidence showed that the suspicious fracture was to be classified as an uncommon refrigeration-induced post-mortem artefact.

**Key words:** forensic pathology, refrigerated human corpse, skull base fracture, refrigeration-induced artefact

Differentiating between ante-mortem and post-mortem injuries is one of the key problems in the forensic examination of cranial base fracture [1]. Severe freezing to death and refrigeration of corpse can induce skull base fractures, which could complicate the diagnosis of head injury and thus the cause of death [2, 3].

In the present cases, skull base fractures were revealed at autopsy after the corpses had been refrigerated for a certain period of time. It was suspected that these fractures were the result of an uncommon phenomenon known as refrigeration-induced postmortem artifact. We hereby present three cases of refrigeration induced postmortem skull base fracture.

### 1. Case report

#### 1.1 Case 1. Case presentation

A 39-year-old man had an argument with his neighbours regarding crop-land matters and the case was referred to the local police station a week later. At the police station, while this man was explaining the details of the problem, he complained of malaise and was immediately taken to the nearby clinic. However, his condition deteriorated while at the clinic and showed increased sweating, chest pain, nausea and he passed away the same day despite resuscitation attempts.

The medical report and preliminary investigations showed that he had a cardiovascular event. He had no prior history of disease or hospital admissions and he was seen as a very healthy and active man by his close peers. The family requested a forensic autopsy be performed. The corpse was refrigerated (at -18°C) until autopsy which was carried out 14 days after death.

#### Autopsy findings

On external examination, after the corpse was derefrigerated, dark red-purplish postmortem hypostasis was present on the back and other dorsal parts of the body. There were no signs of external trauma to the head.

---

1) Department of Forensic Medicine, Tongji Medical College, Huazhong University of Science and Technology, 430030, Wuhan, People's Republic of China

2) Key Laboratory of Evidence Science (China University of Political Science and Law), Ministry of Education, 100040, Beijing, China

\*Corresponding author, professor. Tel: +86-18971341357; Fax: +86-027-83692638;

E-mail: casper603@gmail.com

b) These authors contributed equally to this work.

Conjunctivae were pale without petechial haemorrhages, while corneas were markedly turbid and pupils were not clearly visible. A piece of brain-like tissue was observed in the right nasal cavity (Fig 1). No liquid were found in oral cavity, left nasal cavity and external auditory canal. Marbling was seen all over the putrefying cadaver. Finger nails of both hands showed cyanosis and parchment-like transformation.

There was no injury on the scalp and epicranial aponeurosis. An “L”-shaped crack fracture of the cranial base was observed near the crista galli in the right anterior cranial fossa (Fig 2) with corresponding superficial brain tissue split (approximately 2.0 cm × 4.0 cm) but without hematoma. The brain was swollen, weighing 1505 g; cut surfaces did not show any abnormalities. Hemangiectasis and congestion with transudative haemorrhage were noticed. Obvious cerebral arteriolar sclerosis was found in parenchyma.

The heart weighed 366 g and was hypertrophic. No chamber dilatation was present. The thicknesses of left and right ventricular walls and interventricular septum were 1.9 cm, 0.5 cm and 1.8 cm, respectively. Stenosis of the lumen of the proximal left anterior descending branch was obvious (50%-75% constriction). The openings of left circumflex and right coronary artery showed slight luminal narrowing.

Microscopic examination of the cardiac tissue showed slight adipose infiltration into the right ventricular wall and loss of cross striations of cardiomyocytes. Arteriolosclerosis and stenosis were obvious in the myocardium of the ventricular septum. Papillary muscle fibers were disrupted. Sections through the AV-node did not reveal any abnormalities.

Lungs, liver, kidneys and spleen showed nothing abnormal except arteriosclerosis.

Toxicological analysis for drugs of abuse was negative.

Cause of death was attributed to acute cardiorespiratory failure due to acute myocardial ischemia induced by emotional stress and complicated by underlying coronary disease and arteriolosclerosis.

## 1.2 Case 2

### Case presentation

A 47-year-old man was serving a sentence of 74 days in prison due to larceny. One morning he was found dead in his cell-bed. There was no report of any incident in which he was involved, nor did he had any history of illness as mentioned by the prison medical officers. The deceased family confirmed that he was not a drug abuser and rarely attended hospital. Sudden unexpected death warranted a forensic autopsy. However, due to legal matters, the corpse was kept for seven months in refrigeration after which the decedent's family gave consent for autopsy. During the seven months, the corpse was kept refrigerated at -18°C.

### Autopsy findings

There were no injury on the head and face. No abnormalities were observed on the eyes, bulbar conjunctiva and palpebral conjunctiva and corneal opacity was significant. There were no unusual secretions (liquids) in the external auditory canal, oral and nasal cavities. Marbling was all over the trunk and limbs. The scalp was intact. The brain weighed 1251 g. A crack fracture (approximately 2.0 cm×2.0 cm) was found in the orbital plate in anterior cranial fossa (Fig 3). There was no splintering of corresponding brain or presence of hemorrhage and hematoma on both surfaces and parenchyma. The heart weighed 316 g, with a few ‘chicken fat clots’ in the chambers of the heart. The intimal surface of the coronary arteries was slightly thickened. The superior lobe of the left lung and right lung adhered to the pleura. Multiple cysts, which were full of liquid, were observed on the surfaces of both kidneys. No abnormality was detected in other organs. Microscopic examination of all organs failed to reveal any significant pathology except for some inflammatory cells, especially leukomonocytes, infiltrated around portal regions in the liver.

Toxicological analysis for common drugs of abuse was negative.

According to the decedent's physical situation, evidence from monitor recorder and the testimony from prison roommate (that the decedent died during sleep), the cause of death was inferred undetermined.

## 1.3 Case 3

### Case presentation

A 39-year old man had an argument with another man and he was beaten with an iron rod on his backside before law officers got caught of the perpetrator.. Both men were taken to the police station for enquiry. However, the assaultee began complaining of pain on his back and was thus taken to hospital. The man dropped dead unexpectedly in the waiting room and resuscitation attempts were unsuccessful. Medicolegal autopsy was ordered and the corpse was kept in refrigeration at -18°C for 30 days prior to autopsy.

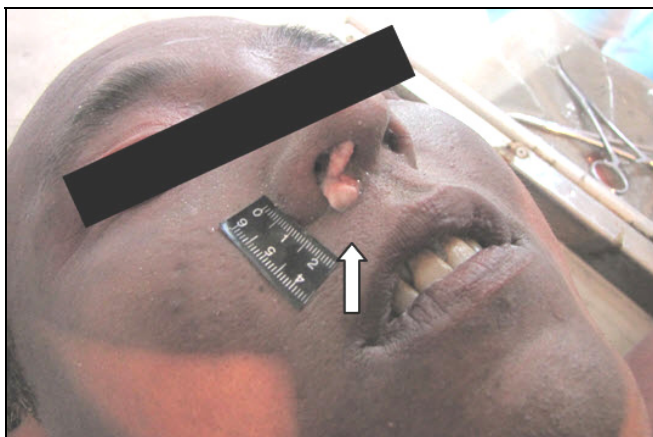### Autopsy findings

Eyes, bulbar conjunctiva and palpebral conjunctiva showed no abnormalities, while corneal opacity was medium. Needle-puncture marks were present on the upper and lower limbs with

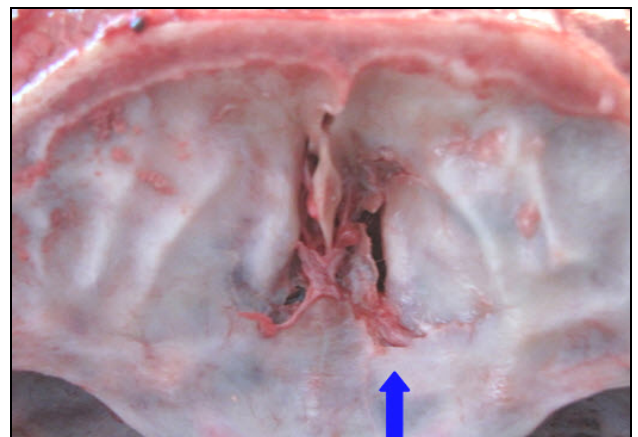
corresponding purplish ecchymoses. A small amount of red liquid flowed out from both nasal cavities. There were several contusions on face and limbs. No scalp injury was noted and the subgaleal layer was clear. The greater wing of sphenoid bone in the right middle cranial fossa had a fracture (Fig 4), with no blood emerging onto the fracture surface and corresponding brain splintering. The 5<sup>th</sup> to 8<sup>th</sup> thoracic vertebra had angulated fracture from superior left to inferior right, which led to correspondent spinal epidural bleeding. The 4<sup>th</sup> to 7<sup>th</sup> ribs had a fracture line 4 cm lateral to left side of the spine, and the 5<sup>th</sup> to 8<sup>th</sup> ribs had a fracture line 3.5 cm lateral to right side of the spine, with large scale hemorrhage (approximately 600ml) into the corresponding injured muscles. The pleura on the left side was fissured while on the right side it was adherent to the lung. Both lungs were collapsed, with the left lung more affected. Other organs displayed nothing abnormal both macroscopically and on microscopic examination.

Toxicological analysis for drugs of abuse was positive for MA (Methamphetamine).

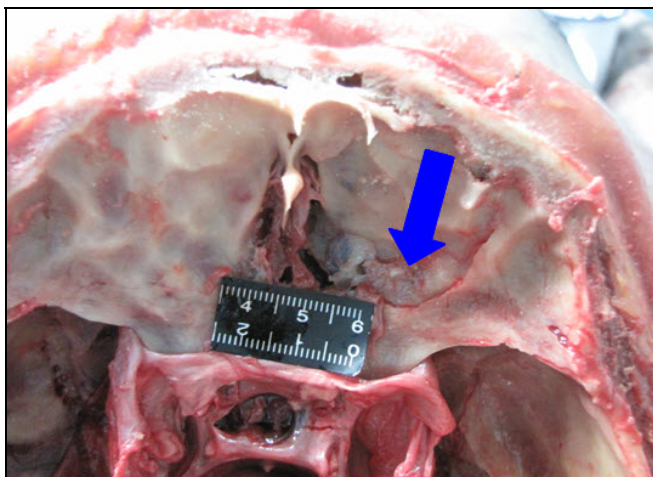
According to the case details, autopsy findings and histopathologic results, the cause of death was due to bilateral pneumothorax as a result of injury to the pleura following ribs fractures.



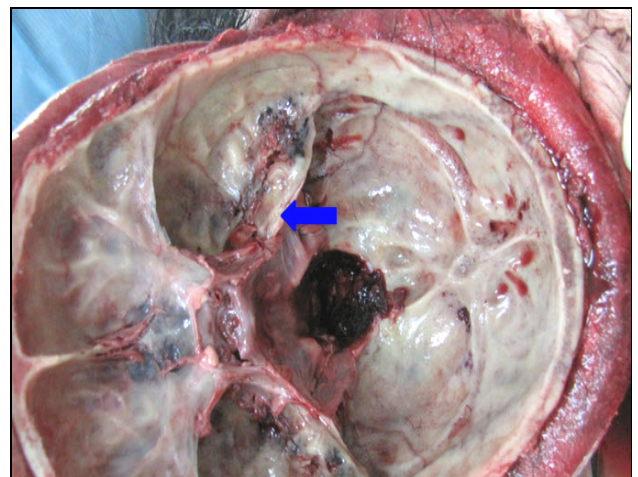
**Fig. 1** A piece of brain-like tissue in right nasal cavity was confirmed, by DNA examination, to be brain tissue of the deceased of case 1.



**Fig. 2** A crack cranial base fracture near the crista galli in right anterior cranial fossa. (Case 1)



**Fig. 3** A crack fracture in orbital plate in anterior cranial fossa. (Case 2)



**Fig. 4** Fracture of greater wing of sphenoid bone in right middle cranial fossa. (Case 3)

## 2 Discussions

The mechanism of wound-like skull base fracture induced by refrigeration depends not only on a loose bony substance and a thin bony structure of the skull [4], but also on the fact that biological tissues expand with cold and contract with heat. The skull is a relatively airtight container, and the water content of the brain is quite high [5]. An unusual physical phenomenon is that water expands when cooled and contracts with heat, especially in a temperature range of 0°C to 4°C. It means that water can show an increase in volume, up to 1/10 increase of its original, when freezing to ice takes place at 0°C; hence, this can lead to significant expansion of brain volume after the corpse is refrigerated [6]. As the corpse is

refrigerated, intracranial pressure is bound to increase due to brain volume expansion and this can induce a skull base fracture at the anatomically thin anterior cranial fossa. Besides, other researches point out that the volume of brain increases to a maximum when the intracranial temperature is 8°C [7, 8]. Since the storage temperature of our 3 cases was obviously below 8°C, it meant that intracranial pressure reached a maximum. The morphology of a skull base fracture produced antemortem is different from that seen postmortem. Skull base fracture produced antemortem is much more complex. It can be caused in situations such as, when external force acting on the ocular region causes supraorbital fracture [9]; when an external force acts directly on the head causing deformation of the skull and leading to fracture in the anterior cranial fossa [10]; or concussion of the brain leading to skull base fracture [11]. An antemortem skull base fracture can be very diffuse, usually involving the anterior, medial, and posterior cranial fossa. It is usually a linear fracture and runs in the same direction as the impact. Contusion, disruption or hemorrhage can be present in the brain [12]. The nature of the cases can usually be inferred from their history, necropsy and microscopic findings. Compared with previous documents [13, 14] and the 3 cases mentioned above, it can be concluded that postmortem skull base fracture appears to involve simple fractures, such as linear fractures, ring fractures, semi-circular fractures. The fractures are usually limited to the cribriform plate and orbital plate where the bony structure is much looser [15]. In a postmortem ring fracture or comminuted fracture, bony fragments would collapse from inner calvarium and form an extracranial depression, and there can be ipsilateral protrusion of brain tissue to the exterior through the nasal cavities, as seen in case 1 where the brain-like tissue was confirmed by DNA examination to be brain tissue. No skull fracture, epidural hematoma, subdural hemorrhage, tissue hemorrhage surrounding the fracture site, palpebral hemorrhage or 'panda eyes sign' could be seen [16]. There were no clues showing violence. In addition, vital reaction around a fractured skull could indicate whether it was produced antemortem or postmortem. In an antemortem fracture, traces of blood would permeate and infiltrate along the micro fracture lines and form what is known as 'Yam bone (guyin)' [17]. In a postmortem fracture, the 'Yam bone' phenomenon is probably absent, which is confirmed in the 3 cases we presented.

Skull base fracture in a corpse is mainly distributed in the anterior, medial and posterior cranial fossa. In some cases (for example case 1), there were be superficial disruption of the corresponding brain tissue, without any signs of antemortem injuries such as hemorrhage surrounding the fracture lines. The fractured flap of bone collapsed from the inner calvarium and protruded to the exterior, which indicated that the direction of the force causing the fracture was from inside to outside. Thus the skull base fractures were not caused by antemortem injury, but most probably by refrigeration storage.

Postmortem fracture of the cranial sutures can be seen in situations where freezing to death occurred and in corpses from refrigeration [18]. This deserves the attention of medicolegal examiners performing autopsies. Such postmortem skull base fracture can easily be mistaken for antemortem injury and can thus have unwarranted legal implications and even cause further family bereavement. Hence, it is important to distinguish between postmortem artifact and antemortem injury in corpses kept under long term refrigeration. It is hoped that research could help to further confirm this phenomenon.

## References

1. Cordner SM. Deciding the cause of death after necropsy. *Lancet*. 1993; 341: 1458-1460.
2. Ingber DE. The architecture of life. *Scientific American*. 1998; 1: 48-57.
3. Moskalenko YE, Kravchenko TI, Gaidar BV, et al. Periodic mobility of cranial bones in humans. *Human Physiology*. 1999; 25: 51-58.
4. Payne-James J, Busuttill A, Smock WE. *Forensic medicine: clinical and pathological aspects*. Greenwich Medical Media Ltd., London, San Francisco. 2003: 271.
5. Haug RH, Greenberg AM. Etiology, distribution and classification of fractures. In: Greenberg AM, editor. *Craniofacial fractures: principles of internal fixation using the AO/ASIF technique*. New York: Springer. 1993. p. 5-20.
6. Hartman SE, Norton JM. Interexaminer reliability in cranial osteopathy. *The Scientific Review of Alternative Medicine*. 2002; 6: 23-35.
7. Michael T, Sheaff D, Hopster J. *Postmortem technique handbook*, 2<sup>nd</sup> ed. London: Springer-Verlag. 2005. p. 78.
8. Miller JD, Ironside JW. Raised intracranial pressure oedema and hydrocephalus. In: Graham DI, Lantos PL, editors. 1996. p. 21-25.
9. Raveh J, Laedrach K, Vuillemin T, Zingg M. Management of combined frontonasal-orbital/skull base fractures and telecanthus in 355 cases. *Arch Otolaryngol Head Neck Surg*. 1992; 118: 605-614.
10. Akita S, Hirano A. Modified coronal incision: Distribution of stress in the scalp and cranium. *Cleft Palate-Craniofacial J*. 1993; 30: 382-386.
11. Konard CJ, Fieber TS, Schuepfer GK, et al. Are fractures of the base of the skull influenced by the mass of the protective? A retrospective study in fatally injured motorcyclists. *J Trauma*. 1996; 41: 854-858.
12. Gee DJ. Reaching conclusions in forensic pathology. *Med Sci Law*. 1995; 35: 12-16.
13. Li JT, Wang J, Huang YZ. Exploration on causes of 3 cases of postmortem fossa cranii anterior fracture. *Chin J Forensic Med*. 2005; 20: 55-56.
14. Jin GS, Zhao S, Cai BC, et al. Refrigeration induced cribriform plate fracture in fossa cranii anterior: 2 cases. *Chin J Forensic Med*. 2006; 21: 247-248.
15. GanYC, Charkravarty D, Flint G. Ring fracture of the skull base: case report and review of the literature. *Br J Neurosurg*. 2002; 16: 300-303.
16. Slupchynskij OS, Berkower AS, Byrne DW, Cayten CG. Association of skull base and facial fractures. *Laryngoscope*. 1992; 102: 1247-1250.
17. Zuo ZJ, Zhu JZ. Study on the microstructures of skull fracture. *Chin J Forens Med*. 1989; 4: 70-74.a
18. Jaslow CR. Mechanical properties of cranial sutures. *J Biomechanics*. 1990; 4: 313-321.