

8. KUCHARZ EJ, JARCZYK R, JONDERKO G, RUBISZ-BRZEZINSKA J, BRZEZINSKA-WCISLO L: High serum level of prolactin in patients with systemic sclerosis. *Clin Rheum* 1996; 15: 314.
9. LAMONTAGNAG, MELI R, CRISCUOLO T, D'ANGELO S, VALENTINI G: Biactivity of prolactin in systemic sclerosis. *Clin Exp Rheumatol* 2004; 22: 145-50.
10. HILTY C, BRUHLMANN P, SPROTT H *et al.*: Altered diurnal rhythm of prolactin in systemic sclerosis. *J Rheumatol* 2000; 27: 2160-5.

Successful treatment of resistant Behçet's disease with etanercept

Sirs,

Behçet's disease (BD) is a chronic, inflammatory vasculitis characterized by oral and genital ulcerations, ocular and skin lesions, arthritis and neurological involvement (1). We report the case of a resistant BD patient who was successfully treated with etanercept.

A 32-year-old woman was admitted at the Rheumatology Unit of the L. Sacco University Hospital in December 2002 for polyarthritis involving the right wrist, left knee, right elbow, proximal interphalangeal joints of the fingers and metatarsophalangeal joints. She also reported an occasional headache. She had a history of recurrent oral and genital aphthous ulcerations, and papulopustular skin lesions (PPL) which started when she was 26 years old. Physical examination revealed a slight fever (37.1°C) and a blood pressure of 120/70 mmHg. She had lost 3 Kg during the last few months. Laboratory findings were as follows: haemoglobin 10g/dl, WBC 6.500/mm³, ESR 55 mm/h, CRP 2.8 mg/dl. The liver and the renal functions were normal.

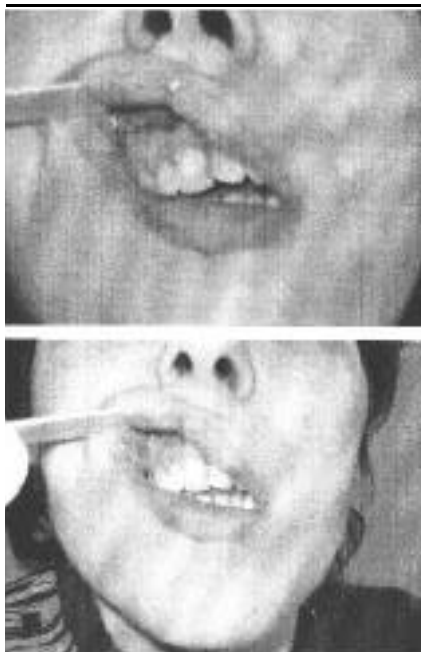


Fig. 1. Oral ulcers in a patient with Behçet disease before and after treatment with etanercept.

RF, ANA and anti-DNA antibodies were negative. Hepatitis B and C, cytomegalovirus, parvovirus B19 and HIV virologies were negative. Anticardiolipin and c and p-ANCA were negative. HLA-B51 was present. Pathergy was negative. Ophthalmological examination detected an anterior uveitis with hypopion. A radiography revealed narrowing of the joint space in the left knee and in the right elbow, erosive changes of the proximal interphalangeal joints, and bone destructive changes in the wrist. Sacroiliac joint involvement was negative.

The diagnosis of BD based on the International Study Group criteria for BD (2) was made and she was treated with oral prednisolone (10 mg/day), methotrexate (MTX) (15 mg/week), and anti-inflammatory agents (NSAIDs). The patient did not tolerate MTX. In April 2003 the disease was severely active. The patient presented with fever, oral ulcers, and polyarthritis; ESR was 99 mm/h, CRP was 5.3 mg/dl. Prednisolone (25 mg/day) and cyclosporin A (CsA) (250 mg/day) were introduced. The treatment was well tolerated by the patient and the corticosteroid dose was tapered.

Four months later the patient presented a PPL on the lower extremities and on the face. Three weeks later the patient presented with acne on the lower extremities, on the face and on the trunk, and oral ulcers. CsA was stopped. An improvement of PPL was observed, but in October 2003 the patient presented with a severe episode of oral and genital aphthae associated with polyarthritis. Treatment with prednisolone 25 mg/day was started. PPD test was negative and chest radiograph did not show any nodular infiltrates. Treatment with etanercept, 25 mg subcutaneously twice a week was started (3). After 4 weeks the lesions disappeared and the polyarthritis improved. At present the patient is in clinical remission (Fig. 1). The current therapy is: MTX (15 mg/week), steroids (7.5 mg/day) and etanercept 25 mg (2 sc weekly injections).

The joint symptoms in BD are present in 40-75% of cases of BD (4, 5). According to Vernon-Roberts *et al.* (6) and Nanke *et al.* (7) joint deformities and destruction have been reported in a few cases. In our case the patient had polyarthritis involving the right wrist, left knee, right elbow, proximal interphalangeal joints of the fingers and metatarsophalangeal joints. The treatment with NSAIDs, corticosteroids and MTX was started as a first-line therapy for BD. MTX is efficacious for arthritis, but this patient did not tolerate it. The patient was treated with CsA but a severe PPL associated with an episode of oral ulcers made it necessary to stop the treatment.

Treatment with anti-TNF- may be useful for the oro-genital ulcerations of BD and for erosive arthritis (8,9). Our findings appear to be the first case in which anti-TNF- is beneficial in the treatment of genital

ulcerations and uncommon erosive arthritis (10).

F. ATZENI¹, MD
P. SARZI-PUTTINI¹, MD
F. CAPSONI², MD
M. MECCHIA³
M.G. MARRAZZA¹, MD
M. CARRABBA¹, MD

¹Rheumatology Unit, L. Sacco University Hospital, Milan; ²Department of Internal Medicine, Ospedale Policlinico, I.R.C.C.S., University of Milan, Milan; ³Wyeth Medical Department, Aprilia (Latina), Italy.

Address correspondence to: Piercarlo Sarzi-Puttini, MD, University Hospital L. Sacco, Rheumatology Unit, Via G.B. Grassi 74, 20157 Milan, Italy. E-mail: sarzi@iisccali.it.

References

1. YAZICI H, YURDAKUL S, HAMURYUDAN V: Behçet's Syndrome. In: KLIPPEL JH, DIEPPE PA (Eds): *Rheumatology*. London Mosby 1998; 7: 26: 1-7.
2. INTERNATIONAL STUDY GROUP FOR BEHÇET'S DISEASE: Criteria for diagnosis of Behçet disease. *Lancet* 1990; 335: 1078-80.
3. MAINI RN, TAYLOR PC: Anti-cytokine therapy in rheumatoid arthritis. *Ann Rev Med* 2000; 51: 207-29.
4. BENAMOUR S, ZEROUAL B, ALAOUI FZ: Joint manifestations in Behçet's disease, a review of 340 cases. *Rev Rheum* 1998; 299-3071
5. SAKANE T, TAKENO M, INABA G: Behçet's disease. *N Engl J Med* 1999; 341: 1284-91.
6. VERNON-ROBERTS B, BARNES CG, REVELL PA: Synovial pathology in Behçet's syndrome. *Ann Rheum Dis* 1978; 37: 139-45.
7. NANKE Y, KOTAKE S, MOMOHARAS, TATEISHI M, YAMANAKA H, KAMATANI N: Synovial histology in three Behçet's disease patients with orthopedic surgery. *Clin Exp Rheumatol* 2002; 20 (Suppl. 26): S35-S39.
8. KAKLAMANI VG, KAKLAMANI PG: Treatment of Behçet's disease- An update. *Semin Arthritis Rheum* 2001; 30: 299-312.
9. MELIKOGLU M, FRESKO I, MATC *et al.*: A double blind placebo controlled trial of etanercept on the mucocutaneous lesions of Behçet syndrome to a TNF- blocker etanercept: an open study. Book of Abstracts. 10th International Congress on Behçet's Disease, Berlin, 2002: Abstr.176
10. SCHEINBERG MA: Treatment of recurrent oral aphthous ulcers with etanercept. *Clin Exp Rheumatol* 2002; 20:733-4.

Can characterization by traditional Korean medical criteria help in our understanding of patients with rheumatoid arthritis ?

Sirs,

Traditional Korean Medicine (TKM) is an ancient discipline that classifies individuals with musculoskeletal problems using very different terms than Western medicine (1-3). TKM relies more on the clinician's reading of the patient's symptoms and signs with little attention to details of joint findings. The relationship between TKM diagnoses and Western concepts of rheumatoid arthritis (RA) have not been previously ex-