Radiology Case Reports

Volume 10, Issue 2, 2015

Osseous femoral avulsion of the anterior cruciate ligament origin in an adult

Samir H. Shah, MD; Jack A. Porrino, MD; Bruce C. Twaddle, MD; and Michael L. Richardson, MD

Injuries of the anterior cruciate ligament are commonly encountered in clinical practice, and occur in a wide variety of settings, from sports-related injuries to polytrauma. Tears of the anterior cruciate ligament supersede osseous avulsion in the adult demographic; however, in the pediatric population, osseous avulsion reflects the most frequent injury. When osseous avulsion of the anterior cruciate ligament occurs in children or adults, the injury typically occurs at the level of the tibial eminence. Conversely, osseous avulsion injuries from the femur are rare, with all cases reported in the literature occurring in the skeletally immature. We report a case of a 47-year-old woman who suffered an osseous avulsion of her anterior cruciate ligament from her lateral femoral condyle. To our knowledge, this reflects the first reported case of femoral osseous avulsion of the anterior cruciate ligament origin in an adult.

Case report

A 47-year-old woman struck by an automobile was airlifted to our emergency department. Multiple pelvic and comminuted intertrochanteric right femoral fractures were identified on her initial pelvic radiographs and computed tomography (CT) study. She was actively bleeding from these injuries, resulting in hemodynamic instability and emergent embolization.

Initial radiographs of the right knee demonstrated open fractures of the tibial plateau and proximal fibula, as well as a small and subtle ossific fragment within the intercondylar notch, adjacent to the medial cortex of the lateral femoral condyle (Fig. 1).

The proximal right femur fracture was fixed with an intramedullary rod and interlocking screws. Wound irrigation of the right tibial plateau and fibular fractures was also

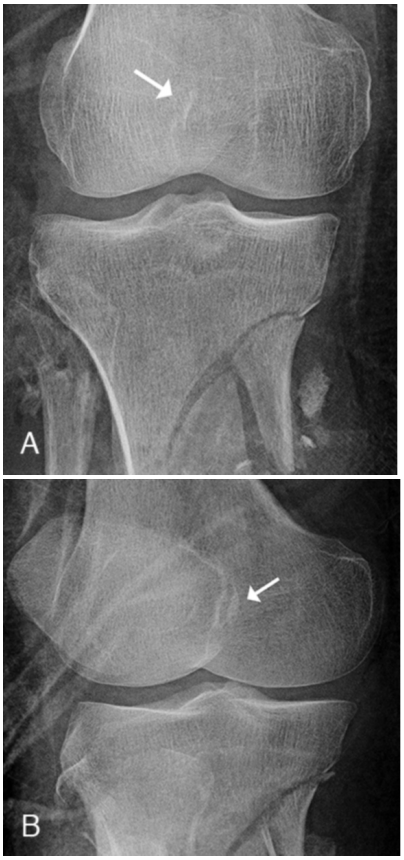

Fig. 1. 47-year-old woman with femoral osseous avulsion of the origin of the anterior cruciate ligament. Frontal (A) and oblique (B) radiographs of the knee demonstrate a small, crescentic, ossific fragment (arrows) adjacent to the medial cortex of the lateral femoral condyle at the expected location of the anterior cruciate ligament origin.

Citation: Shah SH, Porrino JA, Twaddle BC, Richardson ML. Osseous femoral avulsion of the anterior cruciate ligament origin in an adult. *Radiology Case Reports*. (Online) 2015;10(2);1070.

Drs. Shah, Porrino, and Richardson are in the Department of Radiology, and Dr. Twaddle is in the Department of Orthopaedics, all at the University of Washington, Seattle WA. Contact Dr. Porrino at jporrino@uw.edu.

Competing Interests: The authors have declared that no competing interests exist.

DOI: 10.2484/rcr.v10i2.1070

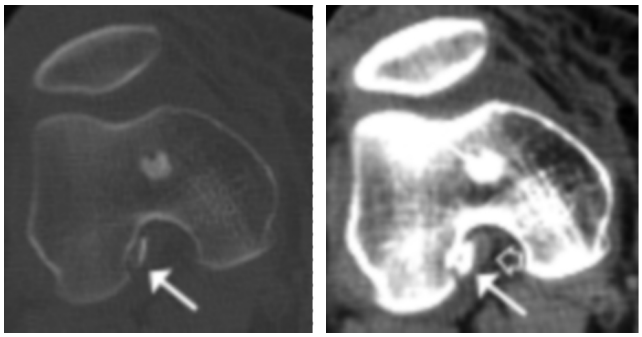

Fig. 2A. Axial view.

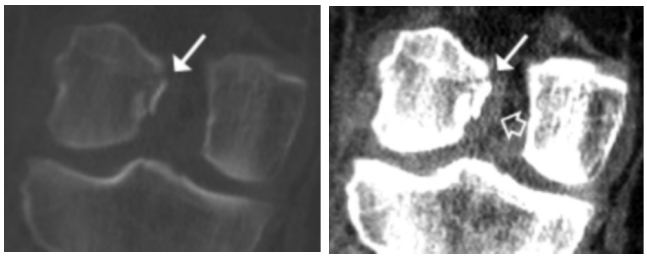

Fig. 2B. Coronal view.

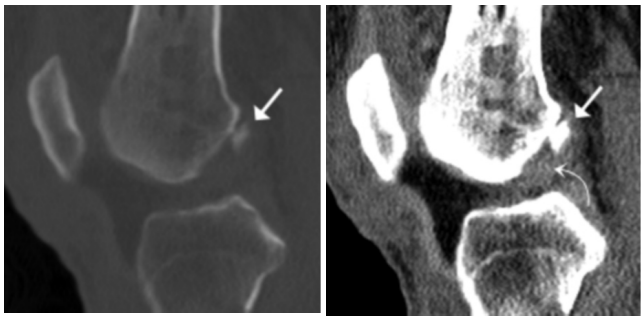

Fig. 2C. Sagittal view.

Fig. 2. 47-year-old woman with femoral osseous avulsion of the origin of the anterior cruciate ligament. Axial (A), coronal (B), and sagittal (C) noncontrast CT imaging with bone and soft-tissue algorithm of the knee demonstrates the avulsed osseous fragment (arrow) and the anterior cruciate ligament (open and curved arrow) arising from the fragment.

performed due to the open nature of these injuries, with definitive repair delayed. Subsequently, an unenhanced CT of the right knee was acquired by the clinical service to further characterize the tibial plateau fracture for preoperative planning purposes. A small avulsed fracture fragment was again noted immediately adjacent to the medial cortex of the lateral femoral condyle, with associated cortical irregularity of the adjacent femur and a grossly intact-appearing anterior cruciate ligament (ACL) attached to the minimally displaced fragment (Fig. 2).

Following repair of the right tibial plateau fracture, a magnetic resonance imaging (MRI) study of the right knee was obtained by the clinical service for a more detailed assessment of the soft tissues. Although poorly depicted by MRI, the avulsed fracture fragment arising from the medial cortex of the lateral femoral condyle was apparent, with marrow edema at the donor site of the lateral femoral condyle. Notably, the ACL was intact (Fig. 3). In addition to the highly comminuted fracture of the proximal fibula, there was avulsion of the distal insertion of the biceps femoris tendon and fibular collateral ligament.

Arthroscopy confirmed osseous femoral avulsion of the ACL origin, with an otherwise intact ACL (Fig. 4). The fracture fragment was reduced provisionally with a Kirschner wire and ultimately fixed with a 4-mm cancellous screw and washer (Fig. 5). Intraoperatively, it was noted that sagittal stability had been successfully restored. A 4-mm cancellous screw and washer were used to stabilize the proximal segment of the fractured fibula. Next, a 3.5-mm anchor was placed into the proximal fibula and used to reattach both the fibular collateral ligament and the biceps femoris tendon.

In addition to the injuries described above, the patient also suffered fractures of the right clavicle, left tibia, and fibula, as well as fractures of multiple lumbar spine transverse processes.

Discussion

In children, epiphyseal chondral and osteochondral ACL avulsions are not uncommon due to relatively elastic connective tissue and correspondingly weaker bony structures (1, 2). Osseous avulsion of the ACL in the pediatric population occurs most commonly at the distal tibial attachment site (1, 2). However, in adults, the ACL tends to tear before osseous avulsion can occur (1, 2). Adult cadaveric models have demonstrated that under typical stressors, osseous avulsion of the ACL is less common than ligament disruption, and when osseous avulsion does occur, it occurs at the level of the tibial eminence (3).

A review of the literature yielded 13 reported cases of proximal femoral osseous avulsion of the ACL; however, all occurred in the skeletally immature (4-16). To our knowledge, there have been no previous reported cases of osseous femoral avulsion of the ACL origin in an adult.

In our case, the avulsed fracture fragment was apparent on the radiographic examination; a small ossific density bordered the medial cortex of the lateral femoral condyle at the expected attachment site of the ACL. Had notch views been obtained, the fragment would likely have been even more conspicuous (4, 6). CT, to greater advantage than MRI, demonstrated the bony avulsion and exhibited continuity of the fragment with the ACL. The MRI readily demonstrated the intact ACL with bone-marrow edema at the lateral femoral condylar donor site of avulsion. The avulsed ossific fragment, however, was challenging to identify on MRI.

Although exceedingly rare in the adult, osseous femoral avulsion injury of the ACL can occur. It is imperative that this tiny avulsed fracture fragment not be overlooked, particularly in the case of polytrauma with additional distract-

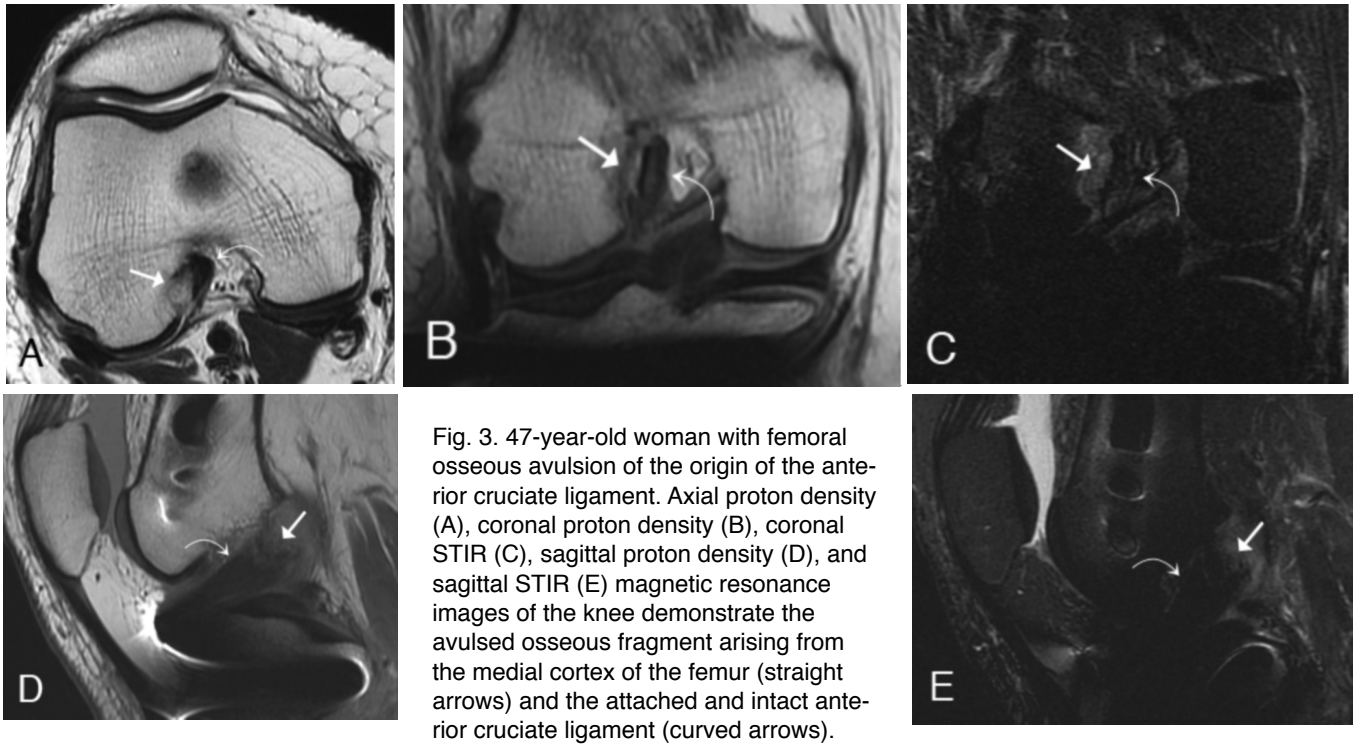

Fig. 3. 47-year-old woman with femoral osseous avulsion of the origin of the anterior cruciate ligament. Axial proton density (A), coronal proton density (B), coronal STIR (C), sagittal proton density (D), and sagittal STIR (E) magnetic resonance images of the knee demonstrate the avulsed osseous fragment arising from the medial cortex of the femur (straight arrows) and the attached and intact anterior cruciate ligament (curved arrows).

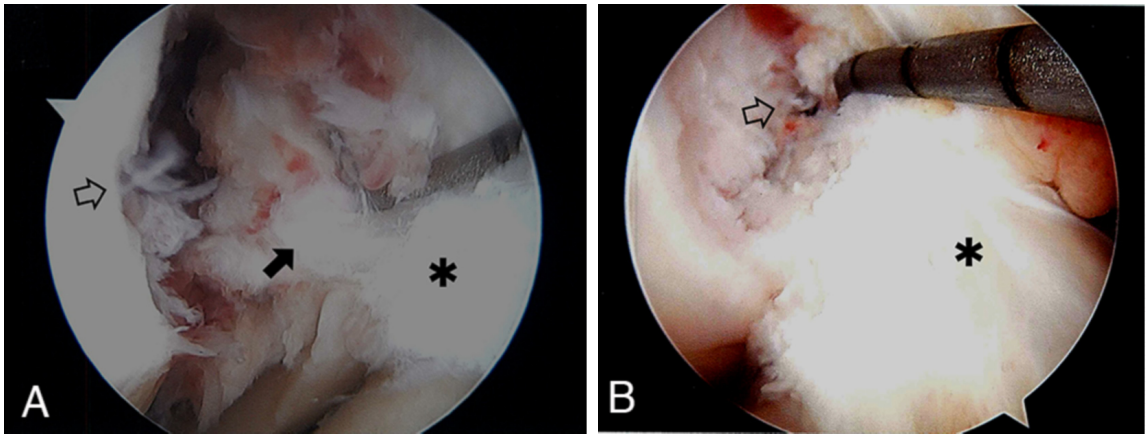

Figure 4. 47-year-old woman with femoral osseous avulsion of the origin of the anterior cruciate ligament. Intra-operative image (A) demonstrates a gap separating the irregular contour of the lateral femoral condyle (open arrow) and the detached anterior cruciate ligament (asterisk), which is attached to the avulsed osseous fragment (closed arrow) prior to repair. Intra-operative image (B) demonstrates a screw (open arrow) fixing the previously avulsed anterior cruciate ligament (asterisk) to the lateral femoral condyle.

ing fractures about the knee joint. While instability of the ACL may be suggested on the clinical examination, separating osseous avulsion from ligament disruption on physical examination alone is not possible. The management of these two injuries is markedly different. Our case demonstrates that this injury can be accurately suggested on radiography, and subsequently confirmed by way of CT or MRI.

References

1. Griffith JF, Antonio GE, Tong CW, Ming CK. Cruciate ligament avulsion fractures. *Arthroscopy*. 2004 Oct;20(8):803-12. [PubMed]
2. Song EK, Seon JK, Park SJ, Yoon TR. Clinical outcome of avulsion fracture of the anterior cruciate ligament between children and adults. *J Pediatr Orthop B*. 2009 Nov;18(6):335-8. [PubMed]

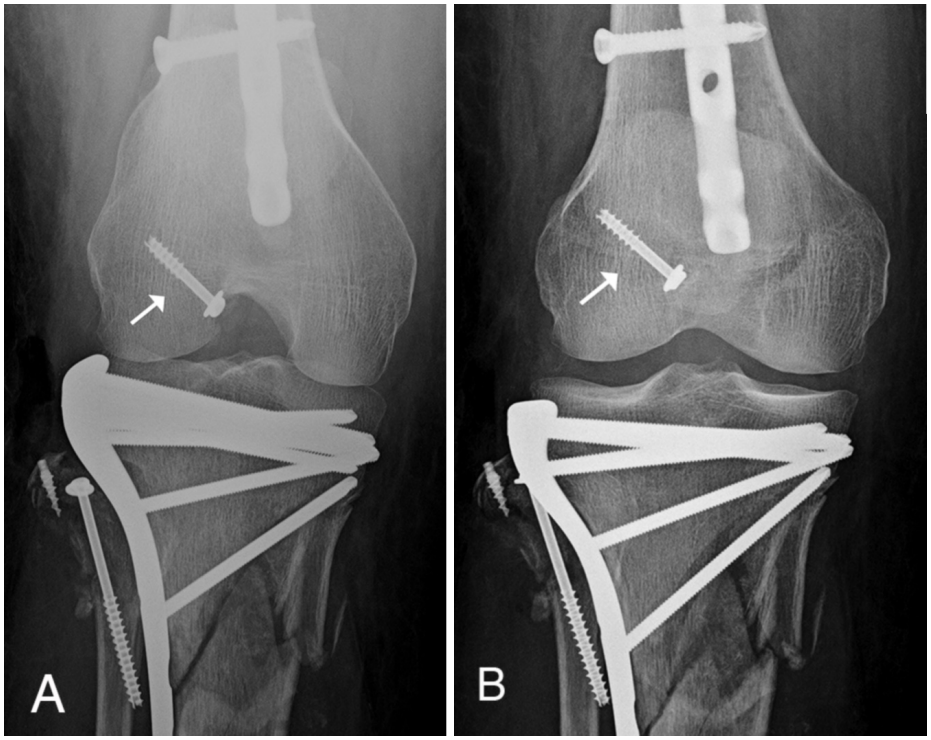

Figure 5. 47-year-old woman with femoral osseous avulsion of the origin of the anterior cruciate ligament. Posteroanterior (A) and anteroposterior (B) postoperative radiographs of the knee demonstrate extensive hardware for repair of fractures and soft-tissue injuries involving the femur, tibia, and fibula. A single partially threaded screw with washer (arrows) fixes the previously avulsed anterior cruciate ligament at its femoral origin.

3. Paschos NK, Gartzonikas D, Barkoula NM, et al. Cadaveric study of anterior cruciate ligament failure patterns under uniaxial tension along the ligament. *Arthroscopy*. 2010 Jul;26(7):957-67. [PubMed]
4. Robinson SC, Driscoll SE. Simultaneous osteochondral avulsion of the femoral and tibial insertions of the anterior cruciate ligament. Report of a case in a thirteen-year-old boy. *J Bone Joint Surg Am.* 1981 Oct;63(8):1342-3. [PubMed]
5. Eady JL, Cardenas CD, Sopa D. Avulsion of the femoral attachment of the anterior cruciate ligament in a seven-year-old child. A case report. *J Bone Joint Surg Am.* 1982 Dec;64(9):1376-8. [PubMed]
6. Wasilewski SA, Frankl U. Osteochondral avulsion fracture of femoral insertion of anterior cruciate ligament. Case report and review of literature. *Am J Sports Med.* 1992 Mar-Apr;20(2):224-6. [PubMed]
7. Uhorchak JM, White PM 3rd, Scully TJ. Type III-A tibial fracture associated with simultaneous anterior cruciate ligament avulsion from the femoral origin. *Am J Sports Med.* 1993 Sep-Oct;21(5):758-61. [PubMed]
8. Corso SJ, Whipple TL. Avulsion of the femoral attachment of the anterior cruciate ligament in a 3-year-old boy. *Arthroscopy*. 1996 Feb;12(1):95-8. [PubMed]
9. Tohyama H, Kutsumi K, Yasuda K. Avulsion fracture at the femoral attachment of the anterior cruciate ligament after intercondylar eminence fracture of the tibia. *Am J Sports Med.* 2002 Mar-Apr;30(2):279-82. [PubMed]
10. Kawate K, Fujisawa Y, Yajima H, Sugimoto K, Tomita Y, Takakura Y. Avulsion of the cartilaginous femoral origin of the anterior cruciate ligament in a three-year-old child. A case report with a thirteen-year follow-up. *J Bone Joint Surg Am*. 2004 Aug;86-A(8):1787-92. [PubMed]
11. Lakshmanan P, Sharma A, Dixit V, Lyons K, Fairclough JA. Avulsion of anterior cruciate ligament from femoral condyle: an unusual case report and a review of the literature. *Knee Surg Sports Traumatol Arthrosc.* 2006 Nov;14(11):1176-9. [PubMed]
12. Edwards MR, Terry J, Gibbs J, Bridle S. Proximal anterior cruciate ligament avulsion fracture in a skeletally immature athlete: a case report and method of physeal sparing repair. *Knee Surg Sports Traumatol Arthrosc.* 2007 Feb;15(2):150-2. [PubMed]
13. Bengtson H, Giangarra C. Osteochondral avulsion fracture of the anterior cruciate ligament femoral origin in a 10-year-old child: a case report. *J Athl Train*. 2011 Jul-Aug;46(4):451-5. [PubMed]
14. Pai SK, Aslam Pervez N, Radcliffe G. Osteochondral avulsion fracture of the femoral origin of the anterior cruciate ligament in an 11-year-old child. *Case Rep Med*. 2012;2012:506798. [PubMed]
15. Wardle NS, Haddad FS. Proximal anterior cruciate ligament avulsion treated with TightRope® fixation device. *Ann R Coll Surg Engl*. 2012 Mar;94(2):e96-8. [PubMed]
16. Langenhan R, Baumann M, Hohendorff B, Probst A, Trobisch P. Arthroscopically assisted reduction and internal fixation of a femoral anterior cruciate ligament osteochondral avulsion fracture in a 14-year-old girl via transphyseal inside-out technique. *Strategies Trauma Limb Reconstr*. 2013 Nov;8(3):193-7. [PubMed]