

CHARACTERISTICS OF FIRST DAY COMPLICATIONS AFTER ODONTECTOMY OF IMPACTED MANDIBULAR THIRD MOLAR IN GENERAL ANESTHESIA

Putri Nurfuadah^{1*}, Seto Adiantoro², Lucky Riawan³, Endang Sjamsudin⁴

^{1*}Resident of Oral and Maxillofacial Surgery Department, Faculty of Dentistry, Universitas Padjadjaran/ RSUP Dr. Hasan Sadikin Bandung, Indonesia

^{2,3,4} Staff of Oral and Maxillofacial Surgery Department, Faculty of Dentistry, Universitas Padjadjaran/ RSUP Dr. Hasan Sadikin Bandung, Indonesia

Article Info: Received 18 December 2021; Accepted 25 January 2022

DOI: <https://doi.org/10.32553/ijmbs.v6i1.2403>

Corresponding author: Putri Nurfuadah

Conflict of interest: No conflict of interest.

Abstract

Introduction: Odontectomy is the most common procedure performed by oral and maxillofacial surgeons. The consideration of odontectomy cases in general anesthesia with certain factors, such as patient anxiety, mental or physical disorders, degree of difficulty in impacted teeth, disoriented patients, number of teeth performed odontectomy, and duration of surgery. Some complications after odontectomy, including swelling, trismus, and paresthesia often occur from the first day after odontectomy. The purpose of this study was to determine the characteristics of the complications on the first day after odontectomy of impacted mandibular third molar in general anesthesia at Dr. Hasan Sadikin General Hospital during January – June 2020.

Methods: This study was a cross-sectional retrospective using medical record data of patients diagnosed with class I, II, and III mandibular molar impaction based on clinical and panoramic x-rays and performed odontectomy of mandibular third molar impaction in general anesthesia at Dr. Hasan Sadikin Hospital for the period January - June 2020.

Results: The obtained data were 186 cases from 98 patients. Data were obtained from secondary data through medical records of mandibular third molar impaction odontectomy patients in general anesthesia who were treated at the inpatient installation of RSUP Dr. Hasan Sadikin for the period during January to June 2020 to determine the characteristics of complications on the first day after odontectomy of impacted mandibular third molar in general anesthesia based on age, gender, and the classification of mandibular third molar impactions. The percentage of complications on the first day after odontectomy of impacted mandibular M3 in general anesthesia at Dr. Hasan Sadikin General Hospital for the period during January - June 2020 showed that the largest number was found in complications of swelling as many as 41 people (54%), followed by trismus as many as 33 people (43%) and paresthesia were 2 patient (3%).

Conclusion: The most common complications were swelling and trismus, where these complications were classified as mild and normal complications from odontectomy of impacted mandibular third molars. Meanwhile, the rarest complication was paresthesia.

Keywords: Complications, Post-odontectomy, Impaction of mandibular third molar

Introduction

Impacted teeth are teeth that have failed to fully erupt in their proper position. This can occur due to insufficient space in the jaw for the growth of the teeth and improper angulation of the tooth.^{1,2} The most frequent incidence of impactions is the third molars. This is because the third molar is the last tooth to grow, so it is often impacted because there is no or lack of adequate space.^{3,4}

Third molars or wisdom teeth develop in the late teens or early 20s. This age is considered the age of wisdom, so that the third molar or wisdom tooth in English is called a wisdom tooth. The prevalence of impacted teeth reached 88.8% in those aged 16-30 years.^{3,4} Odontectomy is the most common procedure performed by oral and maxillofacial surgeons. Some complications after

odontectomy, including swelling, trismus, and paresthesia often occur from the first day after odontectomy.^{5,6,7}

Complications can arise during and after surgery, due to iatrogenic factors. Odontectomy with a high degree of difficulty, such as in impacted teeth that is buried deep, must be considered by the operator since the beginning based on the X-ray or radiograph. During surgery, root fractures can occur, a loose second molar, trauma to the temporo-mandibular joint, pushing roots into the submandibular space, even fracture of the mandibular angle, although the latter is extremely rare.^{8,9,10}

Anesthesia that can be used in odontectomy, namely local anesthesia and general anesthesia. The anesthesia that are often used in odontectomy are local anesthesia, however,

in some cases, general anesthesia may be indicated. The selection of anesthesia is carried out with consideration of the patient's anxiety, anatomical approach, adequate pain control, comorbid systemic medical conditions and potential needs. Information regarding patient sex, patient age, number of teeth extracted, type of tooth extracted, classification of patient impactions, and comorbidity is a patient profile that can be used as a consideration for the choice of anesthesia type in odontectomy patients.^{11,12,13}

Another complication is inferior alveolar nerve injury, resulting in inferior labial paraesthesia to the chin on the same side. Paresthesia can be temporary or permanent, depending on the amount of force on the nerve. Injury can occur all at once, affecting the inferior alveolar artery and vein which runs parallel to the nerve, which can cause profuse bleeding.^{11,12,13}

Physiologically, in young patients, 24-48 hours after surgery, cheek oedema can occur and the appearance of discomfort sensation, that which is part of the healing process. Trismus or masseter muscular spasm can be prevented by motivating the patient to repeatedly open his mouth exercises from the first day after surgery. In patients over 50 years of age, oedema can last up to five days. Complications of ecchymosis in the submucosa or subcutaneous area can occur due to decreased tissue tone, fragile capillaries and weakened intercellular attachments. The situation is not dangerous, and usually lasts from the second to the seventh day after surgery.^{8,9,10,11}

Post-surgical infectious complications can also occur in the socket where the impacted tooth is throbbing pain spreading to the ear and halitosis, an unpleasant odor that comes from the socket. This condition is caused by localized osteomyelitis or alveolar osteitis, also known as dry socket, which causes a longer healing period.^{8,9,10}

Considering the number of incidents, problems and complaints caused by impacted mandibular third molars, it is felt necessary to examine The Characteristics of First Day Complications after Odontectomy of Impacted Mandibular Third Molar in General Anesthesia at Dr. Hasan Sadikin General Hospital in January-June 2020: A Cross-Sectional Retrospective Study

Method

This research is a descriptive study with a retrospective design using medical record data of patients diagnosed with class I, II, and III mandibular third molar impaction based on clinical and panoramic radiograph at Oral Surgery Department of Hasan Sadikin General Hospital who underwent odontectomy of mandibular third molar impaction in general anesthesia at Dr. Hasan Sadikin General Hospital for the period January - June 2020. Ethical approval was obtained from the Research Ethics Committee of the Universitas Padjadjaran, with number 627/UN6.KEP/EC/2020.

The studied variables included age, gender, classification of impacted mandibular third molar, complications of the first day after odontectomy in general anesthesia (swelling, trismus, and paresthesia).

Result

This study was conducted at the dr. Hasan Sadikin General Hospital from January to June 2020. The obtained data were 186 cases from 98 patients. Data were obtained from secondary data through medical records of mandibular third molar impacted odontectomy patients in general anesthesia who were treated at the inpatient installation of Dr. Hasan Sadikin General Hospital during the period of January to June 2020 to determine the characteristics of complications on the first day after odontectomy of impacted mandibular third molar in general anesthesia based on age, gender, and the classification of mandibular third impactions. The research results are presented in tables and diagrams.

From the results of the study through medical records based on age, it was found that patients with ages were categorized into several groups of 0-17 years, 18-65 years, and > 65 years. The number of respondents in the 0 – 17 year old ages group is 4 people or 4%, the 18-65 year old ages group is 94 people or 96%, and the ages group of > 65 years is 0 people or 0%.

Table 1: Characteristics by Age

Characteristic	Frequency (n=...)	Proportion (%)
Age		
0 – 17 year old	4	4%
18 – 65 year old	94	96%
>65 year old	0	0%

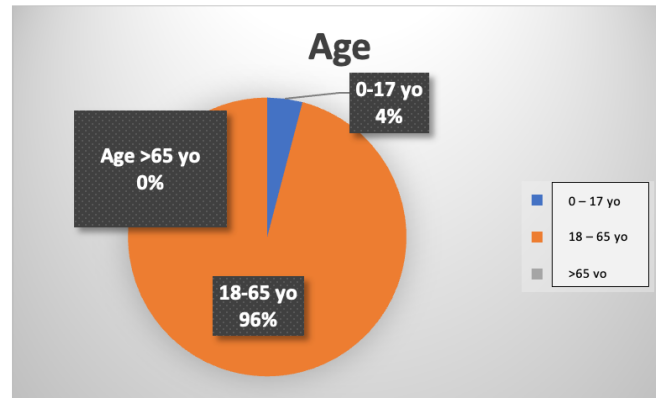


Diagram 1: Patient Characteristics Diagram by Age

From the results of the study through medical records based on gender criteria, it was found that 35 patients were male or 36% and 63 women or 64% female.

Table 2: Characteristics Based on Gender

Characteristic	Frequency (n=...)	Proportion (%)
Gender		
Male	35	36%
Female	63	64%

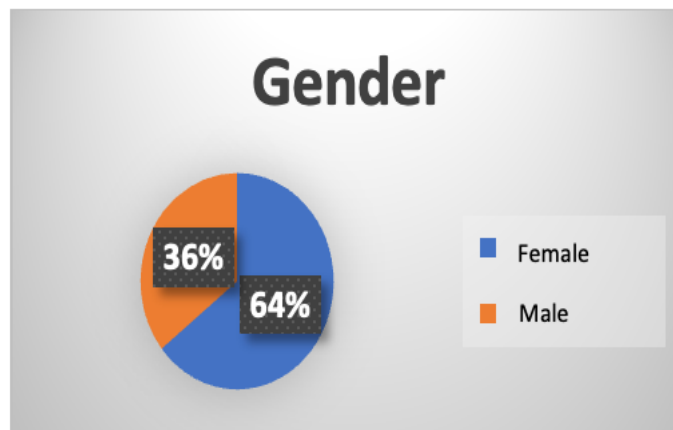


Diagram 2: Patient Characteristics Diagram by Gender

From the results of the study, through medical records based on the classification, it was found that class I mandibular third molar impaction was 56 cases or 28%, class II mandibular third molar impaction was 110 cases or 60%, and class III mandibular third molar impaction was 20 cases or 12%.

Table 3: Characteristics Based on Classification

Characteristic	Frequency (n=...)	Proportion (%)
Classifications		
Class I impacted mandibular third molar	56	28%
Class II impacted mandibular third molar	110	60%
Class III impacted mandibular third molar	20	12%

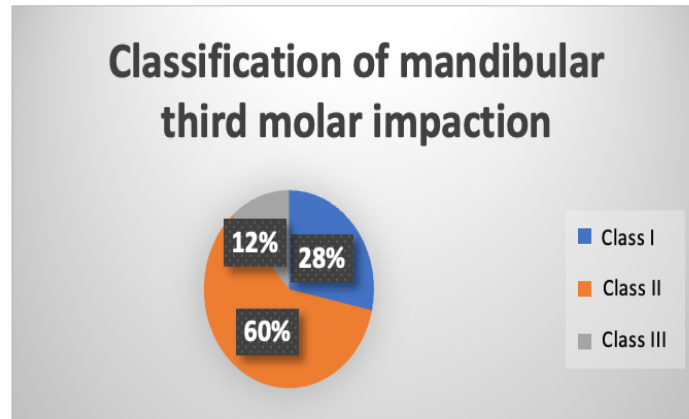


Diagram 3: Patient Characteristics Diagram by Classification

From the results of the study through medical records based on complications on the first day, there were 41 people or 54% who experienced complications of swelling, trismus complications as many as 33 people or 43%, and complications of paresthesias as many as 2 people or 3%.

Table 4: Characteristics Based on Complication

Characteristic	Frequency (n=...)	Proportion (%)
Complications		
Swelling	41	54%
Trismus	33	43%
Paresthesia	2	3%

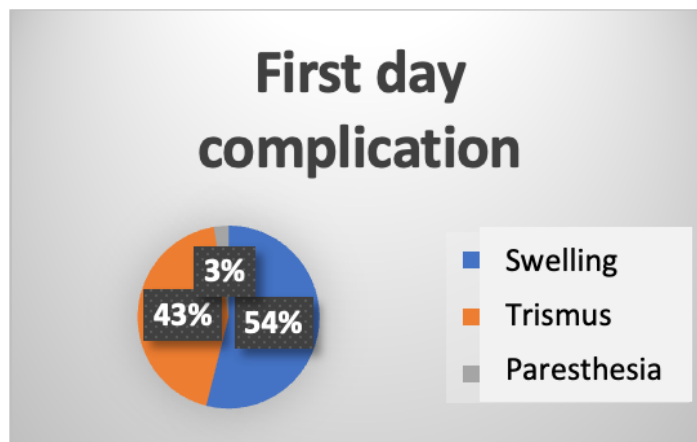


Diagram 4: Patient Characteristics Diagram by Complications

Discussion

This characteristics of the complications of the first day after odontectomy of impacted mandibular third in general anesthesia at the Inpatient Installation of Dr. Hasan Sadikin Hospital for the period January - June 2020 study use a descriptive study with a retrospective design using medical record data of patients diagnosed with class I, II, and III mandibular third molar impaction based on clinical and panoramic radiograph at Oral Surgery Department of

Hasan Sadikin General Hospital who underwent odontectomy of mandibular third molar impaction in general anesthesia at Dr. Hasan Sadikin General Hospital for the period January - June 2020. This study aims to see the characteristics of complications on the first day after odontectomy of impacted mandibular third molar in general anesthesia based on age, gender, and classification of mandibular third molar impaction.

The percentage of patients based on age shows that the largest number is found in the age category at 18-65 year old at 94 patients (96%), then the 0-17 year age category at 4 patients (4%), and the age category > 65 years at 0%.

The percentage of patients based on gender shows that the largest number is found in the female gender, as many as 63 patients (64%), while the male gender is 35 patients (36%).

The percentage of patient cases based on the classification shows that the greatest number is found in class 2 third molar impaction as many as 110 cases (60%), then class 1 third molar impaction as many as 56 cases (28%), and class 3 mandibular third molar impaction as many as 20 cases (12%).

The percentage of patients based on complications on the first day after odontectomy of impacted mandibular third molar in general anesthesia showed that the greatest number was found in complications of swelling as many as 41 patients (54%), followed by trismus as many as 33 patients (43%) and complications of paralysis as many as 2 patients (3%).

Based on the study of patients with complications, there were 76 out of a total of 98 patients. Of the 76 patients, the most common complications were swelling 54%, and trismus 43%, where these complications were classified as mild and normal complications from odontectomy of impacted mandibular third molars. Meanwhile, the rarest complication was paresthesia at 3%.

The complications that occur depend on individual reactions. In general, the deeper the impacted tooth is and the more bone covering it and the greater the deviation of the impacted tooth angulation from alignment with the second molar axis, the more difficult it is to extract. The most common post odontectomy complication is oedema accompanied by pain. Other complications include trismus and paresthesia.^{1,2,3,4,5}

Oedema as a result of local trauma such as odontectomy occurs as a sign of an inflammatory process accompanied by redness and pain. In this study, there were 41 patients suffering from oedema or swelling as many as 54% on the first day post odontectomy. Oedema usually peaks at the end of the second post operative day and usually disappears by the fifth to seventh days. Oedema is a normal tissue reaction from injury to any odontectomy.^{5,6,7,8,9}

In this study, 33 patients experienced trismus or as much as 43% of the patients. The trismus was evaluated by the distance between the upper and lower right middle incisors at maximum mouth opening. Trismus can be caused by oedema around the surgical site of the third molar which will cause changes in the surrounding tissue and the masticatory muscles contract, causing trismus. But there are also those who say that trismus occurs not due to

increased volume of the musculus due to oedema and infiltration, but rather due to a reaction to pain caused by jaw movement.^{9,10,11}

Swelling, pain, and trismus are considered temporary complications and are expected to occur after surgery. Although temporary, this condition can be a source of anxiety for the patient. In this study there were 2 patients who experienced paresthesia or 3% at total. Paresthesia occurs because of the nerve damage. The most frequently injured nerves during tooth extraction and surgery are the inferior alveolar nerve and the lingual nerve. According to previous studies, neurosensory deficits after odontectomy were lower at a prevalence of 0.1% to 22% for lingual nerve deficits and 0.26% to 8.4% for inferior alveolar nerve deficits. Within 4-8 weeks after surgery, 96% of inferior alveolar nerve injuries recovered, and recovery rates were not affected by gender and slightly by age.^{11,12,13}

Conclusions

The most common complications were swelling and trismus, where these complications were classified as mild and normal complications from odontectomy of impacted mandibular third molars. Meanwhile, the rarest complication was paresthesia.

References

1. Lim HW, Mahmud NI, Zaki FH, Tan FY, Balasundram S, Adnan TH. Wisdom Tooth Surgery Complications—Local Anaesthesia versus General Anaesthesia. *Open Journal of Stomatology*. 2019 Mar 14;9(03):51.
2. Balamurugan R. Influence of Tooth Sectioning on Postoperative Pain, Swelling and Trismus Following Surgical Removal of Impacted Mandibular Third Molar. *Journal of Dental Research and Practice*. 2019 Aug 22;1(1):11-7.
3. Chen YW, Chi LY, Lee OK. Revisit incidence of complications after impacted mandibular third molar extraction: A nationwide population-based cohort study. *PloS one*. 2021 Feb 22;16(2):e0246625.
4. Mudjono H, Rahajoe PS. The effect of triangular and reversed triangular flap designs to post third molar odontectomy complications (a pilot study). *Journal of clinical and experimental dentistry*. 2020 Apr;12(4):e327.
5. Ahmed M, Salah MK, Khairy N. Computer-aided design/computer-aided manufacturing cutting guides for odontectomy of deeply impacted mandibular third molars. *Open access Macedonian journal of medical sciences*. 2018 Dec 20;6(12):2395.
6. DS L, Latief BS. Evaluation of Impacted Mandibular Third Molar Position in Relation to Mandibular Canal on Panoramic Radiography compared to Cone-Beam Computed Tomography. *Journal of International Dental & Medical Research*. 2019 May 1;12(2).

7. Leung YY. Guided bone regeneration to reduce root migration after coronectomy of lower third molar: a randomized clinical trial. *Clinical oral investigations*. 2019 Apr;23(4):1595-604.
8. Singh K, Kumar S, Singh S, Mishra V, Sharma PK, Singh D. Impacted mandibular third molar: Comparison of coronectomy with odontectomy. *Indian Journal of Dental Research*. 2018 Sep 1;29(5):605.
9. Kang F, Sah MK, Fei G. Determining the risk relationship associated with inferior alveolar nerve injury following removal of mandibular third molar teeth: A systematic review. *Journal of stomatology, oral and maxillofacial surgery*. 2020 Feb 1;121(1):63-9.
10. La Monaca G, Voza I, Giardino R, Annibali S, Pranno N, Cristalli MP. Prevention of neurological injuries during mandibular third molar surgery: technical notes. *Annali di stomatologia*. 2017 Apr;8(2):45.
11. Baqain ZH, AlHadidi A, AbuKarkay A, Khader Y. Does the use of cone-beam computed tomography before mandibular third molar surgery Impact treatment Planning?. *Journal of Oral and Maxillofacial Surgery*. 2020 Jul 1;78(7):1071-7.
12. Roi CI, Ianes E, Gaje PN, Nica DF, Roi A, Roi A. The Predictability of Difficultness of Lower Third Molar Odontectomy. *REVISTA DE CHIMIE*. 2019 Apr 1;70(4):1342-5.
13. Tsamis C, Rodiou S, Stratos A, Gkantidis N. Removal of a severely impacted mandibular third molar minimizing the risks of compromised periodontium, nerve injury, and mandibular fracture. *Quintessence international*. 2018 Jan 1;49(1).