



Comments? Questions?

Email: compendium@medimedia.com

Web: VetLearn.com • Fax: 800-556-3288

CE

Article #1 (1.5 contact hours)

Refereed Peer Review

KEY FACTS

- Rabbits are increasing in popularity as house pets, and skin disease may be the most common reason that owners seek veterinary care.
- Infestation with the mite *Psoroptes cuniculi* could be the most common skin disease in rabbits; it is the most frequent cause of otitis in this species.
- Rabbit skin diseases with zoonotic potential include infestation with *Cheyletiella* spp and dermatophytes.
- Venereal spirochetosis (rabbit syphilis), caused by the bacterium *Treponema cuniculi*, is not a zoonosis.

Dermatologic Problems of Rabbits*

University of California, Davis

Stephen D. White, DVM, DACVD

Ecole Nationale Vétérinaire de Nantes, France

Patrick J. Bourdeau, DV, DECVD

University of Edinburgh

Anna Meredith, MA, VetMB, CertLAS, CertZooMed, MRCVS

ABSTRACT: Most skin conditions in rabbits result from a wide variety of pathogens, including parasites (the most frequent cause), fungi, bacteria, and viruses. In addition, reports of noninfectious diseases of domestic rabbits are increasing. This article discusses rabbit skin disease based on the predominance of one of four clinical signs: pruritus, scaling or crusting, alopecia with minimal pruritus, and nodules. Miscellaneous conditions are also discussed. Although a number of these diseases may be presented with variable or multiple clinical signs, it is often helpful to approach skin disease in rabbits from the perspective of the most likely differential diagnosis.

Rabbits (*Oryctolagus cuniculus*) are becoming increasingly popular as house pets. Skin diseases may be the most common reason owners bring their pet rabbits to the veterinarian. Skin diseases are also very common in laboratory rabbit colonies and may interfere with the quality and conditions of research. Most of these skin conditions result from such pathogens as parasites (the most frequent cause), fungi, bacteria, and viruses. Reports of noninfectious diseases of domestic rabbits are increasing as well, perhaps because owners desire better and more complete care of their rabbits.

This article discusses a wide range of rabbit skin diseases based on the predominance of one of four clinical signs: pruritus, scaling or crusting, alopecia with minimal pruritus, and nodules. Miscellaneous conditions that do not fit well into this scheme are presented at the end of this article. Although rabbits affected by many of these diseases are presented with variable or multiple clinical signs, it is often helpful to approach dermatologic disease in rabbits from the perspective of the most likely differential diagnosis.

PRURITUS

Pruritus is arguably the most common clinical sign resulting in presentation of rabbits to veterinarians. Clinicians must keep in mind that pruritus may result in other clinical signs such as alopecia and crusts.

*Adapted from White SD, Bourdeau PJ, Meredith A: Dermatological problems of rabbits, *Semin Avian Exotic Pet Med* 11:141–149, 2002, by permission of the publisher.

Ectoparasites

Fleas

Domestic rabbits are often exposed to *Ctenocephalides* spp if they share a household with a dog or cat.¹⁻³ Various flea species may be found on pet rabbits housed outside or exposed to wild rabbits. These include the rabbit flea (*Spilopsyllus cuniculi*), the common Eastern rabbit flea (*Cediopsylla simplex*), the giant Eastern rabbit flea (*Odontopsyllus multispinosus*), and the sticktight flea (*Echidnophaga gallinacea*).^{4,5}

Infestations of *S. cuniculi* are common in rabbit colonies. The life cycle of this flea is controlled by the hormonal cycle of the host, which explains the sudden proliferation seen on pregnant does and young rabbits. *S. cuniculi* is also important as a vector for myxomatosis.^{4,5} *S. cuniculi* most often bites on the rabbit's pinnae and face and may also bite cats and dogs.⁶ Pruritus is variable in flea infestations in rabbits but may be severe.^{2,7}

To our knowledge no flea control products are licensed specifically for rabbits. Traditional ectoparasitocides (carbamates, pyrethrins) have been replaced by newer and more effective products, such as imidacloprid and selamectin. Imidacloprid (Advantage, Bayer Animal Health), a topical adulticide, has been shown to be safe and effective in flea control in rabbits.^{2,3} Long-term use of the insect growth regulator lufenuron (Program, Novartis Animal Health) is also reportedly safe in rabbits.² Adverse reactions to fipronil (Frontline, Merial) have been reported in rabbits, and we do not recommend its use in this species.^{2,3,8,9}

Lice

Infestations by *Haemodipsus ventricosus*, a sucking louse, are rare in pet rabbits, although they are common in wild lagomorphs in Europe. This louse can cause pruritus, erythema, papules, alopecia, and anemia. It may also act as a vector of tularemia (*Francisella tularensis*). Diagnosis is made by visualization of the lice and eggs (nits). Formerly, treatment consisted of various topical treatments using parasiticides approved for use in cats, notably pyrethrins or carbaryl. At present, systemic ivermectin (0.4 mg/kg PO or SC) is used and is often effective.⁵ A study in dogs suggests that imidacloprid may also be effective.¹⁰

Mange Mites

Infestation with the nonburrowing mite *Psoroptes cuniculi* is the most frequent cause of otitis in rabbits and arguably the most frequent dermatologic disease seen in this species. The typical presentation is bilateral, intensely pruritic otitis with thick crusts. These crusts typically are first found in the proximal external ear canal and extend up the inner pinna. In chronic cases,

complications of neurologic signs or otitis media may be seen because the eardrum can become perforated.⁵ This perforation may lead to a purulent otitis medium, due to secondary bacterial infection, and meningitis. Skin involvement may be seen, particularly of the face, neck (dewlap folds), and genitalia, and is intensely pruritic^{2,11} (Figure 1). Areas of alopecia and crusts are often seen. Microscopic examination of the ear crusts or skin scrapings shows numerous mites; in some cases adult mites may be visible on otoscopic examination.

The life cycle of *P. cuniculi* is completed in less than 3 weeks. Adult mites may live off the host for 4 to 21 days, depending on ambient temperature and humidity.² Although infestation with this mite is very contagious among rabbits, one of the authors (S. D. W.) has seen a rabbit that had no contact with other rabbits for more than a year develop signs of infestation; similar long-standing subclinical cases have been reported.²

The recommended treatment of *P. cuniculi* infestation is systemic administration of either ivermectin (0.2 to 0.4 mg/kg SC once every 2 weeks for two to three treatments)^{2,5} or moxidectin (0.2 mg/kg SC once every 10 days for two treatments).¹² Various topical treatments have been used, but these frequently bother the rabbit much more than the subcutaneous injections.

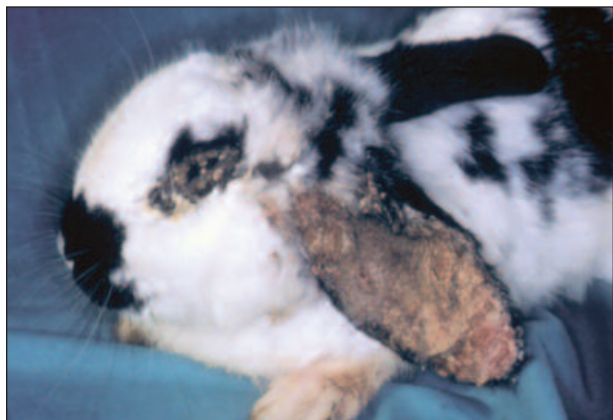

Figure 1—Rabbit with *P. cuniculi* infestation; note extensive crusting of the pinna and periocular area.

Although it has been suggested that using mineral oil in the ear will resolve the infestation, one of the authors (S. D. W.) has seen these mites survive for 1 week in mineral oil under a coverslip on a microscope slide. Although removing ear crusts may lessen the mite burden, it is not necessary and may be painful to the rabbit. If the crusts are removed, they should be softened with mineral oil first; otherwise the lining of the ear canal can be damaged. With the advent of systemic treatment, such manipulation is seldom necessary. All mammals that have come into contact with the infected animal should be treated.

Notoedres cati var *cuniculi*, a rarely observed parasite of rabbits, is responsible for a pruritic facial dermatosis that may extend to other skin areas. Sarcoptic acariasis (*Sarcoptes scabiei* var *cuniculi*) is also rarely reported. This is an extensive, highly pruritic, hyperkeratotic dermatosis. Treatment for these mites is the same ivermectin dosage schedule as for *P. cuniculi* (0.2 to 0.4 mg/kg SC once every 2 weeks for two to three treatments).

A newly described subspecies of the mite *Psorobia lagomorphae* was recently reported to have caused mild pruritus and diffuse alopecia in a 6-month-old dwarf rabbit.¹³ Multiple skin scrapings yielded only five mites. The infestation responded, albeit slowly, to one SC injection of ivermectin (0.2 mg/kg).¹³

Gamasids and Ticks

Ornithonyssus bacoti infestation is very common in laboratory rabbit colonies and may occasionally be observed in pet rabbits. It often is associated with a highly pruritic condition with generalized diffuse hair loss, crusts, and frequent secondary infections. Severe, sometimes fatal anemia is observed in young animals. Immunity probably develops in chronically exposed animals. Control of this intermittent parasite is difficult

in colonies and frequently requires treatment of both the animals and the environment. A recent report on mice and rats has suggested that topical pyriproxifen, a juvenile hormone analog, may be helpful in treating this parasite.¹⁴

Many species of ticks feed on rabbits. The most common in North America is the continental rabbit tick, *Haemaphysalis leporis-palustris*. This is a three-host tick; the rabbit can serve as the host for each stage of the life cycle, although the tick must leave the rabbit after feeding to develop and molt between each stage.² Ticks may cause anemia and can serve as vectors for myxomatosis and papillomavirus as well as for zoonoses such as tularemia.² Ticks should be physically removed from rabbits. Because of the potential presence of zoonotic diseases, the veterinarian should wear gloves and remove the ticks with forceps. Ivermectin (0.4 mg/kg SC) has been recommended for killing ticks feeding on rabbits,² although the drug's efficacy may depend on the tick species and feeding pattern and on the dose received.¹⁵ Amitraz can be used in the topical treatment of tick and mite infestation.⁵ As stated previously, fipronil is not recommended for use in rabbits.

Pinworms

Passalurus ambiguus infestation is extremely common in laboratory rabbits. Clinical signs are rare, but these host-specific parasites may cause pruritus of the anal area, leading to self-trauma or rectal prolapse. Complete control of the parasite is difficult because reinfestations occur. The recommended treatment is piperazine citrate in the drinking water (3 g/L) in alternating 2-week periods.¹⁶ Alternatively, ivermectin has been shown to be effective in the treatment of most pinworm species, including those in rodents, although this efficacy has not been reported specifically for rabbits. The reported dosage regimen in rats for treatment of the pinworm *Syphacia muris* is 0.2 mg/kg/day PO for 5 consecutive days¹⁷; the dosage in mice for *Syphacia obvelata* is 1 mg/kg/day PO given twice, 11 days apart.¹⁸

SCALES AND CRUSTS

Fur Mites

Cheyletiella parasitovorax, the rabbit fur mite, is a non-burrowing mite that is just visible to the naked eye. Some rabbits carry the mites with no overt signs. Lesions are generally not severe, with crusting and scaling along the dorsum, mild to variable pruritus, and partial alopecia in heavy infestations (Figure 2). Cheyletiellosis is a zoonosis causing a papular dermatitis in humans. The life cycle is 14 to 21 days. Although adult female mites have been reported to survive for at least 10 days off the host, this has not been substantiated in *Cheyletiella* infestation in

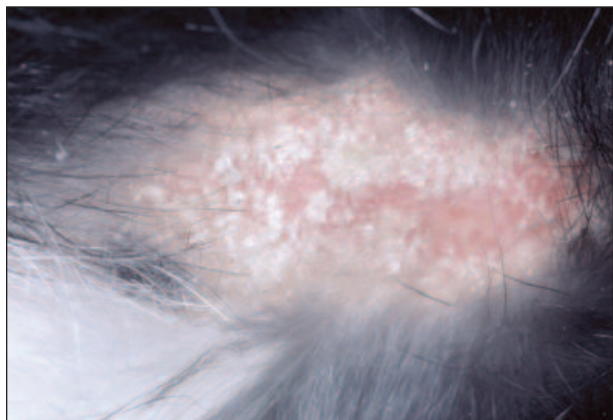


Figure 2—Rabbit with *Cheyletiella* spp infestation; note extensive scaling on the dorsal fur-clipped skin.

dogs.¹⁹ The mites are usually easy to find on microscopic examination of skin scrapings or cellophane tape samples. The treatment of choice is ivermectin (0.2 to 0.4 mg/kg SC once every 2 weeks for two to three treatments). Some clinicians prefer lime sulfur dips.² All mammals that have come in contact with the infected animal should be treated. Although the effectiveness of cleaning the environment is controversial, it probably should be attempted in multirabbit households or colonies.

Listrophorus (Leponacarus) gibbus is a nonburrowing fur mite that is usually nonpathogenic even in heavy infestations. It is not zoonotic. Rarely, *L. gibbus* is associated with lesions on the shoulders, dorsum, or ventral areas.^{5,7}

Bacteria

Venereal spirochetosis, or rabbit syphilis, is caused by *Treponema cuniculi* and is acquired both by venereal and direct contact. This spirochete causes erythema, edema, vesicles, ulcers, crusts, and proliferative lesions around the perineum as well as around the face from autoinoculation (Figure 3). The condition, although not pruritic, is painful. Complications may include metritis, abortion, and neonatal death. Affected does can infect kits as they pass through the birth canal. Rabbits may spontaneously recover but remain asymptomatic carriers, with overt disease precipitated by stress. Clinical signs are very characteristic, but definitive diagnosis involves microscopic visualization of the organism from scrapes on a dark field background, with special silver stains on biopsy, or via serologic tests developed for the detection of human syphilis. Treatment requires penicillin G (42,000 to 84,000 IU/kg SC once weekly for three treatments). Lesions resolve in 1 to 3 weeks.² Treated rabbits should be monitored closely for signs of antibiotic-associated enterotoxemia. All exposed rabbits should be treated. Rabbit syphilis is not zoonotic.

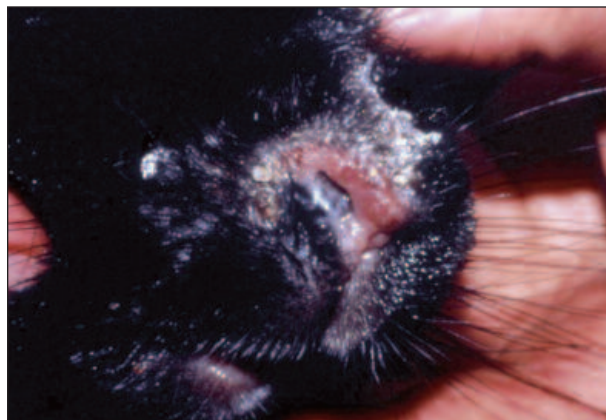


Figure 3—Rabbit with venereal spirochetosis (*T. cuniculi*) infection; note the edema, ulcers, crusts, and proliferative lesions on the muzzle.

Sebaceous Adenitis

One study reported four domestic rabbits with this uncommon disease.²⁰ The rabbits were presented with a history of nonpruritic scaling (Figure 4). Multiple skin biopsies revealed findings compatible with sebaceous adenitis as reported in other species: inflammation directed at the sebaceous gland or an absence of sebaceous glands, a perifollicular lymphocytic infiltrate at the level of the absent sebaceous glands, hyperkeratosis, follicular keratosis, follicular dystrophy, perifollicular fibrosis, and a mural infiltrative lymphocytic folliculitis. Histologic changes not consistent with sebaceous adenitis in other species were interface dermatitis and interface folliculitis with single-cell necrosis and basal cell hydropic degeneration. Successful treatment was not identified but could conceivably include vitamin A or retinoids as reported in dogs.²¹

ALOPECIA Dermatophytes

Several species of dermatophytes affect rabbits. Pet rabbits are most frequently infected with *Microsporum canis* or *Microsporum gypseum*, whereas rabbits kept in outside hutches, rabbits in laboratory colonies, and rabbits from pet shops typically are infected with *Trichophyton mentagrophytes*.

Clinical presentation is variable: diffuse alopecia frequently limited to the nose, ears, face, or extremities; erythema; classic ringworm with broken hairs; folliculitis; or, rarely, favus (yellow, honeycombed crusts). Asymptomatic carriage is common with a risk of transmission to other animals or humans. In one study, four of 104 healthy rabbits had *T. mentagrophytes* cultured from their haircoats.²² Wood's light examination is positive only with infections caused by *M. canis* and

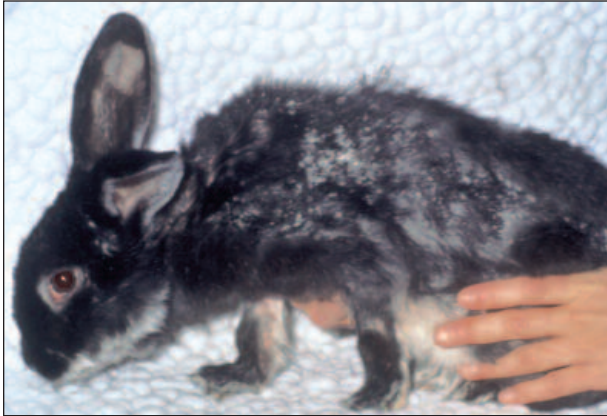

Figure 4—Rabbit with sebaceous adenitis; note the generalized scaling and alopecia. (From White SD, Linder K, Shultheiss P, et al: Sebaceous adenitis in four domestic rabbits [*Oryctolagus cuniculus*]. *Vet Dermatol* 11:53–61, 2000; with permission of Blackwell Publishing)

T. mentagrophytes var *quinckeanum*. Microscopic examination of hair shafts may show infected hairs with a “rotting log” appearance. Definitive diagnosis is via fungal culture and is recommended because speciation may determine the origin of contamination. Recently, an indirect ELISA was developed and its diagnostic potential evaluated for rabbits infected by *T. mentagrophytes*; this test may prove useful in earlier detection of the disease.²³

Treatment, which should include all in-contact mammals, includes topical enilconazole (0.2% solution twice weekly for 3 weeks; not available in the United States) or lime sulfur. Systemic griseofulvin (15 to 25 mg/kg PO for 4 weeks) is also very effective.² Anecdotal reports of lufenuron’s safety at standard doses in rabbits,² in addition to recent reports of its efficacy in dermatophyte infections in dogs and cats with dermatophytosis,²⁴ suggest the investigation of its use in rabbits. Eradication of dermatophytes is very difficult in rabbit colonies.

Follicular Mites

Demodicosis (*Demodex cuniculi*) is a rare condition in rabbits. The most frequent presentation is a nonpruritic hair loss that involves the head. One report associated *D. cuniculi* with both seborrhea sicca and alopecia in two of nine infested dwarf rabbits.²⁵ Treatment with a 0.05% amitraz solution resolved the mite infestation in the one rabbit, but the skin lesions remained static.

Endocrine Conditions

Fur plucking for nest building by the preparturient doe is common, with hair usually plucked from the dewlap, ventrum, or sides. This behavior occurs several days before kindling. No treatment is necessary.⁴

NODULES OF INFECTIOUS ETIOLOGY

Parasites

Coenurus serialis, a frequent parasite of rabbits in rural areas, is the vesicular form of *Taenia serialis* (the dog is the definitive host). Infestation is commonly responsible for the development of multiple, often fluctuant, nodules of 0.5 to 5 cm in diameter in connective tissues (abdominal, subcutaneous, retroorbital). There is no effective medical treatment, although solitary lesions may be carefully removed.^{5,26}

Various *Cuterebra* species may be agents of myiasis in rabbits in the Western hemisphere. The adult fly itself, which has no mouthparts, is harmless. Lesions are fistulated nodules, usually on the head and neck. They may be painful on palpation. Heavy infestations can lead to debilitation and death. Treatment is by careful removal of the larva and treatment of secondary bacterial infection, if present.

Fly-strike by other fly species is common in rabbits during summer months. Strike is usually primary (i.e., occurs on intact skin), and flies are especially attracted by cecotroph accumulation around the perineum and especially in the folds on either side of the genitals. This invariably is due to lack of coprophagy, which can result from a number of factors, including dental disease, obesity, back problems, and old age. Urine scalding caused by urinary incontinence also attracts flies. Initial treatment involves clipping the fur and cleaning the area, then manually removing the maggots and flushing the area with dilute antiseptic or antiparasitic solutions; a 1% silver sulfadiazine cream (Silvadene Cream 1%, Hoechst Roussel) has been recommended.² Supportive therapy should be given for shock, and ivermectin (0.4 mg/kg SC) will kill any larvae that emerge from unrecovered eggs. The underlying cause of the cecotroph or urine accumulation must then be addressed.

Bacteria

Rabbit abscesses have a thick capsule and are filled with thick, tenacious pus that is difficult to remove. *Pasteurella multocida* and *Staphylococcus aureus* are usually isolated from rabbit abscesses, with *Proteus* spp, *Pseudomonas* spp, *Bacteroides* spp, and other bacteria occasionally found. Entry is via a skin wound or, more rarely, secondary to bacteremia. Facial abscesses invariably are secondary to dental or nasolacrimal duct disease, and radiography of the skull is vital for any facial abscess to obtain a prognosis. True subcutaneous abscesses are best treated by complete surgical excision. If this is not possible, lancing and aggressive flushing with antiseptic solutions, plus appropriate antibiotic therapy, can be employed. Injection of gentamicin into the abscess capsule has been reported anecdotally by



Figure 5—Rabbit with myxomatosis; note the nodules (myxomas) on the face and ears.

some clinicians to be effective. Underlying bony involvement carries an extremely poor prognosis. Surgical debridement, removing affected teeth, and packing the abscess cavity with antibiotic-impregnated polymethylmethacrylate beads can be successful in many cases.^{2,27} These beads need not be removed. We do not recommend the use of calcium hydroxide because it may cause severe tissue necrosis.

Ulcerative or plantar pododermatitis (“sore hocks”) is a chronic, ulcerative, granulomatous dermatitis of the metatarsal area. This condition is seen mainly in overweight, inactive rabbits that are kept on wet bedding or grid floors, in rough cages, or in unsanitary conditions. Hereditary factors may also be involved. Rex rabbits particularly are affected because they lack protective guard hairs. The secondary infectious agent most commonly present is *S. aureus*. Lesions are bilateral, found in the plantar aspect of the metatarsal area, with progression typified by erythema, hyperkeratosis, crusts, pus, necrosis, osteomyelitis, and septicemia. Treatment is difficult and is based on correction of predisposing conditions, surgical drainage, topical

antimicrobials, surgical dressings, and systemic antibiotics (based on bacterial culture and sensitivity). Enrofloxacin (5 to 15 mg/kg SC q24h) may prove helpful in early cases. Methylmethacrylate beads have been reported to be helpful.² The earlier this disease is addressed, the better the chances of successful treatment are.

Necrobacillosis (Schmorl’s disease) is caused by *Fusobacterium necrophorum*. This disease usually results from poor husbandry and is relatively uncommon among pet rabbits.⁴ Abscesses, ulcerations, and necrosis develop on the face and neck. Definitive diagnosis is made by culture. Treatment requires debridement, topical antimicrobials, and systemic antibiotics. One recommended treatment regimen is penicillin, 40,000 IU/kg/day SC for 10 to 30 days.² Treated rabbits should be monitored closely for signs of antibiotic-associated enterotoxemia.

Brucellosis is a chronic rabbit disease with internal involvement and subcutaneous abscesses. Diagnosis is made by serology and culture. Treatment is controversial.

Acute cellulitis with head, neck, or thoracic swellings is generally due to *P. multocida* or *S. aureus*. The rabbit is usually febrile (104°F to 108°F; 40°C to 42°C), and the swellings are usually painful and erythematous. Treatment involves the use of antibiotics based on bacterial culture and sensitivity and cool water soaks to lower the body temperature. Surviving rabbits may have their swellings progress to abscesses or necrotic eschars.²

Viruses

Myxomatosis is an important and common cause of nodules in rabbits in many countries. The myxoma virus is a poxvirus transmitted by arthropods (mainly mosquitoes and the rabbit flea *S. cuniculi*, although a role for fur mites in transmission has also been suggested) via direct and indirect contact.² Myxomatosis is relatively infrequent in dwarf rabbits, probably because of epidemiologic conditions. Virulence is variable, particularly among wild rabbits of the genus *Sylvilagus*, but morbidity and mortality are generally high in pet rabbits, sometimes approaching 100%.² The rabbits develop a systemic illness after an incubation period of 8 to 21 days. Clinical signs are edema of the head, ears, eyelids, and genitalia; a milky oculonasal discharge; and, later, development of myxomas—firm, nonpruritic, erythematous nodules (0.5 to 2.0 cm in diameter) (Figure 5). Affected rabbits are usually lethargic and febrile. Sometimes the infection is limited to a spontaneously regressing papulonodular eruption. In Angora rabbits immunized with a heterologous vaccine, myxomatosis causes black papules in depilated skin. Diagnosis is based on clinical presentation and histopathology and may be confirmed with viral isolation studies. Management of myxomatosis is limited

to treatment of secondary bacterial infections. Prevention is based on vector control and the use of a homologous vaccine; nonhealthy rabbits and pregnant or lactating females should not be vaccinated. A heterologous intradermal vaccine containing an attenuated Shope fibroma virus has also been used. Vaccination is not always effective, but vaccinated animals that contract the virus have less severe clinical signs and often survive with good supportive care. Animals with severe myxomatosis should be euthanized. Vaccines are not commercially available in the United States.

The Shope papillomavirus, a naturally occurring poxvirus of North and South American wild rabbits (*Sylvilagus* spp), produces hyperkeratotic nodules. These hornlike nodules (warts) have been hypothesized as the origin of the jackalope legend of the western United States and the *wolpertinger* legend of southern Germany (where papillomavirus is also found), both of which depict horned rabbits or hares.²⁸ Infection of domestic rabbits (*O. cuniculus*), although rare, has been reported and results in multiple hornlike lesions around the ears and eyelids. Manual removal has resulted in healing in wild rabbits, but experimental infection in domestic rabbits resulted in approximately 75% of inoculation sites undergoing malignant transformation to squamous cell carcinoma. Metastasis of the squamous cell carcinomas to the axillary lymph nodes has been reported. Domestic rabbits are infected occasionally via mosquito vectors and develop papillomas that slough away approximately 30 days after inoculation. Newborn and young animals develop more extensive lesions. Diagnosis is based on clinical signs and histopathology. Treatment involves removal of the papillomas or squamous cell carcinomas and control of arthropod vectors.²

Fibromas in domestic rabbits usually are thought to be caused by the Shope fibroma virus. In the Eastern cottontail rabbit (*Sylvilagus floridanus*), and possibly in other North American rabbits, the virus causes benign, localized fibromas of the legs, feet, muzzle, or periocular area. These fibromas usually regress over a period of months. Regression of similar tumors has been noted in domestic rabbits in the United States; however, Shope fibroma virus has also been implicated in several severe epizootics in commercial rabbitries in the United States. Diagnosis is based on clinical signs and histopathology or virus isolation and identification. No treatment is known, but control of arthropod vectors would seem prudent.^{2,4}

NODULES OF NONINFECTIOUS ETIOLOGY

Neoplasia

Cutaneous lymphoma has been described in four domestic rabbits.^{29,30} Three of the rabbits were young (7 weeks, 1 year, and 18 months) and were euthanized

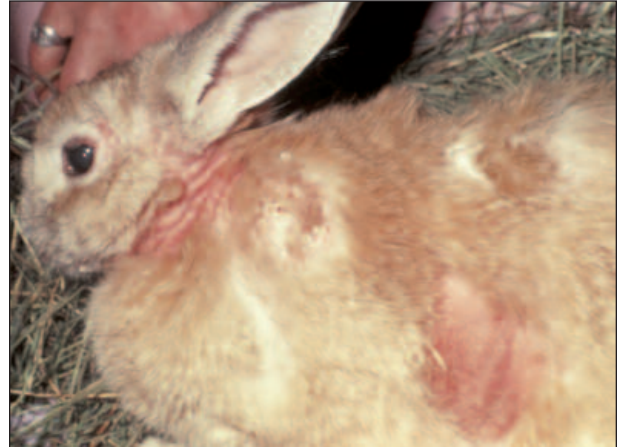

Figure 6—Rabbit with cutaneous lymphoma; note alopecia and scaling of the neck and lateral trunk. (From White SD, Campbell T, Logan A, et al: Lymphoma with cutaneous involvement in three domestic rabbits (*Oryctolagus cuniculus*). *Vet Dermatol* 11:61–67, 2000; with permission of Blackwell Publishing)

soon after showing clinical signs. Lymphoma also was found in the internal organs of two of these rabbits. The fourth rabbit was 9.5 years of age and lived for more than 1 year after diagnosis; clinical signs and histologic findings resembled epitheliotropic T cell lymphoma in other domestic species³⁰ (Figure 6). No response was seen with either 2 months of α -interferon administration or a 2.5-week course of isotretinoin treatment. After 1 year the rabbit died suddenly; the owner refused necropsy. Immunologic stains of the tumor in three of the rabbits (including the 9.5-year-old) showed T cells to be the lymphoma cell type.³⁰

Squamous cell carcinoma, sebaceous gland carcinoma, and basal cell tumor are other cutaneous neoplasms reported in rabbits.³¹ Trichoblastomas (basal cell tumors) were the most commonly diagnosed skin neoplasms in a recent retrospective study.³²

Dermal Fibrosis

This condition has been reported in two adult intact male rabbits.^{33,34} The noted clinical sign was several areas of skin thickening on the dorsum. Neither alopecia nor pruritus was reported, and treatment was not attempted. One report conjectured that this change was similar histologically and clinically to the thickening seen on the cheeks of intact male cats and hypothesized that these changes were hormonally induced.³⁴

Eosinophilic Granuloma

An eosinophilic granuloma-like lesion, identified as an eosinophilic plaque, has been reported in a New Zealand white rabbit.³⁵ One of the authors (A. M.) has

seen a histologically confirmed case of eosinophilic granuloma in a mixed-breed house rabbit. The clinical presentation was self-mutilation of the ventral abdomen; weight loss; and an erythematous, necrotic, ulcerative, well-demarcated lesion stretching from the umbilicus to the perineum. *Cheyletiella* mites and eggs were found in scrapings taken from the edge of the lesion. Complete resolution was achieved with an injection of methylprednisolone acetate and treatment of the mites with ivermectin.

MISCELLANEOUS CONDITIONS

Cutaneous Asthenia (Ehlers-Danlos Syndrome)

The hallmark of Ehlers-Danlos syndrome is skin fragility in a young rabbit. Four cases of this syndrome have been described in the literature.³⁶⁻³⁹ Typical clinical presentation is hyperextensible, thin, fragile skin or gaping wounds that heal poorly. A genetic defect is suspected because of the young age of the reported rabbits (4 months to 1 year) and because the condition was found in two sibling rabbits.³⁶ Diagnosis is based on clinical findings. Histopathologic examination of the skin biopsy may be normal or may reveal a reduced density of collagen fibers. A decreased number of hair follicles have been observed. Electron microscopy has shown ultrastructural abnormalities in the structure of the collagen fibrils and in their arrangement in bundles of fibers.^{37,39}

Blue Fur Disease

This moist dermatitis, caused by *Pseudomonas aeruginosa*, is common in overweight and female rabbits with a large dewlap or in animals with severe dental disease and excess salivation. The wet fur becomes infected with *Pseudomonas* and turns a characteristic blue color. Treatment involves clipping the affected area and applying an antiseptic solution (e.g., dilute chlorhexidine), plus addressing the underlying cause.

REFERENCES

- Collins BR: Dermatologic disorders of common small nondomestic animals, in Nesbitt GH (ed): *Dermatology. Contemporary Issues in Small Animal Practice*, vol 8. New York, Churchill Livingstone, 1987, pp 235-294.
- Jenkins JR: Skin disorders of the rabbit. *Vet Clin North Am Exot Anim Pract* 4:543-563, 2001.
- Jacobs DE, Hutchinson MJ, Fukase T, et al: Efficacy of imidacloprid on rabbits naturally or experimentally infested with the cat flea, *Ctenocephalides felis*. *Compend Contin Educ Pract Vet* 23(suppl A):11-14, 2001.
- Burgmann P: Dermatology of rabbits, rodents and ferrets, in Rosenthal K (ed): *Practical Exotic Animal Medicine: The Compendium Collection*. Yardley, PA, Veterinary Learning Systems, 1997, pp 174-195.
- Bourdeau PJ: Ectoparasites in rodents and rabbits, in *Proc 17th Eur Soc Vet Dermatol-Eur College Vet Dermatol Congr*:39-48, 2001.
- Harvey RG: Dermatitis in a cat associated with *Spilopsyllus cuniculi*. *Vet Rec* 126:89-90, 1990.
- Pinter L: *Leporacarus gibbus* and *Spilopsyllus cuniculi* infestation in a pet rabbit. *J Small Anim Pract* 40:220-221, 1999.
- Malley D: Use of Frontline spray in rabbits. *Vet Rec* 140:664, 1997.
- Webster M: Product warning: Frontline. *Aust Vet J* 77:202, 1999.
- Hanssen I, Mencke N, Asskildt H, et al: Field study on the insecticidal efficacy of Advantage against natural infestations of dogs with lice. *Parasitol Res* 85:347-348, 1999.
- Cutler SL: Ectopic *Psoroptes cuniculi* infestation in a pet rabbit. *J Small Anim Pract* 39:86-87, 1998.
- Wagner R, Wendlberger U: Field efficacy of moxidectin in dogs and rabbits naturally infested with *Sarcoptes* spp, *Demodex* spp and *Psoroptes* spp mites. *Vet Parasitol* 93:149-158, 2000.
- Bourdeau P, Fain A, Fromeaux-Cau C, et al: An original dermatosis in a rabbit (*Oryctolagus cuniculus*) due to a newly discovered mite *Psorobia lagomorphae* nov. subsp [abstract], in *Proc 17th Eur Soc Vet Dermatol-Eur College Vet Dermatol Congr*:188, 2001.
- Bourdeau P, Mangion C: The acaricidal effects of pyriproxifen on *Ornithonyssus bacoti*: A new concept in control [abstract]. *Vet Dermatol* 11(suppl 1):58, 2000.
- Jackson HC, Chesterman MP: In-vivo effects of ivermectin on *Rhipicephalus appendiculatus*. The influence of tick feeding patterns and drug pharmacokinetics. *Exp Appl Acarol* 7:109-119, 1989.
- The Merck Veterinary Manual*. Whitehouse Station, NJ, Merck & Co, 1998, p 1396.
- Battles AH, Adams SW, Courtney CH, et al: Efficacy of ivermectin against natural infection of *Syphacia muris* in rats. *Lab Anim Sci* 37:791-792, 1987.
- Flynn BM, Brown PA, Strong D: Treatment of *Syphacia obvelata* in mice using ivermectin. *Lab Anim Sci* 39:461-463, 1989.
- White SD, Rosychuk RAW, Fieseler KV: Clinicopathologic findings, sensitivity to house dust mites and efficacy of milbemycin oxime treatment of dogs with *Cheyletiella* sp infestation. *Vet Dermatol* 12:13-18, 2001.
- White SD, Linder K, Shultheiss P, et al: Sebaceous adenitis in four domestic rabbits (*Oryctolagus cuniculus*). *Vet Dermatol* 11:53-61, 2000.
- White SD, Rosychuk RAW, Scott KV, et al: Sebaceous adenitis in dogs and results of treatment with isotretinoin and etretinate in 30 cases (1990-1994). *JAVMA* 297:197-200, 1995.
- Vangeel I, Pasmans F, Vanrobaeys M, et al: Prevalence of dermatophytes in asymptomatic guinea pigs and rabbits. *Vet Rec* 146:440-441, 2000.
- Zrimsek P, Kos J, Pinter L, et al: Detection by ELISA of the humoral immune response in rabbits naturally infected with *Trichophyton mentagrophytes*. *Vet Microbiol* 70:77-86, 1999.
- Ben Zion Y, Arzi B: Use of lufenuron for treating fungal infections of dogs and cats: 297 cases (1997-1999). *JAVMA* 217:1510-1513, 2000.
- Harvey RG: *Demodex cuniculi* in dwarf rabbits (*Oryctolagus cuniculus*). *J Small Anim Pract* 31:204-207, 1990.
- Fountain K: *Coenurus serialis* in a pet rabbit. *Vet Rec* 147:340, 2000.
- Tomczak RL, Dowdy N, Storm T, et al: Use of ceftazidime-impregnated polymethyl methacrylate beads in the treatment of *Pseudomonas osteomyelitis*. *J Foot Surg* 28:542-546, 1989.

28. Simberloff DS: A funny thing happened on the way to the taxidermist. *Nat Hist* 96(8):50–55, 1987.
29. Hinton H, Regan M: Cutaneous lymphoma in a rabbit. *Vet Rec* 103:140–141, 1978.
30. White SD, Campbell T, Logan A, et al: Lymphoma with cutaneous involvement in three domestic rabbits (*Oryctolagus cuniculus*). *Vet Dermatol* 11:61–67, 2000.
31. Roccabianca P, Ghisleni G, Scanziani E: Simultaneous seminoma and interstitial cell tumour in a rabbit with a previous cutaneous basal cell tumour. *J Comp Pathol* 121:95–99, 1999.
32. Mauldin EM, Goldschmidt MH: A retrospective study of cutaneous neoplasms in domestic rabbits (1900–2001) [abstract]. *Vet Dermatol* 13:214, 2002.
33. Mackay R: Dermal fibrosis in a rabbit. *Vet Rec* 147:252, 2000.
34. Hargreaves J, Hartley NJ: Dermal fibrosis in a rabbit. *Vet Rec* 147:400, 2000.
35. Henriksen P: Eosinophilic granuloma-like lesion in a rabbit. *Nord Vet Med* 35:243–244, 1983.
36. Harvey RG, Brown PJ, Young RD, et al: A connective tissue defect in two rabbits similar to the Ehlers-Danlos syndrome. *Vet Rec* 126:130–132, 1990.
37. Brown PJ, Young RD, Cripps PJ: Abnormalities of collagen fibrils in a rabbit with a connective tissue defect similar to Ehlers-Danlos syndrome. *Res Vet Sci* 55:346–350, 1993.
38. Sinke JD, van Dijk JE, Willemse T: A case of Ehlers-Danlos-like syndrome in a rabbit with a review of the disease in other species. *Vet Q* 19:182–185, 1997.
39. Iglauer F, Wilmering G, Huisinga E, et al: Cutaneous asthenia (Ehlers-Danlos syndrome) in a domestic rabbit. *Dtsch Tierarztl Wochenschr* 106:500–505, 1999.
4. Venereal spirochetosis (rabbit syphilis) is caused by infection with
 - a. *T. cuniculi*.
 - b. myxomatosis virus.
 - c. *M. canis*.
 - d. *M. gypseum*.
 - e. Shope fibroma virus.
5. On histopathology, sebaceous adenitis may show
 - a. thinning of the stratum corneum.
 - b. inflammation of the follicular sweat glands.
 - c. absence of the sebaceous glands.
 - d. hypertrophy of the sebaceous glands.
 - e. abnormal twisting of the dermal collagen fibers.
6. Rabbits treated with penicillin G should be monitored closely for signs of
 - a. skin rashes.
 - b. antibiotic-associated enterotoxemia.
 - c. metritis and abortion.
 - d. autoimmune thrombocytopenia.
 - e. keratoconjunctivitis sicca.
7. Definitive diagnosis of dermatophytosis is made by
 - a. fungal culture.
 - b. histopathology.
 - c. Wood's lamp examination.
 - d. direct microscopic examination of affected hairs.
 - e. electron microscopy.

ARTICLE #1 CE TEST

The article you have read qualifies for 1.5 contact hours of Continuing Education Credit from the Auburn University College of Veterinary Medicine. Choose the best answer to each of the following questions; then mark your answers on the postage-paid envelope inserted in *Compendium*.

1. The life cycle of the rabbit flea is controlled by the
 - a. hormonal cycle of the rabbit.
 - b. ambient temperature.
 - c. presence of other flea species.
 - d. species of the rabbit.
 - e. blood type of the rabbit.
2. Which ectoparasiticide is not recommended for use in rabbits?
 - a. ivermectin
 - b. fipronil
 - c. imidacloprid
 - d. lime sulfur
 - e. selamectin
3. The most frequent cause of otitis in rabbits is
 - a. *P. aeruginosa*.
 - b. *Malassezia pachydermatis*.
 - c. *T. mentagrophytes*.
 - d. *P. cuniculi*.
 - e. *O. bacoti*.
8. Treatment of *Cuterebra* spp entails
 - a. ivermectin.
 - b. piperazine.
 - c. no drug intervention.
 - d. careful surgical removal.
 - e. griseofulvin.
9. A rabbit is presented with edema of the head, ears, eyelids, and genitalia; a milky oculonasal discharge; and development of firm, nonpruritic, erythematous nodules. The rabbit is lethargic and febrile. The most likely diagnosis is
 - a. rabbit syphilis.
 - b. myxomatosis.
 - c. cuterebriasis.
 - d. viral papillomatosis.
 - e. *Pasteurella* spp infection.
10. The nonburrowing rabbit fur mite that causes a scaling dermatosis, and may cause a papular eruption in humans, is
 - a. *Listrophorus gibbus*.
 - b. *Leporacarus gibbus*.
 - c. *O. bacoti*.
 - d. *P. cuniculi*.
 - e. *C. parasitovorax*.