ORIGINAL ARTICLE

Cytohistological correlation in diagnosis of lung tumors by using fiberoptic bronchoscopy: Study of 200 cases

Anita Bodh, Vijay Kaushal, Surender Kashyap[1], Anchna Gulati

Departments of Pathology, and [1]Pulmonary Medicine, I.G.M.C., Shimla, Himachal Pradesh, India

Address for correspondence:
Dr. Anita Bodh, Department of Pathology, I.G.M.C., Shimla, Himachal Pradesh, India. E-mail: anitabodh@yahoo.co.in

Access this article online
Website: www.ijpmonline.org
DOI: 10.4103/0377-4929.118661
Quick Response Code:

ABSTRACT

Background: Examination of specimens obtained through flexible fiberoptic bronchoscope is an important and often the initial diagnostic technique performed in patients with suspected malignant lung lesion. **Aims:** To evaluate the correlation of cytological findings of bronchial washings, bronchial brushing and imprint smear of bronchial biopsy in the diagnosis of lung tumors, with histopathology of bronchial biopsy taking the latter as the confirmatory diagnostic test. **Materials and Methods:** A total of 200 patients with lung mass were included in the study. Bronchial brushings were obtained from all 200 cases. In the first 100 cases, pre-biopsy bronchial washing (washing collected before the brushing and biopsy procedure) while post-biopsy washing (washing at the end of the procedure) was procured in all 200 cases. Imprint smears of bronchial biopsy were prepared in 150 cases. **Results:** Sensitivity and specificity of brushing was 76.58% and 77.78% respectively and that of imprint smear was 81.35% and 78.12% respectively. Pre-biopsy and post-biopsy washing showed high specificity of 88.89%, but low sensitivity of 30.14 and 36.77% respectively. No significant difference was found in sensitivity between brushing and imprint smear (Chi-square; $P = 0.4187$); and between pre-biopsy and post-biopsy washing (Chi-square; $P = 0.7982$). However, there was a significant difference between sensitivity of brushing and washing (Chi-square; $P = 0.0001$). The sensitivity of combination of three cytological diagnostic techniques was 87.29%. **Conclusion:** Bronchial brushing and washing cytology in combination with imprint cytology aids in the diagnosis of lung tumors. Therefore, all these techniques may be used concurrently along with bronchial biopsy to diagnose lung tumors.

KEY WORDS: Bronchial washing, brushing, fiberoptic bronchoscopy, imprint smear, lung cancer

INTRODUCTION

Lung cancer is the most frequently diagnosed cancer and also the leading cause of all cancer associated deaths in the world.[1] Previously bronchogenic carcinoma was considered to be infrequent in India, but in the recent past a trend of increase in its incidence has been noticed.[2] Lung cancer has been estimated to be the most frequent among all the new cases of cancers in male in this country.[3]

Bronchoscopy is perhaps the most invaluable tool for diagnosis of lung cancer. Various diagnostic techniques have been developed using flexible fiberoptic bronchoscopy.[4,5] Cytological assessment of specimens of the respiratory tract is an important and often the initial diagnostic technique carried out in a patient with suspected malignant lung lesion.[6] The utilities of cytology is extensive and some time they help in planning the treatment without the requirement for an open biopsy. Both washing and brushing are very effective in the diagnosis and differential diagnosis of lung cancers. Brushings often offer excellent specimens and accurate information about the site of the lesion.[7] Imprint smears from bronchial biopsy has also been found to give a good diagnostic yield.[8] Among various bronchoscopic techniques, bronchial biopsy has the highest sensitivity for endobronchial malignant lesions.[9] Bronchial biopsy has also been used as the gold standard diagnostic test to assess the efficacy of other cytologic techniques.[10] Better diagnostic yield is often obtained when cytologic techniques are used together with bronchial biopsy.[11] In general the concordance between cytology and histopathology ranges from 70% to 90% and the bronchial biopsy is confirmatory for most of the cytological findings.[4]

In view of the importance of cytological methods in diagnosis of lung tumors and paucity of such studies from our state, the current study was planned with the objective of assessing the correlation of cytology of bronchial washings, bronchial brushing and imprint smear of bronchial biopsy in the diagnosing lung tumors, with histopathology of bronchial biopsy taking the latter as the confirmatory diagnostic test

MATERIALS AND METHODS

It was a prospective study conducted in the Department of Pathology of a teaching hospital. The samples for cytological and histological examination were collected from the indoor/outdoor patients in whom clinical findings, radiological examination and bronchoscopic examination suggested lung mass. A total of 200 cases were included in the study. The samples were obtained by flexible fiberoptic bronchoscopy done by the Pulmonologist. Bronchial brushings were obtained by the use of a stiff-bristle disposable brush. Brushing material was smeared directly on to at least three clean glass slides. The air dried smears were stained with Geimsa stain. In the first 100 cases, bronchial washing was obtained before the brushing and biopsy procedure (pre-biopsy washing). However, at the end of procedure bronchial washing (post-biopsy washing) was procured in all 200 cases. Samples were centrifuged and prepared into air dried smear. Staining was done with Giemsa stain. Imprint smears were prepared from the bronchial biopsy in 150 out of 200 cases. Imprint smears were prepared by placing forceps biopsy specimens of about 2 mm size on a glass slide and rolling over the surface. The smears were air dried and stained with Giemsa stain. Bronchial biopsies were fixed in 10% formalin and stained with H and E.

RESULTS

Majority cases (73.0%) were males with male female ratio of 3.35:1. The mean age of the sample was 62 years with a range of 25-89 years. Most of the patients were from a rural background (86.5%) and rural urban ratio was 6.41. Out of 200 cases subjected to bronchoscopy, lung cancer was confirmed in 155 (77.5%) cases by histopathology of bronchial biopsy as shown in Table 1. Among patients with lung cancer, 88.24% of male and 50% of females were active smokers at the time of assessment. Squamous cell carcinoma was found to be the commonest lung cancer (38.70%), followed by small cell carcinoma (27.10%) and adenocarcinoma (23.87%).

Morphological differentiation of lung cancer by different cytological techniques is shown in Table 2. All except one case of bronchial biopsy [Figure 1] could be differentiated in to a specific type of carcinoma. However, minority of washing [Figure 2] samples (6/22 in pre-biopsy and 15/57 in post-biopsy washing) which showed malignancy could be classified morphologically into a specific type of carcinoma. Bronchial brushing [Figure 3] and imprint smear cytology [Figure 4] were found to be better than washing cytology in morphological differentiation of lung tumor.

Comparison of various cytological techniques with bronchial biopsy is shown in Tables 3 and 4. Sensitivity and specificity of brushing was found to be 78.06% and 77.78% respectively and that of imprint smear was 81.35% and 78.12% respectively. Pre-biopsy and post-biopsy washing showed high specificity of 88.89%, but a very low sensitivity of 30.14 and 36.77% respectively.

Table 1: Lung cancer distribution

Lung cancer	*Number of cases*		*Total*	*%*
	Male	*Female*		
Squamous cell carcinoma	47	13	60	38.70
Small cell carcinoma	31	11	42	27.10
Adenocarcinoma	29	8	37	23.87
Large cell anaplastic carcinoma	8	2	10	6.45
Poorly differentiated carcinoma	3	1	4	2.58
Bronchial carcinoid	0	1	1	0.65
Positive of malignancy*	1	0	1	0.65
Total	119	36	155	100

*Sample had scant material and differentiation in to specific type of tumor was not possible

Table 2: Morphology of lung cancer by different techniques

Type of lesions	*Biopsy N=155*	*Brush N=121*	*Imprint N=96*	*Washing*	
				Post-biopsy N=57	*Pre-biopsy N=22*
Squamous cell carcinoma	60	44	30	5	3
Small cell carcinoma	42	33	26	5	1
Adenocarcinoma	37	29	23	2	2
Large cell anaplastic carcinoma	10	7	4	3	0
Poorly differentiated non-small cell CA	4	3	5	0	0
Positive for malignancy* (scant material)	1	5	8	42	16
Bronchial carcinoid	1	0	0	0	0
Total	155	121	96	57	22

*Samples had scant material and differentiation in to specific type of tumor was not possible.
CA: Carcinoma

There was no significant difference in sensitivity between brushing and imprint smear (Chi-square; $P = 0.4187$); and between pre-biopsy and post-biopsy washing (Chi-square; $P = 0.7982$).

However, there was statistically significant difference between sensitivity of brushing and washing (Chi-square; $P = 0.0001$). The sensitivity of combination of three diagnostic techniques brushing, imprint smear and washing is 87.29%.

DISCUSSION

The present study was conducted with the objectives of assessing the sensitivity and specificity of bronchoscopic cytological procedures; bronchial brushing, washing, imprint cytology by comparing with the histopathology of bronchial biopsy obtained from lung tumors.

In the present study, the bronchial brushing could detect malignancy in 121 out of 155 (78.06%) cases and we found a sensitivity of 78.06% and specificity of 77.78%. This finding of the present study is similar to the result that was observed by Mak *et al.*[12] and Chen *et al.*[13]

Imprint smear of bronchial biopsy had a sensitivity of 81.35% and in 69.07% (67/96) cases correct cell typing by imprint smear could

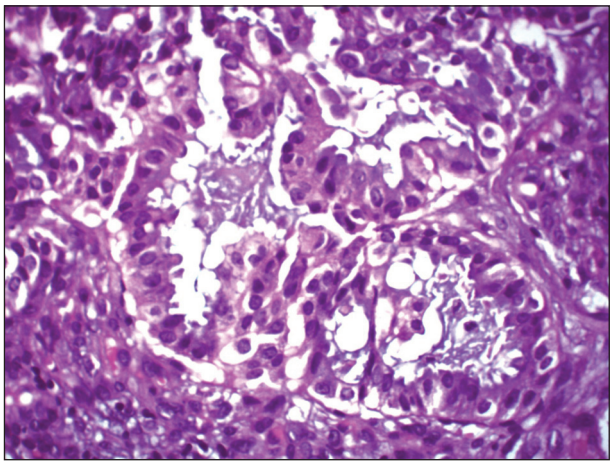

Figure 1: Bronchial biopsy of adenocarcinoma of lung (H and E, ×400)

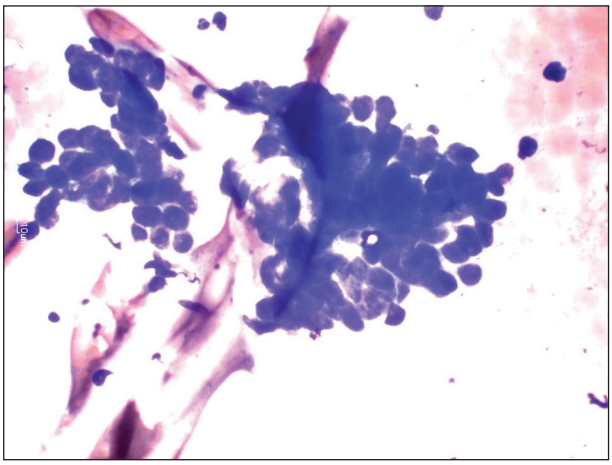

Figure 2: Bronchial washing shows squamous cell carcinoma (Giemsa stain, ×400)

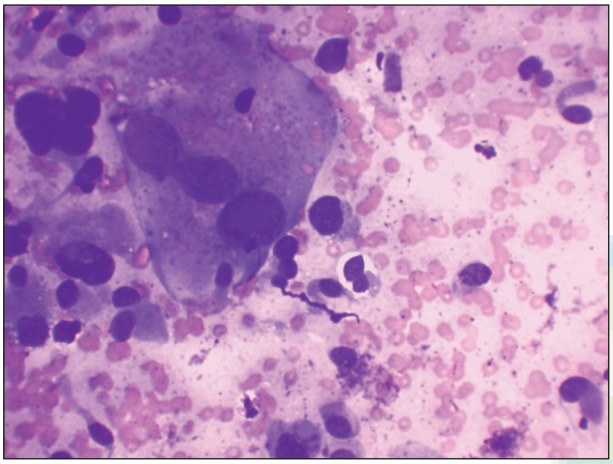

Figure 3: Bronchial brushing showing emperipolesis and tumor giant cell of large cell undifferentiated carcinoma (Giemsa stain, ×400)

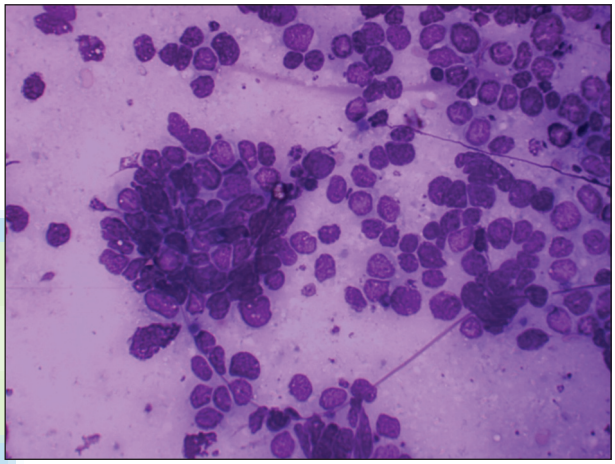

Figure 4: Imprint smear of bronchial biopsy showing small cell carcinoma (Giemsa stain, ×400)

Table 3: Results of cytological techniques compared to gold standard (bronchial biopsy)

Sample	*Test results*				*Total*
	True positive	*True negative*	*False positive*	*False negative*	
Brushing	121	35	10	34	200
Imprint smear	96	25	7	22	150
Pre-biopsy washing	22	24	3	51	100
Post-biopsy washing	57	40	5	98	200

Table 4: Comparison of indices of cytological techniques

Cytological test	*Sensitivity (%)*	*Specificity (%)*
Brushing	78.06	77.78
Imprint smear	81.35	78.12
Pre-biopsy washing	30.14	88.89
Post-biopsy washing	36.77	88.89

be made. Previous studies have found almost similar results of positive rate of diagnostic yield from imprint smear of bronchial biopsy.[8,14] However, as far as morphological typing is concerned a previous study had a higher rate of cell typing of different carcinomas among the positive imprint smear cases (86.1%) as compared to ours (69.07%).[8] Overall relatively fewer literatures are available that evaluated the imprint smear of the bronchial biopsy in the diagnosis.

Bronchial washing is often used along with bronchial brushing and biopsy to diagnose lung cancer. However, the optimal timing of bronchial washing with respect to biopsy and brushing (i.e., whether before or after biopsy and brushing) has been subject to debate. In order to assess the optimal sequence in which bronchial washing be performed, the washing was obtained in two ways in the present study: Pre-biopsy washing and post-biopsy washing. Sensitivity of pre-biopsy washing was found to be 30.14% and that of post-biopsy washing was 36.77% in patients of lung cancer confirmed by bronchial biopsy. Previous studies by Buccheri, *et al*.,[15] Park *et al*.[16] and Karahalli *et al*.[17] had found almost comparable result of bronchial washing in lung cancer cases. However, in many other previous studies by Solomon *et al*.,[18] van der Drift *et al*.,[19] Fernández-Villar *et al*.,[20] Khan and Rafi[21] the

diagnostic yield of bronchial washing was at variance with that of our study. On comparing, no significant difference was found between sensitivity of pre-biopsy washing and post-biopsy washing cytology in the current study. Similar trend was noticed in previous studies also.[19,22]

There has been a controversy as to whether bronchial washing should be routinely used or not. Many studies like Trevisani *et al*.,[23] Karahalli *et al*.[17] in the past reported that the diagnostic yield did not increase significantly further by the addition of bronchial washing to bronchial biopsy and recommended that washing should not be routinely used. However, authors likes Mak *et al*.,[12] Jones *et al*.[24] have suggested that bronchial biopsy, brushing and washing should be performed to obtain optimal diagnostic yield. Liwsrisakun *et al*.[25] have observed that the addition of bronchial washing to either biopsy or brushing is beneficial, but it may not be cost-effective.

False positive results were noticed in these cytological techniques used in the present study. It may be possible that some of these classified as false positives in the present study might be true positives as methods other than bronchial biopsy to confirm the diagnosis of lung cancer were not used in the present study. Majority of the previous studies[8,9,17,19,26] that have used other techniques such as rebronchoscopy, surgery, transthoracic needle aspiration (TTNA), tumor markers and autopsy, to prove the cases of lung cancer have shown that bronchial biopsy does not provide diagnostic yield in all cases of lung cancer. Chances of missing the diagnosis by bronchial biopsy are more in peripheral lung tumors. In the present study, most of false positive on brushing (8 out of 10) with respect to bronchial biopsy were diagnosed as adenocarcinoma. On bronchoscopic examination, the gross morphology of majority of these cases of adenocarcinoma were compression type lesion i.e., extrinsic compression of the bronchus by the lesion[15] and thus there may be a possibility of getting less representative material by bronchial biopsy in such tumors. Furthermore, in mucinous type of adenocarcinoma, bronchial biopsy specimen may contain pools of mucin, very few neoplastic cells with a relative lack of atypia that make the diagnosis of adenocarcinoma more difficult as observed by Butnor.[26]

One of the limitations of our study is use of only bronchial biopsy for the validation of cytological techniques and the absence of other confirmatory tests like surgical biopsy, transbronchial needle aspiration, TTNA, mediastinoscopy, biopsies of extrapulmonary lesions and autopsy. Other limitations was the inability to further typing of large cells carcinomas and sub-typing of poorly differentiated non-small cell carcinomas in the absence of tumor markers.

Based on findings of the study, it may be concluded that obtaining of bronchial brushing and washing cytology specimens using bronchoscopy in combination with imprint cytology aids in the diagnosis of lung tumors with a reasonable high accuracy rate of morphological typing of neoplasms. Therefore, all these techniques may be used concurrently along with bronchial biopsy to diagnose the lung tumors.

REFERENCES

1. Parkin DM, Bray F, Ferlay J, Pisani P. Global cancer statistics, 2002. CA Cancer J Clin 2005;55:74-108.
2. Behera D, Balamugesh T. Lung cancer in India. Indian J Chest Dis Allied Sci 2004;46:269-81.
3. International Agency for Research on Cancer. GLOBOCAN 2008-Cancer Incidence and Mortality Worldwide in 2008. Available from: http://www.globocan.iarc.fr/. [Last accessed on 2012 Jul 8].
4. Rosai J. Respiratory tract — Lung & pleura. In: Rosai and Ackerman's Surgical Pathology. 9th ed. Missouri: Mosby, An Imprint of Elsevier; 2004. p. 359-458.
5. El-Bayoumi E, Silvestri GA. Bronchoscopy for the diagnosis and staging of lung cancer. Semin Respir Crit Care Med 2008;29:261-70.
6. Guidelines of the Papanicolaou Society of Cytopathology for the examination of cytologic specimens obtained from the respiratory tract. Papanicolaou Society of Cytopathology Task Force on Standards of Practice. Diagn Cytopathol 1999;21:61-9.
7. Melamed MR. Tumours of the lung: Conventional cytology and aspiration biopsy. In: Koss LG, Melamed MR, editors. Koss's Diagnostic Cytology and its Histopathologic Basis. 5th ed. Lippincott: Williams & Wilkins; 2006. p. 643-712.
8. Popp W, Rauscher H, Ritschka L, Redtenbacher S, Zwick H, Dutz W. Diagnostic sensitivity of different techniques in the diagnosis of lung tumors with the flexible fiberoptic bronchoscope. Comparison of brush biopsy, imprint cytology of forceps biopsy, and histology of forceps biopsy. Cancer 1991;67:72-5.
9. Schreiber G, McCrory DC. Performance characteristics of different modalities for diagnosis of suspected lung cancer: Summary of published evidence. Chest 2003;123:115S-28.
10. Gaur DS, Thapliyal NC, Kishore S, Pathak VP. Efficacy of broncho-alveolar lavage and bronchial brush cytology in diagnosing lung cancers. J Cytol 2007;24:73-7.
11. Rivera MP, Detterbeck F, Mehta AC, American College of Chest Physicians. Diagnosis of lung cancer: The guidelines. Chest 2003; 123:129S-36.
12. Mak VH, Johnston ID, Hetzel MR, Grubb C. Value of washings and brushings at fibreoptic bronchoscopy in the diagnosis of lung cancer. Thorax 1990;45:373-6.
13. Chen WT, Chao TY, Wu CP, Perng WC, Shen CY, Chiang CH. Comparison of the diagnostic yield of bronchial brushing cytology before and after endobronchial biopsy of flexible fibroptic bronchoscopy — A prospective study. J Med Sci 1997;18:165-70.
14. Jan RA. Yield of imprint and crush cytology in endobronchial growths. Chest 2009;136:141S.
15. Buccheri G, Barberis P, Delfino MS. Diagnostic, morphologic, and histopathologic correlates in bronchogenic carcinoma. A review of 1,045 bronchoscopic examinations. Chest 1991;99:809-14.
16. Park KS, Park JY, Cha SI, Son JW, Kim KY, Kim JS, *et al*. Bronchial brushing and bronchial washing for diagnosis of central lung cancer. Tuberc Respir Dis 1999;46:817-25.
17. Karahalli E, Yilmaz A, Türker H, Ozvaran K. Usefulness of various diagnostic techniques during fiberoptic bronchoscopy for endoscopically visible lung cancer: Should cytologic examinations be performed routinely? Respiration 2001;68:611-4.
18. Solomon DA, Solliday NH, Gracey DR. Cytology in fiberoptic bronchoscopy. Comparison of bronchial brushing, washing and post-bronchoscopy sputum. Chest 1974;65:616-9.
19. van der Drift MA, van der Wilt GJ, Thunnissen FB, Janssen JP. A prospective study of the timing and cost-effectiveness of bronchial

washing during bronchoscopy for pulmonary malignant tumors. Chest 2005;128:394-400.
20. Fernández-Villar A, González A, Leiro V, Represas C, Botana MI, Blanco P, *et al*. Effect of different bronchial washing sequences on diagnostic yield in endoscopically visible lung cancer. Arch Bronconeumol 2006;42:278-82.
21. Khan RSA, Rafi ud Din. Malignant lung tumors: Efficacy of bronchial wash cytology and its correlation with biopsy in diagnosis. Prof Med J 2009;16:187-91.
22. Yigla M, Tov N, Solomonov A, Hardak E, Ben-Izhak O, Rubin AH, *et al*. Bronchoscopic procedures in the diagnosis of exophytic endobronchial malignant neoplasms. J Bronchology 2002;9:102-7.
23. Trevisani L, Pazzi P, Sartori S, Potena A. Value of washings and brushings at fibreoptic bronchoscopy in the diagnosis of lung cancer. Thorax 1991;46:74.
24. Jones AM, Hanson IM, Armstrong GR, O'Driscoll BR. Value and accuracy of cytology in addition to histology in the diagnosis of lung cancer at flexible bronchoscopy. Respir Med 2001;95:374-8.
25. Liwsrisakun C, Pothirat C, Bumroongkit C, Deesomchok A. Role of bronchial washing in the diagnosis of endoscopically visible lung cancer. J Med Assoc Thai 2004;87:600-4.
26. Butnor KJ. Avoiding underdiagnosis, overdiagnosis, and misdiagnosis of lung carcinoma. Arch Pathol Lab Med 2008;132:1118-32.

How to cite this article: Bodh A, Kaushal V, Kashyap S, Gulati A. Cytohistological correlation in diagnosis of lung tumors by using fiberoptic bronchoscopy: Study of 200 cases. Indian J Pathol Microbiol 2013;56:84-8.

Source of Support: Nil, **Conflict of Interest:** None declared.