afterwards, and the pulse rate rose to 35 per minute. An inhalation of 3 minims of amyl nitrite brought the pulse rate up to 40, but the patient's condition was still critical. A further injection of atropine sulphate raised the pulse rate to 60 per minute, the sweating stopped, and the pupils dilated a little.

A little cold tea and bread were now given, and the patient slowly recovered. An hour later he was out of danger and I permitted him to go home.

Cases of eserine poisoning in ophthalmological practice must be rare; and it is obvious that the patient's resistance was far below par, owing to his fast. The effect of atropine in saving the patient's life is obvious.

A CASE OF SPONTANEOUS EXPULSION OF A FOREIGN BODY FROM THE LEFT BRONCHUS.

By K. N. PRADHAN,

Mayo Hospital, Nagpur, C. P.

A MAHOMEDAN boy aged 9 was brought to me at 8 p.m. on the 10th January, 1926. He had had a coloured glass bead in his mouth, and it had suddenly slipped into the trachea. His father brought a duplicate of the bead; it was about 2|5ths of an inch by 1|5th of an inch, and one of some used for ear-rings. Passage of the bead into the trachea was followed by a noisy fit of coughing and pain in the inter-clavicular region, but he took his evening meal well. Stridor however continued.

On examination stridor was present, especially during expiration. Pulse and temperature were normal, and the respiration not particularly increased in rate. Wheezing sounds were heard over both lungs, and a few crepitations on the left side. Nothing was done that evening.

Next day cough and stridor had increased. The child was now examined under an anæsthetic. Laryngoscopic examination failed to shew anything. A branchoscope was available, but no suitable forceps for removal of the foreign body. Colonel Tarr suggested *x*-rays, but as the bead was of glass I did not think that any shadow would shew. The child was taken direct from the theatre to the *x*-ray room, and screening shewed a shadow exactly corresponding to the bead, lying with its sharp narrower end upwards in the left bronchus. The radiologist explained the shadow as being due to the thin coating of metal around the bead.

That afternoon there was slight fever, temperature 102° F., but the stridor had disappeared, and the child was allowed to play. The next day examination of the chest failed to shew any abnormal breath sounds. I explained to the father the "silent interval of Jackson," and told him to bring the child back if there was any fever or cough. I also sent for suitable forceps for the bronchoscope.

On the 17th March the father returned to hospital. He stated that up to the 16th March the child had seemed to be in fair health, except for occasional spells of coughing. That evening, however, he was seized with severe dyspnœa and a choking cough, and appeared to be about to die; when suddenly the bead was coughed out in the presence of the father. The bead, which was brought for examination, had lost its lustrous coating.

I tried to persuade the father to have the child *x*-rayed again, but he would not consent. The case is of interest in the long duration of time during which the foreign body remained lodged in the bronchus, and in its spontaneous expulsion by natural means.

INTRAVENOUS IODINE IN A CASE OF PUERPERAL SEPSIS.

By S. R. INGLE,

Medical Officer, Karjat Dispensary, Colaba.

A HINDU woman, aged 20, second para, was admitted to this dispensary on 9th April, 1926, for difficult labour.

Previous labour.—Difficult and prolonged. Breech presentation. Dead child.

Condition on admission.—The patient had been in labour over 60 hours. The bag of waters had ruptured 48 hours previous to her admission to the dispensary. The patient was poorly nourished, not fully developed and weak. Temperature 100° F., pulse 110 p.m. The child's lie was transverse and it was in 1st position, viz., head to the left, back to the front and legs extended and palpable at the fundus. The right shoulder was driven into the pelvis and the corresponding hand had prolapsed out of the vagina with a loop of umbilical cord. The uterus was firmly contracted over the child which was dead.

Operation.—Under chloroform anæsthesia, attempts were made to turn the child and to deliver it as a breech presentation; but this was found to be impossible owing to the contracted condition of the uterus and smallness of the pelvis. Embryotomy was therefore performed and the child extracted. The placenta followed 15 minutes after delivery of the child and 1 c.c. of pituitrin was injected. On examination the vaginal wall and cervix were found bruised and lacerated. A hot lysol douche was administered and the patient put to bed in Fowler's position. There was no postpartum bleeding. Unfortunately no pelvic measurements could be taken for want of a pelvimeter.

9-4-1926. 4 p.m. Temperature 101°F., pulse 120 p.m. The patient was put on to a mixture containing quinine, ergot and strychnine.

10-4-1926. 8 a.m. Temperature 101° F., pulse 124 p.m. and feeble. External parts

swollen and there was much discharge from the vagina. Hot vaginal douche (1 drachm lysol to a pint of water) morning and evening. Quinine and ergot mixture continued.

10-4-1926. 4 p.m. Temperature 102.4° F., pulse as before. Polyvalent antistreptococcal serum, 10 c.c. injected subcutaneously.

11-4-1926. 8 a.m. Temperature 101.4° F., pulse as before. The patient was put on to a mixture containing potassium citrate, ergot and digitalis.

11-4-1926. 4 p.m. Temperature 105° F., pulse 130 p.m. and feeble. Patient delirious. Iodine douche (2 drachms to a pint) morning and evening. Six grains of camphor in 2 c.c. of olive oil injected intramuscularly at 5 p.m., and ½ grain of iodine in 2 c.c. of distilled water given intravenously. Ice bag to the head.

12-4-1926. 8 a.m. Temperature 102.4° F., pulse 120 p.m. Discharge is less offensive. Swelling of external parts subsided.

½ grain of iodine in 2 c.c. of sterile water intravenously.

13-4-1926. 8 a.m. Temperature 102° F., pulse 130 p.m. and feeble. Six grains of camphor in 2 c.c. of olive oil intramuscularly.

Discharge less. Douche and citrate mixture continued.

½ grain of iodine in 2 c.c. of water intravenously.

14-4-1926. 8 a.m. Temperature 100° F., pulse 110 p.m. General condition satisfactory. Local lesions much better.

15-4-1926. 8 a.m. Temperature 100° F., pulse 114 p.m. and good.

½ grain of iodine intravenously.

16-4-1926. 8 a.m. Temperature normal, pulse 104 p.m. Discharge much reduced and had no smell; feeling better.

Local lesions almost healed up except a tear in the cervix which requires repair. Patient was put on to a tonic mixture.

From 16-4-1926 up to the time of writing—(19-4-1926)—the patient has had no fever and is picking up strength. She could not be given more than 10 c.c. of antistreptococcal serum as she was too poor to buy it and it was not available in the dispensary. She was therefore treated with intravenous iodine. There was no reaction after the iodine injections in this case. The solution of iodine used was the following:—

Iodum	..	.. grs. 6
Potassium iodidi		.. grs. 6
Aqua distillata		.. oz. 1

2 c.c. or 40 minims contain ½ grain of iodine. Intravenous administration of iodine appears to be a most efficacious remedy in cases of puerperal sepsis. Further, its cost is minimal.

AN ATYPICAL CASE OF DOUBLE HYDROCELE.

By R. V. GAJENDRAGADKAR,

Assistant Surgeon, Civil Hospital, Osmanabad, Sholapur District, H. E. the Nizam's Dominions.

THE photograph sent herewith is that of a Hindu male patient of the clerical class, 45 years of age, who was admitted to this hospital for the radical cure of his hydrocele on the 7th January 1926.

The hydrocele had been present since childhood, and was formerly about the size of a lemon; during the past three years, however, it had grown enormously. On examination there was found to be a huge, double-loculated hydrocele on the left side with no hernia; it was about 18″ in length and 12″ in breadth. On the right side there was also a hydrocele of small size. The penis was buried in the fold of the tumour as shewn in the photograph.

Operation.—An incision 8″ in length was made, and the tunica vaginalis separated from the tunica albuginea. The tumour was then tapped, some 3 to 4 lbs. of clear serous fluid being collected in a sterile bottle. The whole tumour was then shelled out, the redundant portion of the tunica albuginea clipped away, and it was then turned back and sutured. The skin incision was sutured and a small gauze drain inserted. The wound healed by first intention; operation was performed on the 7th January and the patient was discharged on the 20th January 1926.

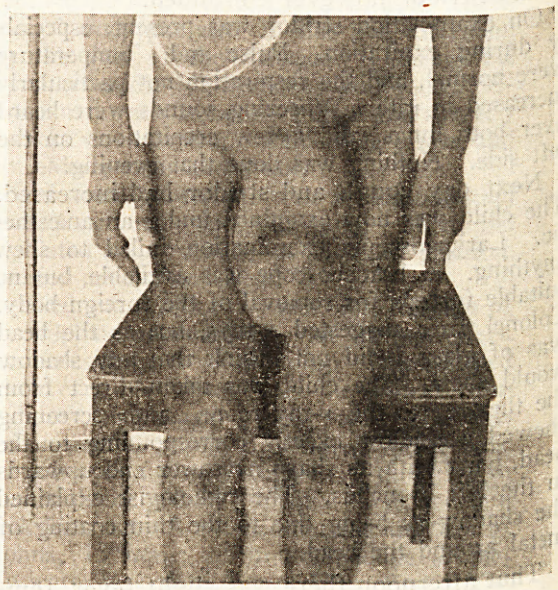

A peculiar feature of the case was the presence within the sac towards the end in which the epididymis lay, of what were apparently small many-sided foreign bodies resembling papaya seeds.