

## Correlation Between Bone and Soft Tissue Thickness in Maxillary Anterior Teeth

Nasrin Esfahanizadeh<sup>1</sup>, Niloufar Daneshparvar<sup>2</sup>✉, Farinaz Askarpour<sup>3</sup>, Nasrin Akhondi<sup>4</sup>, Mehrdad Panjnoush<sup>5</sup>

<sup>1</sup> Associate Professor, Department of Periodontics, Dental Branch, Islamic Azad University, Tehran, Iran; Member of Dental Implant Research Center, Tehran University of Medical Sciences, Tehran, Iran

<sup>2</sup> General Dentist, College Station, USA

<sup>3</sup> Periodontist, Private Practice, Tehran, Iran

<sup>4</sup> Assistant Professor, Department of Mathematics, South Tehran Branch, Islamic Azad University, Tehran, Iran

<sup>5</sup> Assistant Professor, Head of Department of Oral and Maxillofacial Radiology, School of Dentistry, Tehran University of Medical Sciences, Tehran, Iran

### Abstract

**Objectives:** The purpose of this study was to determine buccal bone and soft tissue thicknesses and their correlation in the maxillary anterior region using cone beam computed tomography (CBCT).

**Materials and Methods:** In this cross sectional study, 330 sound maxillary incisors in 60 patients with a mean age of 37.5 years were assessed by CBCT scans. For better visualization of soft tissue, patients were asked to use plastic retractors in order to retract their lips and cheeks away from the gingival tissue before taking the scans. Measurements were made in three different positions: at the crest and at 2 and 5mm apical to the crest. The cemento-enamel junction–crest distance was measured. For data analyses, the Pearson's correlation coefficient, ANOVA and intraclass correlation coefficient were used.

**Results:** There were mildly significant linear associations between labial soft tissue and bone thickness in the canines and incisors ( $r < 0.40$ ,  $P < 0.05$ ), but no association was found for the lateral incisors. The mean thickness of buccal bone differed significantly in the maxillary anterior teeth, being greater for the lateral incisors ( $P < 0.05$ ). For soft tissue thickness, the results were the same, and the least thickness was recorded for the canines. There was a mild association between labial soft tissue and bone thickness in canines and incisors ( $r = 0.2$ ,  $P = 0.3$ ), but no such linear association was seen for the lateral incisors.

**Conclusions:** The mean thickness of buccal bone and soft tissue in the anterior maxilla was  $< 1$ mm and there was a mild linear correlation between them.

**Keywords:** Facial Bones; Cone-Beam Computed Tomography; Maxilla; Esthetics, Dental  
*Journal of Dentistry, Tehran University of Medical Sciences, Tehran, Iran (2016; Vol. 13, No. 5)*

✉Corresponding author:  
N. Daneshparavar, General  
Dentist, College Station, USA

nildan89@yahoo.com

Received: 4 February 2016

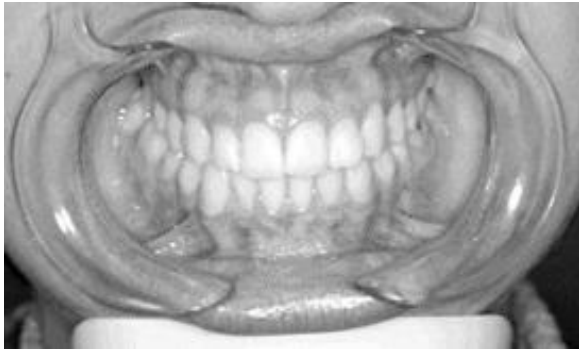Accepted: 23 July 2016

### INTRODUCTION

In terms of esthetics, the anterior maxillary region in particular contributes to an enhanced smile and self-esteem of patients. To achieve a favorable outcome in periodontal and implant treatment, it is crucial to pay attention to morphological characteristics of periodontal tissue such as buccal bone and soft tissue thickness [1]. Alveolar bone contains tooth sockets in the maxilla and mandible. Teeth roots are surrounded by two layers of cortical bone namely the outer cortical plate and alveolar bone proper; cancellous bone is located between the two bone plates. No cancellous bone is seen in

regions with very thin buccal bone and these regions are mainly formed by bundle bone. Bundle bone is a tooth-related structure and is resorbed upon extraction of teeth. Following buccal bone resorption, soft tissue will recess, jeopardizing esthetics [2].

Buccal bone thickness determines the contour of the overlying gingiva. A thin alveolar bone is normally covered by a thin gingival tissue. A thick buccal bone supports the soft tissue and dental papillae and a thick tissue biotype is more resistant to recession [1-3], provides superior implant esthetics and better conceals the prosthetic components of dental implants [1,4].



**Fig. 1:** The patient uses a plastic retractor before scanning

It also facilitates positioning of implant in different locations especially in immediate implant placement [1,5]. A thick tissue biotype plays a significant role in outcome of periodontal therapy [6,7] such as root coverage procedures [6,8,9]. Hence, measuring the thickness of soft tissue and the underlying bone before implant placement is beneficial to prevent complications such as soft tissue recession, implant exposure and consequent psychological problems [1,10]. When required, augmentation can be considered to achieve adequate contours [11].

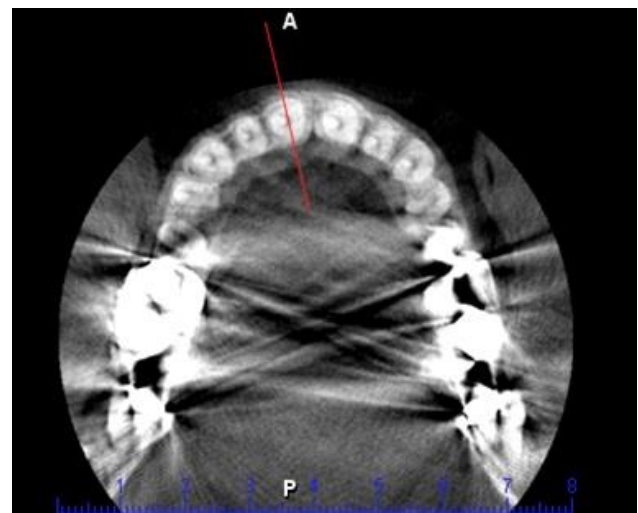
Different methods have been used for measuring buccal bone thickness. Spray et al, [12] reported buccal bone thickness of  $1.8 \pm 1.41$  mm using a caliper. Katranji et al, [13] reported  $1.59 \pm 0.07$  mm thickness using a Boley gauge, and Nowzari et al, [14] reported  $1.12 \pm 0.30$  mm thickness using cone beam computed tomography (CBCT) scans. For soft tissue thickness, different techniques have also been used such as visual inspection, probe transparency, ultrasound and soft tissue CBCT, in which the patients use a plastic lip retractor at the time of scanning for better visualization of soft tissue [15]. Also, CBCT is a suitable method for visualization of teeth and soft tissue anatomy [6] and has the advantage of superior diagnostic value and precise measurement of periodontal dimensions [15]. Barriviera et al, [16] and Müller et al, [17] reported the mean canine gingival thickness to be 0.2 and 0.7 mm, respectively, and Fu et al, [6] reported a mean labial soft tissue

thickness of 0.5 mm in the maxillary anterior region.

Variations in soft tissue and buccal bone dimensions have been speculated to be a result of differences in ethnicity, tooth positions and methodologies [1]. Although determination of soft tissue and buccal bone thickness has been investigated by many authors, only a limited number of studies [6,18] have assessed the association between these variables. Primary thickness of maxillary bone has a significant effect on the final level of soft and hard tissues following tooth extraction and also on selecting the appropriate method of implant placement (immediate/early/delayed) and prevention of subsequent complications [10]. Therefore, this study aimed to measure the dimensions of soft tissue and the underlying bone in the anterior maxilla using CBCT and to determine the association of bone and soft tissue thickness in the maxillary anterior teeth.

## MATERIALS AND METHODS

This cross-sectional study was conducted on patients requiring implant treatment in the Department of Periodontics and Implantology. Sixty patients (35 women, 25 men) with a mean ( $\pm$ standard deviation) age of  $37.5 \pm 10.1$  years were selected.



**Fig. 2:** Line "A" shows the midline of the selected tooth

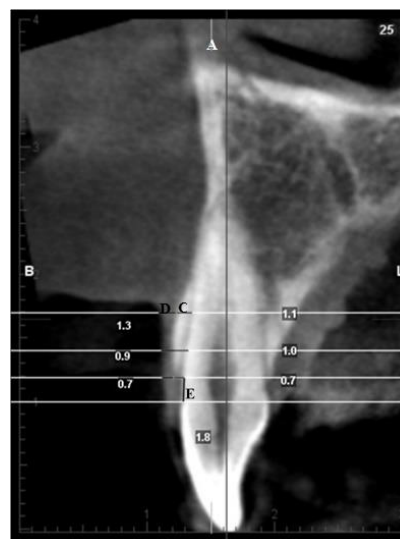
**Table 1:** Association between soft and hard tissue thickness in the maxillary anterior teeth

Tooth type	Coefficient	P-value
Right canine	0.282	0.043
Right lateral incisor	0.202	0.160
Right central incisor	0.369	0.002
Left central incisor	0.332	0.011
Left lateral incisor	0.204	0.138
Left canine	0.276	0.036

The criteria of eligibility were as follows: Presence of at least four teeth in the maxillary anterior region (central incisors, lateral incisors and canines), absence of redness, inflammation or bleeding on probing, absence of attachment loss, probing pocket depth  $\leq 3$ mm, absence of extensive subgingival restorations and tooth mal-alignment, no pregnancy or lactation and not taking medications affecting periodontal soft tissue [19].

This study was approved by the Ethics Committee of Faculty of Dentistry. Written informed consent was obtained from all the patients who were then referred to a radiology center for CBCT examination. The CBCT scans were taken with a Planmeca Promax 3D unit (Planmeca, Helsinki, Finland) with 80x80mm field of view, total scanning time of 30 seconds at 80-82 kVp and 12 mA, and an exposure time of 12 seconds. The scans were acquired in high-resolution mode with a voxel size of 0.16mm, and the gray scale was 12 bits. Romexis software (Planmeca, Helsinki, Finland) was used for analysis of the images (the observer was trained to use Romexis). The scans were displayed on an EA43FX VIAO laptop (Sony Corporation, Shanghai, China) with the screen resolution of 1366x768 pixels. For better visualization of soft tissue, the patients were asked to use plastic retractors in order to retract their lips and cheeks away from the gingival tissue before taking the scans (Fig. 1). The software provided frontal, axial and sagittal views of CBCT scans. After exploring the 3D model by an observer, the model was oriented in order to find the best orientation to generate a 2D image. The distances

were measured on 2D images using the measurement tool of the given software. By using the cross-sectional views taken from the midline of each maxillary anterior tooth (Fig. 2), measurement of facial bone and soft tissue thickness was performed at three different locations: At the crestal level and at 2 and 5mm apical to the crest and perpendicular to the inner cortical plate at the site of each tooth [14]. The cemento-enamel junction-to-crest distance was also recorded (Fig. 3). All the measurements were performed by a single calibrated examiner. The measurements were repeated on 15 randomly selected scans in order to estimate the intra-examiner reliability by calculating the intraclass correlation coefficient, which was found to be 0.7.



**Fig. 3:** The cross-sectional view of the tooth. Vertical line A indicates the long axis of the tooth. Horizontal lines B (white) from coronal to apical are: cemento-enamel junction, crestal level, 2mm apical to the crest and 5mm apical to the crest, respectively; Horizontal line C (gray) indicates buccal bone thickness; Horizontal line D (gray) indicates soft tissue thickness; Vertical line E (black) shows the cemento-enamel junction-crest distance

**Table 2:** The mean±standard deviation of hard and soft tissue thicknesses (mm) and cemento-enamel junction-crest distance (mm) in maxillary anterior teeth

Tooth type	Hard tissue thickness	Soft tissue thickness	Cemento-enamel junction-crest distance
Right canine	0.66±0.21	0.73±0.13	1.74±0.04
Right lateral	0.7±0.3	0.93±0.19	1.64±0.04
Right central	0.72±0.16	0.96±0.23	1.62±0.05
Left central	0.69±0.17	0.92±0.19	1.6±0.04
Left lateral	0.85±0.29	0.92±0.2	1.65±0.04
Left canine	0.67±0.21	0.77±0.18	1.73±0.05
P-value	0.0001	0.0001	0.601

For higher precision, thickness of hard and soft tissue was measured in three points (at the crest and at 2 and 5mm from the crest) of each tooth and the mean of the three values was recorded as thickness of hard and soft tissue for each tooth. Data analysis was done using Pearson's correlation coefficient to assess the correlation of hard and soft tissue thickness for each tooth. ANOVA was used to compare the thickness of hard tissue and soft tissue between different teeth. The  $\alpha$  and  $\beta$  values were set at 0.05 and 0.10, respectively.

## RESULTS

Results of data analysis in 330 anterior teeth of 60 eligible patients who required CBCT scans showed that in the right and left canines, there was a mild correlation ( $r=0.276$ ,  $P=0.282$ ) between soft tissue and the underlying bone. Similar results were obtained in the right and left central incisors ( $r=0.369$ ,  $P=0.332$ ) between soft tissue and the underlying bone. In the right and left lateral incisors, no such association was observed (Table 1).

There was a significant difference in the mean thickness of buccal bone in the studied teeth ( $P=0.0001$ ). The bone thickness of the lateral incisors was greater than that of central incisors and canines. Concerning soft tissue thickness, the result was the same ( $P=0.0001$ ) and the least thickness was observed in the right and left canines. No significant differences were found in cemento-enamel junction-crest distance between the maxillary anterior teeth ( $P>0.05$ , Table 2).

Buccal soft tissue thickness in the aforementioned locations was different between the maxillary anterior teeth, and the soft tissue thickness was the least in the right canine. Buccal bone thickness at 2 and 5mm below the crest differed between the maxillary anterior teeth and in the left lateral incisor, the mean thickness was more than in other areas (Table 3).

## DISCUSSION

The thickness of buccal bone and soft tissue and the correlation between them in the maxillary anterior region were evaluated in the present study. In 330 anterior teeth, the mean thickness of facial bone was  $0.73\pm0.23$ mm (range: 0.13-1.8mm) and the mean buccal soft tissue thickness was  $0.87\pm0.21$ mm (range: 0.40-1.7mm).

The mean cemento-enamel junction-crest distance was  $1.67\pm0.043$ mm (range: 0.8-2.1mm). All patients participating in this study had thin hard and soft tissues. The thickest buccal bone was found at 2mm below the crest.

The results of the present study with respect to the mean buccal bone thickness were consistent with those reported by Braut et al, [10] who measured the mean buccal bone thickness in the maxillary anterior teeth using CBCT, with the thicknesses in the central, lateral and canine areas at the crest being 0.47, 0.54 and 0.45mm, respectively.

Additionally, the results of the present study were consistent with those reported by Fu et al, [6] who evaluated buccal bone and soft tissue thickness in 22 cadavers using CBCT

**Table 3:** The mean± standard deviation of thickness of buccal soft and hard tissues (mm) in the selected locations in anterior maxillary teeth

Location	Buccal soft tissue			Buccal hard tissue		
	At the crest	2mm apical to the crest	5mm apical to the crest	At the crest	2mm apical to the crest	5mm apical to the crest
Right canine	0.82±0.22	0.67±0.16	0.71 ±0.28	0.49 ±0.17	0.85±0.31	0.66±0.35
Right lateral incisor	0.93±0.28	0.75±0.18	1±0.38	0.48±0.13	0.96±0.33	0.89±0.63
Right central incisor	1.02±0.23	0.86±0.23	1±0.48	0.52±0.13	0.87±0.26	0.77±0.3
Left central incisor	1±0.24	0.79±0.18	0.96±0.43	0.49±0.14	0.88±0.24	0.71±0.29
Left lateral incisor	0.95±0.29	0.75±0.18	1.06±0.39	0.45±0.14	1.05±0.35	1.05±0.63
Left canine	0.85±0.22	0.7±0.19	0.77±0.31	0.46±0.16	0.85±0.32	0.71±0.34

scans and showed the mean thickness to be 0.94mm and 0.57mm, respectively with moderate correlation between them ( $r=0.4$ ). Nevertheless, in the study by Fu et al, [6] criteria such as healthy periodontium of the examined teeth were not included. In the present study, a mild correlation was found between buccal hard and soft tissues in canines and central incisors; however, such association was not detected for the lateral incisors.

In a study by Ghassemian et al, [20] buccal bone thickness was measured on 66 CBCT scans. At 2mm apical to the crest, the buccal bone thickness was 1.39mm for canines, 1.28mm for the lateral incisors and 1.22mm for central incisors. In their study, the thickness of facial bone increased from the bone crest to the apical area whereas in the present study the thickest facial bone was detected at 2mm below the crest and then at 5mm apical to the crest and at the crest, respectively.

The reason for such finding might be the bone's tendency to become thin as a result of root convexity at the crest and possible fenestration in the apical region [14]. Variations in the reported measurements may also be related to racial disparities between the two different populations and their effect on soft tissue and facial bone thickness [1]. In this study, the least buccal bone and soft tissue thickness was observed in canines. Considering the canines' root form and prominence, this outcome was expected. Soft tissue CBCT was used in this study to

measure labial soft tissue and bone thickness. In this method, the soft tissues of the lips and cheeks were retracted and a dark space was created between the lip and the buccal gingiva. Otherwise, the above-mentioned tissues would collapse on the facial gingiva and clear visualization of the soft tissue would not be possible. Soft tissue CBCT is a simple and noninvasive method for visualization of periodontal structures [18]. High resolution, great precision in linear measurements and low radiation exposure are other advantages of this technique [20]. Fu et al, [6] reported no statistically significant differences between clinical and radiographic measurements of facial bone and soft tissue thickness. It seems that CBCT can be used as an objective method for labial bone and soft tissue assessments.

Measuring tissue dimensions at three different levels was one of the advantages of this study. Among these locations, the crestal position may be the most relevant since the crestal bone supports the gingival margin and if this bony structure resorbs, mucosal recession would ensue, contributing to esthetic problems. The bone covering the root consists of two layers of cortical bone (the outer cortical plate and the alveolar bone proper) separated by a layer of trabecular bone. If the buccal bone is very thin, the trabecular bone may be completely missing and it may solely be comprised of bundle bone. Bundle bone is a tooth-dependent structure, which is resorbed after tooth extraction [21,22].

The mean thickness of facial bone was 0.81mm in our study, which was the same as the value reported by Chappuis et al [23]. The thin buccal bone in the maxillary anterior teeth has been shown in several studies; therefore, an esthetic outcome may require adjunctive bone augmentation for most patients [24,25].

The characteristics of the soft tissue are determined by alveolar process dimensions, form, position and inclination of the teeth [22]. In this study, the facial bone and soft tissue thickness of sound natural teeth were evaluated. Patients with tooth mal-alignment, periodontitis and gingivitis were not included. Also, patients taking medications affecting periodontium, pregnancy and any condition, which could affect soft and hard tissue thickness were excluded [19,26].

Eliminating these confounding variables was a strength of the present study. Meanwhile, there were also some limitations due to too many inclusion and exclusion criteria, which not only complicated the sampling procedure due to the limited number of eligible subjects, but also decreased generalizability of the study results to the general population.

## CONCLUSION

The mean thickness of buccal bone and soft tissue in the anterior maxilla was <1mm and there was a mild linear association between them. The thinnest facial bone and soft tissue was detected in canine teeth.

## REFERENCES

- 1- Fu JH, Lee A, Wang HL. Influence of tissue biotype on implant esthetics. *Int J Oral Maxillofac Implants*. 2011 May-Jun;26(3):499-508.
- 2- Small PN, Tarnow DP, Cho SC. Gingival recession around wide-diameter versus standard-diameter implants: A 3- to 5-year longitudinal prospective study. *Pract Proced Aesthet Dent*. 2001 Mar;13(2):143-6.
- 3- Kao RT, Fagan MC, Conte GJ. Thick vs thin

gingival biotypes: A key determinant in treatment planning for dental implants. *J Calif Dent Assoc*. 2008 Mar;36(3):193-8.

- 4- Jung RE, Sailer I, Hammerle CH, Attin T, Schmidlin P. In vitro color changes of soft tissues caused by restorative materials. *Int J Periodontics Restorative Dent*. 2007 Jun;27(3):251-7.

- 5- Evans CD, Chen ST. Esthetic outcomes of immediate implant placements. *Clin Oral Implants Res*. 2008 Jan;19(1):73-80.

- 6- Fu JH, Yeh CY, Chan HL, Tatarakis N, Leong DJ, Wang HL. Tissue biotype and its relation to the underlying bone morphology. *J Periodontol*. 2010 Apr;81(4):569-74.

- 7- Claffey N, Shanley D. Relationship of gingival thickness and bleeding to loss of probing attachment in shallow sites following nonsurgical periodontal therapy. *J Clin Periodontol*. 1986 Aug;13(7):654-7.

- 8- Huang LH, Neiva RE, Wang HL. Factors affecting the outcomes of coronally advanced flap root coverage procedure. *J Periodontol*. 2005 Oct;76(10):1729-34.

- 9- Hwang D, Wang HL. Flap thickness as a predictor of root coverage: A systematic review. *J Periodontol*. 2006 Oct;77(10):1625-34.

- 10- Braut V, Bornstein MM, Belser U, Buser D. Thickness of the anterior maxillary facial bone wall- a retrospective radiographic study using cone-beam computed tomography. *Int J Periodontics Restorative Dent*. 2011 Apr;31(2):125-31.

- 11- Masaki C, Nakamoto T, Mukaibo T, Kondo Y, Hosokawa R. Strategies for alveolar ridge reconstruction and preservation for implant therapy. *J Prosthodont Res*. 2015 Oct;59(4):220-8.

- 12- Spray JR, Black CG, Morris HF, Ochi S. The influence of bone thickness on facial marginal bone response: stage 1 placement through stage 2 uncovering. *Ann Periodontol*. 2000 Dec;5(1):119-28.

- 13- Katranji A, Misch K, Wang HL. Cortical bone thickness in dentate and edentulous human cadavers. *J Periodontol*. 2007 May;78(5):874-8.

- 14- Nowzari H, Molayem S, Chiu CH, Rich SK. Cone-beam computed tomographic measurement of maxillary central incisors to determine prevalence of

- facial alveolar bone width  $\geq 2$  mm. *Clin Implant Dent Relat Res.* 2012 Aug;14(4):595-602.
- 15- Ronay V, Sahrman P, Bindl A, Attin T, Schmidlin PR. Current status and perspectives of mucogingival soft tissue management methods. *J Esthet Restor Dent.* 2011 Jun;23(3):146-56.
- 16- Barriviera M, Duarte WR, Januário AL, Faber J, Bezerra AC. A new method to assess and measure palatal masticatory mucosa by cone-beam computerized tomography. *J Clin Periodontol.* 2009 Jul;36(7):564-8.
- 17- Müller HP, Schaller N, Eger T, Heinecke A. Thickness of masticatory mucosa. *J Clin Periodontol.* 2000 Jun;27(6):431-6.
- 18- Januário AL, Barriviera M, Duarte WR. Soft tissue cone beam computed tomography: a novel method for the measurement of gingival tissue and the dimensions of the dentogingival unit. *J Esthet Restor Dent.* 2008;20(6):366-74.
- 19- Novac J. Classification of diseases and conditions affecting the periodontium. IN: Newman M, Takei H, Carranza F. *Carranza's clinical periodontology.* 10th ed., St. Louis, Saunders Elsevier, 2011:11.
- 20- Ghassemian M, Nowzari H, Lajolo C, Verdugo F, Pirroni TD, Addona A. The thickness of facial alveolar bone overlying healthy maxillary anterior teeth. *J Periodontol.* 2012 Feb;83(2):187-97.
- 21- Januário AL, Duarte WR, Barriviera M, Mesti JC, Araújo MG, Lindhe J. Dimension of the facial bone wall in the anterior maxilla: a cone-beam computed tomography. *Clin Oral Implants Res.* 2011 Oct;22(10):1168-71.
- 22- Lindhe J, Arajou M. The edentulous alveolar ridge. IN: Lindhe J, Lang N, Karring T. *Clinical periodontology and implant dentistry.* 5th ed., Oxford, Blackwell Publishing Ltd., 2008:53.
- 23- Chappuis V, Engel O, Reyes M, Shahim K, Nolte LP, Buser D. Ridge alterations post-extraction in the esthetic zone: a 3D analysis with CBCT. *J Dent Res.* 2013 Dec;92(12 Suppl):195S-201S.
- 24- Demircan S, Demircan E. Dental cone beam computed tomography analyses of the anterior maxillary bone thickness for immediate implant placement. *Implant Dent.* 2015 Dec;24(6):664-8.
- 25- Zekry A, Wang R, Chau AC, Lang NP. Facial alveolar bone wall width - a cone-beam computed tomography study in Asians. *Clin Oral Implants Res.* 2014 Feb;25(2):194-206.
- 26- De Rouck T, Eghbali R, Collys K, De Bruyn H, Cosyn J. The gingival biotype revisited: transparency of the periodontal probe through the gingival margin as a method to discriminate thin from thick gingival. *J Clin Periodontol.* 2009 May;36(5):428-33.