

Aggressive Therapy With Intravenous Abciximab and Intra-Arterial rtPA and Additional PTA/Stenting Improves Clinical Outcome in Acute Vertebrobasilar Occlusion

Combined Local Fibrinolysis and Intravenous Abciximab in Acute Vertebrobasilar Stroke Treatment (FAST)

Results of a Multicenter Study

Bernd Eckert, MD; Christoph Koch, MD; Götz Thomalla, MD; Thomas Kucinski, MD; Ulrich Grzyska, MD; Joachim Roether, MD; Karsten Alfke, MD; Olav Jansen, MD; Herrmann Zeumer, MD

Background and Purpose—A combined therapy of local recombinant tissue plasminogen activator (rtPA) fibrinolysis and intravenous Abciximab platelet inhibition with additional percutaneous transluminal angioplasty (PTA)/stenting may improve recanalization and neurological outcome in patients with acute vertebrobasilar occlusion.

Methods Combined FAST therapy consisted on intravenous bolus of Abciximab (0.25 mg/kg) followed by a 12-hour infusion therapy (0.125 μ g/kg per minute) and low-dose intra-arterial rtPA (median dosage: 20 mg, FAST cohort: N=47). The results were compared with a retrospective cohort, treated by intraarterial rtPA monotherapy (median dosage: 40 mg, rtPA cohort, N=41). Additional PTA/stenting was performed in case of severe residual stenosis. Recanalization success was classified according to the Trials in Myocardial Infarction (TIMI) criteria: TIMI0/1, failed recanalization; TIMI2/3, successful recanalization. Bleeding complications were evaluated according to severe extracerebral hemorrhage (ECH), asymptomatic intracerebral hemorrhage (AIH), and symptomatic intracerebral hemorrhage (SIH).

Results—Overall bleeding rate was higher under the combined therapy, but the SIH rate did not differ (FAST versus rtPA: ECH, 3% versus 0%; AIH, 32% versus 22%; SIH 13% versus 12%). Additional PTA/stenting was performed in 14 (FAST) versus 5 (rtPA) patients. TIMI2/3 recanalization rate was similar (FAST, 72%; rtPA, 68%), but TIMI3 rate was remarkably higher under combined therapy (FAST, 45%; rtPA, N=22%). Neurologic outcome appeared better under combined therapy (FAST versus rtPA: favorable outcome rate: 34% versus 17%) with a significantly lower mortality rate (FAST versus rtPA: 38% versus 68%; $P=0.006$). These results were consistent for embolic and atherothrombotic occlusions.

Conclusion—Combined therapy of intravenous Abciximab and half dose intra-arterial rtPA with additional PTA/stenting appears to improve neurologic outcome in acute vertebrobasilar occlusion despite an increase of overall bleeding complications. (*Stroke*. 2005;36:1160-1165.)

Key Words: stents ■ stroke, ischemic ■ thrombolysis

Stroke caused by angiographically documented acute vertebrobasilar occlusion (VBO) is a dramatic clinical event with a mortality rate approaching 90% if patients are treated by standard medical therapy including anticoagulation agents.^{1,2} Even under endovascular rescue therapy by means of local intra-arterial fibrinolysis (LIF), the mortality remains $\approx 60\%$.^{3,4}

Platelet glycoprotein (GP) IIb/IIIa receptor inhibitors such as Abciximab induce a rapid and effective inhibition of platelet aggregation. Adjunctive Abciximab application might improve

the rate and extent of intraarterial fibrinolysis in acute stroke through thrombolysis of the platelet thrombus and by preventing rethrombosis. GP IIb/IIIa receptor inhibitors have been reported to preserve microvascular patency in animal stroke studies and may have neuroprotective properties.⁵ In the cerebral circulation, successful adjunctive Abciximab therapy after failed intra-arterial fibrinolysis has been described as rescue treatment in rare cases of basilar artery re-thrombosis⁶ and acute middle cerebral artery stroke.⁷

Received December 20, 2004; final revision received January 28, 2005; accepted February 14, 2005.

From the Department of Neuroradiology (B.E., T.K., U.G., H.Z.), Department of Neurology (G.T., J.R.), University Hospital Hamburg-Eppendorf; the Department of Neuroradiology (C.K.), University Hospital Lübeck; and the Department of Neuroradiology (K.A., O.J.), University Hospital Kiel.

Correspondence to Bernd Eckert, MD, Allgemeines Krankenhaus Altona, Neuroradiologie, Paul-Ehrlich-Str. 1 D-22763 Hamburg, Germany. E-mail bernd.eckert@ak-altona.lbk-hh.de

© 2005 American Heart Association, Inc.

Stroke is available at <http://www.strokeaha.org>

DOI: 10.1161/01.STR.0000165918.80812.1e

Additional percutaneous transluminal angioplasty (PTA)/stenting of the underlying stenosis in atherothrombotic occlusions is another invariant treatment factor in acute VBO. A VBO data analysis⁴ suggested a positive effect of immediate additional PTA in case of severe residual stenosis after LIF. In 2001 the present research group changed its treatment philosophy in acute VBO. All patients were treated with combined intravenous Abciximab and intra-arterial recombinant tissue plasminogen activator (rtPA) according to the FAST protocol (FAST cohort).⁸ In case of severe residual stenosis after LIF, additional PTA/stenting was performed. The aim of the present study was to evaluate the safety and efficacy of this aggressive approach in comparison to a retrospective cohort treated with intra-arterial rtPA monotherapy⁴ (rtPA cohort).

Subjects and Methods

Preprocedural Management

CT scan and CT angiography were performed in all patients before treatment to exclude intracranial hemorrhage or a severe brain stem infarct and to confirm the clinical diagnosis of a vertebrobasilar occlusion.

Inclusion Criteria

Acute brain stem symptoms with evidence of intracranial VBO (including bilateral distal occlusion of the vertebral arteries) in CT angiography or catheter angiography. To be eligible for treatment, at least brain stem reflexes still had to be present before intubation.

Exclusion Criteria

Any kind of intracranial hemorrhage or the detection of a brain stem infarct were considered a contraindication for treatment. The CT evidence of minor ischemic lesions in the cerebellum or in the territory of the posterior cerebral artery did not lead to exclusion from treatment.

If possible, informed consent was obtained before treatment. If the patients were not able to give informed consent, they were treated in line with a compassionate treatment policy that had been approved by the local ethic committee.

FAST Cohort

Between April 2001 and December 2003, 47 consecutive patients with angiographically established intracranial VBO were treated (University Hospital Hamburg, N=36; University Hospital of Luebeck, N=8; and University Hospital of Kiel, N=3). Clinical examination was performed by a stroke neurologist before intubation and included scoring according to the modified Rankin Scale (mRS) and National Institute of Health Stroke Scale (NIHSS).

Procedural FAST Treatment

Intravenous Abciximab and intra-arterial rtPA was administered according to the FAST protocol published elsewhere.^{8,9} If VBO was verified by catheter angiography, the intravenous Abciximab therapy was initiated (bolus of 0.25 mg/kg body weight) followed by an infusion of 0.125 μ g/kg per body weight per minute and maintained for 12 hours. If VBO was diagnosed by CT angiography, Abciximab therapy was begun before angiography as a "bridging therapy." The rtPA was administered through the microcatheter at the site of occlusion for a maximum of 2 hours or until recanalization was established. The dosage was 10 to 20 mg per hour.

Endovascular procedure was performed according to the protocol, described elsewhere.⁹ The rtPA was administered through the microcatheter at the site of occlusion. Angiographic control series were performed at 15 minute intervals. Heparin was only used for catheter-flushing (500 IE per hour) with a maximum of 2000 IE.

PTA and Stenting

Patients with atherothrombotic occlusions (AO) who revealed major (>70%) residual stenosis after local fibrinolysis were treated with additional PTA/stenting. The prerequisite to perform PTA/stenting was complete recanalization of local thrombosis and of secondary embolism in the basilaris tip, if present. At a first step, the microcatheter was placed beyond the stenosis and a long guide wire was navigated into the distal posterior cerebral artery (0.014-inch Choice PT, 300-cm; Boston Scientific). The microcatheter was then removed and the guide wire was kept in position during the following procedure. In case of tight stenosis, predilatation was performed with a 2- to 2.5-mm balloon catheter (Omni Pass, Cordis Europa NV, or Maverick, Boston Scientific Scimed) with a pressure of 6 atm. Maintaining the position of the guide wire, the balloon catheter was removed and an INX Stent (3 mm to 3.5 mm; Medtronic AVE) was inserted and released by inflation of the underlying balloon with 6 atm. In cases of less severe stenosis, the stenting was performed without predilatation.

Postprocedural Management

After local rtPA treatment, the patients were referred to the neurological intensive care unit with remnant sheath at the femoral puncture site. Blood samples were taken to evaluate the coagulation parameters including the thrombocyte count at 2 and 24 hours after Abciximab bolus administration. The sheath was removed when the first coagulation control proved normal. A control CT scan was performed at 1 and 4 days after therapy to rule out hemorrhage and monitor the extent of infarction. Postprocedural anticoagulation started 24 hours after the end of the Abciximab infusion and consisted of prophylactic Enoxaparin-Natrium (1 \times 20 mg/d to 1 \times 40 mg/d during immobilization) and acetyl salicyl acid (ASA) (100 mg) as permanent therapy. In case of additional PTA/stenting, the patients were treated with an increased dosage of Enoxaparin-Natrium (2 \times 40 mg for 3 days), ASA (100 mg), and Clopidogrel (75 mg/d). The combination of ASA and clopidogrel was maintained for 4 weeks. Thereafter, all patients received a permanent ASA or clopidogrel therapy.

rtPA Cohort

The data of these patients were taken from a recently published report summarizing our results in 83 patients between 1989 and 1999 treated with different fibrinolytic agents (urokinase, rtPA, rtPA with plasminogen).⁴ We included those patients treated with rtPA (N=41). The clinical and radiological inclusion and exclusion criteria, as well as the procedural rtPA application modes, were identical to the present FAST cohort.

Treatment Factor Analysis: Clinical Follow-up

In the FAST cohort, clinical outcome was evaluated at 3 months by an experienced stroke neurologist using the mRS. The patient or next of kin was interviewed using a structured interview. In the retrospective rtPA cohort, the outcome was evaluated according to the study results⁴ using the mRS. Neurological outcome was categorized as favorable (mRS \leq 3, no or mild to moderate disability), unfavorable (mRS 4 to 5, severe disability), or death (mRS=6).

Type of Occlusion

The occlusion site were stratified in lower third (including vertebrobasilar junction), middle third, and distal third of the basilar artery ("top of the basilar"). Similar to previous studies,^{2,4,10} the types of occlusion were classified as either embolic occlusion (distal third of the basilar artery (BA), no atherosclerotic disease in adjacent vessels) or AO (2 proximal basilar segments, evidence of underlying stenosis and atherosclerotic disease). Stenosis of the extracranial proximal VA associated with secondary basilar tip embolism was classified as embolic occlusion.

Recanalization

Recanalization success was classified according to criteria of the Trials in Myocardial Infarction (TIMI)¹¹ as follows: TIMIO, com-

TABLE 1. Neurologic Outcome and Bleeding Rate Related to FAST and rtPA Treatment and Type of Occlusion

Diagnostic or Treatment Variables	FAST Cohort			rtPA Cohort		
	Basilar Embolism (%)	Atherothrombosis (%)	All (%)	Basilar Embolism (%)	Atherothrombosis (%)	All (%)
No.	28	19	47	16	25	41
Favorable outcome mRS 0–3	10 (36)	6 (32)	16 (34)	2 (13)	5 (20)	7 (17)
Unfavorable outcome mRS >3	5 (18)	8 (42)	13 (28)	3 (19)	3 (12)	6 (15)
Death	13 (46)	5 (26)	18 (38)	11 (69)	17 (68)	28 (68)
Asymptomatic intracerebral bleeding	8 (29)	7 (37)	15 (32)	6 (38)	3 (12)	9 (22)
Symptomatic intracerebral bleeding	3 (11)	3 (16)	6 (13)	2 (13)	3 (12)	5 (12)

plete occlusion of the BA; TIMI1, partial recanalization but remnant occlusion of the BA; TIMI2, incomplete recanalization with continuous BA patency but remnant thrombus; TIMI3, complete recanalization. TIMI0 and TIMI1 were classified as recanalization failure; TIMI2 and TIMI3 were defined as recanalization.

Bleeding Complications

Extracerebral bleeding complications were classified as severe if additional therapy (ie, blood transfusion or intervention) was required. Intracranial hemorrhage was defined as symptomatic intracranial hemorrhage (SIH), if there was evidence of clinical deterioration (>4 according to National Institutes of Health Stroke Scale [NIHSS]) associated with evidence of bleeding on cranial computed tomography. In intubated patients with nondefinable neurologic status, intracranial bleeding was defined as SIH according to radiologic criteria: parenchymal hematoma with mass effect or subarachnoid hemorrhage (SAH) with hydrocephalus.

Intracranial bleeding was defined as AIH if clinical deterioration or radiological criteria were absent. AIH included hemorrhagic infarct transformation, SAH, or intraventricular hemorrhage without hydrocephalus and small asymptomatic PH distant from the infarct

Time to Treatment

The time to treatment was defined as the interval between the onset of brain stem symptoms and the beginning of local rtPA fibrinolysis. In cases of nonspecific preceding symptoms such as vertigo and nausea, only the development of pronounced brain stem symptoms was defined as symptom onset. In the FAST cohort, the time to Abciximab therapy was additionally evaluated.

Data Analysis

Analysis included recanalization rate, survival and neurological outcome, intracranial bleeding related to type of treatment (FAST versus RTPA), and type of occlusion (atherothrombotic versus embolic). Time to rtPA treatment and rtPA dosage were also

evaluated. Statistical analysis of survival were calculated by Fisher exact test (exact *P* values).

Results

Clinical Outcome

Clinical outcome is summarized in Table 1.

FAST Cohort

Forty-seven cases (17 female, 30 male, age 31 to 84 years, mean 69 years) were evaluated. Clinical data on admission were as follows: mean mRS, 4.9; median mRS, 5; and mean NIHSS, 26.8. Clinical follow-up after 3 months according to mRS were as follows: mRS1, N=3; mRS2, N=8; mRS3, N=5; mRS4, N=3; mRS5, N=10; mRS6, N=18.

rtPA Cohort

Forty-one cases (7 female, 34 male, age 28 to 79 years, mean 61 years) were evaluated. Clinical data according to the mRS and NIHSS scoring system on admission was not assessed.

Bleeding Complications

Bleeding complications are summarized in Tables 1 and 2.

FAST Cohort

A thrombocytopenia with platelet counts <100 000 did not occur. Severe extracerebral hemorrhage requiring additional therapy occurred in 3 (6%) patients. One gastrointestinal bleeding occurred during treatment and required endoscopic intervention (endoscopy revealed Mallory–Weiss syndrome). One maxillary sinus hemorrhage required urgent intervention

TABLE 2. Recanalization Rate and PTA/Stenting Related to FAST and rtPA Cohort and Occlusion

Recanalization Success	FAST Cohort			rtPA Cohort		
	Basilar Embolism (%)	Atherothrombosis (%)	All (%)	Basilar Embolism (%)	Atherothrombosis (%)	All (%)
No.	28	19	47	16	25	41
TIMI 2/3	20 (71)	14 (74)	34 (72)	11 (69)	17 (68)	28 (68)
TIMI 2	12 (43)	1 (5)	13 (28)	7 (44)	12 (48)	19 (46)
TIMI 3	8 (29)	13 (68)	21 (45)	4 (25)	5 (20)	9 (22)
PTA/Stenting (No.)		15	15		5	5

TIMI2: partial recanalization; TIMI3: complete recanalization.

with tamponade and tracheotomy; and there was one case of diffuse bleeding from multiple puncture sites after treatment requiring blood transfusion. All 3 patients recovered.

Intracranial Hemorrhage

CT or MR evaluation of all patients revealed intracranial hemorrhage in 21 patients (43%). Asymptomatic intracranial hemorrhage (AIH) was seen in 15 patients. The bleeding types were as follows: hemorrhagic infarct transformation, N=6; SAH, N=2; HT with SAH, N=4; intraventricular hemorrhage, N=1; distant parenchymal hematoma, N=2. SIH occurred in 6 patients all of whom died. In 2 of these patients, SIH was induced by technical complications. In one patient PTA/stenting of a severe calcified 80% intracranial VA stenosis resulted in vessel wall dissection with fatal SAH. In another patient with proximal high-grade VA stenosis with huge adherent thrombus and secondary basilar embolism, guide wire navigation (without "roadmap" conditions) after Abciximab application resulted in vessel wall dissection and SAH. In 2 patients, SIH was associated with late treatment onset (>13 hours).

rtPA Cohort

Severe extracerebral hemorrhage requiring intervention or blood transfusion did not occur. CT or MR evaluation of all patients revealed intracranial hemorrhage in 14 patients (32%). Symptomatic intracerebral hemorrhage occurred in 5 patients, all of whom died. One patient was treated with 20 mg rtPA, the remaining 5 patients were treated with 40 to 80 mg rtPA (mean rtPA dosage: 48 mg). Time to treatment was prolonged in 2 patients (13 hours and 14 hours, respectively).

Asymptomatic intracerebral hemorrhage was seen in 9 patients. Hemorrhagic infarct transformation was detected in 8 patients. In one patient, a guide wire perforation led to a perimesencephalic SAH without hydrocephalus.

Occlusion Type

Recanalization according to type of occlusion is summarized in Table 2.

FAST Cohort

Fifteen (79%) of the 19 patients with AO were treated by additional PTA/stenting. The reason for omitting PTA/stenting in the 4 patients were: residual secondary embolus in the basilaris tip in 2 cases, one epistaxis requiring urgent intervention, and a technically inaccessible stenosis.

rtPA Cohort

In the late treatment period after 1997, 5 (20%) of the 25 patients with AO and severe residual stenosis after LIF were treated by additional PTA without stenting.

Time to Treatment

In the FAST cohort, average time to rtPA therapy was 361 ± 149 minutes (range, 202 to 850 minutes; median, 330 minutes). According to the protocol the Abciximab therapy was initiated before local fibrinolysis. The time to Abciximab bolus administration was 308 ± 144 minutes (range, 120 to 780 minutes).

In the rtPA cohort, average time to rtPA therapy was 496 ± 196 minutes (range, 180 to 1080 minutes; median, 480 minutes).

Dosage of rtPA

In the FAST cohort, mean rtPA dosage was 29 ± 14 mg (range, 7.5 to 80 mg; median, 20 mg). In the first phase of the study, the rtPA dosage was 10 mg/h (N=7). Starting December 2001, the dosage was increased to 20 mg/h. Four patients with early treatment onset and persistent occlusion after application of 40 mg rtPA received additional rtPA in another 30 minutes to 1 hour but within 6 hours after symptom onset as a last resort therapy. In 3 of these patients, asymptomatic intracranial bleeding occurred. Two other patients with technically inaccessible occlusions were treated by intravenous rtPA application (40 mg and 20 mg rtPA, respectively). In the one patient with SAH caused by guide wire perforation, as described, rtPA was not administered.

In the rtPA cohort, 10 to 20 mg rtPA was applied in 17 patients: 30 to 80 mg rtPA was given in 24 patients. Mean rtPA dosage was 46 ± 26 mg (range, 18 to 80 mg; median, 40 mg).

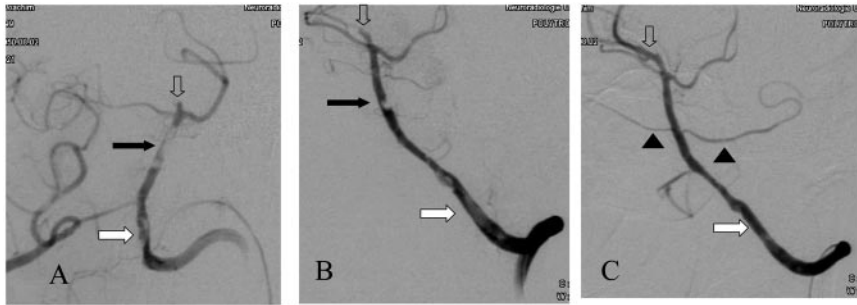
Discussion

The diagnosis of acute VBO is always life-threatening and demands immediate treatment. The etiology and treatment conditions vary considerably (eg, embolic versus atherothrombotic occlusion, extent of occlusion and collateral pathways, time to treatment, clinical conditions). Since the implementation of LIF,¹² a wide consensus has developed among clinicians that patients with acute VBO should be treated by this approach, if available. Beside accurate angiographic diagnosis, the intra-arterial approach offers mechanical options like PTA/stenting or other catheter devices for thrombus extraction.^{13,14} In case of considerable treatment delay for endovascular therapy, intravenous thrombolysis may be an appropriate alternative.¹⁵

Placebo-controlled randomized trials cannot be proposed in acute VBO. In such dramatic clinical situations urging "best possible treatment," the implementation of randomized trials will remain an ethical problem. The scientific option at hand to evaluate new endovascular treatment strategies is the implementation of a prospective trial and comparison with a retrospective study cohort treated under comparable conditions by means of LIF.

With LIF, recanalization rates in acute vertebrobasilar occlusion do not exceed 70% and mortality rates remain at $\approx 60\%$.^{3,4} Increasing the dosage of plasminogen activators has not improved clinical and angiographic results.⁴ The aim of the present study was to find out if an aggressive therapy with adjunctive application of GP IIb/IIIa inhibitor and additional PTA/stenting speeds up recanalization and improves clinical outcome.

Compared with a retrospective cohort (rtPA), the combined therapy (FAST) showed a trend toward improved neurological outcome (FAST versus rtPA: favorable outcome rate 34% versus 17%). The mortality rate was significantly lower (FAST versus rtPA: 38% versus 68%; $P=0.006$). The clinical benefit of the combined FAST treatment mode might be explained 3 ways.



stenosis. B, 20 minutes after intravenous Abciximab application. Effective partial recanalization of the large basilar thrombus, persistent bilateral AICA occlusion. Residual thrombus in the left VA and in PCA. Local rtPA fibrinolysis was started with 20 mg/h. C, 1 hour after local rtPA therapy. Complete recanalization in the BA, the PCA, and the left VA. Both AICA are reperfused (arrow heads). Proximal left VA stenosis was treated by PTA afterward. The patient recovered completely (3-month follow-up: NIHSS, 2; mRS, 1).

Sequential thrombolysis with intravenous Abciximab and intra-arterial rtPA. Angiographic depiction (AP and oblique views) via left vertebral artery (VA). A, Before therapy, 160 minutes after sudden onset of bulbar symptoms, asymmetric tetraparesis, and disturbed vigilance (NIHSS, 16; mRS, 5): Evidence of embolism in the distal left VA (white arrow), in the basilar artery (black arrow) with bilateral occlusions of the anterior inferior cerebellar arteries (AICA), and in the posterior cerebral artery (PCA, open arrows) caused by arterioarterial embolism of proximal left VA

First, FAST treatment leads to a more effective recanalization. Even though the overall TIMI2/TIMI3 recanalization rate did not differ between FAST and rtPA (72% versus 68%), the rate of complete TIMI3 recanalization was remarkably higher in the FAST therapy (45% versus 22%). One major reason is the higher rate of additional PTA/stenting in the FAST cohort in patients with atherothrombotic occlusions. In embolic occlusions without additional PTA/stenting, there was also a clear clinical benefit from the combined treatment despite only a small improvement of TIMI3 flow. In cases of incomplete recanalization, we hypothesize a more rapid complete recanalization in adjunctive Abciximab therapy because of facilitation of intrinsic fibrinolysis and rethrombosis protection. Additionally, Abciximab may have an intrinsic recanalizing effect like in the documented case (Figure 1) and reported in other studies.^{6,7}

Second, the combined therapy is effective in preventing reocclusion. Subsequent transcranial Doppler monitoring during intravenous thrombolysis has demonstrated that arterial reocclusion is a major contributor to secondary clinical deterioration.¹⁶ In a recent report on LIF, a reocclusion rate of 17% was documented during the intervention.¹⁷ The desired increase of plasmin induced by plasminogen activators such as rtPA also affects an increase of thrombin¹⁸ with subsequent platelet activation. PTA/stenting with disruption of atherosclerotic plaque and endothelial erosion is another mechanism that triggers platelet activation.¹⁸ Abciximab impedes platelet aggregation and inhibits platelet induced thrombin generation with subsequent reduction of platelet counter-regulatory granule secretion of native tPA inhibitor 1 and $\alpha 2$ -anti-plasmin.¹⁹

Third, the combined treatment may improve the microvascularization. An improvement of microvascular perfusion by GP IIb/IIIa inhibitors has been demonstrated in animal studies.⁵ In a recent animal study combined treatment with the monoclonal antibody 7E3 (Fab fragment of Abciximab) and rtPA significantly reduced infarct volume and increased microvessel perfusion.²⁰

In the FAST cohort, the overall bleeding rate was higher than in rtPA monotherapy. Severe extracerebral hemorrhage requiring immediate intervention occurred in 3 patients after FAST treatment and was not observed in the rtPA cohort. The rate of asymptomatic intracerebral bleeding was also higher

in the FAST cohort. This increased incidence of AIH was mainly caused by a higher rate of SAH, which occurred in 6 patients in the FAST cohort but in only 1 patient in the rtPA cohort. The rate of symptomatic intracranial hemorrhages with clinical deterioration, however, did not differ. Two SIH in the FAST cohort were technically induced. In the rtPA cohort, guide wire perforation only led to one asymptomatic small perimesencephalic hemorrhage. Mechanical vessel wall alterations may bear a higher risk of major SAH consequences in case of combined FAST treatment.

Tirofiban and Eptifibatid are further GP IIb/IIIa receptor antagonist agents. Successful therapy with intravenous rtPA and intravenous Tirofiban based on MR angiography has been reported in basilar artery occlusion²¹ and in middle cerebral artery occlusion.²² Further study is necessary to evaluate the optimal application mode and type of adjunctive GP IIb/IIIa treatment. In case of treatment delay, a "bridging" therapy with intravenous GP IIb/IIIa until further endovascular treatment might be an alternative to intravenous thrombolysis.

The main limitation of the present study is the restricted methodical comparability of the 2 study cohorts, with one being prospective and the other retrospective. The higher rate of additional PTA/stenting and the earlier treatment in the FAST cohort are 2 important factors that probably favored the results of the FAST cohort.

In conclusion, the combination therapy of intra-arterial low-dose rtPA and adjunctive intravenous Abciximab with additional PTA/stenting is a feasible concept to improve recanalization and clinical outcome in patients with acute VBO. This aggressive approach, however, bears an increased risk of extracerebral and intracerebral bleeding complications, thus requiring careful endovascular catheterization and intensive postinterventional care. In cases of late treatment onset (>6 hours after symptom onset), the increased bleeding risk might even outweigh the clinical benefit. Further study of the type and application form of adjunctive GP IIb/IIIa and its combination with mechanical endovascular stroke devices is warranted.

Acknowledgments

We thank Dr Jarold Knispel, Hamburg, for his language advice.

References

1. Kubik CS, Adams RD. Occlusion of the basilar artery—a clinical and pathological study. *Brain*. 1946;69:73–121.
2. Hacke W, Zeumer H, Ferbert A, Bruckmann H, del Zoppo GJ. Intra-arterial thrombolytic therapy improves outcome in patients with acute vertebrobasilar occlusive disease. *Stroke*. 1988;19:1216–1222.
3. Levy EI, Firlik AD, Wisniewski S, Rubin G, Jungreis CA, Wechsler LR, Yonas H. Factors affecting survival rates for acute vertebrobasilar artery occlusions treated with intra-arterial thrombolytic therapy: a meta-analytical approach. *Neurosurgery*. 1999;45:539–545.
4. Eckert B, Kucinski T, Pfeiffer G, Groden C, Zeumer H. Endovascular therapy of acute vertebrobasilar occlusion: early treatment onset as the most important factor. *Cerebrovasc Dis*. 2002;14:42–50.
5. Choudri TF, Hoh BL, Zerwes H-G, et al. Reduced microvascular thrombosis and improved outcome in acute murine stroke by inhibiting GP IIb/IIIa receptor-mediated platelet aggregation. *J Clin Invest*. 1998;102:1301–1310.
6. Wallace RC, Furlan AJ, Moliterno DJ, Stevens GH, Masaryk TJ, Perl J. Basilar artery rethrombosis: successful treatment with platelet glycoprotein IIb/IIIa receptor inhibitor. *AJNR Am J Neuroradiol*. 1997;18:1257–1260.
7. Lee KY, Heo JH, Lee SI, Yoon PH. Rescue treatment with abciximab in acute ischemic stroke. *Neurology*. 2001;56:1585–1587.
8. Eckert B, Kucinski T, Wittkugel O, Roether J, Solymosi L, Gödicke J, Zeumer H. Combined local fibrinolysis and intravenous abciximab in acute stroke treatment: FAST-studie, hintergrund und design. *Klinische Neuroradiologie*. 2002;12:127–135.
9. Eckert B, Koch C, Thomalla G, Roether J, Zeumer H. Acute basilar artery occlusion treated with combined intravenous abciximab and intra-arterial tissue plasminogen activator: Report of 3 cases. *Stroke*. 2002;33:1424–1427.
10. Archer CR, Horenstein S. Basilar artery occlusion. Clinical and radiological correlation. *Stroke*. 1977;8:383–390.
11. TIMI. The thrombolysis in myocardial infarction (TIMI) trial. Phase I findings. TIMI study group. *N Engl J Med*. 1985;312:932–936.
12. Zeumer H, Hacke W, Kolmann HL, Poeck K. Lokale Fibrinolyse-therapie bei Basilaristhrombose. *Dtsch Med Wschr*. 1982;107:728–731.
13. Bellon RJ, Putman CM, Budzik RF, Pergolizzi RS, Reinking GF, Norbash AM. Rheolytic thrombectomy of the occluded internal carotid artery in the setting of acute ischemic stroke. *AJNR Am J Neuroradiol*. 2001;22:526–530.
14. Pierre Gobin Y, Starkman S, Duckwiler GR, Grobelny T, Kidwell CS, Jahan R, Pile-Spellman J, Segal A, Vinuela F, Saver JL. Merci 1: a phase I study of mechanical embolus removal in cerebral ischemia. *Stroke*. 2004;35:2848–2854.
15. Lindsberg PJ, Soenne L, Tatlisumak T, Roine RO, Kallela M, Happpola O, Kaste M. Long-term outcome after intravenous thrombolysis of basilar artery occlusion. *JAMA*. 2004;292:1862–1866.
16. Burgin WS, Alexandrov AV. Deterioration following improvement with tpa therapy: carotid thrombosis and reocclusion. *Neurology*. 2001;56:568–570.
17. Qureshi AI, Siddiqui AM, Kim SH, Hanel RA, Xavier AR, Kirmani JF, Suri MF, Boulos AS, Hopkins LN. Reocclusion of recanalized arteries during intra-arterial thrombolysis for acute ischemic stroke. *AJNR Am J Neuroradiol*. 2004;25:322–328.
18. Becker R. Dynamics of coronary thrombolysis and reocclusion. *Clin Cardiol*. 1997;20:III2–III5.
19. Zhu Y, Carmeliet P, Fay WP. Plasminogen activator inhibitor-1 is a major determinant of arterial thrombolysis resistance. *Circulation*. 1999;99:3050–3055.
20. Zhang L, Zhang ZG, Zhang R, Morris D, Lu M, Collier BS, Chopp M. Adjuvant treatment with a glycoprotein IIb/IIIa receptor inhibitor increases the therapeutic window for low-dose tissue plasminogen activator administration in a rat model of embolic stroke. *Circulation*. 2003;107:2837–2843.
21. Junghans U, Seitz RJ, Wittsack HJ, Aulich A, Siebler M. Treatment of acute basilar artery thrombosis with a combination of systemic alteplase and tirofiban, a nonpeptide platelet glycoprotein IIb/IIIa inhibitor: report of four cases. *Radiology*. 2001;221:795–801.
22. Straub S, Junghans U, Jovanovic V, Wittsack HJ, Seitz RJ, Siebler M. Systemic thrombolysis with recombinant tissue plasminogen activator and tirofiban in acute middle cerebral artery occlusion. *Stroke*. 2004;35:705–709.

Aggressive Therapy With Intravenous Abciximab and Intra-Arterial rtPA and Additional PTA/Stenting Improves Clinical Outcome in Acute Vertebrobasilar Occlusion: Combined Local Fibrinolysis and Intravenous Abciximab in Acute Vertebrobasilar Stroke Treatment (FAST): Results of a Multicenter Study

Bernd Eckert, Christoph Koch, Götz Thomalla, Thomas Kucinski, Ulrich Grzyska, Joachim Roether, Karsten Alfke, Olav Jansen and Herrmann Zeumer

Stroke. 2005;36:1160-1165; originally published online May 12, 2005;

doi: 10.1161/01.STR.0000165918.80812.1e

Stroke is published by the American Heart Association, 7272 Greenville Avenue, Dallas, TX 75231

Copyright © 2005 American Heart Association, Inc. All rights reserved.

Print ISSN: 0039-2499. Online ISSN: 1524-4628

The online version of this article, along with updated information and services, is located on the World Wide Web at:

<http://stroke.ahajournals.org/content/36/6/1160>

Permissions: Requests for permissions to reproduce figures, tables, or portions of articles originally published in *Stroke* can be obtained via RightsLink, a service of the Copyright Clearance Center, not the Editorial Office. Once the online version of the published article for which permission is being requested is located, click Request Permissions in the middle column of the Web page under Services. Further information about this process is available in the [Permissions and Rights Question and Answer](#) document.

Reprints: Information about reprints can be found online at:
<http://www.lww.com/reprints>

Subscriptions: Information about subscribing to *Stroke* is online at:
<http://stroke.ahajournals.org/subscriptions/>