

# Conventional multiple or microdissection testicular sperm extraction: a comparative study

A.Tsujimura<sup>1</sup>, K.Matsumiya<sup>1,4</sup>, Y.Miyagawa<sup>1</sup>, A.Tohda<sup>1</sup>, H.Miura<sup>1</sup>, K.Nishimura<sup>1</sup>, M.Koga<sup>2</sup>, M.Takeyama<sup>2</sup>, H.Fujioka<sup>3</sup> and A.Okuyama<sup>1</sup>

<sup>1</sup>Departments of Urology, Osaka University Graduate School of Medicine, 2-2 Yamadaoka, Suita, 565-0871, <sup>2</sup>Osaka Central Hospital, Osaka, 530-0001 and <sup>3</sup>Osaka Police Hospital, Osaka, 543-8502, Japan

<sup>4</sup>To whom correspondence should be addressed. E-mail: matsumiya@uro.med.osaka-u.ac.jp

**BACKGROUND:** Testicular sperm extraction (TESE) with ICSI is becoming the first-line treatment for non-obstructive azoospermia (NOA). Recently, the sperm retrieval rate (SRR) by microdissection TESE was reported to be higher than by conventional TESE. However, a comprehensive comparison between multiple and microdissection TESE patients including histological findings has not been reported. **METHODS:** Patients with NOA who underwent microdissection TESE ( $n = 56$ ) or multiple TESE ( $n = 37$ ) were compared. Pre-operative characteristics were similar between groups. In addition, microscopic findings during microdissection TESE also were investigated. **RESULTS:** Operative time was significantly longer for microdissection TESE than for multiple TESE. Histological examination suggested that spermatogenesis was relatively more impaired in the microdissection TESE group than in the multiple TESE group. Despite this, SRR by microdissection TESE (42.9%) appeared higher than by conventional TESE (35.1%) although this observation failed to reach statistical significance. Seventeen of 26 patients (65.4%) with heterogeneous tubule were successful for sperm retrieval. No severe operative complications occurred in any patient in either group, and no patient required post-operative hormone replacement to treat hypogonadism. **CONCLUSIONS:** Microsurgical technique is safe and may improve SRR for TESE in a variety of patients with NOA, especially patients with heterogeneous testicular tubules.

*Key words:* histopathology/multiple testicular sperm extraction/non-obstructive azoospermia/spermatogenesis/testicular sperm extraction

## Introduction

Testicular sperm extraction (TESE) for ICSI was first introduced for treatment of obstructive azoospermia in 1993 (Craft *et al.*, 1993; Schoysman *et al.*, 1993). Soon afterwards, testicular sperm were retrieved successfully and used in ICSI in cases of non-obstructive azoospermia (NOA) (Devroey *et al.*, 1995; Silber *et al.*, 1995a,b,c, 1996; Mansour *et al.*, 1996). TESE combined with ICSI is now becoming the first-line treatment in NOA. Open testicular biopsy appears to be more effective than needle biopsy for retrieval of testicular sperm in azoospermic men (Friedler *et al.*, 1997; Ezech *et al.*, 1998; Friedler, 1998; Rosenlund *et al.*, 1998). Multiple TESE is still a more effective procedure for sperm retrieval in patients with NOA, since the testis in these patients is known to be heterogeneous (Tournaye *et al.*, 1995; Hauser *et al.*, 1998; Ostad *et al.*, 1998). Very recently, a new procedure, microsurgical operation for TESE (microdissection TESE) was reported; here individual seminiferous tubules can be seen under the operating microscope (Schlegel and Li, 1998; Schlegel, 1999; Amer *et al.*, 2000; Silber, 2000). Larger volumes of intratubular germ cells that have active spermatogenesis cause certain tubules to be identifiable as larger and more whitish and opaque

than tubules without sperm production. Using microdissection TESE, Schlegel reported a large increase in ability to find sperm, 45% (10/22) to 63% (17/27) of men with NOA (Schlegel, 1999). Although this represents a major improvement in sperm retrieval rate (SRR), underlying pathological abnormalities in the cases were not presented. Histological findings are important in any comparison, since a relationship between SRR and testicular histopathology has been reported in the context of conventional TESE (Tournaye *et al.*, 1997; Su *et al.*, 1999; Seo and Ko, 2001). In a prospective comparative study of patients with NOA and bilaterally identical testicular histology who underwent conventional TESE on one side and microdissection TESE on the other (Amer *et al.*, 2000), SRR by microdissection TESE was higher (47%) than by conventional TESE (30%). In that report, however, only one sample was taken from the testis subjected to conventional TESE, indicating that the procedure was simple, rather than multiple, with TESE.

In the present study we compared SRR by microdissection TESE with that obtained by conventional multiple TESE in patients with histological findings including hypospermatogenesis, maturation arrest (MA), and Sertoli cell-only syndrome (SCOS). Diagnostic biopsy specimens were reviewed in all

**Table I.** A comparison of endocrine profiles between multiple testicular sperm extraction (TESE) and microdissection TESE groups

	Multiple (n = 37)	Microdissection (n = 56) <sup>a</sup>	<i>P</i> <sup>b</sup>
Age (years)	32.4 ± 4.6	33.9 ± 5.4	0.154
Duration of infertility (months)	42.4 ± 31.0	49.9 ± 44.7	0.361
Testicular size (ml)	7.2 ± 3.7	8.6 ± 4.9	0.156
Patients with varicocele, <i>n</i> (%)	3 (8.1)	9 (16.1)	0.262
Patients after orchidopexy, <i>n</i> (%)	3 (8.1)	2 (3.6)	0.342
Endocrine profile			
LH (mIU/ml)	11.3 ± 8.6	8.3 ± 7.1	0.079
FSH (mIU/ml)	22.6 ± 10.6	24.0 ± 14.6	0.611
Testosterone (ng/dl)	4.4 ± 1.7	3.7 ± 1.7	0.062
Free testosterone (pg/dl)	15.5 ± 7.9	13.4 ± 4.0	0.214
Prolactin (ng/dl)	12.3 ± 9.3	9.4 ± 9.8	0.171

Data are mean ± SD unless stated otherwise.

<sup>a</sup>One case had undergone unilateral orchiectomy due to unknown reason when he was a child.

<sup>b</sup>All values are non-significant.

cases. In addition, we investigated the microscopic findings of testicular tubule during microdissection TESE, divided into three subgroups: homogeneously thick, homogeneously thin, and heterogeneous appearance.

## Materials and methods

### Patients

Thirty-seven patients who underwent conventional multiple TESE and 56 patients who underwent microdissection TESE at Osaka University Hospital, Osaka Central Hospital, or Osaka Police Hospital were included in this study. All patients were diagnosed with NOA on the basis of a complete history, physical examination, and endocrine profile, and scheduled for TESE with sperm freezing. Of 37 patients in the multiple TESE group, six (16.2%) had a 47,XXY karyotype (Klinefelter syndrome); this also was true for nine of 56 (16.1%) patients in the microdissection TESE group. Pre-operative patient characteristics are shown in Table I. As is also shown in Table I, endocrine data, including FSH, LH, prolactin, testosterone and free testosterone for the two groups were similar. Based on these findings, pre-operative patient characteristics in the two groups were considered nearly identical.

### Surgical approach

#### Multiple TESE

Multiple TESE ordinarily was performed under spinal or local anaesthesia. Through a small vertical incision in the median scrotal raphe, the skin, dartos muscle, and tunica vaginalis were opened to expose the tunica albuginea. The tunica albuginea was incised for ~4 mm at the upper pole near the head of the epididymis. Gentle pressure was applied to the testis to extrude a sufficient volume, which was excised with sharp scissors. If no sperm were seen in the initial sample according to the procedure of sperm retrieval described below, subsequent samples were taken from other locations, in the midline of the testis and at the lower pole opposite the rete testis, and subsequently from the contralateral testis. All testicular samples were approximately the same size and weight (~50 mg). The procedure was terminated when sperm were retrieved or all three samples from upper, middle, and lower sites per testis had been examined for the presence of testicular sperm. The tunica albuginea was closed with 3–0 Vicryl, and then the scrotum layers were closed separately.

### Microdissection TESE

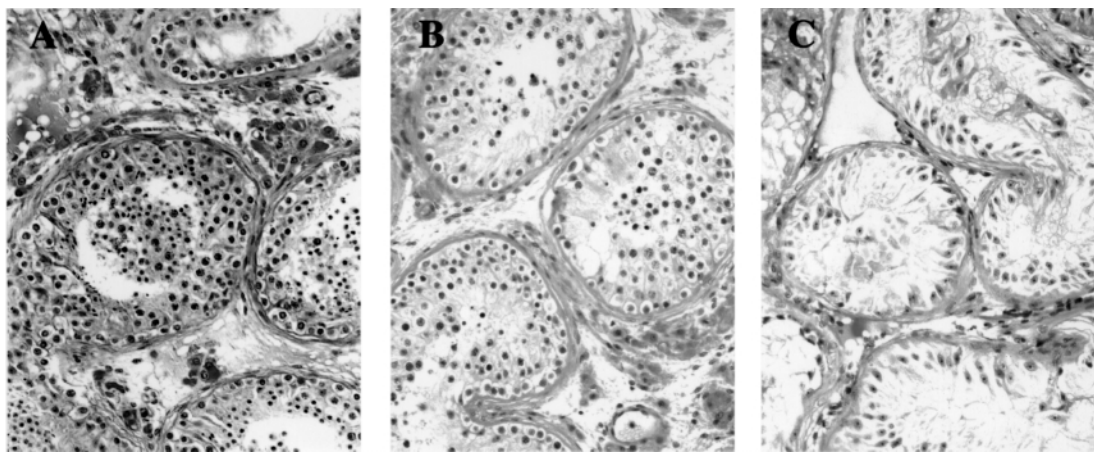
Microdissection TESE was performed under general anaesthesia according to the procedure reported previously (Schlegel, 1999; Silber, 2000). After the tunica albuginea was opened widely along the antimesenteric border, direct examination of the testicular parenchyma was performed at ×20 to ×40 magnifications under the operating microscope. An attempt was made to identify individual seminiferous tubules that were larger than other tubules in the testicular parenchyma; a previous report has indicated that larger volume of intratubular germ cells with active spermatogenesis within such tubules cause the tubule to appear larger, more opaque and whiter than tubules without sperm production. The examination was carried out to include as much of the testicular parenchyma as possible. Small samples (10–15 mg) were excised sharply from the larger, more opaque tubules. The procedure was terminated when sperm were retrieved or further biopsy was thought likely to jeopardize the blood supply of the testis. If all tubules were seen to have an identical morphological appearance, at least three samples (upper, middle, and lower) that were equivalent to those from multiple TESE were obtained.

### Sperm retrieval

Each sample was placed in a Petri dish filled with 0.5 ml of human tubal fluid (HTF) medium, minced, and shredded using sterile glass slides. Then, each sample was examined immediately by placing a small droplet of dispersed tissue suspension on the slide under a phase microscope using ×200 magnification for the presence of the testicular sperm. If no sperm were seen in the initial sample, subsequent samples were taken from the same testis and, if needed, from the contralateral testis. Finally in each case, a small sample was taken for histological diagnosis. Further, all testicular samples for ICSI with 5 ml of HTF were subjected to centrifugation at 1800 *g* with careful, extended examination to determine the presence of even a single sperm after TESE procedure.

### Methods

Operative time, histological findings, including Johnsen's score count (JSC) (Johnsen, 1970), and SRR were compared between multiple TESE and microdissection TESE groups. Each testicular specimen for histological diagnosis was evaluated based on the most advanced pattern of spermatogenesis present such as hypospermatogenesis (reduction in the degree of normal spermatogenesis and focal spermatogenesis with spermatid stage arrest), MA (spermatocyte stage arrest,



**Figure 1.** Histopathological findings of testicular samples of diagnostic biopsies were classified as hypospermatogenesis (A), maturation arrest (B), and Sertoli cell-only syndrome (C).

**Table II.** A comparison of operative time, histological findings, and sperm retrieval rate between multiple testicular sperm extraction (TESE) and microdissection TESE groups

	Multiple (OP time: 68.2 ± 24.5 min) <sup>a</sup>					Microdissection (OP time: 146.8 ± 52.3 min) <sup>a</sup>				
	Cases (%)	JSC	Success	Failure	SRR (%)	Cases (%)	JSC	Success	Failure	SRR (%)
SCOS	23 (62.2)	1.8 ± 0.4	3	20	13.0	40 (71.4)	1.8 ± 0.5	9	31	22.5
MA	1 (2.7)	4.0	0	1	0.0	4 (7.1)	4.7 ± 1.1	3	1	75.0
H	13 (35.1)	6.2 ± 0.6	10	3	76.9	12 (21.4)	6.5 ± 1.4	12	0	100.0
Total	37 (100.0)	3.4 ± 2.2	13	24	35.1	56 (100.0)	3.0 ± 2.1	24	32	42.9

OP = operation; JSC = Johnsen’s score count; SRR = sperm retrieval rate; SCO = Sertoli cell-only syndrome; MA = maturation arrest; H = hypospermatogenesis.

<sup>a</sup>*P* < 0.001.

absence of the later stages of germ cells in spermatogenesis), and SCOS (absence of germ cells in the seminiferous tubules; Figure 1). In addition, JSC was evaluated in each case. A case showing normal spermatogenesis, indicating obstructive azoospermia, was excluded from this study. In case of failure of sperm retrieval, the presence of round spermatids was checked. This round spermatid retrieval rate (rStRR) was compared between the multiple and microdissection TESE groups. The number of patients requiring post-operative hormone replacement therapy also was evaluated in each group. Further, microscopic findings of testicular tubule during operation were divided into three subgroups: homogeneously thick, homogeneously thin, and heterogeneous appearance in the microdissection TESE group. SRR was compared between these three subgroups.

**Statistical analysis**

All data are presented as mean ± SD. Statistical analysis between the two groups described above was performed by unpaired Student’s *t*-test or  $\chi^2$ -analysis as appropriate. *P* < 0.05 was considered to indicate a significant difference.

**Results**

Comparative data of operative time, histological findings as well as JSC, and SRR are shown in Table II. Mean operative time was longer in the microdissection TESE group (146.8 ± 52.3 min) than in the multiple TESE group (68.2 ± 24.5 min). By histological examination, the microdissection TESE group of 56 patients included 40 patients (71.4%) with SCOS (JSC; 1.8 ± 0.5), four patients (7.1%) with maturation arrest (JSC;

4.7 ± 1.1) and 12 patients (21.4%) with hypospermatogenesis (JSC; 6.5 ± 1.4). The multiple TESE group of 37 patients included 23 patients (62.2%) with SCOS (JSC; 1.8 ± 0.4), one patient (2.7%) with maturation arrest (JSC; 4.0), and 13 patients (35.1%) with hypospermatogenesis (JSC; 6.2 ± 0.6). JSC was slightly higher in the multiple TESE group (3.4 ± 2.2) than the microdissection TESE group (3.0 ± 2.1). Thus, impairment of spermatogenesis was somewhat more severe in the group undergoing microdissection TESE than in the multiple TESE group, although this difference was not statistically significant. Nonetheless, testicular sperm were found in 24 of 56 patients by undergoing microdissection TESE (42.9%), but only 13 of 37 patients (35.1%) undergoing multiple TESE. Comparison between the two groups showed that SRR by microdissection TESE and by multiple TESE in patients with histological diagnosis of SCOS (22.5 versus 13.0%) and hypospermatogenesis (100.0 versus 76.9%) was similar. Numbers of patients with maturation arrest were too small for comparison. No patients needed post-operative hormone replacement therapy because of hypogonadism in either group. In patients with failure of sperm retrieval, the results of rStRR are shown in Table III. rStRR was the same in the microdissection TESE (25.0%) and multiple TESE groups (20.8%). Three patients diagnosed as hypospermatogenesis in the multiple TESE group had round spermatids. Seven of 31 patients (22.6%) diagnosed as SCOS in the microdissection



**Table III.** A comparison of round spermatid retrieval rate between multiple testicular sperm extraction (TESE) and microdissection TESE groups

	Multiple				Microdissection			
	Cases	Success	Failure	rStRR (%)	Cases	Success	Failure	rStRR (%)
SCO	20	2 <sup>a</sup>	18	10.0	31	7 <sup>a</sup>	24	22.6
MA	1	0	1	0.0	1	1	0	100.0
H	3	3	0	100.0	0	–	–	–
Total	24	5	19	20.8	32	8	24	25.0

<sup>a</sup>One case of each group was found to have elongated spermatids.  
rStRR = round spermatid retrieval rate; SCO = Sertoli cell-only syndrome; MA = maturation arrest;  
H = hypospermatogenesis.

**Table IV.** Microscopic findings of testicular tubule during operation

	Cases (%)	Success	Failure	SRR (%)
Homogeneous				
Thick	7 (12.5)	7	0	100.0
H		7	0	100.0
Thin	23 (41.1)	0	23	0.0
MA		0	1	0.0
SCO		0	22	0.0
Heterogeneous	26 (46.4)	17	9	65.4
H		5	0	100.0
MA		3	0	100.0
SCO		9	9	50.0
Total	56 (100.0)	24	32	42.9

SRR = sperm retrieval rate; SCO = Sertoli cell-only syndrome; MA = maturation arrest; H = hypospermatogenesis.

TESE group were found to have round spermatids, while only two of 20 SCOS patients (10.0%) in the multiple TESE group had round spermatids (difference not significant).

Microscopic findings of testicular tubule of patients by microdissection TESE during operation are shown in Table IV. Seven of 56 patients (12.5%) showed homogeneously thick tubule and all of these were classified as hypospermatogenesis. In this subgroup, all patients were found to have testicular sperm. Twenty-three patients (41.1%) showed homogeneously thin tubules and 22 of these were classified as SCOS, with one patient classified as MA. No patient had testicular sperm in this subgroup. Twenty-six patients (46.4%) showed heterogeneous thickness of testicular tubule under the operative microscope. Seventeen of 26 patients were found to have testicular sperm (SRR; 65.4%). Eight patients, including five with hypospermatogenesis and three with maturation arrest, had testicular sperm. In this heterogeneous subgroup, there was no patient with either hypospermatogenesis or maturation arrest who did not have testicular sperm. Furthermore, nine out of a total of 18 patients with SCOS had testicular sperm in this subgroup; hence SRR was 50.0%.

## Discussion

A certain minimum threshold of spermatogenesis is necessary for testicular sperm to reach the ejaculate. As a consequence, men with NOA may be able to initiate a pregnancy if sperm

can be retrieved using TESE (Silber *et al.*, 1997). TESE combined with ICSI now is the first-line treatment in NOA. The current focus of TESE is identification of a seminiferous tubule that contains sperm. Several kinds of TESE procedure have been used, such as needle biopsy, open biopsy to obtain one sample (simple TESE) or multiple samples (multiple TESE), and microsurgical operation (microdissection TESE).

Testicular damage may be minimized by using needle biopsy rather than open biopsy to obtain sperm. However, in difficult cases of NOA, where spermatogenesis is very meagre, needle biopsy is much less likely to obtain rare foci of spermatogenesis for ICSI than open biopsy (Craft *et al.*, 1997). In one report, 14% of patients with NOA had successful sperm recovery by needle biopsy, while 63% of patients had successful sperm recovery by open biopsy (Ezeh *et al.*, 1998). Open biopsy, therefore, came to be preferred. Further, the testis of patients with NOA typically is heterogeneous with respect to spermatogenesis; a single sample from prior diagnostic testicular biopsy failed to predict success or failure of subsequent TESE in  $\geq 15\%$  of patients. Since no particular location in the testis was particularly likely to contain sperm, multiple TESE has been recommended (Silber, 2000). Indeed, sperm were often present in only one sample and not in another when multiple TESE was performed (Hauser *et al.*, 1998). Thus, multiple TESE has been the standard procedure for obtaining testicular sperm for ICSI until quite recently.

Microdissection TESE first was introduced by Schlegel (1999). Direct vision with the operating microscope in microdissection TESE is of great advantage, since larger, more opaque, whitish tubules, presumably containing more intratubular germ cells with active spermatogenesis, can be identified. Generally, the testis is small in patients with NOA involving severely impaired spermatogenesis, such as in SCOS and Klinefelter syndrome. Minute foci of normal spermatogenesis in the small testis can be detected under the operating microscope; only tiny portions need be removed, minimizing operative damage. After introduction of the microdissection technique, the ability to find sperm was reported to increase from 45% (10/22) to 63% (17/27) of TESE in men with NOA (Schlegel, 1999). Sperm have been reported to be retrieved with microdissection TESE in six men after sperm retrieval by standard TESE had been unsuccessful. Although the reported SRR using the operating microscope has been very

high, underlying pathological abnormalities in the cases were not presented. So whether overall testicular damage in the microdissection TESE group was as severe as in the multiple TESE group was not clear. Such underlying pathological findings are very important, since many reports have demonstrated a relationship between successful TESE and testicular histopathology (Tournaye *et al.*, 1997; Su *et al.*, 1999; Seo and Ko, 2001).

In a prospective comparative study, 100 patients with NOA and bilaterally identical testicular histology underwent TESE via conventional open biopsy on one side and the microsurgical procedure on the other (Amer *et al.*, 2000). SRR by microdissection TESE was higher (47%) than by conventional TESE (30%). However, the procedure used in that study was simple rather than multiple TESE, since only one sample was excised from the testis. The present study is the first direct comparison of SRR by microdissection TESE and multiple TESE in patients with NOA to include consideration of testicular histopathology.

In the present study, pre-operative patient characteristics of microdissection TESE and multiple TESE groups, including endocrine profiles, were similar. However, the histological examinations showed that in the microdissection TESE group, 71.4% of patients had SCOS, 7.1% had MA and 21.4% had hypospermatogenesis; the respective values in the multiple TESE group were 62.2, 2.7 and 35.1%. This difference of histological distribution meant that the JSC of the microdissection TESE group ( $3.0 \pm 2.1$ ) was slightly lower than that of the multiple TESE group ( $3.4 \pm 2.2$ ). Overall SRR by microdissection TESE (42.9%) appeared higher than by multiple TESE (35.1%), although this difference was not statistically significant (Table II). However, since our histological findings indicated slightly underlying impairment of spermatogenesis in the group with microdissection TESE, we suspect that microdissection TESE is relatively effective for sperm retrieval in cases of NOA. Further, no sperm were found by multiple TESE in three of 13 patients diagnosed with hypospermatogenesis, while sperm were found in all 12 such patients in the microdissection TESE group. In general, hypospermatogenesis is defined as a reduction in the degree of normal spermatogenesis and focal spermatogenesis with spermatid stage arrest (Narbaitz *et al.*, 1978). This means that patients diagnosed with hypospermatogenesis by histological examination should have obtainable testicular sperm. In reality, four of 12 patients with hypospermatogenesis in whom sperm were retrieved by microdissection TESE in our departments had previous unsuccessful multiple TESE at other clinics. We believe that microdissection TESE offers a great advantage for patients with hypospermatogenesis, since testicular sperm are reliably detected and retrieved. In addition, ooplasmic injection of elongating spermatid and round spermatid/round spermatid nucleus was recently reported in a clinical trial of treatment for NOA (Tesarik *et al.*, 1995; Yamanaka *et al.*, 1997; Sofikitis *et al.*, 1998a,b). Indeed, this treatment was reported to achieve fertilization, pregnancy, and delivery in some cases. This advanced treatment offers a great advantage for patients with failure of testicular sperm retrieval, since even such patients may have a chance to be treated for

infertility. Therefore we investigated rStRR in patients with failure of testicular sperm retrieval. Likewise SRR, rStRR in cases with failure of sperm retrieval by microdissection TESE (25.0%) appeared higher than by multiple TESE (20.8%), although this difference was not a significantly different (Table III). rStRR was higher by microdissection TESE (22.6%) than by multiple TESE (10.0%) in patients with the most severe impairment (SCOS). Taken together with ooplasmic injection of early haploid cells, microdissection TESE is a valuable procedure for patients with SCOS, even if sperm are not detected. Since this advanced technique is, however, restricted by the Japanese Association of Obstetrics and Gynecologists in Japan, we did not try it. Thus, most of our patients with failure of sperm retrieval had to quit infertility treatment: some patients requested artificial insemination with donor's semen.

SRR and rStRR in patients with the most severe impairment (SCOS) appeared higher by microdissection TESE (22.5 and 22.6%) than by multiple TESE (13.0 and 10.0%) although these findings did not reach statistical significance. This finding is in agreement with previous reports (Schlegel, 1999; Amer *et al.*, 2000; Silber, 2000). A great advantage of microdissection TESE is direct vision with the operating microscope to identify larger, more opaque, whitish tubules, presumably containing more intratubular germ cells with active spermatogenesis. Therefore we focused on microscopic findings of testicular tubule during operation (Table IV). Thirty of 56 patients showed homogeneous thickness, either thick or thin, for testicular tubule in the present study. Actually microdissection TESE did not provide a great advantage in these 30 patients, because the operating microscope was not necessary to identify a larger tubule containing sperm. This means that SRR by microdissection TESE should be same as that by multiple TESE in these cases. In this aspect, microdissection TESE with the operating microscope was greatly useful for patients who had heterogeneous testicular tubule. Our result showed that 17 of 26 (65.4%) patients with heterogeneous testicular tubule were successful for sperm retrieval by microdissection TESE. Nine of 18 patients (50.0%) with SCOS in this heterogeneous subgroup were successful for sperm retrieval, yielding what appeared to be higher SRR (22.5%) by microdissection TESE than multiple TESE (13.0%) compared with all patients with SCOS in this study. Taken together, we think that microdissection TESE is the best way for patients with SCOS, who may have heterogeneous testicular tubule.

Microdissection TESE was reported to cause significantly fewer acute and chronic complications than conventional procedures based on post-operative ultrasonography (Amer *et al.*, 2000). In the present study, operative time was significantly longer in cases of microdissection TESE than multiple TESE. However, severe complications, such as acute epididymitis, scrotal haematoma and testicular hydrocele were not seen in any patient in either the microdissection TESE or the multiple TESE group. In addition, no patient required hormone replacement therapy for treatment of post-operative hypogonadism. These findings suggested that microdissection TESE is safe in terms of both surgical and endocrinological complications.

SRR and rStRR appeared to be higher by microdissection TESE than multiple TESE despite a smaller volume of testicular parenchyma removed in microdissection TESE than in multiple TESE. Complications were not seen in any patient performed by microdissection TESE. Twenty-six of 56 patients (46.4%) had heterogeneous testicular tubule and 17 of 26 patients (65.4%) were successful for sperm retrieval by identification of larger tubule. Further, nine of these successful 17 patients were classified as the most severe testicular impairment (SCOS). We conclude that the microsurgical technique may improve sperm retrieval by TESE for patients with hypospermatogenesis and for patients with SCOS. The latter patients may have heterogeneous testicular tubules, and tubules containing germ cells with active spermatogenesis may be detected by the operative microscope.

### Acknowledgements

We are very grateful to Ms K.Adachi, M.Kojima, and M.Omune of our laboratory, Mr T.Tsuiji of Okamoto Clinic, Ms K.Okubo of Wakimoto Clinic, and Ms M.Watabe for their assistance and discussion. We also thank Drs Y.Okamoto of Okamoto Clinic, H.Wakimoto of Wakimoto Clinic and K.Miyazaki of Miyazaki Ladies Clinic for data collection.

### References

- Amer, M., Ateyah, A., Hany, R. and Zohdy, W. (2000) Prospective comparative study between microsurgical and conventional testicular sperm extraction in non-obstructive azoospermia: follow-up by serial ultrasound examination. *Hum. Reprod.*, **15**, 653–656.
- Craft, I., Bennett, V. and Nicholson, N. (1993) Fertilizing ability of testicular spermatozoa. *Lancet*, **342**, 864.
- Craft, I., Tsigotis, M., Courtauld, E. and Farrer-Brown, G. (1997) Testicular needle aspiration as an alternative to biopsy for the assessment of spermatogenesis. *Hum. Reprod.*, **12**, 1483–1487.
- Devroey, P., Liu, J., Nagy, Z.P., Goossens, A., Tournaye, H., Camus, M., Van Steirteghem, A. and Silber, S. (1995) Pregnancies after testicular sperm extraction and intracytoplasmic sperm injection in non-obstructive azoospermia. *Hum. Reprod.*, **10**, 1457–1460.
- Ezeh, V.I.O., Moore, H.D.M. and Cooke, I.D. (1998) A prospective study of multiple needle biopsies versus a single open biopsy for testicular sperm extraction in men with non-obstructive azoospermia. *Hum. Reprod.*, **13**, 3075–3080.
- Friedler, S. (1998) Testicular sperm aspiration (TESA): the appropriate technique. [Letter to the editor.] *Hum. Reprod.*, **13**, 1111–1114.
- Friedler, S., Raziel, A., Strassburger, D., Soffer, Y., Komarovsky, D. and Ron-El, R. (1997) Testicular spermatozoa retrieval by percutaneous five needle sperm aspiration compared with testicular sperm extraction by open biopsy in men with non-obstructive azoospermia. *Hum. Reprod.*, **12**, 1488–1492.
- Hauser, R., Botchan, A., Amit, A., Ben Yosef, D., Gamzu, R., Paz, G., Lessing, J.B., Yogev, L. and Yavetz, H. (1998) Multiple testicular sampling in non-obstructive azoospermia: is it necessary? *Hum. Reprod.*, **13**, 3081–3085.
- Johnsen, S.G. (1970) Testicular biopsy score count: a method for registration of spermatogenesis in human testis: normal values and results in 335 hypogonadal males. *Hormones*, **1**, 2–25.
- Mansour, R.I., Aboulghar, M., A., Serour, G.I., Fahmi, I., Ramzy, A.M. and Amin, Y. (1996) Intracytoplasmic sperm injection using microsurgically retrieved epididymal and testicular sperm. *Fertil. Steril.*, **12**, 566–572.
- Narbaitz, R., Tolnai, G., Jolly, E.E., Barwin, N. and McKay, D.E. (1978) Ultrastructural studies on testicular biopsies from eighteen cases of hypospermatogenesis. *Fertil. Steril.*, **30**, 679–686.
- Ostad, M., Liotta, D., Ye, Z. and Schlegel, P.N. (1998) Testicular sperm extraction (TESE) for non-obstructive azoospermia: results of multibiopsy approach with optimized tissue dispersion. *Urology*, **52**, 692–696.
- Rosenlund, B., Kvist, U., Ploen, L., Rozell, B.L., Sjöblom, P. and Hillensjö, T. (1998) A comparison between open and percutaneous needle biopsies in men with azoospermia. *Hum. Reprod.*, **13**, 1266–1271.
- Schlegel, P.N. (1999) Testicular sperm extraction: microdissection improves sperm yield with minimal tissue excision. *Hum. Reprod.*, **14**, 131–135.
- Schlegel, P.N. and Li, P.S. (1998) Microdissection TESE: spermatozoa retrieval in non-obstructive azoospermia. *Hum. Reprod. Update*, **4**, 439.
- Schoysman, R., Vanderzwalmen, O., Nijis, M., Segal-Bertin, G. and van de Casseye, M. (1993) Successful fertilization by testicular spermatozoa in an in-vitro fertilization program. *Hum. Reprod.*, **8**, 1339–1340.
- Seo, J.T. and Ko, W.-J. (2001) Predictive factors of successful testicular sperm recovery in non-obstructive azoospermia patients. *Int. J. Androl.*, **24**, 306–310.
- Silber, S.J. (2000) Microsurgical TESE and the distribution of spermatogenesis in non-obstructive azoospermia. *Hum. Reprod.*, **15**, 2278–2284.
- Silber, S.J., Nagy, P., Liu, J., Tournaye, H., Lissens, W., Ferec, C., Liebaers, I., Devroey, P. and Van Steirteghem, A.C. (1995a) The use of epididymal and testicular spermatozoa for intracytoplasmic sperm injection: the genetic implications for male infertility. *Hum. Reprod.*, **10**, 2031–2043.
- Silber, S.J., Van Steirteghem, A.C. and Devroey, P. (1995b) Sertoli cell only revisited. *Hum. Reprod.*, **10**, 1031–1032.
- Silber, S.J., Van Steirteghem, A.C., Lui, J., Nagy, Z., Tournaye, H. and Devroey, P. (1995c) High fertilization and pregnancy rates after intracytoplasmic sperm injection with spermatozoa obtained from testicular biopsy. *Hum. Reprod.*, **10**, 148–152.
- Silber, S.J., van Steirteghem, A.C., Lui, J., Tournaye, H. and Devroey, P. (1996) Normal pregnancies resulting from testicular sperm extraction and intracytoplasmic sperm injection for azoospermia due to maturation arrest. *Fertil. Steril.*, **1**, 110–117.
- Silber, S.J., Nagy, Z., Devroey, P., Tournaye, H. and Van Steirteghem, A.C. (1997) Distribution of spermatogenesis in the testicles of azoospermic men with germinal failure. *Hum. Reprod.*, **12**, 2422–2428.
- Sofikitis, N.V., Yamamoto, Y., Miyagawa, I., Mekras, G., Mio, Y., Toda, T., Antypas, S., Kawamura, H., Kanakas, N., Antoniou, N. *et al.* (1998a) Ooplasmic injection of elongating spermatids for the treatment of non-obstructive azoospermia. *Hum. Reprod.*, **13**, 709–714.
- Sofikitis, N.V., Miyagawa, I., Yamamoto, Y., Loutradis, D., Mantzavinos, T. and Tarlatzis, V. (1998b) Micro- and macro-consequences of ooplasmic injection of early haploid male gametes. *Hum. Reprod. Update*, **4**, 197–212.
- Su, L., M., Palermo, G.D., Goldstein, M., Veeck, L.L., Rosenwaks, Z. and Schlegel, P.N. (1999) Testicular sperm extraction with intracytoplasmic sperm injection for non-obstructive azoospermia: testicular histology can predict success of sperm retrieval. *J. Urol.*, **161**, 112–116.
- Tesarik, J., Mendoza, C. and Testart, J. (1995) Viable embryos from injection of round spermatids into oocytes. *N. Engl. J. Med.*, **333**, 525.
- Tournaye, H., Camus, M., Goossens, A., Liu, J., Nagy, P., Silber, S. and Van Steirteghem, A.C. (1995) Recent concepts in the management of infertility because of non-obstructive azoospermia. *Hum. Reprod.*, **10** (Suppl. 1), 115–119.
- Tournaye, H., Verheyen, G., Nagy, P., Ubaldi, F., Goossens, A., Silber, S. and Van Steirteghem, A.C. (1997) Are there any predictive factors for successful testicular sperm recovery in azoospermic patients? *Hum. Reprod.*, **12**, 80–86.
- Yamanaka, K., Sofikitis, N.V., Miyagawa, I., Yamamoto, Y., Toda, T., Antypas, S., Dimitriadis, D., Takenaka, M., Taniguchi, K., Takahashi, K. *et al.* (1997) Ooplasmic round spermatid nuclear injection procedures as an experimental treatment for nonobstructive azoospermia. *J. Assist. Reprod. Genet.*, **14**, 55–62.

Submitted on March 27, 2002; resubmitted on June 13, 2002; accepted on July 22, 2002