Isolated complete bitemporal hemianopia in traumatic chiasmal syndrome

Dai Woo Kim[1], Ungsoo Samuel Kim[1,2]

A 29-year-old man presented with a chief complaint of lateral blindness in the left eye at 4 months after an accidental fall. His best corrected visual acuity was 0.7 in the left eye and 1.0 in the right eye. Visual field test showed a complete bitemporal hemianopic defect without any neurologic symptoms. An orbital computed tomography scan with non-enhancement conducted at the time of the visit showed multiple frontal skull fractures and cerebromalacia a small fracture in the sphenoidal boneboth frontal lobes. No radiological abnormalities of the visual pathway were detected. Optical coherence showed reduced thickness in the retinal nerve fiber layer, primarily in the superior and inferior part of the left eye. To our knowledge, a complete bitemporal hemianopia without neurological deficits is extremely rare in traumatic chiasmal syndrome.

Keywords: Bitemporal hemianopia, Traumatic chiasmal syndrome, visual field

Access this article online

Website: www.ijo.in

Quick Response Code:

A 29-year-old man sustained a closed head trauma in an accidental fall. Four months after the accident, he presented with a chief complaint of lateral blindness in the left eye. His best corrected visual acuity was 0.7 in the left eye and 1.0 in the right eye. Humphrey visual field test showed a complete bitemporal hemianopic defect [Fig. 1]. Other than the visual defect, no focal neurological deficits, including cranial nerve palsy, diabetes insipidus, cerebrospinal fluid rhinorrhea, and panhypopituitarism were detected. Fundus photography showed a pale disc in the left eye [Fig. 2a]. An orbital computed tomography scan with nonenhancement conducted at the time of the visit showed multiple frontal skull fractures and cerebromalacia in both frontal lobes. No radiological abnormalities of the visual pathway were detected. Optical coherence tomography (OCT) showed reduced thickness in the retinal nerve fiber layer (RNFL), primarily in the superior and inferior part of the left eye [Fig. 2b].

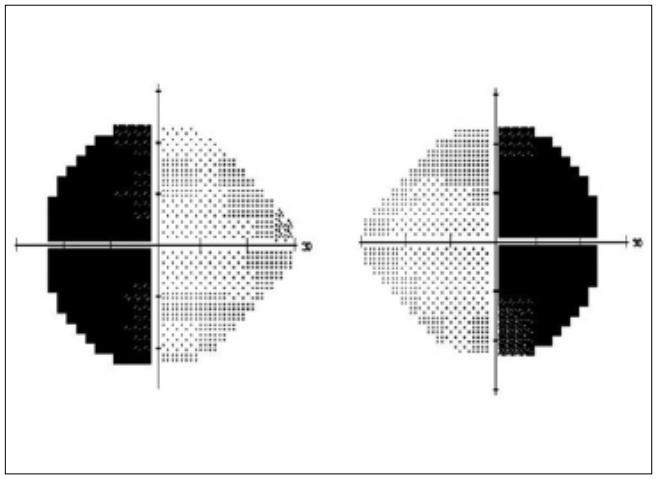

Figure 1: Humphrey automated static perimetry shows complete bitemporal hemianopia

Discussion

Chiasmal syndrome comprises various signs and symptoms associated with lesions of the optic chiasm. Trauma is one of the rare etiologies of chiasmal syndrome because few patients survive after the severe impact.[1,2] Various visual field defects including bitemporal hemianopia, temporal hemianopia, and quadrantanopia have been reported;[2] however, complete bitemporal hemianopia without profound visual loss, as seen in the present case, is rare. Frequently associated neurological complications include cranial nerve palsies, diabetes insipidus, cerebrospinal fluid rhinorrhea, panhypopituitarism, and carotid-cavernous fistula.[2-4] However, in our patient, visual deficit occurred in isolation without other neurological abnormalities at 7 months' follow-up after the injury. In our case, the RNFL loss was detected primarily in the superior and inferior regions in OCT with 4-quadrant or 12 30° segment views. The reason that the OCT findings of the traumatic bitemporal hemianopsia did not show the classical bow-tie pattern may be attributed to the complex nature of the traumatic injury.

[1]Departments of Ophthalmology, Kim's Eye Hospital, Seoul, [2]Konyang University College of Medicine, Daejeon, Korea

Correspondence to: Prof. Ungsoo Samuel Kim, Department of Ophthalmology, Kim's Eye Hospital, Konyang University College of Medicine, Youngdeungpo 4th 156, Youngdeungpo-gu, Seoul - 150-034, Korea. E-mail: ungsookim@kimeye.com

Manuscript received: 16.12.12; Revision accepted: 09.09.13

References

1. Resneck JD, Lederman IR. Traumatic chiasmal syndrome associated with pneumocephalus and sellar fracture. Am J Ophthalmol 1981;92:233-7.
2. Hassan A, Crompton JL, Sandhu A. Traumatic chiasmal syndrome: A series of 19 patients. Clin Experiment Ophthalmol 2002;30:273-80.
3. Savino PJ, Glaser JS, Schatz NJ. Traumatic chiasmal syndrome.

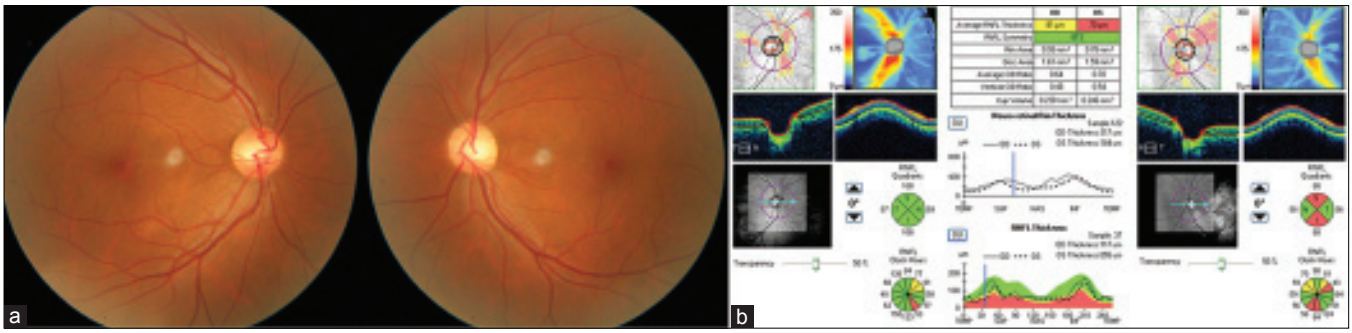

Figure 2: (a) Fundus photography showing optic disc pallor in the left eye. (b) Optical coherence tomography of the retinal nerve fiber layer. The right eye shows moderate to severe retinal nerve fiber loss in the supratemporal part and severe loss in the inferior part. The left eye shows severe retinal nerve fiber loss, primarily in the superior and inferior parts

Neurology 1980;30:963-70.

4. Kawai K, Narita Y, Nagai A, Nakagomi T, Kobayashi K, Kirino T, *et al.* Traumatic chiasmal syndrome presenting with bitemporal hemianopsia. J Trauma 1998;44:224-9.

Cite this article as: Citation will be included before issue gets online***

Source of Support: Nil. **Conflict of Interest:** None declared.