

Skin Therapy Letter[®]

Volume 11 • Number 9 • November 2006

Indexed by the US National Library of Medicine and PubMed

EDITOR: DR. STUART MADDIN

EDITOR-IN-CHIEF

Stuart Maddin, MD
University of British Columbia, Vancouver, Canada

ASSOCIATE EDITORS

Hugo Degreef, MD, PhD - Medical Dermatology
Catholic University, Leuven, Belgium

Jason Rivers, MD - Medical Dermatology
University of British Columbia, Vancouver, Canada

Jeffrey S. Dover, MD - Surgical Dermatology
Yale University School of Medicine, New Haven, USA
Dartmouth Medical School, Hanover, USA

ASSISTANT ASSOCIATE EDITOR

Murad Alam, MD - Surgical Dermatology
Northwestern University Medical School, Chicago, USA

EDITORIAL ADVISORY BOARD

Kenneth A. Arndt, MD
Beth Israel Hospital
Harvard Medical School, Boston, USA

Wilma Fowler Bergfeld, MD
Cleveland Clinic, Cleveland, USA

Jan D. Bos, MD
University of Amsterdam, Amsterdam, Holland

Alastair Carruthers, MD
University of British Columbia, Vancouver, Canada

Bryce Cowan, MD, PhD
University of British Columbia, Vancouver, Canada

Boni E. Elewski, MD
University of Alabama, Birmingham, USA

Barbara A. Gilchrest, MD
Boston University School of Medicine, Boston, USA

Christopher E.M. Griffiths, MD
University of Manchester, Manchester, UK

Aditya K. Gupta, MD, PhD, MBA/MCM
University of Toronto, Toronto, Canada

Mark Lebwohl, MD
Mt. Sinai Medical Center, New York, USA

James J. Leydon, MD
University of Pennsylvania, Philadelphia, USA

Harvey Lui, MD
University of British Columbia, Vancouver, Canada

Howard I. Maibach, MD
University of California Hospital, San Francisco, USA

Jose Mascaro, MD, MS
University of Barcelona, Barcelona, Spain

Larry E. Millikan, MD
Tulane University Medical Center, New Orleans, USA

Jean Paul Ortonne, MD
Centre Hospitalier Universitaire de Nice, Nice, France

Ted Rosen, MD
Baylor College of Medicine, Houston, USA

Alan R. Shalita, MD
SUNY Health Sciences Center, Brooklyn, USA

Wolfram Sterry, MD
Humboldt University, Berlin, Germany

Richard Thomas, MD
University of British Columbia, Vancouver, Canada

Stephen K. Tyring, MD, PhD, MBA
University of Texas Health Science Center, Houston, USA

John Voorhees, MD
University of Michigan, Ann Arbor, USA

Guy Webster, MD
Jefferson Medical College, Philadelphia, USA

Klaus Wolff, MD
University of Vienna, Vienna, Austria

MANAGING EDITOR

Penelope Gray-Allan

Topical Treatments for Melasma and Postinflammatory Hyperpigmentation

C.B. Lynde; J.N. Kraft, MD; C.W. Lynde, MD, FRCPC

Faculty of Medicine, University of Toronto, Toronto, Canada

ABSTRACT

Hyperpigmentation disorders of the skin are common and can be the source of significant psychosocial distress for patients. The most common of these disorders are melasma and postinflammatory hyperpigmentation. Sunscreen use and minimizing sun exposure are crucial in all cases. Topical applications are the mainstay of treatment and include phenols, retinoids, corticosteroids, and their combinations.

Key Words: hyperpigmentation, melasma, postinflammatory hyperpigmentation, PIH

Hyperpigmentation of the skin is a very common problem, with many patients seeking therapies to improve their cosmetic appearance. It is the result of an increase in cutaneous melanin deposition either by increased melanin synthesis or, less commonly, by a greater number of melanocytes. The amount of color change depends on the location of the melanin deposition. Epidermal involvement appears as brown discoloration whereas dermal deposition appears as blue-grey.¹ Mixed epidermal and dermal depositions appear as brown-grey discolorations. The use of a Wood's lamp can often be very beneficial in determining the location of melanin deposition showing enhancement of color contrast in lesional skin for the epidermal type, but not the dermal types. The mixed type has enhancement in some areas of lesional skin, but not in other areas.² Whether the melanin is deposited in the epidermis or dermis is important therapeutically because dermal hyperpigmentation is much more challenging to treat.³

The most common pigmentation disorders for which patients seek treatment are melasma and postinflammatory hyperpigmentation (PIH). These conditions may have a major impact because disfiguring facial lesions can significantly affect a person's psychological and social wellbeing, contributing to lower productivity, social functioning, and self-esteem.^{4,5}

Melasma

Melasma is a common acquired pigmentary disorder that occurs mainly in women (more than 90% of cases)⁶ of all racial and ethnic groups, but particularly affects those with Fitzpatrick skin types IV–VI.⁷ While the cause of melasma is unknown, factors include: a genetic predisposition, ultraviolet light exposure, and estrogen exposure.⁸ Estrogen is thought to induce melasma as it often develops during pregnancy, with use of oral contraceptives, and with hormone replacement therapy (HRT) in postmenopausal women.⁹ Melasma in pregnancy usually clears within a few months of delivery.

Discontinuation of oral contraceptives or HRT, in combination with adequate sun protection, may also result in melasma clearance,¹⁰ although there is a paucity of literature with regard to HRT and the clearance of this condition.

Melasma presents as brown to grey macules and patches, with serrated, irregular, and geographic borders.⁷ The pigmented patches are usually sharply demarcated¹⁰ and symmetrical. Melasma has a predilection for sun-exposed areas. The three major patterns of distribution are: centrofacial (cheeks, forehead, upper lip, nose, and chin) (66% of cases), malar (cheeks and nose) (20% of cases) and mandibular (rami of the mandible) (15% of cases). See Table 1 for the differential diagnosis.⁸

Postinflammatory Hyperpigmentation (PIH)

PIH represents a pathophysiologic response to cutaneous inflammation, such as acne, atopic dermatitis, lichen planus, and psoriasis. Similar to melasma, it is more obvious in patients with brown or black skin.⁸ It has no gender or age predominance.¹⁰ The lesions are characteristically limited to the site of the preceding inflammation and have indistinct, feathered borders.⁷ Melanocytes can either be stimulated by the inflammatory process to become hypertrophic, thus secreting more melanin, or the number of melanocytes can increase. Epidermal hyperpigmentation (e.g., associated with acne) occurs when increased melanin is transferred to keratinocytes while dermal pigmentation (e.g., associated with lichen planus and cutaneous lupus erythematosus) occurs when the basement membrane is disrupted and melanin falls into the dermis and resides within melanophages.⁸

Any inflammatory disorder can be associated with PIH, including:

- Acne vulgaris
- Atopic dermatitis
- Discoid lupus erythematosus
- Erythema dyschromicum perstans
- Fixed drug eruption
- Generalized drug eruption
- Idiopathic eruptive macular pigmentation
- Impetigo
- Insect bites
- Irritant and allergic contact and photocontact-dermatitis
- Lichen planus
- Lichen simplex chronicus
- Morphea
- Pityriasis rosea
- Polymorphous light eruption
- Psoriasis
- Trauma (i.e., burns, abrasions, postsurgical)
- Viral exanthem

Hyperpigmentation Treatments

Therapeutic goals for hyperpigmentation include promoting the degradation of melanosomes, inhibiting the formation of melanosomes, and retarding the proliferation of melanocytes.¹¹ Because sun exposure is an important etiologic factor in hyperpigmentation, all patients should use daily, broad-spectrum, high SPF sunscreens and minimize sun exposure.¹² Although this practice is widely used there are no clinical trials to support its therapeutic benefit. Most of the therapies used for hyperpigmentation have been studied in melasma and the same treatment principles hold for PIH.³

Condition	Distinguishing Features
Cutaneous mercury deposits	<ul style="list-style-type: none"> • History of mercury containing soaps/creams • Dermatitis may be present
Drug-induced hyperpigmentation	<ul style="list-style-type: none"> • History of medication • Hyperpigmentation less patterned and less irregular
Erythema dyschromicum perstans	<ul style="list-style-type: none"> • Gray to blue-brown lesions • Inflammatory phase with rim of erythema occasionally seen • Distribution includes nonsun-exposed areas
Exogenous ochronosis	<ul style="list-style-type: none"> • History of hydroquinone application • Banana-shaped, yellow-brown deposits in the dermis
Lichen planus actinicus	<ul style="list-style-type: none"> • Fine scale overlying violaceous lesions
Postinflammatory hyperpigmentation	<ul style="list-style-type: none"> • History or presence of inflammation with erythema, and/or scaling

Table 1: Differential Diagnosis of Melasma

Topical Treatments for Melasma

In those patients with epidermal type melasma, there are multiple treatments available (see Table 2).⁶ Topical agents include phenols, e.g., hydroquinone (HQ); retinoids, e.g., tretinoin; azelaic acid; kojic acid (KA); and glycolic acid (GA).

Hydroquinone

HQ 2%–4% has been widely used for melasma therapy. It inhibits the conversion of dopa to melanin by inhibiting the activity of tyrosinase.¹³ Moreover, Jimbow, et al. proposed that it may interfere with DNA and RNA synthesis, degrade melanosomes, and destroy melanocytes.¹⁴

There are rare case reports of allergic contact dermatitis to HQ,¹⁵⁻¹⁷ however, irritant reactions are more common, with up to 25% developing an itchy eruption as demonstrated in a recent randomized control trial.¹⁸ We recommend that patients test HQ on a hidden area, e.g., the upper inner arm, prior to use on areas that are especially visible, such as the face.

Ennes, et al. compared HQ 4% with placebo over 12 weeks in 48 patients who had melasma. Thirty-eight percent of HQ patients showed total improvement and 57% demonstrated partial improvement. Only 8% of placebo patients achieved total improvement and 17% were treatment failures.¹⁹ Side-effects included irritant and allergic contact dermatitis, PIH, nail bleaching and rarely, ochronosis-like pigmentation.⁸ Toxicity studies have shown HQ is capable of inducing renal adenoma in rats and is fetotoxic in animals.²⁰ These findings influenced the EU to ban HQ agents as a cosmetic. However, these complications have not been reported in humans.²¹

Under no circumstances should monobenzylether, or any other ethers of HQ, be used to treat melasma as they can lead to a permanent loss of melanocytes with the development of a disfiguring confetti-like leukoderma.⁷

Retinoids

Tretinoin 0.05%–0.1% reduces pigmentation by inhibiting tyrosinase transcription, as well as by interrupting melanin synthesis.²² While tretinoin may be effective in reducing melasma, it typically takes at least 24 weeks to see clinical improvement.²³ It may also increase pigmentation secondary to irritation¹⁰ and may cause erythema and peeling.²⁴ Other retinoids including adapalene, tazarotene and topical isotretinoin have also been used.^{25,26}

Azelaic Acid

Azelaic acid (15%–20%) (Finacea®, Intendis), a C9 dicarboxylic acid, is a reversible inhibitor of tyrosinase²⁷ and may also have both cytotoxic and antiproliferative effects on melanocytes.²⁸ In a randomized, double-blind study, azelaic acid was shown to be as effective as HQ 4% but without its side effects.²⁹ The combination of azelaic acid with 0.05% tretinoin or 15%–20% glycolic acid may produce earlier, more pronounced skin lightening.⁸ Adverse effects include pruritus, mild erythema, scaling, and burning.²⁸

Kojic Acid

KA 2% is produced by the fungus *Aspergilline oryzae* and is a tyrosinase inhibitor.⁷ It is generally equivalent to other therapies but may be more irritating.³⁰ In one double-blind study, KA 2% combined with HQ 2% was shown to be superior to glycolic acid (GA) 10% and HQ 2%.³¹ Another double-blind study compared GA 5% with either HQ 4% or KA 4% for 3 months. Both combinations proved equally effective with reduction of pigmentation in 51% of patients.³² KA may be effective if a patient has difficulty tolerating other first-line therapies.³⁰

Glycolic Acid

GA 5%–10% is an alpha-hydroxy acid and has been studied in combination with other agents. It decreases pigment by many mechanisms including thinning the stratum corneum, enhancing epidermolysis, dispersing melanin in the basal layer of the epidermis, and increasing collagen synthesis in the dermis.² One combination study compared GA 10% plus HQ 4% in a cream that included vitamins C and E and sunscreen vs. sunscreen cream alone. Seventy-five percent of patients improved using the treatment enhanced cream compared with only 13% who used the sunscreen alone. Mild irritation was a common adverse effect.³³

Combination Therapy

Combination therapy is more effective than single agents used alone. The etiology of melasma is not completely understood, thus, therapies that can act at different stages of pigmentation can produce better clinical results than a single therapy acting at a single stage.⁶

The addition of tretinoin eliminates pigment and increases keratinocyte proliferation by preventing the oxidation of HQ and improving epidermal penetration. Further, adding topical corticosteroids reduces the irritative effects of hypopigmenting agents, and

inhibits melanin synthesis by decreasing cellular metabolism.⁶ This combination, HQ 5%, tretinoin 0.1%, and dexamethasone 0.1%, was first introduced in 1975 and termed the Kligman formula after its inventor. It has been the most extensively used combination therapy for melasma worldwide.³⁴

More recently, results from a multicenter, randomized, double-blind control trial demonstrated that a new combination of HQ 4%, tretinoin 0.05%, and fluocinolone acetonide 0.01% (Tri-Luma[®], Galderma) proved better than any combination of two of the above agents, with 77% of patients showing complete or nearly complete clearing. Clinically significant improvement was noted as early as 4 weeks with maximum results at 8 weeks. The most common adverse effects were mild local irritation, erythema, and skin peeling.³⁵ The mixture should be applied to the entire affected area to avoid blotchiness. The recent 2006 consensus of the Pigmentary Disorders Academy (PDA), a group of international dermatologists and leaders in pigmentary disorders who receive sponsorship from Galderma, supported the use of triple therapy.

The PDA consensus suggested that first-line therapy for melasma should consist of fixed topical therapies and only when triple combination therapy is unavailable or patients have a sensitivity to the ingredients, should dual ingredients or single agents be considered.⁶

Over-the-Counter Products

Over-the-counter (OTC) products are readily available, and many patients have already tried these measures prior to consulting a dermatologist. At the present time the available concentrations of HQ for OTC use are not as efficacious as prescription formulations.³⁶ Alpha and beta hydroxy acid home chemical peels and topical vitamin A are also available.

The combination of N-acetyl glucosamine (NAG) and niacinamide (Olay[®] Definity[®]) was recently shown to reduce facial hyperpigmentation in Japanese and Caucasian subjects with facial hyperpigmentation in two double-blind, vehicle-controlled, split-face, left-right randomized clinical studies.³⁷ In another double-blind, vehicle-controlled, full-face clinical study, a significant reduction in facial hyperpigmented spots was seen in patients with facial hyperpigmentation using the NAG 2% + niacinamide 4% formulation when compared with the vehicle regimen.³⁸ There were no adverse effects reported.

Miscellaneous Treatments

Other topical therapies have been used including ascorbic acid, licorice extract and, in the past, mercury.⁶

Treatments			Quality of Evidence*	
Epidermal	Topical	Phenols (e.g., HQ)	B-C	
		Retinoids (e.g., tretinoin)	B-C	
		Azelaic Acid	B	
		Combination	HQ, retinoid, corticosteroid	A-B
			KA & GA	B
			HQ & GA	B
	Chemical Peels	Alpha hydroxy acids (GA)	B-C	
		Salicylic acid	C	
	Dermabrasion		E	
Laser Therapy		C-D		
Dermal	Pulsed CO ₂ laser followed by Q-switched alexandrite laser		C	

Table 2: Melasma Therapies. Similar therapies are used clinically to treat PIH. Note: for all therapies sunscreen use and UV avoidance is important.

*Quality of Evidence⁶

- A There is good evidence to support the use of this procedure.
- B There is fair evidence to support the use of this procedure.
- C There is poor evidence to support the use of this procedure.
- D There is fair evidence to reject the use of this procedure.
- E There is good evidence to reject the use of this procedure.

Treatment During Pregnancy

Treatment of melasma in pregnant women is routinely deferred until after delivery. This is because, first of all, melasma is more resistant to treatment because the hormonal trigger for it persists throughout pregnancy.³⁹ Second, therapy may be unnecessary since most women have a significant improvement in melasma after parturition. Third, therapy for melasma is contraindicated during pregnancy.

Treatment of PIH

Initial treatments for PIH should, if possible, manage and control the underlying skin condition.¹⁰ To lower the risk of PIH in patients with inflammatory conditions such as acne and atopic dermatitis, they should present early to a physician. As with melasma, sunscreen and sun avoidance are extremely important. Other treatment options are similar to those discussed above for melasma.² A clinical trial evaluated the effects of 0.1% tretinoin cream on PIH in patients with Type VI skin. Although significant lightening effects were seen, 50% of patients in the treatment group experienced moderate dermatitis.⁴⁰

Another PIH treatment study observed the addition of GA peels to a topical regimen of HQ 2%, GA 10% and tretinoin 0.05% cream in PIH patients with Type VI skin. This study showed improvement with peels and minimal adverse effects.⁴¹ However, as mentioned earlier, caution must be taken when performing peels on darker skinned patients because there is a higher risk of hyperpigmentation.³⁰

Conclusion

Hyperpigmentation, most commonly melasma and PIH, remain a therapeutic challenge. Multiple topical modalities can be used, and combination topical therapies are the current first-line approach.

References

1. Weismann K, Lorentzen HF. Dermoscopic color perspective. *Arch Dermatol* 142(9):1250 (2006 Sep).
2. Victor FC, Gelber J, Rao B. Melasma: a review. *J Cutan Med Surg*. 8(2):97-102 (2004 Mar-Apr).
3. Cayce KA, Feldman SR, McMichael AJ. Hyperpigmentation: a review of common treatment options. *J Drugs Dermatol* 3(6):668-73 (2004 Nov-Dec).
4. Anderson RT, Rajagopalan R. Development and validation of a quality of life instrument for cutaneous diseases. *J Am Acad Dermatol* 37(1):41-50 (1997 Jul).
5. Finlay AY. Quality of life measurement in dermatology: a practical guide. *Br J Dermatol* 136(3):305-14 (1997 Mar).
6. Rendon M, Berneburg M, Arellano I, Picardo M. Treatment of melasma. *J Am Acad Dermatol* 54(5 Suppl):S272-81 (2006 May).
7. Wolff K, Johnson RA, Szuurmond D. *Fitzpatrick's Color Atlas and Synopsis of Clinical Dermatology*. Toronto: McGraw-Hill (2005).
8. Bologna JL, Jorizzo JL, Rapini RP. *Dermatology*. Toronto: Mosby (2003).
9. Johnston GA, Sviland L, McLelland J. Melasma of the arms associated with hormone replacement therapy. *Br J Dermatol* 139(5):932 (1998 Nov).
10. James WD, Berger TG, Elston DM. *Andrews' Diseases of the Skin Clinical Dermatology*. Tenth Edition. Toronto: Saunders Elsevier (2006).
11. Pandya AG, Guevara IL. Disorders of hyperpigmentation. *Dermatol Clin* 18(1):91-8 (2000 Jan).
12. Pathak MA, Fitzpatrick TB, Kraus EW. Usefulness of retinoic acid in the treatment of melasma. *J Am Acad Dermatol* 15(4 Pt 2):894-9 (1986 Oct).
13. Palumbo A, d'Ischia M, Misuraca G, Prota G. Mechanism of inhibition of melanogenesis by hydroquinone. *Biochem Biophys Acta* 1073(1):85-90 (1991 Jan).
14. Jimbow K, Obata H, Pathak MA, Fitzpatrick TB. Mechanism of depigmentation by hydroquinone. *J Invest Dermatol* 62(4):436-49 (1974 Apr).
15. Barrientos N, Ortiz-Frutos J, Gomez E, Iglesias L. Allergic contact dermatitis from a bleaching cream. *Am J Contact Derm* 12(1):33-4 (2001 Mar).
16. Romaguera C, Grimalt F. Dermatitis from PABA and hydroquinone. *Contact Dermatitis* 9(3):226 (1983 May).
17. Camarasa JG, Serra-Baldrich E. Exogenous ochronosis with allergic contact dermatitis from hydroquinone. *Contact Dermatitis* 31(1):57-8 (1994 Jul).
18. Haddad AL, Matos LF, Brunstein F, Ferreira LM, Silva A, Costa D Jr. A clinical, prospective, randomized, double-blind trial comparing skin whitening complex with hydroquinone vs. placebo in the treatment of melasma. *Int J Dermatol* 42(2):153-6 (2003 Feb).
19. Ennes SB, Paschoalick RC, Mota De Avelar Alchorne M. A double-blind, comparative, placebo-controlled study of the efficacy and tolerability of 4% hydroquinone as a depigmenting agent in melasma. *J Dermatolog Treat* 11(3):173-9 (2000 Sep).
20. DeCaprio AP. The toxicology of hydroquinone – relevance to occupational and environmental exposure. *Crit Rev Toxicol* 29(3):283–330 (1999 May).
21. Mahé A, Ly F, Perret JL. Systemic complications of the cosmetic use of skin-bleaching products. *Int J Dermatol* 44(Suppl 1):37-8 (2005 Oct).
22. Romero C, Aberdam E, Larnier C, Ortonne JP. Retinoic acid as modulator of UVB-induced melanocyte differentiation. Involvement of the melanogenic enzymes expression. *J Cell*

23. Griffiths CE, Finkel LJ, Ditre CM, Hamilton TA, Ellis CN, Voorhees JJ. Topical tretinoin (retinoic acid) improves melasma. A vehicle-controlled, clinical trial. *Br J Dermatol* 129(4):415-21 (1993 Oct).
24. Grimes PE. Melasma. Etiologic and therapeutic considerations. *Arch Dermatol* 131(12):1453-7 (1995 Dec).
25. Shroot B. Pharmacodynamics and pharmacokinetics of topical adapalene. *J Am Acad Dermatol* 39(2 Pt 3):S17-24 (1998 Aug).
26. Leenutaphong V, Nettakul A, Rattanasuwon P. Topical isotretinoin for melasma in Thai patients: a vehicle-controlled clinical trial. *J Med Assoc Thai* 82(9):868-75 (1999 Sep).
27. Nazzaro-Porro M. Azelaic acid. *J Am Acad Dermatol* 17(6):1033-41 (1987 Dec).
28. Fitton A, Goa KL. Azelaic acid. A review of its pharmacological properties and therapeutic efficacy in acne and hyperpigmentary skin disorders. *Drugs* 41(5):780-98 (1991 May).
29. Balina LM, Graupe K. The treatment of melasma. 20% azelaic acid versus 4% hydroquinone cream. *Int J Dermatol* 30(12):893-5 (1991 Dec).
30. Cayce KA, McMichael AJ, Feldman SR. Hyperpigmentation: An overview of the common afflictions. *Dermatol Nurs* 16(5):401-6, 413-16 (2004 Oct).
31. Lim JT. Treatment of melasma using kojic acid in a gel containing hydroquinone and glycolic acid. *Dermatol Surg* 25(4):282-4 (1999 Apr).
32. Garcia A, Fulton JE Jr. The combination of glycolic acid and hydroquinone or kojic acid for the treatment of melasma and related conditions. *Dermatol Surg* 22(5):443-7 (1996 May).
33. Guevara IL, Pandya AG. Safety and efficacy of 4% hydroquinone combined with 10% glycolic acid, antioxidants, and sunscreen in the treatment of melasma. *Int J Dermatol* 42(12):966-72 (2003 Dec).
34. Kligman AM, Willis I. A new formula for depigmenting human skin. *Arch Dermatol* 111(1):40-8 (1975 Jan).
35. Taylor SC, Torok H, Jones T, et al. Efficacy and safety of a new triple-combination agent for the treatment of facial melasma. *Cutis* 72(1):67-72 (2003 Jul).
36. Halder RM, Richards GM. Topical agents used in the management of hyperpigmentation. *Skin Therapy Lett* 9(6):1-3 (2004 Jun-Jul).
37. Bissett D, Robinson LR, Li J, et al. Topical N-acetyl glucosamine reduces the appearance of hyperpigmented spots on human facial skin. Presented at: the 64th Annual Meeting of the American Academy of Dermatology, San Francisco, CA; March 3-7, 2006. Poster #236.
38. Kimball AB, Bissett DL, Robinson LR, et al. Topical formulation containing N-acetyl glucosamine and niacinamide reduces the appearance of hyperpigmented spots on human facial skin. Presented at: the 64th Annual Meeting of the American Academy of Dermatology, San Francisco, CA; March 3-7, 2006. Poster #235.
39. Nussbaum R, Benedetto AV. Cosmetic aspects of pregnancy. *Clin Dermatol* 24(2):133-41 (2006 Mar-Apr).
40. Bulengo-Ransby SM, Griffiths CE, Kimbrough-Green CK, et al. Topical tretinoin (retinoic acid) therapy for hyperpigmented lesions caused by inflammation of the skin in black patients. *N Engl J Med* 328(20):1438-43 (1993 May).
41. Burns RL, Prevost-Blank PL, Lawry MA, Lawry TB, Faria DT, Fivenson DP. Glycolic acid peels for postinflammatory hyperpigmentation in black patients. A comparative study. *Dermatol Surg* 23(3):171-4 (1997 Mar).

Get more clinical information at

www.SkinTherapyLetter.ca

A Physician's site for:

A-Details : Online Drug Presentations

Skin Therapy Letter® Articles

Meeting Abstracts and Proceedings

Refer your patients for self-help to www.SkinCareGuide.ca or any of the following sites:

AcneGuide.ca	EczemaGuide.ca	FungalGuide.ca	HerpesGuide.ca
RosaceaGuide.ca	SkinCancerGuide.ca	PsoriasisGuide.ca	PsoriaticArthritisGuide.ca
BotoxFacts.ca	Lice.ca	MildCleanser.ca	MohsSurgery.ca
Dermatologists.ca	ColdSores.ca	Sweating.ca	DermatologyCare.ca
SkinPharmacies.ca		SkinTherapyLetter.ca	

We welcome your comments and suggestions. Please e-mail us at physicians@skincareguide.com

Fractional Laser Treatment for Pigmentation and Texture Improvement

Z. Rahman, MD¹; M. Alam, MD, MSCI²; J. S. Dover, MD, FRCPC, FRCP³⁻⁵

¹Stanford University, Stanford, USA

²Section of Cutaneous and Aesthetic Surgery, Department of Dermatology, Northwestern University, Chicago, USA

³SkinCare Physicians of Chestnut Hill, Chestnut Hill, USA

⁴Department of Medicine (Dermatology), Dartmouth Medical School, Hanover, USA

⁵Department of Dermatology, Yale University School of Medicine, New Haven, USA

ABSTRACT

Fractional laser treatment with the 1,550nm erbium fiber laser (Fraxel® Laser, Reliant Technologies) has bridged the gap between the ablative and nonablative laser modalities used to treat the epidermal and dermal signs of skin aging. By targeting water as its chromophore, the laser induces a dense array of microscopic, columnar thermal zones of tissue injury that do not perforate or impair the function of the epidermis. The significant skin remodeling that ensues can be used to treat, with limited downtime, epidermal pigmentation, melasma, and rhytides, as well as textural abnormalities that include acne-related and surgical scars.

Key Words: *ablative laser, pigmentation, textural abnormalities, photoaging, acne scars, surgical scars*

Although ablative laser modalities remain the gold standard for the treatment of photoaging, most patients cannot tolerate the 1–2 weeks of downtime required with these procedures. Additionally, ablative skin treatment carries the risks of pigmentary alteration, infection, and scarring. At the other end of the spectrum, nonablative modalities induce collagen remodeling through deep dermal heating, yet have no epidermal resurfacing effect.

The Fraxel® Laser is a 30watt, diode pumped, 1,550nm erbium fiber laser that targets water as its chromophore. Utilizing the concept of fractional treatment 70–100µm wide and 250–800µm deep, microthermal zones (MTZs) of tissue coagulation are produced. Tissue is not vaporized and the stratum corneum remains intact. The epidermal coagulated tissue is expelled and replaced by keratinocyte migration. When there is significant damage to the basement membrane zone, dermal contents are also expelled as microscopic epidermal and dermal necrotic debris (MENDs). In this way, epidermal and dermal pigmentation can be treated without specifically targeting melanin as the chromophore. Zones of collagen denaturation in the dermis cause upregulation of the inflammatory cascade, which leads to collagen remodeling and new collagen formation.

In the first study of the fractional laser, 15 subjects received treatments of varying densities at test sites on the distal forearm. Biopsies were taken from the

treated tissue at intervals of 48 hours, 1 week, 1 month, and 3 months in order to identify MTZs and to characterize the wound healing process.¹ This data supported the use of the device for coagulation of soft tissue and, in November 2003, the US FDA approved it for that purpose. Since then, the fractional laser device has received additional FDA clearance for the treatment of periorbital rhytides, pigmented lesions, melasma, skin resurfacing, acne scars, and surgical scars.

The fractional laser contains an intelligent optical tracking system that utilizes OptiGuide Blue™ tint, a water soluble FDC dye. The optical mouse in the laser handpiece recognizes subtle differences in the density of blue dye on the skin's dermatoglyphs. The mouse communicates with the laser to lay down an even MTZ spot pattern independent of handpiece velocity. This system allows for a more even placement of MTZs, which is important in fractional tissue treatment where the optimal spacing between lesions allows for rapid re-epithelialization and prevents negative sequelae associated with fully ablative treatment at depths of 300–800µm. The dye can be challenging to remove in patients with enlarged pores or with hyperkeratotic lesions, such as actinic keratoses. The use of a dimethicone-based sealant prior to blue dye application can assist in removal of the dye. Blue dye is best removed with a foam-based skin cleanser that increases the surface area of the surfactant in contact with the skin.

Pain Management

Pain management is one of the most significant hurdles of the procedure. Discomfort from the laser treatment is managed by use of topical anesthetics, e.g., LMX-5[®], EMLA[®] (AstraZeneca), and other lidocaine/tetracaine formulations, such as 7% lidocaine/ 7% tetracaine (S-Caine[™], ZARS), prior to procedure.

Forced air cooling (Zimmer Cryo 5[®], Zimmer Medizin Sytems), which is often used concurrently with fractional laser treatment,² increases patient comfort significantly. Histologic analysis reveals a slight reduction in thermal damage zone width, but no statistically significant change in lesion depth. Forced cooled air should be used at the lowest possible setting to minimize alteration in the MTZs. When treating for superficial indications such as pigmentation and melasma, Zimmer settings should be 1–2. When treating deeper indications such as deep rhytides or scars, higher forced air settings, in combination with higher laser settings, may be used.

Oral anxiolytics and analgesics may be required in a small minority of patients who cannot tolerate the procedure with topical anesthetic alone.

Treatment Protocols by Indication

The current recommended treatment protocols are listed in Table 1. Important concepts to consider when using the fractional laser device are treatment energy, density, coverage, volume of tissue treated, and treatment intervals. The first three concepts, energy, density, and coverage, are closely related. The depth and width of the MTZs are proportional to energy. These are displayed in Figures 1 and 2. In order to achieve the desired coverage, densities should be lowered for higher energy treatments. For example, a 10mJ, 2,000MTZ/cm² treatment and a 20mJ, 1000MTZ/cm² treatment both have 20% coverage.

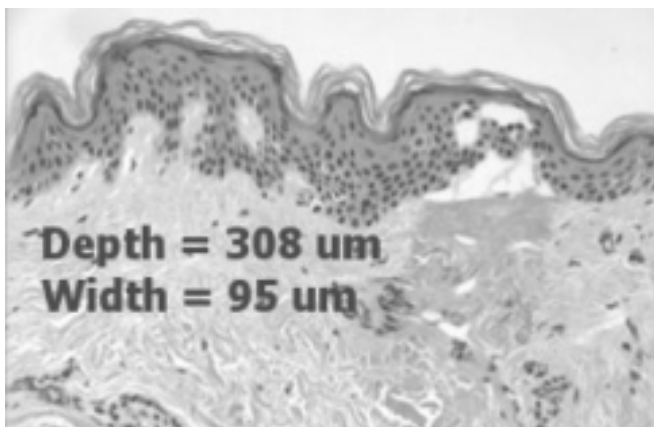


Figure 1: Depth coagulation at 8mJ

However, the 20mJ treatment results in twice the volume of tissue treated. This is important when treating deeper indications such as scars or deep rhytides. Treatments can be spaced as close as 1 week and as far apart as 6 weeks. Higher energy treatments should be spaced every 2–4 weeks.

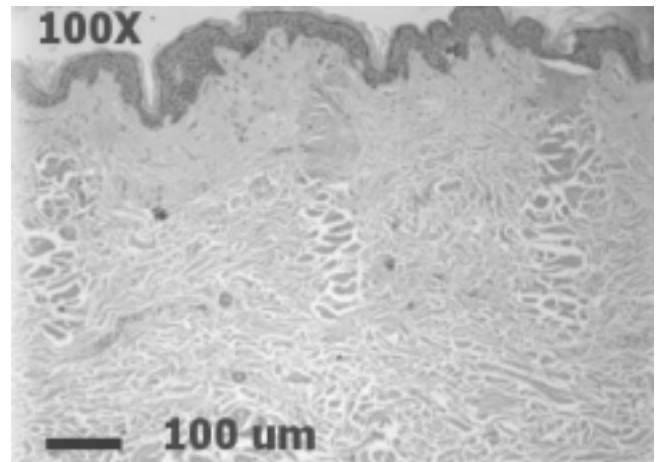


Figure 2a: Depth coagulation at 20mJ, 100X magnification

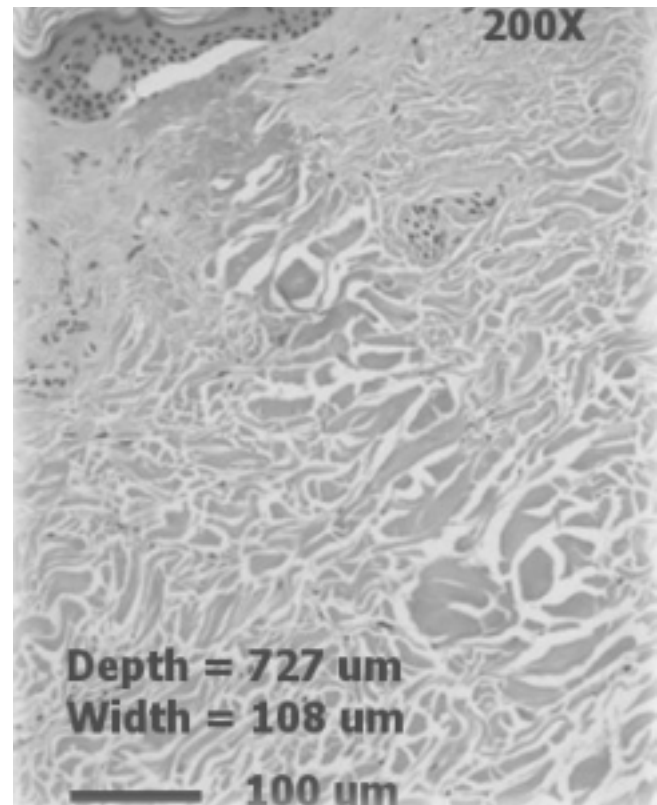


Figure 2b: Depth coagulation at 20mJ, 200X magnification

The energy counter on the machine allows the user to determine whether an adequate treatment has been performed. The calculations require knowledge of treatment energy, surface area treated, and total number of kJs used. On average, a full face treatment requires 5–8kJ.

Application	Energy	Treatment Density (MTZ/cm ²)	Pass Density (MTZ/cm ²)	Number of Passes	Coverage
Melasma	6mJ	1000	250	4	5%
		1500	250	6	7%
		2000	250	8	10%
	8mJ	1500	250	6	10%
		2000	250	8	14%
		3000	250	12	22%
Off-Face Resurfacing	8-10mJ	1500	250	6	10-14%
		2000	250	8	14-19%
		3000	250	12	22-29%
Mild-to-Moderate Rhytides* and Pigmentation (Glogau II-III)	8-10mJ	1500	250	6	10-14%
		2000	250	8	14-19%
		2500	250	10	20-24%
	12mJ	1250	125	10	15%
		1500	250	6	18%
		2000	250	8	24%
Severe Rhytides* and Pigmentation (Glogau IV)Scars**	15mJ	1000	125	8	15%
		1250	125	10	19%
		1500	125	12	23%
	20-25mJ	750	125	6	14-16%
		1000	125	8	19-22%
		1250	125	10	24-27%

Table 1: The current recommended treatment settings based on indication for the fractional laser device.

COVERAGE:	LOW	MID	HIGH
-----------	-----	-----	------

*Presently FDA cleared for periorbital wrinkles

** Presently FDA cleared for acne scars and surgical scars

Photodamage, Including Pigmentation and Rhytides

Treatment of dynamic wrinkles should include a combination approach, limiting muscle movement through the injection of neuromodulators. One “targeted” treatment for photodamage of the face uses higher energies in areas of deeper rhytides, such as in the perioral or periorbital region.³ The forehead, cheeks, and nose can be treated at lower energies. Off-face resurfacing should be performed at lower energies, as well, except when treating acne scars or other indications requiring deeper penetration. Treatment algorithms can be tailored to suit patient expectations and the targeted

indication. A greater number of “gentler” treatments (5+) with less downtime are required to achieve the same cumulative results as fewer (perhaps 4) “high-level” treatments that entail greater downtime. The probability of achieving 100% tissue coverage is far greater with five 20% treatments than with ten 10% treatments. This is due to the probability of targeting the same site with subsequent treatments. Clinical photographs of two patients reveal improvement of pigmentation and rhytides following a series of Fraxel® treatments. (See Figures 3, 4, and 5.)

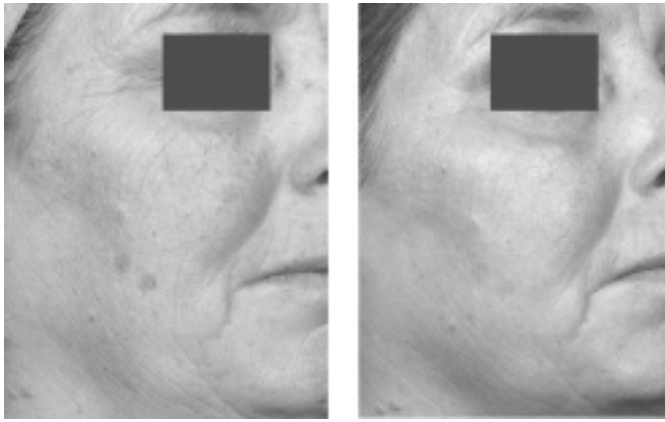


Figure 3: Treatment to improve pigmentation and rhytides using the Fraxel® Laser at baseline and after 4 treatments at 8mJ, 2,500MTZ/cm². Perioral: 15mJ, 1,500MTZ/cm²

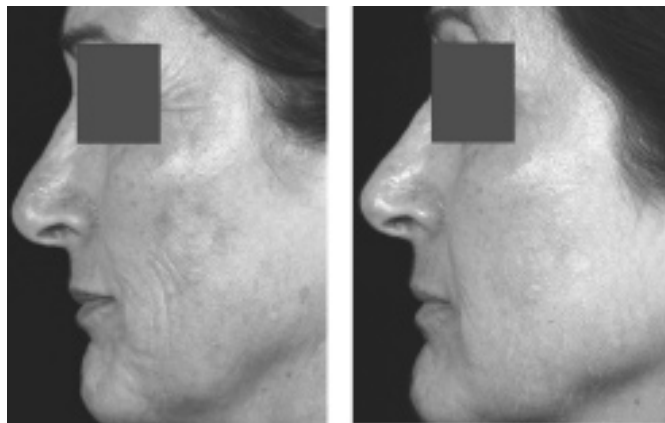


Figure 4: Treatment to improve pigmentation and rhytides using the Fraxel® Laser at baseline and after 4 treatments

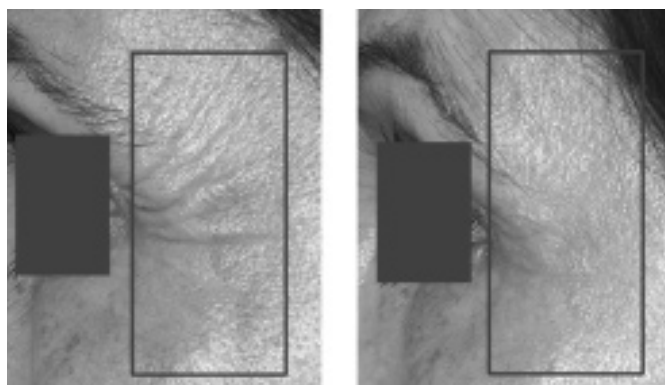


Figure 5: Treatment to improve pigmentation and rhytides using the Fraxel® Laser at baseline and after 4 treatments

Scars (Acne and Surgical)

Comparative data evaluating high vs. low energy treatments shows improved results with higher energy

treatments.⁴ Regardless of the energy used, the same percentage of the epidermis is treated. However, the use of high energies for deeper targets is based on the principle of a larger volume of tissue treated at higher energies. At equal surface area coverage of 20%, a 20mJ treatment treats twice the volume of tissue as a 10mJ treatment. This explains the greater efficacy seen for deep rhytides and acne scars with higher energy treatments. A clinical result of a Fitzpatrick skin type V patient undergoing treatment for acne scarring is shown in Figure 6.

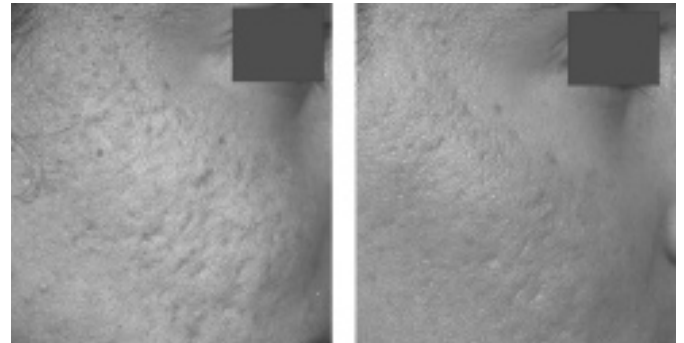


Figure 6: Treatment of acne scarring using the Fraxel® Laser at baseline and 1 month after 5 treatments q2wks, 15mJ, 1,500MTZ/cm²

Melasma

Results in the treatment of melasma are encouraging. Before this treatment is commenced, the underlying etiology and hormonal factors should be elucidated. All patients should be placed on a bleaching regimen, must practice strict sun avoidance, and use high SPF sunscreens. Retinoids should be stopped 1 week prior to treatment as they blunt the heat shock response, which is essential to rapid reepithelialization following tissue injury.

Ideally, patients should be treated monthly at low energies of 6–8mJ at 1,000-2,000MTZ/cm².⁵ Melasma patients usually require fewer total treatments. A regimen of 2–3 total treatments with a “touch-up” at 6 months is commonly prescribed, although touch-up treatments are not always necessary. There is a risk of postinflammatory change, particularly in those patients who have hyperactive melanocytes. In our experience, the postinflammatory changes that occur following treatment are likely more homogeneous and better tolerated than the mottled, uneven pigmentation of melasma. Melasma can be recurrent, particularly when the causative melanocytes and hormonal profile are present.

Side-effects and Postoperative Care

Postoperatively, patients can apply sunscreen and/or makeup. There is no oozing because there is no disruption in the stratum corneum, however some patients may experience excessive desquamation and even some crusting following an aggressive treatment. The majority of patients experience some degree of erythema, which resolves within 2–3 days following a gentle to modestly aggressive treatment. Erythema may persist for up to 1 week after more aggressive treatments.

Post-treatment edema is very patient-dependent. Some have little swelling. The average patient experiences edema for 1–3 days; <5% of patients have swelling for up to 1 week. The risk of edema also increases with higher level treatments. The majority of patients do well by applying ice at 10 minute intervals for the first 24 hours after treatment, and by sleeping on extra pillows. Although some physicians advocate the use of topical or short course systemic corticosteroids following treatment, the inflammatory cascade that leads to subsequent upregulation of collagen production may be best left unaltered.

There is always a risk of postinflammatory pigmentary alteration following any type of inflammatory process in the skin, and fractional laser treatments are no exception. Our own experience indicates an approximately 10%–12% incidence of hyperpigmentation after fractional treatments. This is most common in patients with a history of postinflammatory hyperpigmentation (PIH) or melasma. PIH is more common in patients of darker skin types (IV–V). A precautionary 6-week pretreatment with hydroquinone and a strict sun-protection regimen are advisable for these individuals.

Bulk heating can result from treating too large a fraction of the skin at one time, or from inadequate cooling between laser passes. To reduce this risk, the density of MTZs per pass should be halved to 125MTZ/cm² when using energies above 15mJ. Treating a small area without allowing the skin to cool between passes can lead to bulk heating, even at lower energies. Treatment of >35%–40% of the skin in a single session may lead to adverse sequelae. Maintaining sufficient normal tissue between the deep zones of coagulated epidermis and dermis is essential for rapid healing following fractional treatments.

Conclusions

Fractional laser resurfacing is a safe and effective modality for the treatment of epidermal pigmentation and wrinkles associated with photoaging, melasma, and

acne scars. Two years of clinical data and studies have allowed for optimization of treatment parameters with improved patient outcomes. In comparison with traditional ablative modalities, fractional laser treatment may be used to resurface any nonfacial part of the body, but is particularly useful on the neck, chest, and hands. For selected applications, fractional laser treatments may have greater efficacy than some other nonablative modalities; however, they have a similar, limited downtime.

References

1. Manstein D, Herron GS, Sink RK, Tanner H, Anderson RR. Fractional photothermolysis: a new concept for cutaneous remodeling using microscopic patterns of thermal injury. *Lasers Surg Med* 34(5):426-38 (2004).
2. Fisher GH, Kim KH, Bernstein LJ, Geronemus RG. Concurrent use of a handheld forced cold air device minimizes patient discomfort during fractional photothermolysis. *Dermatol Surg* 31(9 Pt 2):1242-4 (2005 Sep).
3. Rahman Z, Rokhsar CK, Tse Y, Lee S, Fitzpatrick R. The treatment of photodamage and facial rhytides with fractional photothermolysis. *Lasers Surg Med* 36(suppl 17):32 (2005).
4. Rahman Z, Tanner H, Jiang K. Treatment of atrophic scars with the 1550nm erbium-fiber fractional laser. *Lasers Surg Med* 38(suppl 18):24 (2006).
5. Tannous ZS, Astner S. Utilizing fractional resurfacing in the treatment of therapy-resistant melasma. *J Cosmet Laser Ther* 7(1):39-43 (2005 Mar).

~Conference News~

The Third Annual Meeting of Advances in Cosmetic & Medical Dermatology

January 17-22, 2007

Wailea Marriot Resort, Maui, Hawaii

Medical Dermatology

- Melanoma & Non-Melanoma Skin Cancer
- Biologics
- Collagen Vascular Diseases
- Infectious Diseases
- Pediatric Dermatology
- Controversial topics in Dermatology

Cosmetic Dermatology

- Botulinum Toxin A
- Fillers
- Lasers
- Management of Venous Disease

Seminars

- Practice Management & Coding Strategies
- Legal-Risk Management
- Ethics

Workshops

- Biologics
- Cutaneous Oncology
- Lasers
- Botulinum Toxin A
- Fillers
- Sclerotherapy

**For more information and to register go to
<http://www.acmd-derm-hawaii.com>
Deadline for registration is December 15, 2006**

Class	Name/Company	Approval Dates and Comments
<i>Antifungal Agent</i>	Ketoconazole 2% Gel <i>Xolegel™</i> Barrier Therapeutics	The US FDA approved this antifungal agent in July 2006 for the topical treatment of seborrheic dermatitis in immunocompetent adults and children >12 years of age. Xolegel™ is the first prescription gel formulation of ketoconazole approved in the US.
<i>Antipsoriatic Agent</i>	Infliximab <i>Remicade®</i> Centocor	The US FDA approved this antiTNF- α agent in September 2006 for the treatment of adult patients with chronic severe (i.e., extensive or disabling) plaque psoriasis, who are candidates for systemic therapy and when other systemic therapies are medically less appropriate. The recommended dose is an infusion of 5mg/kg followed by additional doses at 2 and 6 weeks after the first infusion and then every 8 weeks thereafter.
<i>Vaccines</i>	Quadrivalent Human Papillomavirus Recombinant Vaccine <i>Gardasil™</i> Merck	The European Union approved this vaccine in September 2006 for use in children and adolescents aged 9-15 years and in adult females aged 16-26 years for the prevention of cervical cancer and high-grade cervical dysplasias/ precancers caused by human papillomavirus (HPV) types 6, 11, 16 and 18.
<i>Atopic Dermatitis Agent</i>	Desonide <i>Verdeso™ Foam 0.05%</i> Connetics	The US FDA approved this low-potency topical steroid for the treatment of mild-to-moderate atopic dermatitis. This product, previously referred to as Desilux™ is the first approved product formulated in Connetics' VersaFoam®-EF emulsion formulation foam vehicle.

Drug News

<i>Antiacne Agent</i>	In an October 2006 Dear Healthcare Professional letter from the US FDA and the iPLEDGE program, healthcare professionals and patients were notified of an update to iPLEDGE, a risk management program to reduce the risk of fetal exposure to isotretinoin (Accutane®, Hoffmann-La Roche). One element of the program will be eliminated: the 23 day lock-out period for males and females of nonchildbearing potential, which will allow these patients the ability to have a new prescription filled after the 7-day window has expired. However, both the patient and prescriber must complete the qualification process again to ensure the patient has met all qualification criteria, including confirming patient counseling in the iPLEDGE system. For additional information visit: http://www.ipledgeprogram.com/ .
<i>Melanoma</i>	A team of researchers has developed a model for estimating the 5-year risk of melanoma, which can be used by health professionals to identify individuals with a higher risk of this deadly skin cancer and to help them plan for potential interventions. The gender-specific model uses information on skin complexion and sun exposure, and a physical examination of the back and shoulders to estimate the probability of an individual developing the first primary melanoma. The model is designed for physicians to assess nonHispanic white men and women between 20 and 70 years of age. It is not intended to assess the risk of individuals with a prior melanoma or nonmelanoma skin cancer or for those with a family history of melanoma, because they are already recognized as being at higher risk. The tool is available at http://www.cancer.gov/melanomarisktool . Source: Fears TR, Guerry D 4th, Pfeiffer RM, et al. <i>J Clin Ocol</i> 24(22):3590-6 (2006 Aug).

Skin Therapy Letter® (ISSN 1201-5989) Copyright 2006 by SkinCareGuide.com. Skin Therapy Letter® is published 10 times annually by SkinCareGuide.com Ltd, 1107 – 750 West Pender, Vancouver, British Columbia, Canada, V6C 2T8. Managing Editor: Penelope Gray-Allan: meditor@skincareguide.com. All rights reserved. Reproduction in whole or in part by any process is strictly forbidden without prior consent of the publisher in writing. While every effort is made to see that no inaccurate or misleading data, opinion or statement appears in the Skin Therapy Letter®, the Publishers and Editorial Board wish to make it clear that the data and opinions appearing in the articles herein are the responsibility of the contributor. Accordingly, the Publishers, the Editorial Committee and their respective employees, officers and agents accept no liability whatsoever for the consequences of any such inaccurate or misleading data, opinion, or statement. While every effort is made to ensure that drug doses and other quantities are presented accurately, readers are advised that new methods and techniques involving drug usage, and described herein, should only be followed in conjunction with the drug manufacturer's own published literature. Printed on acid free paper effective with Volume 1, Issue 1, 1995.

Subscription Information. Annual subscription: Canadian \$94 individual; \$171 institutional (plus GST); US \$66 individual; \$121 institutional. Outside North America: US\$88 individual; \$143 institutional. We sell reprints in bulk (100 copies of the same article or more). For individual reprints, we sell photocopies of the articles. The cost is \$20 to fax and \$15 to mail. Prepayment is required. Student rates available upon request. Sales inquiries: business@skincareguide.com

www.SkinTherapyLetter.com
www.SkinTherapyLetter.ca