

Corneal epithelial map after Photorefractive Keratectomy with and without mitomycin-C

Shaabani Amirreza (✉ shaabani_amirreza@yahoo.com)

Farabi Eye Hospital <https://orcid.org/0000-0003-2425-7292>

Jabbarvand Mahmoud

Farabi Eye Hospital

Shahbazi Ahad

Farabi Eye Hospital

Research Article

Keywords: Corneal epithelial thickness, Mitomycin-C, Photorefractive Keratectomy

DOI: <https://doi.org/10.21203/rs.3.rs-444610/v1>

License: © ⓘ This work is licensed under a Creative Commons Attribution 4.0 International License.

[Read Full License](#)

Abstract

Purpose: To compare epithelial thickness before and after photorefractive keratectomy (PRK) with and without mitomycin-C (MMC).

Methods: Forty eyes treated with PRK for low myopia (less than -4.00 D) and low astigmatism (less than -2.00) were included in this interventional case series. The right eye of each patient assigned to receive intraoperative topical MMC% 0.02 for 15 to 30 seconds and other eye received equally balanced salt solution (control group). Epithelial thickness profile was analyzed before and 6 months postoperatively.

Results: Epithelial thickness map was analyzed in superior and inferior of the cornea within central 7 mm diameter. Maximum and minimum thickness was measured and the data were compared before and after PRK. The Superior, the inferior and the maximum epithelial thickness were significantly increased after surgery in both groups ($p < 0.05$). There was no significant difference in epithelial thickness profile between case and control group at baseline and 6-month post PRK. Final distance corrected visual acuity was similar in two groups. No case of corneal haze was observed during 6 months follow up visits.

Conclusion: Intraoperative MMC% 0.02 in PRK for low myopia patients did not change the epithelial thickness profile and refractive results, when compared with matched control eyes in 6 months follow up. It seems that MMC doesn't have a statistically significant impact in epithelial remodeling based on this data set.

Introduction

Photorefractive keratectomy (PRK) involves removing epithelium and epithelial basement membrane, followed by laser photoablation of the Bowman layer and anterior stroma [1]. It seems that the corneal epithelium restores its preoperative thickness without contributing significantly to the refractive changes after PRK [2]. There are several methods to measure corneal epithelial thickness including confocal microscopy, ultrasound, and optical coherence tomography (OCT) [3]. Reliability and repeatability of epithelial thickness measured by OCT has been shown in some studies [4].

Mitomycin-C (MMC) is a chemotherapeutic agent that has antiproliferative effects. It is an alkylating agent resulting in cross-linking of DNA. Intraoperative use of topical MMC for PRK has been considered an effective adjuvant treatment to limit the formation of subepithelial corneal haze, especially in high myopia patients [5].

Application of Mitomycin-C (MMC) during PRK has been using for many years by most of refractive surgeons in order to decrease the postoperative haze [6,7]. However, there are still some concerns regarding the use of intraoperative MMC. Some studies found concentration-dependent and duration-dependent keratocyte loss, corneal edema, anterior chamber penetration and endothelial cell loss due to MMC [8,9]. Furthermore, MMC might associated with a higher rate of corneal epithelial problems, such as delayed epithelial wound healing [10].

Corneal epithelial profile helps us to better understanding the anatomical and optical characteristics of the eye that improves the safety and accuracy of refractive surgery procedures. Due to controversial opinions about use of MMC after ablation surface in low myopia and considering the toxicity of MMC and its damage to the limbal stem cells and endothelium of the cornea [9], we have examined the effect of MMC use on the corneal epithelium and the incidence of corneal haze 6 months postoperatively.

Methods

This prospective interventional case series was conducted between February 2018 and March 2019 in Farabi eye hospital, Tehran, Iran. Informed consents were obtained from all cases. The study protocol adhered to the Declaration of Helsinki. Tehran University of Medical Sciences ethical board committee approved the study protocol.

Patients with low myopia (less than -4.00 D) and low astigmatism (less than -2.00) were included in this study. History of corneal pathology or surgery and the residual central corneal thickness of fewer than 400 microns were considered as exclusion criteria.

A complete ophthalmic examination including measurement of uncorrected distance visual acuity (UDVA), corrected distance visual acuity (CDVA) (using Snellen chart), subjective refraction, slit lamp biomicroscopy, Goldmann applanation tonometry and dilated fundus examination was performed at baseline in all patients.

Corneal epithelial thickness profile was measured using SD-OCT (RTVue-100; Optovue, Inc., Fremont, CA.). Each map is divided into 25 sectors, within central 7 millimeters. (Figure 1). The average epithelial thickness over the central 7 mm diameter in superior and inferior of the cornea and the maximum and minimum epithelial thickness and standard deviations were used in the analysis. The same examination and imaging were performed at 6-month post PRK. In addition, corneal haze was documented in follow-up visits.

Patients underwent uncomplicated PRK for myopia and/or astigmatism. The laser settings were based on manifest refractions. All PRK procedures were performed under topical anesthesia. The epithelium was gently removed with a blunt spatula in central 8 mm zone after application of 20% alcohol for 15 seconds. Photorefractive keratectomy was performed with Amaris1050RS laser (SCHWIND eye-tech-solutions, Kleinostheim, Germany) using a 6.3 mm ablation zone. Intraoperative MMC 0.02% was used for all right eyes (case group). MMC was applied for 10 seconds for each diopter of manifest refraction. The mean MMC time was 23 seconds. Ablations in left eyes (control group) was performed without MMC. The same experienced anterior segment surgeon [M.J] performed all PRK procedures. Postoperative drops were consisted of chloramphenicol eye drop (0.5%) four times a day for 1 week and betamethasone eye drop (0.5%) four times a day, gradually tapered over 2 months.

To present data, we used mean, standard deviation, median and range. To compare the two groups which were used in paired eyes, we used Wilcoxon signed rank test. Also, this test was used to assess the

change within groups. Statistical analysis was performed using SPSS software version 16.0 for windows (SPSS Inc., Chicago, IL, USA). Significance was set at 5% cut off.

Results

Forty eyes (20 patient) were enrolled in this study. The mean age of patients was 32.1 (range: 25 to 43) years and 61.5% of them were female. Baseline characteristics and ablation depth were similar in both groups (Table 1).

Considering all cases and controls mean baseline superior and inferior corneal epithelial thickness was 51.33 μm and 55.45 μm , respectively. Baseline corneal thickness profile was similar in study groups (Table 2).

The maximum and superior epithelial thickness was significantly increased after PRK in both groups ($p < 0.05$). The inferior epithelial thickness increased in control eyes ($p = 0.007$) (Table 3)

Baseline and 6-months postoperative thickness profile were compared between study groups in Table 2. There was no significant difference in any corneal thickness parameters between MMC and control groups ($p > 0.05$).

UDVA in all eyes was 20/20 after 6 months. None of cases showed corneal haze during 6-months follow-up visit.

Discussion

In this study, we evaluated the effect of MMC on epithelial thickness profile after PRK in low myopia and low astigmatism. Corneal epithelial thickness was significantly increased after PRK with or without using MMC. However, there was no significant difference between study groups after 6 months.

Evaluation of corneal epithelial thickness profile in our study demonstrated the mean baseline superior and inferior corneal epithelial thickness was 51.33 μm and 55.45 μm , respectively. These measurements are similar to previous reported range value (about 48 μm to 58 μm) [11]. As it shown before, we found that superior corneal epithelium is thinner than the inferior area.

The thorough indication of MMC during PRK has not been determined yet. Some studies suggested that postoperative haze is uncommon or minimal in patients with low myopia [12]. Others believe that an ablation depth of 50 to 75 μm is the cutoff point to define high-risk procedures that necessitate MMC application [13,14]. Therefore, using intraoperative MMC in eyes with low myopia is still controversial. A study showed that use of intraoperative MMC (0.02% for 15 s) in PRK for mild myopia (spherical equivalent - 0.75 to - 3.87 D) does not induce any significant changes in tear film index, total higher order aberrations, or haze compared to the placebo-treated contralateral eyes after 6 months follow up [15]. In

our investigation, final UDVA was 20/20 in all eyes and was not different between MMC cases and match controls. Moreover, no cases showed corneal haze after 6 months.

Corneal epithelial thickness will be change after excimer laser refractive surgery [2,11]. In this study, corneal epithelial thickness was increased after PRK with or without using MMC. Several investigations showed that corneal epithelial thickness increase up to 20% after PRK. This persistent increase continued to 1-year post PRK in some studies. However, there was no correlation between the epithelial thickening and postoperative refraction changes [11,16]. Chen et al. reported that corneal epithelial thickness increase up 3 months after PRK using MMC in 46 eyes [11]. Similar results have been shown in some other studies [16-18].

Our study suffers from small sample size and relatively short follow up period. However, most of cases with postoperative corneal haze were detected early during postoperative period [19].

In this study, we showed that the use of MMC in low myopia PRK ablation cause not a significant change in the epithelial thickness profile and refractive results after 6 months follow up. Since MMC has toxic effects on the cornea and epithelial map will not change without mitomycin use in low myopic PRK, the necessity of using MMC in PRK must be re-evaluate with more researchs.

Declarations

Funding

No funding

Conflicts of interest

Disclosure statement;

Amirreza Shaabani has nothing to disclose

Mahmoud Jabbarvand has nothing to disclose.

Ahad. Shahbazi has nothing to disclose.

Availability of data and material

All data are available to present

Code availability

Stated in the text

Authors' contributions

Stated in title page

Ethics approval

Tehran University of Medical Sciences ethical board committee approved the study protocol

Acknowledgement

None

References

1. Alió JL, Muftuoglu O, Ortiz D et al. Ten-year follow-up of laser in situ keratomileusis for myopia of up to -10 diopters. *Am J Ophthalmol*. 2008 Jan;145(1):46-54.
2. Moller-Pedersen T, Cavanagh HD, Petroll WM, Jester JV. Stromal wound healing explains refractive instability and haze development after photorefractive keratectomy: a 1-year confocal microscopic study. 2000 Jul;107(7):1235-45.
3. Yan Li, Ou Tan, Robert Brass, Jack L. Weiss, David Huang. Corneal Epithelial Thickness Mapping by Fourier-domain Optical Coherence Tomography in Normal and Keratoconic Eyes. *Ophthalmology*. 2012 December ; 119(12): 2425–2433.
4. Ma JX, Wang L, Weikert MP, Montes de Oca I, Koch DD. Evaluation of the Repeatability and Reproducibility of Corneal Epithelial Thickness Mapping for a 9-mm Zone Using Optical Coherence Tomography. *Cornea*. 2019 Jan;38(1):67-73.
5. Caroline Piva, Marcony R. Santhiago. Mitomycin C application in refractive surgery. *Rev Bras Oftalmol*. 2015; 74 (6): 403-6.
6. Ahmad Shojaei, Mohsen Ramezanzadeh, Saeed Soleyman-Jahi, Mina Almasi-Nasrabadi, Parisa Rezazadeh, Medi Eslani. Short-time mitomycin-C application during photorefractive keratectomy in patients with low myopia. *J Cataract Refract Surg* 2013; 39:197–203.
7. Arranz-Marquez E, Katsanos A, Kozobolis VP, Konstas AGP, Teus MA. A Critical Overview of the Biological Effects of Mitomycin C Application on the Cornea Following Refractive Surgery. *Adv Ther*. 2019 Apr;36(4):786-797.
8. Chang SW. Corneal keratocyte apoptosis following topical intraoperative mitomycin C in rabbits. *J Refract Surg*. 2005 Sep-Oct;21(5):446-53.
9. Chang SW. Early corneal edema following topical application of mitomycin-C. *J Cataract Refract Surg*. 2004 Aug;30(8):1742-50.
10. Kremer I, Ehrenberg M, Levinger S. Delayed epithelial healing following photorefractive keratectomy with mitomycin C treatment. *Acta Ophthalmol*. 2012 May;90(3):271-6.
11. Xiangjun Chen, Aleksandar Stojanovic, Yanhua Liu, Yunyun Chen, Yang Zhou, Tor Paaske Utheim. Postoperative Changes in Corneal Epithelial and Stromal Thickness Profiles After Photorefractive Keratectomy in Treatment of Myopia. *J Refract Surg*. 2015;31(7):446-453.

12. Spadea L, Giovannetti F. Main Complications of Photorefractive Keratectomy and their Management. *Clin Ophthalmol*. 2019 Nov 27;13:2305-2315.
13. Lacayo GO, Majmudar PA. How and when to use mitomycin-C in refractive surgery. *Curr Opin Ophthalmol*. 2005 Aug;16(4):256-9.
14. Lin N1, Yee SB, Mitra S, Chuang AZ, Yee RW. Prediction of corneal haze using an ablation depth/corneal thickness ratio after laser epithelial keratomileusis. *J Refract Surg*. 2004 Nov-Dec;20(6):797-802.
15. Mohammadi SF, Ashrafi E, Norouzi N, et al. Effects of mitomycin-C on tear film, corneal biomechanics, and surface irregularity in mild to moderate myopic surface ablation: preliminary results. *J Cataract Refract Surg*. 2014;40:937–42.
16. Ivarsen A, Fledelius W, Hjortdal J. Three-Year Changes in Epithelial and Stromal Thickness after PRK or LASIK for High Myopia. *IOVS*, May 2009, Vol. 50, No. 5.
17. Patel SV, Erie JC, McLaren JW, Bourne WM. Confocal microscopy changes in epithelial and stromal thickness up to 7 years after LASIK and photorefractive keratectomy for myopia. *J Refract Surg*. 2007 Apr;23(4):385-92.
18. Tomás-Juan J, Larranaga AM, Hanneken L. Corneal regeneration after photorefractive keratectomy: a review. *J Optom*. 2015;8(3):149-169.
19. Murueta-Goyena A, Cañadas P. Visual outcomes and management after corneal refractive surgery: A review. *J Optom*. 2018 Apr-Jun;11(2):121-129.

Tables

Table 1. Baseline and intraoperative characteristics in study groups

Variables	Case group (n=20)	Control group (n=20)	P Value*
Baseline manifest sphere (D)	-1.17 ± 1.61	-1.0 ± 1.7	0.794
Baseline manifest cylinder (D)	-0.92 ± 0.7	-.85 ± 1.04	0.845
Ablation depth (µm)	46.61 ± 19.72	45 ± 21.47	0.843

D= diopter

* Based on Paired Samples t-test

Table 2. Epithelial thickness profile at baseline and post PRK in study groups

	Variables	Case group (n=20)	Control group (n=20)	P value*
Baseline	Superior corneal epithelial thickness (µm)	50.89 ± 4.51	51.76 ± 4.12	0.17
	Inferior corneal epithelial thickness (µm)	55.3 ± 3.42	55.61 ± 3.52	0.677
	Maximum corneal epithelial thickness (µm)	59 ± 4.22	58.3 ± 3.4	0.126
	Minimum corneal epithelial thickness (µm)	46.07 ± 5.21	47.3 ± 3.32	0.070
6- months post PRK	Superior corneal epithelial thickness (µm)	52 ± 3.51	53.76 ± 4.71	0.251
	Inferior corneal epithelial thickness (µm)	56.84 ± 4.96	57.92 ± 4.27	0.601
	Maximum corneal epithelial thickness (µm)	62.3 ± 5.7	63.76 ± 5.61	0.796
	Minimum corneal epithelial thickness (µm)	44.53 ± 6.3	45.23 ± 5.05	0.549

* Based on Wilcoxon signed rank test.

Table 3. P value* for comparing baseline and post PRK values in each study group

Variables	Case group (n=20)	Control group (n=20)
Superior corneal epithelial thickness	0.038	0.006
Inferior corneal epithelial thickness	0.098	0.007
Maximum corneal epithelial thickness	0.027	0.001
Minimum corneal epithelial thickness	0.409	0.735

* Based on Wilcoxon signed rank test.

Figures

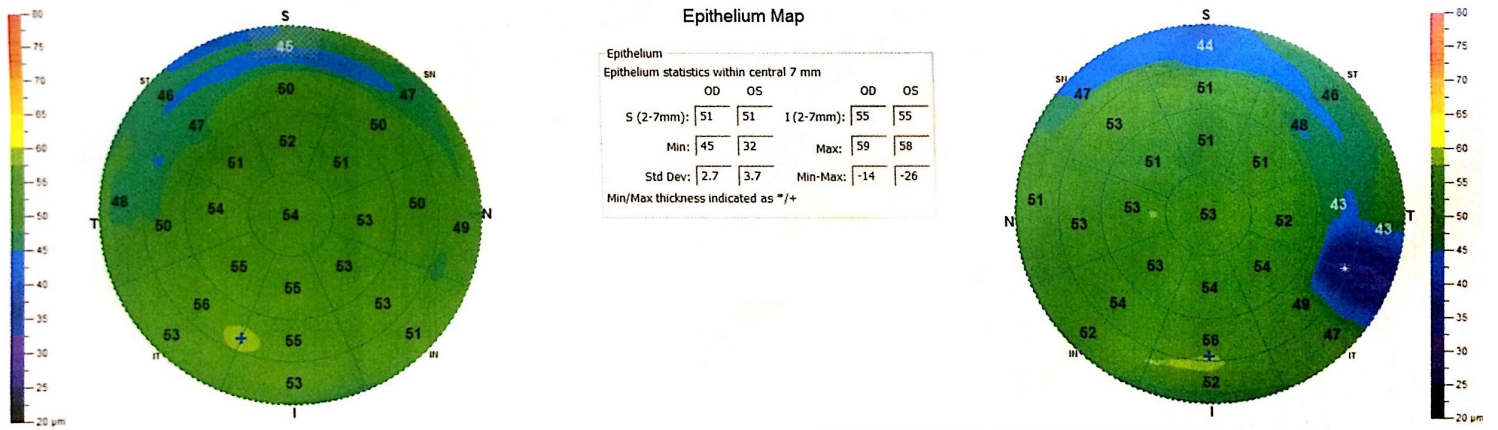


Figure 1

The data output of the spectral-domain optical coherence tomography measurement shows (left) right eye and (right) left eye corneal epithelial thickness profiles over the 7-mm diameter.




Figure 2

Preoperative epithelial thickness profile (μm) (top). Postoperative epithelial thickness profile (μm) (bottom). Note that right eye with intraoperative MMC and left eye without intraoperative MMC.