Radiology Case Reports

Volume 8, Issue 2, 2013

Transcatheter arterial embolization of a uterine artery pseudoaneurysm with Onyx® following D&C for uterine bleeding

Mark Wendel, MD; Michael Beheshti, MD; Muhammad Yousaf, MD; and Eren Erdem, MD

Transcatheter uterine artery embolization is well described and performed for treatment of symptomatic uterine leiomyomas, for postpartum hemorrhage, and for hemorrhage following hysterectomy. Embolic agents have included polyvinyl alcohol, gelfoam, coils, and Embospheres®. We present a case of severe uterine hemorrhage after a missed abortion (after two instances of dilatation and curettage), which could not be managed with traditional embolic techniques but was successfully controlled with Onyx®.

Case report

A 22-year-old gravida 3, para 2, a previously healthy white female, presented to her doctor with heavy uterine bleeding and received a diagnosis of missed abortion after workup. She underwent dilation and curettage (D&C), but continued to have uterine bleeding that resulted in a call to EMS and transport to a medical facility. The blood loss was estimated to be approximately 700 mL. She underwent a second D&C that resulted in more severe bleeding. An immediate sonogram demonstrated a mass in the endometrium, and high-color-flow Doppler signal was detected there as well, suggesting the possibility of a pseudoaneurysm. The patient was referred from an outside facility to the Interventional Radiology service for angiography with possible embolization, since she wanted to preserve fertility if possible.

A preprocedure MRI demonstrated a 1.2-cm pseudoaneurysm involving the left uterine artery; the endometrial mass was felt to represent a hematoma (Figs. 1, 2).

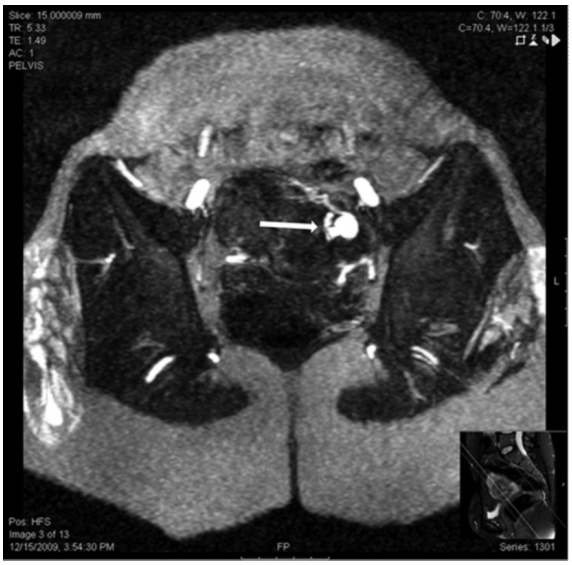

Figure 1. 22-year-old female with uterine artery pseudoaneurysm. MRI 3D MIP gradient image demonstrating the pseudoaneurysm in the left aspect of the uterus myometrium (white arrow).

Pelvic and select uterine artery injections also demonstrated a left uterine artery pseudoaneurysm (Fig. 3). During the study, active extravasation from the pseudoaneurysm to the hematoma was identified.

Citation: Wendel M, Beheshti M, Yousaf M, Erdem E. Transcatheter arterial emboiation of a uterine artery pseudoaneurysm with Onyx following D&C for uterine bleeding. *Radiology Case Reports*. (Online) 2013;8:630.

The authors are all at the University of Arkansas for Medical Scienes, Little Rock AK. Contact Dr. Wendel at wendelma@hotmail.com.

Competing Interests: The authors have declared that no competing interests exist.

DOI: 10.2484/rcr.v8i2.630

Figure 2. 22-year-old female with uterine artery pseudoaneurysm. Axial T1, fat-suppressed, post-contrast image demonstrates the pseudoaneurysm (white arrow) and surrounding hematoma (black arrow).

Owing to the size of the pseudoaneurysm and its location, we attempted to obtain proximal and distal control with embolization. Attempts to pass a Tracker (Target Therapeutics, Fremont, CA, USA) microcatheter distal to the pseudoaneurysm were complicated by development of a uterine-artery spasm.

A second attempt was successful with a flow-directed microcatheter, Marathon (ev3 Endovascular, Inc. Plymouth, MN), commonly used for intracranial vascular malformation catheterizations. An X-Pedion (ev3 Endovascular, Inc. Plymouth, MN) microwire successfully negotiated the microcatheter distal to the pseudoanerysm in the uterine artery. The angiogram obtained from the microcatheter revealed reflux of the contrast to the pseudoaneurysm from the distal artery (Fig. 4).

Figure 3. 22-year-old female with uterine artery pseudoaneurysm. Digital subtraction angiographic (DSA) image image demonstrates distal injection of the left uterine artery with backfilling of the pseudoaneurysm.

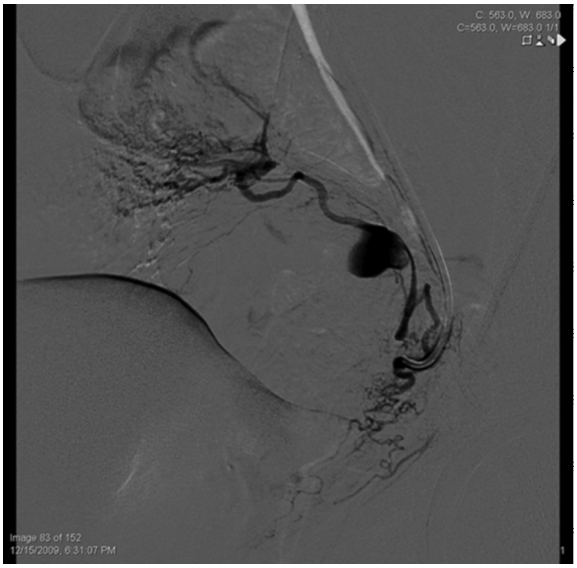

Figure 4. 22-year-old female with uterine artery pseudoaneurysm. DSA image demonstrates the uterine artery in spasm.

Figure 5. 22-year-old female with uterine artery pseudoaneurysm. DSA image demonstrates distal injection of the left uterine artery with backfilling of the pseudoaneurysm.

The inner diameter of the microcatheter is 0.013 in. and not suitable for thrombogenic coils to deliver; therefore, we decided to use Onyx 18 (ev3 Endovascular, Inc. Plymouth, MN) as the embolization agent. The Onyx® was slowly injected to occlude the uterine artery distal to the pseudo-

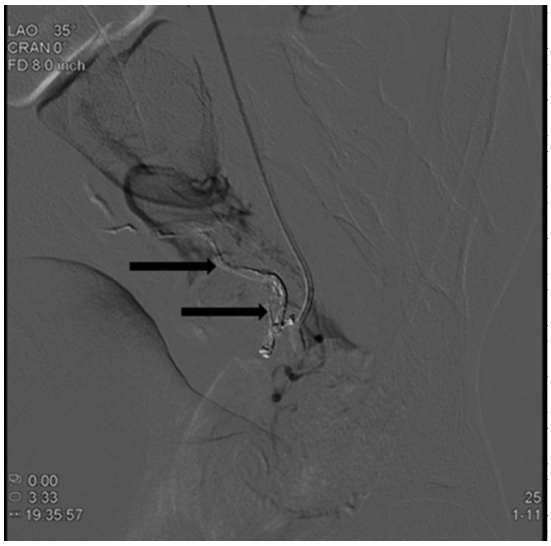

Figure 6. 22-year-old female with uterine artery pseudoaneurysm. DSA image demonstrates Onyx® slowly injected distal to the pseudoaneurysm to occlude the uterine artery and more proximally across the pseudoaneurysm. Note the Onyx® cast (black arrows).

aneurysm, at the site of the pseudoaneurysm, and more proximally with good control of the flow; this obliterated the parent artery without leakage into the pseudoaneurysm, thus avoiding mass effect in the myometrium (Fig. 5).

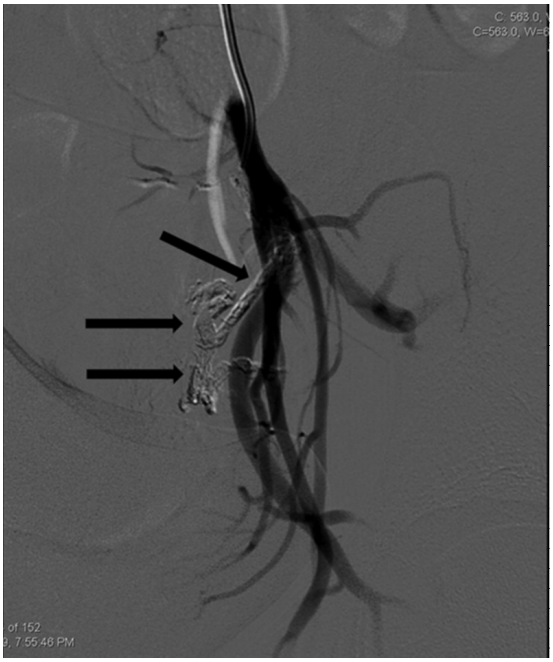

Figure 7. 22-year-old female with uterine artery pseudoaneurysm. Followup angiogram demonstrates good result without opacification of the pseudoaneurysm with contrast. Note the Onyx® cast (black arrows).

Followup angiography demonstrated a good result without opacification of the pseudoaneurysm with contrast (Figs. 6, 7). Delayed angiography of the right uterine artery demonstrated no cross-filling of the pseudoaneurysm (Fig. 8).

Figure 8. 22-year-old female with uterine artery pseudoaneurysm. Delayed angiogram of the right uterine artery demonstrates no cross-filling of the pseudoaneurysm.

The patient was admitted to the hospital following the procedure and had an uneventful hospital course with resolution of the hemorrhage. She experienced mild to moderate cramping during the night; the next morning, that was controlled with a 30mg dose of ketorolac and NSAIDs by mouth. She was discharged home the following day in good condition, with a two-week followup with her primary physician. She maintained a stable hematocrit level and had no further uterine bleeding at the time of followup.

Discussion

Uterine bleeding is usually treated with D&C following a missed abortion if serial quantitative β-hcg levels fail to drop at an appropriate rate. A second D&C may be performed if the elevated serum β-hcg persists. Definitive treatment of these conditions is often hysterectomy after conservative workup and treatment.

Pseudoaneurysm treatment with Onyx® has been described in the renal arteries by Rennert et al (1) and Zelenak et al (2) and in the subclavian artery by Amiridze, Trivedi, and Kshitij (3). 100% success of the procedure for embolization of the pseudoaneurysm is documented, with an average 21-month followup of no recurrence of renal bleeding or AV fistulas in the selected patients. Experiences of treatment of peripheral aneurysms in the internal iliac and thoracic collateral arteries and in peripheral pseudo-

aneurysms in a lumbar artery and a renal artery are described by Vanninen and Manninen while using a combination of Onyx® and a stent and Onyx® with balloon assistance (4).

Pseudoaneurysms of the uterine artery are well described in postpartum hemorrhage and after uterine curettage that can result in significant uterine bleeding; they are effectively treated with transcatheter arterial embolization (5). These are commonly discovered after the procedure when the hemorrhage fails to resolve; ultrasound of the pelvis demonstrates focal areas of increased color or swirling flow within the uterus or myometrium.

In a case report submitted by Padavala and Ahluwalia (6), pseudoaneurysm of the left uterine artery was discovered and treated with transcatheter arterial embolization with polyvinyl alcohol particles. Recurrence of the pseudoaneurysm occurred within 72 hours of the procedure that precipitated the hysterectomy.

Use of Onyx® for embolization in the uterine artery is not well described. The advantage of Onyx® compared to PVA particles is the permanence of the media and the good control of the Onyx® during delivery. The Onyx® is delivered under controlled injection with direct visualization of the polymer during application (instead of flow direction, as with PVA). The result of Onyx® application is a permanent solid plug that takes the shape of the vessel or defect it is injected into.

Immediately after injection into the bloodstream, Onyx® begins to solidify from the outside surface to the inside as the carrier solvent, DMSO (dimethyl-sulfoxide), dissipates into the blood. Onyx® must be injected through DMSO-compatible catheters (for example, Marathon TM, Echelon TM, Rebar®, or UltraFlow TM HPC - ev3 Endovascular, Inc. Plymouth, MN). Since Onyx® solidification occurs when injected into the bloodstream, multiple small controlled injections for a slow, controlled occlusion of the target vessel are possible. VanRooij, Sluzewski, and Beute (7) report possible procedure times greater than 60 minutes. Given the potential of a lengthy procedure, radiation dose must be considered.

Onyx® is available in two concentrations: Onyx 18 (6% EVOH) and Onyx 34 (8% EVOH). Onyx 34 has a higher viscosity than Onyx 18 and is commonly used for higher-flow conditions (such as those that occur in a nidus) or for larger-vessel diameters. The higher viscosity of Onyx 34 allows the building of an embolic base at the catheter tip before injection of Onxy 18 to gain control of the embolic target. Injection of Onyx 18 allows for more distal travel of Onyx® into smaller portions of the target vessels. The potential complications of liquid embolic agents are the same for Onyx® as for other liquid embolic agents, including nontarget embolization and the possibility of gluing the catheter to the vessel. An additional risk of skin discoloration is present if the embolization is near the skin surface, as Onyx® has a dark color. We used Onyx 18 for injection into the uterine-artery pseudoaneurysm because of the small vessel size and because it could penetrate more distally and prevent back-filling of the pseudoaneurysm from collateral vessels.

No long-term data is available for the effect on fertility after use of Onyx® in the uterine arteries.

References

1. Rennert J, Herold T, Schreyer AG, Banas B, Jung EM, Feuerbach S, Lenhart M, Mueller-Wille R, Zorger N. Evaluation of a liquid embolization agent (Onyx) for transcatheter embolization for renal vascular lesions. *Rofo*. 2009 181(10), 996-1001. [PubMed]
2. Zelenák K, Sopilko I, Svihra J, Kliment J. Successful embolization of a renal artery pseudoaneurysm with arteriovenous fistula and extravasations using onyx after partial nephrectomy for renal cell carcinoma. *Cardiovasc Intervent Radiol*. 2009 32:163-165. [PubMed]
3. Amiridze N, Trivedi Y, Dalal K. Endovascular rapair of subclavian artery complex peudoaneurysm and arteriovenous fistula with coils and onyx. *J Vasc Surg* 2009 50(2), 420-423. [PubMed]
4. Vanninen, RL, Manninen, I. Onyx, a new liquid embolic material for peripheral interventions: preliminary experience in aneurysm, pseudoaneurysm, and pulmonary arteriovenous malformation embolization. *Cardiovasc Intervent Radiol* 2007 30(2), 196-200. [PubMed]
5. Kwon, FH, Kim, GS. Obstretric iatrogenic arterial injuries of the uterus: diagnosis with US and treatment with transcatheter arterial embolization. *Radiographics* 2002 22:35-46. [PubMed]
6. Padavala, S. M. and Ahluwalia, A. Post-abortal bleeding due to uterine artery pseudoaneurysm. *J Obstet Gynaecol*, 2004 24(7), 834-835. [PubMed]
7. van Rooij, WJ, Sluzewski M, Beute GN. Brain AVM embolization with Onyx. *AJNR* 2007 28: 172-177. [PubMed]