

## ACUTE LIVER FAILURE CAUSED BY PARACETAMOL TOXICITY: A CASE REPORT

ALESSANDRO FEOLA\*, BRUNO DELLA PIETRA\*\*

\*Department of Biomedicine and Prevention, University of Rome "Tor Vergata", Via Montpellier 1, 00133 - Rome, Italy - \*\*Department of Experimental Medicine, Second University of Naples, Via Luciano Armanni 5, 80138 - Naples, Italy

---

### ABSTRACT

*This was a case of acute liver failure caused by paracetamol toxicity. The patient was a 54-year-old woman who self-medicated with paracetamol to treat a fever. She was admitted to hospital after 3 days of nausea, vomiting, and jaundice. After excluding viral hepatitis, diagnosis leaned towards hepatitis secondary to paracetamol, which was later confirmed by serum paracetamol levels (69.4 mg/L). Despite acetylcysteine therapy, the patient died after a few hours. Upon macroscopic examination at autopsy, diffuse congestion of the hepatic parenchyma with alterations to the normal structure and diffuse parenchymal necrosis were observed. Upon microscopic examination of hepatic tissue, features of hepatic centrilobular necrosis were present. From data reported in the literature, findings obtained from the clinical history and the anatomopathological evidence suggested that the death of the patient was attributable to accidental paracetamol poisoning.*

**Keywords:** acute liver failure, paracetamol, acetaminophen, adverse drug reaction, liver injury, poisoning.

DOI: 10.19193/0393-6384\_2017\_1\_008

---

Received September 30, 2016; Accepted November 02, 2016

### Introduction

Acute liver failure (ALF) is the clinical manifestation of sudden and severe hepatic injury. It is a rare disorder, with an incidence between one and six cases per million people every year in the developed world, and it has a high mortality rate<sup>(1)</sup>. There are many definitions of ALF, but it is mainly characterised by the presence of encephalopathy during the course of fulminant hepatitis in a patient without previously known hepatopathy<sup>(2)</sup>. The causes of ALF are many and vary in reason and geographic region<sup>(3)</sup>, but the main causes are viral hepatitis (in particular, hepatitis B virus and hepatitis A virus) and medication overdose, in particular, paraceta-

mol, but it can also occur with statins, non-steroidal anti-inflammatories, antibiotics (nitrofurantoin and ketoconazole), anti-epileptics (phenytoin and valproate), anti-tuberculosis drugs, particularly isoniazid, and other drugs such as propylthiouracil and disulfiram<sup>(1-3)</sup>.

In 13-17% of patients, ALF is attributed to an idiosyncratic drug reaction<sup>(4)</sup>. Rare causes are hyperthermic injury from heat shock or after a protracted seizure, toxic insults (poisoning with toxic mushroom species such as *Amanita* spp.), Wilson's disease, autoimmune hepatitis, ischaemic injury as a result of systemic hypotension with sepsis or cardiac failure, Budd-Chiari syndrome, malignant infiltration of the liver, or pregnancy-related dis-

eases<sup>(1-3)</sup>. The clinical management of ALF is difficult because the condition is rapidly progressive and leads to multi-organ failure with sudden and severe complications. It is very important to identify the cause of the liver injury to implement a specific therapy in addition to standard intensive care. Sometimes the severity of the case demands urgent decision-making regarding emergency liver transplantation<sup>(1)</sup>. The prognosis of ALF depends on different factors, such as sex, age, cause of failure, hepatic, clinical, and biological statuses upon admission, degree of hepatic encephalopathy, and other laboratory parameters<sup>(3)</sup>.

### Case presentation

A 54-year-old woman was admitted to the hospital of a small town near Naples, Italy. She complained of nausea and vomiting for the past 3 days and jaundice. At 14:30, the first laboratory analysis showed increased levels of serum creatinine (2.43 mg/dL), aminotransferases (aspartate aminotransferase (AST): 99 U/L; alanine aminotransferase (ALT): 36 U/L), and bilirubin (total: 3.40 mg/dL, direct: 1.22 mg/dL; indirect: 2.18 mg/dL), while there was a reduction in red blood cells ( $2.77 \times 10^6/\text{mm}^3$ ), haemoglobin (8.7 g/dL), and platelets ( $6000 \times 10^3/\text{mm}^3$ ). Over the following 2 hours, the patient showed a progressive elevation in aminotransferases (AST: 196 U/L; ALT: 153 U/L). Early the next morning, laboratory analysis showed a further and marked increase in aminotransferases (AST: 9930 U/L; ALT: 4460 U/L) and an elevation of the international normalised ratio to 2.

At that point, the patient began developing signs of renal failure and encephalopathy. Because of the severity of the case, the treating physicians decided to transfer the woman to a specialised hospital with a liver transplantation unit. Upon admission to the new hospital, the woman presented with grade III encephalopathy. To rule out any infectious diseases common in Naples, viral hepatitis markers were evaluated and were found to be negative. Some hours later, the patient's husband mentioned that she had ingested some paracetamol tablets a few days earlier to relieve symptoms of fever. Based on this new information, the doctors leaned towards a diagnosis of hepatitis secondary to paracetamol, and quantified serum paracetamol levels (69.4 mg/L). Therapy with acetylcysteine was started. Her clinical condition remained poor. In the evening, laboratory analysis showed metabolic aci-

dosis with elevated serum creatinine (2.8 mg/dL), aminotransferases (AST: 3994 U/L; ALT: 2518 U/L), and alteration of the international normalised ratio to 1.42. Additionally, there was a further reduction in red blood cells ( $2.01 \times 10^6/\text{mm}^3$ ), haemoglobin (6.3 g/dL), and platelets ( $5000 \times 10^3/\text{mm}^3$ ). In the subsequent hours, a blood transfusion was performed. Unfortunately, after sudden-onset bradycardia, the patient died.

### Autopsy findings

A complete post-mortem examination was performed 84 hours after the patient's death. Upon opening the abdomen, the peritoneum appeared smooth and glistening with an intracavitary effusion of about 500 cc of brownish-yellow liquid. At the level of the serosa of the hepatic flexure of the colon, there was slight haemorrhagic infiltration. The liver appeared to have normal shape, but with increased volume. The hepatic parenchyma appeared diffusely congested and with alterations to the normal structure and diffuse parenchymal necrosis (Fig. 1). The adrenal glands showed an initial framework of apoplexy. All other organs were characterised by congestion and oedema. The heart was removed in toto and fixed in formalin for further pathological examination.

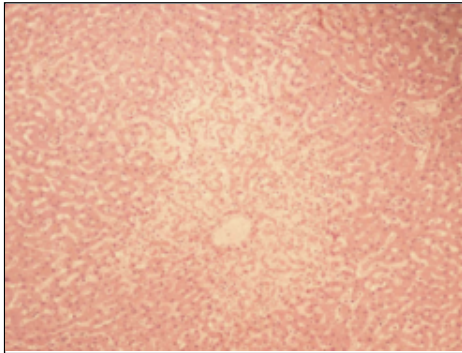


**Fig. 1:** Macroscopic examination of the liver showed diffuse parenchymal congestion with alterations to the normal structure and diffuse parenchymal necrosis.

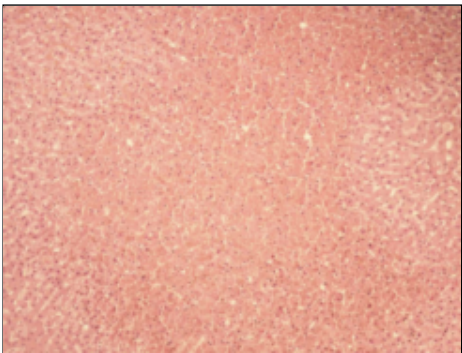
### Histopathological findings

Tissue samples taken at autopsy were prepared and embedded in paraffin wax, and 4- $\mu\text{m}$ -thick cross-sections were cut and stained with haematoxylin/eosin by standard methods. The heart was characterised by myocardial congestion and oedema, with areas of myofibrillar fragmentation and extravasation of blood between the myofibrils. The liver was strewn with multiple foci of centrilobular necrosis, partly confluent, with haemorrhagic

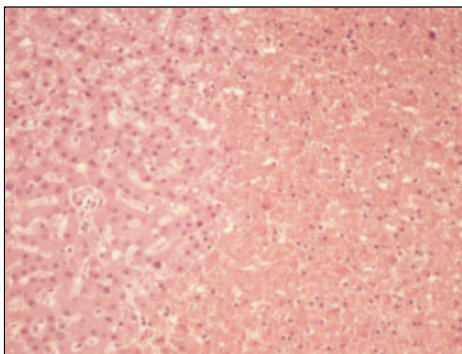
imprints (Fig. 2-4). Diffuse intra-hepatic cholestasis and microvesicular steatosis were present. The adrenal glands were congested and showed multiple areas of haemorrhage, partly confluent, in the medulla.



**Fig. 2:** Liver section stained with haematoxylin/eosin. Centrilobular necrosis is evident (magnification:  $\times 100$ ).



**Fig. 3:** Liver section stained with haematoxylin/eosin. Necrosis with haemorrhagic imprint is evident (magnification:  $\times 100$ ).



**Fig. 4:** Liver section stained with haematoxylin/eosin. Necrosis with haemorrhagic imprint is evident (magnification:  $\times 200$ ).

## Discussion

Edwards and Aronson defined ‘adverse drug reaction’ as: “an appreciably harmful or unpleasant reaction, resulting from an intervention related to the use of a medicinal product, which predicts haz-

ard from future administration and warrants prevention or specific treatment, or alteration of the dosage regimen, or withdrawal of the product”<sup>(5)</sup>.

It is possible to distinguish six types of adverse drug reactions:

- A) dose-related;
- B) non-dose-related;
- C) dose-related and time-related;
- D) time-related;
- E) withdrawal;
- F) unexpected failure of therapy.

Paracetamol (N-acetyl-p-aminophenol), better known in the United States as acetaminophen, is the active metabolite of phenacetin. It is a widely used analgesic and antipyretic drug, and is considered an efficient alternative to aspirin. Paracetamol overdose is currently the most frequent cause of ALF in the United States, the United Kingdom, and many other countries<sup>(6)</sup>. The minimum lethal dose is about 10 g<sup>(7)</sup>.

In the current case, we could not estimate accurately the dose of ingested paracetamol because we did not receive the complete clinical history of the patient, nor could we know if she had ingested more than one form of paracetamol within several days, if she had ingested other drugs containing paracetamol unknowingly, if she had only one dose, or if this was the first time she ingested paracetamol.

Therapeutic doses of paracetamol have the potential to result in liver damage if they are associated with circumstances that enhance the activity of the cytochrome P-450 system or that deplete the available glutathione<sup>(8)</sup>. Regardless of whether it occurs as a result of a single overdose or after repeated supra-therapeutic ingestion, the progression of paracetamol poisoning can be summarised into four stages: preclinical toxic effects; hepatic injury; hepatic failure; and recovery<sup>(9)</sup>. Early clinical signs (4-12 hours after ingestion) are characterised by nausea, vomiting, diarrhoea, and abdominal pain. At this stage, the patient presents a normal serum AST concentration<sup>(9, 10)</sup>. Then, 24-48 hours later, when these signs are abating, hepatic injury becomes apparent, even though maximal abnormalities and hepatic failure could become evident only 4-6 days after ingestion<sup>(10)</sup>. Renal failure and myocardial injury may be present<sup>(10)</sup>.

The management of paracetamol poisoning is dependent on the time between the ingestion of paracetamol and the time of therapy. Within 1 hour of paracetamol overdose, the administration of acti-

vated charcoal is effective to prevent systemic absorption of the drug<sup>(11)</sup>. In the early stages of paracetamol poisoning (<15 hours), oral or intravenous therapy with acetylcysteine, which acts as a glutathione donor, is an effective antidote. Additionally, therapy with acetylcysteine is important 15 hours post-ingestion for appropriate management<sup>(12)</sup>.

When a patient presents with ALF, it is very important to manage the case in an intensive care unit and, if necessary, transfer the patient as soon as possible to a centre with a liver transplantation unit<sup>(13)</sup>. Liver transplantation still remains the most promising option for the treatment of ALF<sup>(14)</sup>. In the current case, clinical management by doctors was correct. Given that ALF can have numerous causes, the most frequent causes were excluded. After being informed of the patient's paracetamol ingestion, and once serum paracetamol levels were confirmed, the treating physicians administered the appropriate treatment with acetylcysteine.

In conclusion, from data reported in the literature<sup>(8)</sup>, results obtained from the clinical history and the anatomopathological evidence suggested that the death of the patient was attributable to accidental paracetamol poisoning.

## References

- 1) Bernal W, Auzinger G, Dhawan A, Wendon J. Acute liver failure. *Lancet* 2010; 376 (9736): 190-201.
- 2) Ichai P, Samuel D. Epidemiology of liver failure. *Clin Res Hepatol Gastroenterol* 2011; 35 (10): 610-7.
- 3) Ichai P, Samuel D. Etiology and prognosis of fulminant hepatitis in adults. *Liver Transpl* 2008; 14 (suppl. 2): s67-79.
- 4) Hussaini SH, Farrington EA. Idiosyncratic drug-induced liver injury: an overview. *Expert Opin* 2007; 6 (6): 673-84.
- 5) Edwards IR, Aronson JK. Adverse drug reactions: definitions, diagnosis, and management. *Lancet* 2000; 356 (9237): 1255-9.
- 6) Jaeschke H, Williams CD, Ramachandran A, Bajt ML. Acetaminophen hepatotoxicity and repair: the role of sterile inflammation and innate immunity. *Liver Int* 2012; 32 (1): 8-20.
- 7) Moffat AC, Osselton MD, Widdop B. Clarke's analysis of drugs and poisons. London: Pharmaceutical Press. 2011.
- 8) Gyamlani GG, Prikh CR. Acetaminophen toxicity: suicidal vs accidental. *Critical Care* 2002; 6 (2): 155-9.
- 9) Heard JK. Acetylcysteine for acetaminophen poisoning. *N Engl J Med*. 2008; 359 (3): 285-92.
- 10) Kasper LD, Fauci AS, Hauser SL, Long DL, Jameson JL, Loscalzo J. Harrison's principles of internal medicine. 19th Edition. New York: McGraw-Hill. 2015.
- 11) Williams CD, Farhood A, Jaeschke H. Role of caspase-1 and interleukin-1 $\beta$  in acetaminophen-induced hepatic inflammation and liver injury. *Toxicol Appl Pharm* 2010; 247 (3): 168-78.
- 12) Dargan PI, Alison LJ. Management of paracetamol poisoning. *Trends Pharmacol Sci* 2003; 24 (4): 154-7.
- 13) Mas A, Rodes J. Fulminant hepatic failure. *Lancet* 1997; 349 (9058): 1081-5.
- 14) Gotthardt D, Riediger C, Weiss KH, Encke J, Schemmer P, Schmidt J, Sauer P. Fulminant hepatic failure: etiology and indications for liver transplantation. *Nephrol Dial Transplant* 2007; 22 (suppl. 8): 5-8.

Corresponding author  
Dr. ALESSANDRO FEOLA  
via Montpellier 1,  
00133 Roma, Italia.  
E-mail: alessandro.feola@icloud.com  
(Italy)