

Botulinum Toxin Type A Treatment for Contouring of the Lower Face

MEE YOUNG PARK, MD,* KI YOUNG AHN, MD, PhD,[†] AND DUCK SOO JUNG, MD, PhD[‡]

*Department of Neurology, Yeungnam University Medical Center, [†]Department of Plastic and Reconstructive Surgery, and [‡]Department of Radiology, Daegu Catholic University Hospital, Daegu, Korea

BACKGROUND. Since type A botulinum toxin was first reported for the treatment of masseter muscle hypertrophy in 1994, there have been few reports about cosmetic indications for contouring procedures of the lower face with injection of botulinum toxin type A, and this procedure remains unpredictable.

OBJECTIVES. This study attempted a quantitative prospective analysis of reduction of masseter muscle hypertrophy after Botox injection, using ultrasound and computerized tomography (CT) scans to analyze the possible use of botulinum toxin type A as a contouring procedure for the lower face.

METHODS. Forty-five patients consented to the study and received a contouring procedure of the lower face from November 2001 to April 2002. Twenty five to 30 U of Botox per side was injected at five to six points into the prominent portions of the mandibular angle. Serial measurements were made of the thickness of the masseter muscle by ultrasound and CT before the injections and at 1 and 3 months thereafter. A quantitative analysis for the masseter thickness changes was performed on just one patient who underwent all ultrasound and CT scans. Statistical analysis of the masseter thickness change was by two-way and multiple comparison analysis. To evaluate clinical long-term effects, the patient's satisfaction with the procedure and any side effects after injections were monitored during 4 to 10 months of follow-up.

RESULTS. Among the total of 45 patients, 15 underwent the three ultrasound measurements, and 14 had the three CT measurements. With regard to quantitative analysis of the thickness change to the masseter on both sides of the face according to time points, this was gradually reduced by both the ultrasound and CT measurements during the first 3 months. By ultrasound, the maximum reduction in masseter thickness was seen 1 month after the injections, with a slight increase being observed at 3 months after injection. A continued reduction of masseteric muscle thickness was seen on the CT up to 3 months after injection. In terms of patient satisfaction for up to 10 months of follow-up, the results were as follows: very satisfied, 1; satisfied, 36; slight improvement, 3; no change or dissatisfied, 5. Main local side effects included masticatory difficulties, muscle aching at injection sites, and speech disturbance. However, these side effects were transitory, usually lasting from 1 to 4 weeks after the injections.

CONCLUSIONS. Preliminary results from this study suggest that an injection of Botox resulted in relatively satisfactory clinical effects, although there was only a short-term follow-up. It is suggested that the use of botulinum toxin type A for contouring of the lower face can be established as a simple, predictable, alternative facial contouring procedure without a prolonged recovery time.

M. Y. PARK, MD, K. Y. AHN, MD, PHD, AND D. S. JUNG, MD, PHD HAVE INDICATED NO SIGNIFICANT INTEREST WITH COMMERCIAL SUPPORTERS.

SINCE TYPE A botulinum toxin was first used for treatment of masseteric hypertrophy in 1994,¹ there have been few reports on the subject.^{2,3} Limitations of these studies have included small patient numbers, different dosages and botulinum toxin A preparations, and conflicting results after treatment.

The mechanisms of treatment of hypertrophy of the masseter by botulinum toxin type A are somewhat different from those of treatment of the facial hyperkinetic wrinkles such as crow's feet and wrinkles on the glabellar and forehead area;⁴ that is, the

temporary effects of muscle atrophy, followed by chemodenervation due to acetylcholine blockade at the neuromuscular junction by botulinum toxin type A, were mainly used for the treatment of hypertrophied muscle.

Although a few reports about the cosmetic indications for contouring procedures of the lower face with injection of botulinum toxin type A into the masseter have become available recently,^{5,6} these methods remain an unestablished procedure. Therefore, it is necessary to study further whether these methods could have successful outcomes. In addition, the relationship between the dose and clinical effects of Botox remains to be determined.

This study attempted a quantitative prospective analysis of reduction of masseter muscle after Botox

Address correspondence and reprint requests to: Ki Young Ahn, MD, PhD, Department of Plastic and Reconstructive Surgery, Daegu Catholic University Hospital, #3056-6 Daemyung 4-dong, Nam-gu, Daegu, Korea, 705-718, or e-mail: kyahn@cuth.cataegu.ac.kr.

injection and analyzed the possible use of botulinum toxin type A as a contouring procedure of the lower face.

Methods

Forty-five patients consented to participate in the study after a thorough explanation about the nature and established use of botulinum toxin type A and its potential side effects. They received a contouring procedure of the lower face from November 2001 to April 2002. The study was approved by the clinical research ethics committee of the affiliated university hospital, and all patients were free to withdraw from the treatment at any time.

Potential causes of benign masseter hypertrophy, including the chewing of gum or cuttlefish, bruxism, a history of long-term dental treatment and temporomandibular joint pain, and bony protuberance of the mandibular angle through the anteroposterior view, were investigated before the injection.

We used Botox containing 100 U, which was reconstituted with 2 mL of a normal saline to yield 5 U per 0.1 mL. Percutaneous intramuscular injections of the masseter by palpations were performed without electromyographic guidance. Twenty-five to 30 U were injected into each side at five to six points at prominent portions of the mandibular angle.

Several anatomical landmarks of the face, including the lateral canthus, inferior orbital rim, external meatus, and the mandibular angle, were selected for serial ultrasound and computerized tomography (CT) measurements. For serial ultrasound measurements, the probe was placed on imaginary lines between the lateral canthus and the mandibular angle. The same radiologist took three measurements, and the mean data were presented. For the serial CT scans, the patients were placed in a supine position with head splints, and the scan was based on the line between the inferior orbital rim and external meatus axially at 1-cm intervals. The mean value of three sections just above the mandibular angle was presented (Figure 1).

To obtain normal background data at the same point as a control, 12 "normal" women between the ages of 20 and 40 were selected and given ultrasound and CT scans. Serial measurements of the thickness of the masseter were made by ultrasound and CT scans before the Botox injection and at 1 and 3 months thereafter. A quantitative analysis for the masseter thickness changes was performed on just one patient who underwent all ultrasound and CT scans. Statistical analysis of the masseter thickness changes was performed using two-way and multiple comparison analysis. The difference was considered statistically

significant if the *P* value was less than 0.05. An SPSS for Windows version 10.0 software package was used for the statistical analysis.

To evaluate long-term clinical effects, the patient's degree of satisfaction and any side effects were monitored during 4 to 10 months of follow-up. The patient's satisfaction was rated as very satisfied, satisfied, slight improvement, and dissatisfied or no change.

Results

Two males and 43 females participated in the study. Ages ranged between 24 and 48 years, with a mean of 35. Medical histories before injection were as follows: chewing gum or cuttlefish, 18; temporomandibular joint pain, 15; long-term dental treatment, 7; and bruxism, 7. Eighteen patients (40%) had parameters of benign masseteric hypertrophy. Ten patients (28%) had a mild or prominent bony protuberance of the mandibular angle on the anteroposterior view. Most of the patients were injected bilaterally, and four were injected unilaterally for facial symmetry.

The mean (SD) thicknesses of masseter muscles in normal control subjects by ultrasound were 12.1 (1.0) mm on the left side and 12.1 (1.1) mm on the right side. By CT scans, these figures were 12.1 (1.2) and 12.5 (1.8) mm, respectively.

Among the total of 45 patients, 15 underwent all three ultrasound scans, whereas 14 received all three CT scans. The mean masseteric thickness before injection was 14.0 (1.9) mm on the left side and 14.4 (2.2) mm on the right side, as measured by ultrasound. Using CT, these measurements were 14.9 (2.2) and 15.5 (3.3) mm, respectively.

Mean masseteric thicknesses at 1 and 3 months after injection by ultrasound were 11.2 (1.6) and 11.5 (1.4) mm on the left side and 11.5 (1.6) and 11.9 (1.4) mm on the right side, respectively. By CT scan, these respective figures were 13.3 (2.1) and 12.0 (1.7) mm and 14.2 (2.6) and 12.7 (2.2) mm (Table 1).

The results of CT on both the left and right sides were usually higher than the ultrasound measurements. The differences between the right and left sides by ultrasound and CT scan were not statistically significant at all times (left, $F = 2.900$, $P = 0.076$; right, $F = 3.735$, $P = 0.065$). However, the different periods that the CT and ultrasounds were taken did exhibit statistical significance ($P < 0.05$). Thickness by ultrasound fell to the lowest point at 1 month after the injections but increased until 3 months after injection. CT measurements of muscle thickness decreased steadily over 3 months after injection (Figure 2). The

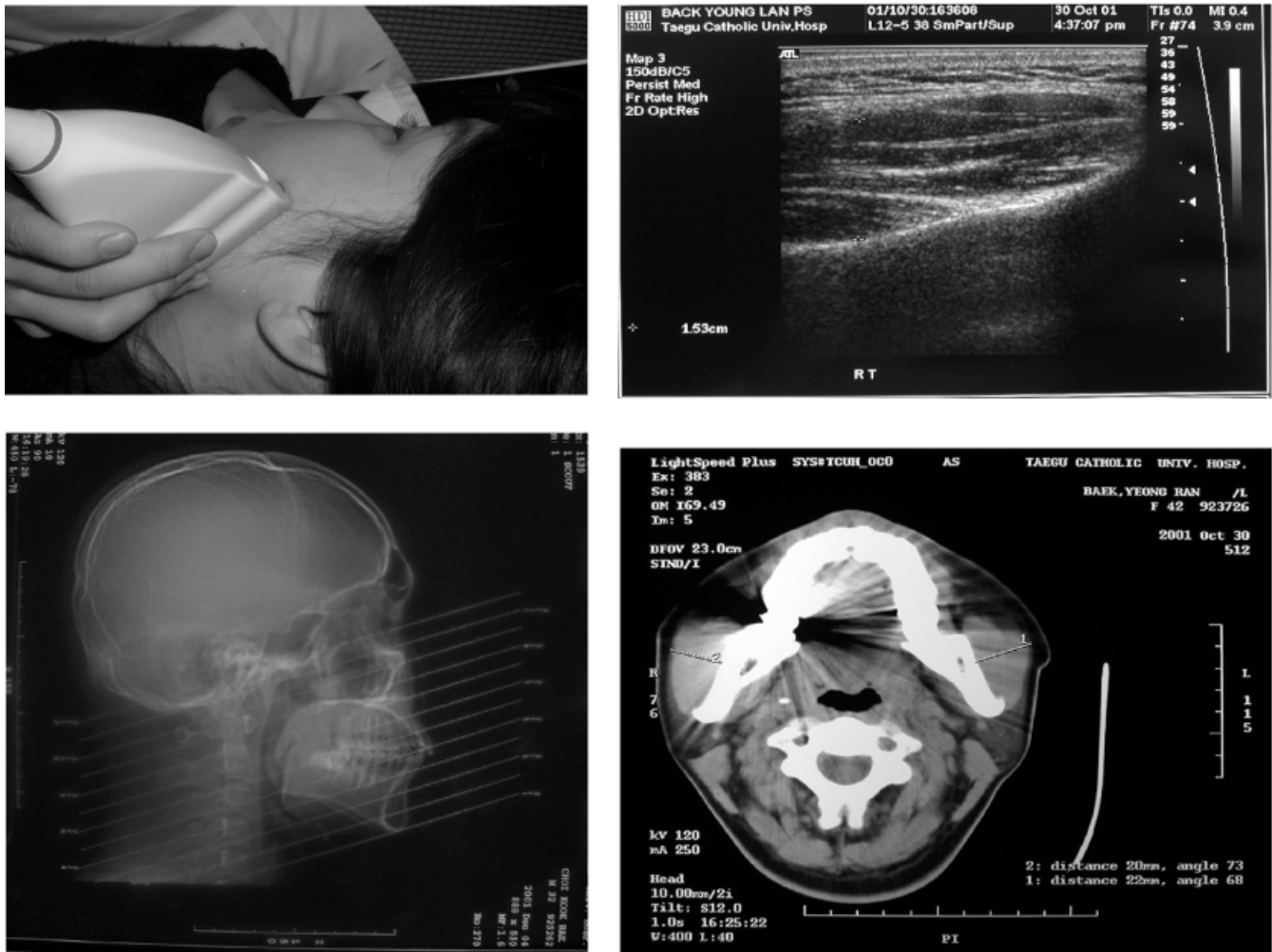


Figure 1. Measurement of the ultrasound and CT. Measuring the thickness of masseter muscle of the patients using ultrasound (above). Measuring the thickness of masseter muscle of the patients using computerized tomogram (below).

Table 1. Descriptive Analysis of Observed Data for the Masseter Thickness in Both Sides (mean [SD])

Time Methods	Preinjection		Postinjection 1 Month		Postinjection 3 Months		Controls (N = 12)	
	Lt	Rt	Lt	Rt	Lt	Rt	Lt	Rt
CT (N = 14)	14.9(2.2)	15.5(3.3)	13.3(2.1)	14.2(2.6)	12.0(1.7)	12.7(2.2)	12.1(1.2)	12.5(1.8)
SONO (N = 15)	14.0(1.9)	14.4(2.2)	11.2(1.6)	11.5(1.6)	11.5(1.4)	11.9(1.4)	12.1(1.0)	12.1(1.1)

Lt, Left; Rt, Right; Mo, Month; SONO, Ultrasound; CT, Computerized tomography.

difference between CT and ultrasound measurements was statistically significant 1 month after injection on both the right and left sides (left, $F = 8.579$, $P = 0.008$; right, $F = 10.541$, $P = 0.003$). Multiple comparison analysis using the Scheffe method in each testing phase and by test group showed a statistical significance in both the CT and ultrasound measurements between preinjection and 3 months after injection. However,

there was no statistical significance in comparing the preinjection phase to a month after injection and between a month of the injection and 3 months after it ($P < 0.05$).

The results in terms of patient satisfaction up to 10 months of follow-up were as follows: very satisfied, 1; satisfied, 36; slight improvement, 3; and dissatisfied, 5 (Table 2 and Figures 3–6). The main local side effects

included masticatory difficulty with hard food (20), speech disturbance (7), and ache at injection sites (11). These complaints were transient, usually lasting from

1 to 4 weeks after injection. In addition, facial asymmetry and prominent zygoma were observed (Table 3).

Discussion

Asian women tend to prefer oval and almond-shaped faces and dislike a square jaw, which they believe gives them a masculine image. Differences in facial preferences between Westerners and Asians arise from ethnic differences in the craniofacial shape, with Westerners usually having long, narrow faces and Asians having short, wide faces.⁷ Therefore, Asian women tend to dislike the square shape, as they believe it makes the face look wider.

Contouring of the mandible is therefore a relatively common esthetic procedure among Asians, although it is rare among Westerners. At present, the contouring procedure for the lower face mainly involves resection of the angle or body of the mandible. Such surgical procedures had many disadvantages, including persistent swelling, hematoma, and postoperative pain. In addition to these immediate complications, prominent scars may occur on the neck with the extraoral approach, and partial palsy of the facial nerve is often

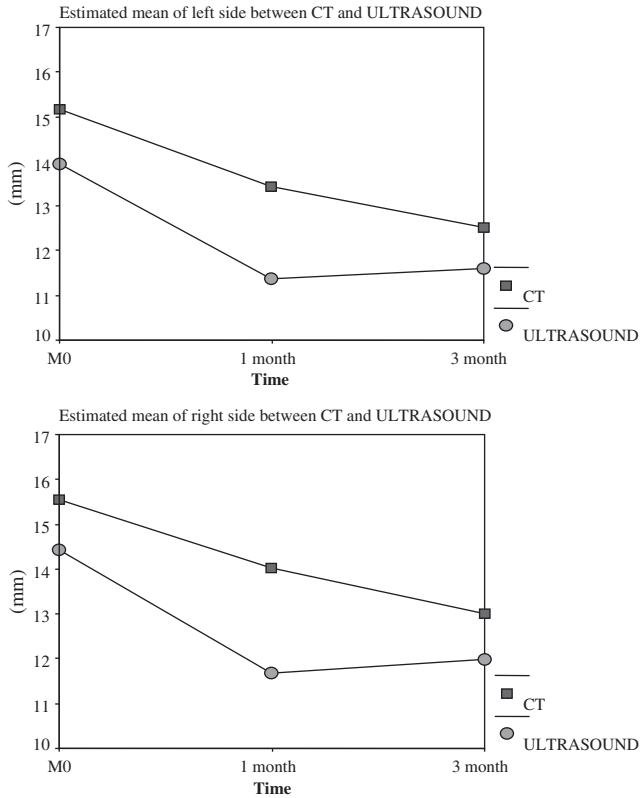


Figure 2. Estimated mean of both sides between CT and ultrasound. Masseter muscle thickness was gradually reduced, as seen by both CT and ultrasound scans during the first 3 months after injections, although thickness by ultrasound fell to the lowest point at 1 month after the injections but increased until 3 months after injection. CT measurements of muscle thickness decreased steadily over 3 months after injection.

Table 2. Patient's Satisfaction

Results	Number of Patients
Very Satisfied	1
Satisfied	36
Slightly improvement	3
Dissatisfied	5
Total	45

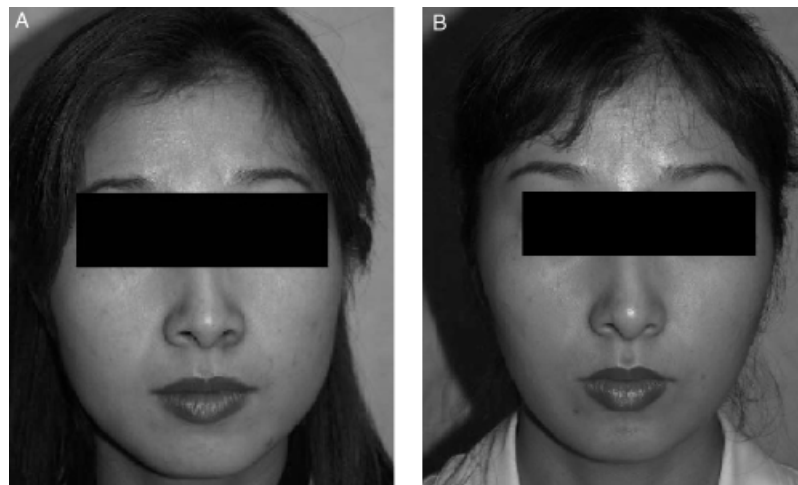


Figure 3. (A) A 28-year-old patient before injection with botulinum toxin A. (B) The same patient 10 months after injection.




Figure 4. (A) A 24-year-old patient before injection with Botulinum toxin A. The same patient 1 month (B) and 5 months (C) after injection.

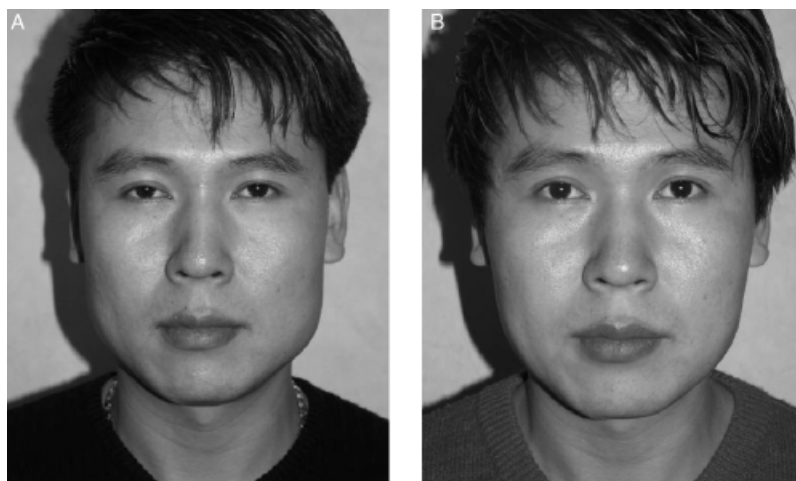


Figure 5. (A) A 28-year-old patient before the injection with botulinum toxin A. (B) The same patient 4 months after injection.

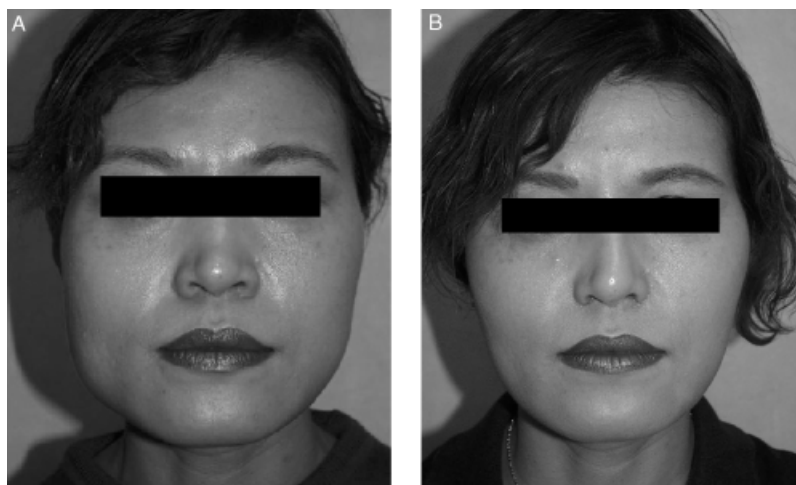


Figure 6. (A) A 34-year-old patient before the injection with botulinum toxin A for facial symmetry. (B) The same patient 3 months after the injection.

Table 3. Local Side Effects

<i>Side Effects</i>	<i>Number of Patients</i>
Masticatory difficulty	20
Speech disturbance	7
Muscle aching	11
Prominent zygoma	2
Facial asymmetry	2
Total	42

reported.^{5,6} Patients who desire the facial contouring procedure are generally 20 to 40 years old and usually have a job that makes surgical procedures difficult. Therefore, the use of botulinum toxin type A for contouring of the lower face may offer a simple alternative to surgery, without a long recovery time, if this method could achieve an adequate and more predictable reduction in muscle thickness.

In this study, the masseters of the patient group were approximately 2 to 3 mm thicker than those of control subjects. In particular, 40% of the patients had parameters of the benign masseter hypertrophy. Interestingly, just 28% of the patients had a bony prominence in their mandibular angle, underscoring the importance of the anteroposterior view as a very simple test to perform before the procedure.

The differences between CT and ultrasound scans in the patient group appeared to be mainly caused by discrepancies of measuring points of the masseter between two methods. This research also found that it was very difficult to test the same area again at 1 to 3 months after the procedure. Therefore, it was necessary to have external anatomical landmarks and uniform position of patients with a head splint at repetitive measurements.

Intramuscular injection of botulinum toxin type A led to temporary partial denervation in the area of the neuromuscular synapses by prohibiting the release of acetylcholine. In animal experiments,⁸ within 10 to 14 days after the injection, the muscle fibers begin to show atrophy histologically. This atrophy continued to develop over a 4- to 6-week period. Note that there is not only fiber atrophy, as indicated by generalized reduction in fiber diameters, but also a large degree of fiber size variability. The fiber atrophy is a reversible phenomenon with recovery over 4 to 6 months. Seventeen orbicularis oculi muscle specimens taken from patients during ptosis and myectomy surgery were evaluated for cholinesterase staining characteristics and fiber variability. Diffuse cholinesterase activity was seen, starting at Weeks 3 to 4, and this staining pattern was maintained through 3 to 4 months after injection. In all patients studied after 6

months, it could not be distinguished from that seen in control subjects.⁹ In this study, masseter muscle thickness was gradually reduced, as seen by both CT and ultrasound scans during the first 3 months after injections, although the data for CT and ultrasound were somewhat different. Some patients who missed serial measurements because of an irregular follow-up period had masseter muscle thickness of 12.2 mm by ultrasound of eight patients and 13.9 mm by CT of six at 5 to 6 months after injection, which was a slight increase from the mean thickness seen at 3 months after injection. Although reduction of the masseter muscle 5 to 6 months after the injection cannot be analyzed statistically, it can be safely inferred that the reduction of masseter muscle after injection goes through similar phases, as described in the previous studies.^{8,9}

Of 17 patients who had Botox injections more than 9 months earlier, a follow-up of 10 patients found that three of the patients received repeat procedures. There was one case of recovery to the preprocedure level, and most showed a slight improvement. These results show that the clinical effects from this study persisted longer than previous data from muscle biopsies obtained from animal and human experimental studies.^{8,9} These clinical effects may be due to attenuation or correction of the underlying causes of benign masseter hypertrophy after botulinum toxin type A injection. It is also speculative whether a temporary denervation effect on muscles such as the masseter could have a longer clinical effect than the histochemical changes of atrophied muscle. This hypothesis warrants further analysis with more patients and muscle biopsies in future.

von Lindern et al.⁶ have reported that seven patients with unilateral or bilateral hypertrophy of the masseter and temporalis muscles were treated with an average of 100 U of another botulinum type A toxin preparation (Dysport) and showed a 50% reduction in masseter muscle thickness. That result was considered to be aesthetically satisfactory after a single injection in four patients. To et al.⁵ reported that five patients with unilateral and bilateral hypertrophy of the masseter were treated with 200 to 300 U of Dysport per side, and ultrasound measurements were performed. Three of five patients needed a secondary injection within 1 year. Mandel and Tanakan³ reported that one patient with unilateral hypertrophy of the masseter was treated with 5 U of Botox, and the effect lasted approximately 4 months, although no long-term results were reported.

In this study, the average amount of thickness change of masseter in ultrasound and CT measurement studies was approximately 2.8 to 2.9 mm, and these changes were equivalent to approximately 18% to

20% of the muscle thickness of the masseter at preinjection. In an extreme case, one patient who was excluded from the quantitative analysis of the thickness change showed an approximate 30% masseter thickness change. Over the 4 to 10 months of follow-up, more than 80% of the total patients were satisfied with the contouring effects of the lower face.

Although the dosages used for each muscle were different among the different authors,^{3,5,6} it is suggested that 25 to 30 U of Botox injected into each muscle were equivalent to approximately 100 U of Dysport.⁶ However, inconsistent with previous studies,^{5,6} our results showed that whereas duration of clinical effect during the follow-up period was similar, the average amount of muscle reduction was somewhat different. In this study, the main side effects seen after Botox injection were transient mild masticatory weakness and speech disturbances, which were temporary and did not disturb normal life. It was considered that these side effects were closely associated with the dosage used.

As in Sloop's dose-response curve,¹⁰ the dose-response relationship parallels in lower doses, but the higher doses do not produce the more effect out at a certain dose. Therefore, a more adequate dose determination of botulinum toxin type A for contouring of the lower face is required in future. The sustained effect of repetitive botulinum toxin type A injection into the masseter on the surrounding masticatory muscles around temporomandibular joints and mandible angle also requires long-term follow-up.

Approaches to a better understanding of the mechanism of action of botulinum toxin type A for contouring of the lower face should be considered different from the treatment of facial wrinkles at the different viewpoints. The study for the adequate dose, clinical effects, and duration of the effect of botulinum toxin type A is still preliminary. This study showed preliminary quantitative results after Botox with

noninvasive ultrasound and CT scans, even though it was for a short-term follow-up.

In conclusion, the use of Botox for contouring of the lower face may become established as a simple, predictable alternative method of facial contouring without a prolonged recovery time. To our knowledge, this is the first report demonstrating clinical effects of Botox on the masseter muscle, which was monitored by ultrasound and CT scans.

References

1. Moore AP, Wood GD. The medical management of masseteric hypertrophy with botulinum toxin type A. *Br J Oral Maxillofac Surg* 1994;32:26-8.
2. Smyth AG. Botulinum toxin treatment of bilateral masseteric hypertrophy. *Br J Oral Maxillofac Surg* 1994;32:29-33.
3. Mandel L, Tanakan M. Treatment of unilateral masseteric hypertrophy with botulinum toxin: case report. *J Oral Maxillofac Surg* 1999;57:1017-9.
4. Ahn KY, Park MY, Park DH, Han DG. Botulinum toxin A for the treatment of facial hyperkinetic wrinkle lines in Koreans. *Plast Reconstr Surg* 2000;105:778-84.
5. To EW, Ahuja AT, Ho WS, et al. A prospective study of the effect of botulinum toxin A on masseteric muscle hypertrophy with ultrasonographic and electromyographic measurement. *Br J Plast Surg* 2001;54:197-200.
6. von Lindern JJ, Niederhagen B, Appel T, Berge S, Reich RH. Type A botulinum toxin for the treatment of hypertrophy of the masseter and temporal muscle: an alternative treatment. *Plast Reconstr Surg* 2001;107:327-32.
7. Satoh K. Mandibular contouring surgery by angular contouring combined with genioplasty in Orientals. *Plast Reconstr Surg* 1998;101:461-72.
8. Borodic GE, Ferrante RJ, Pearce LB, Alderson K. Pharmacology and histology of the therapeutic application of botulinum toxin. In: Jankovic J, Hallett M eds. *Therapy with Botulinum Toxin*. New York: Mancel Dekkey, 1994:119.
9. Bordic GE, Ferrante R. Histologic effects of repeated botulinum toxin over many years in human orbicularis oculi muscle. *J Clin Neuro Ophthalmol* 1992;12:121-7.
10. Sloop RR, Escutin RO, Matus JA, Cole BA, Peterson GW. Dose-response curve of human extensor digitorum brevis muscle function to intramuscularly injected botulinum toxin type A. *Neurology* 1996;46:1382-6.

responses. Park et al. described a large experience with this treatment and carefully documented the responses to treatment. This is a fascinating expansion of the aesthetic use of botulinum toxin type A.

ALASTAIR CARRUTHERS, MD
JEAN CARRUTHERS, MD
Vancouver, Canada

Commentary

Although the treatment of masseteric hypertrophy with botulinum toxin type A was first described in 1994, this indication has not been given the attention accorded to other aesthetic indications. This may be partly due to ignorance on the part of afflicted individuals and their physicians that this treatment is available. However, the recent explosion of interest in this condition in Korea reflects on important ethnic aesthetic