

MORPHOLOGICAL STUDY OF KIDNEY IN CADAVERS OF WESTERN MAHARASHTRA REGION

Shweta B Shambharkar ^{*1}, Shabana Borate ², Amandeep Kaur Ratta ³, Suresh Gangane ⁴.

^{*1} Assistant Professor, Department of Anatomy, Govt. Medical College, Gondia, Maharashtra, India.

² Associate Professor, Department of Anatomy, Grant Govt. Medical College, Mumbai, Maharashtra, India.

³ National Program Officer, Maternal Health, Norway India Partnership Initiative, IPE Global, New Delhi, India.

⁴ Ex Professor and Head, Dept of Anatomy, Grant Govt. Medical College, Mumbai, Professor and Head, Terna medical College, New Mumbai, Maharashtra, India.

ABSTRACT

The Kidneys are the most important organs responsible for removing excess water, salts and waste products from the blood and for maintenance of blood pH. Dimensions of kidney vary in a large interval from birth to adulthood. Changes in kidney length, parenchymal width (PW), cortex width (CW) or volume can be associated with atherosclerotic renal diseases, arterial hypertension, atherosclerotic renovascular disease, or diabetes mellitus or to be indicative of these. The renal dimensions can also be an indicator for unilateral glomerular filtration rate. The coronal section study of kidney provides good knowledge in cases of chronic renal diseases and renal transplantation. The purpose of this study was to determine the anatomical parameters of the kidney in adults. Weight, length, breadth, maximum anteroposterior thickness, cortical width, parenchymal widths were studied in 100 adult cadaveric kidneys. The data was statistically analysed. No statistical significance was seen with respect to the difference in right and left side. But the differences which are frequently seen i.e. length of left kidney greater than the right was also found in the present study, resulting in greater breadth and thickness on the right side. Males had slightly higher values than females, though not statistically significant. The mean values provided in the study could be of use to surgeons, radiologists and nephrologists.

KEY WORDS: Morphology, Kidney, Parenchymal, Cortical, Renal Transplantation.

Corresponding Author: Dr. Shweta B Shambharkar, Plot No.43/B, Dhadiwal Layout, Suyog Nagar Square, Post: Parwati Nagar, Nagpur, Maharashtra-440027, India.

Phone: 9960810368 E-Mail: shambharkar.shweta4@gmail.com

Access this Article online	Journal Information
Quick Response code  DOI: 10.16965/ijar.2020.188	International Journal of Anatomy and Research ISSN (E) 2321-4287 ISSN (P) 2321-8967 https://www.ijmhr.org/ijar.htm DOI-Prefix: https://dx.doi.org/10.16965/ijar  
	Article Information
	Received: 13 Jun 2020 Peer Review: 13 Jun 2020 Revised: None
	Accepted: 28 Jul 2020 Published (O): 10 Aug 2020 Published (P): 10 Aug 2020

INTRODUCTION

The kidneys as a part of excretory system are important excretory organs that excrete the final products of metabolic activities and excess water to control the concentrations of various substances in body fluids. They also have endocrine functions producing and releasing erythro-

poietin which affects blood formation of renin which influences blood pressure and 1,25 hydroxycholecalciferol, which is involved in the control of calcium metabolism and is a derivative of vitamin D. The kidneys in fresh state are reddish-brown, which change to grayish-brown in embalmed cadavers. They are situated poster-

iorly behind the peritoneum on each side of the vertebral column with right kidney slightly inferior to the left probably due to its relationship to the liver. The left kidney is little longer and narrower than the right kidney and lies nearer the median plane. The transpyloric plane passes through the superior part of the right renal hilum and inferior part of the left. Each kidney is about 11 cm in length, 6 cm in breadth and 3 cm in antero-posterior dimension. In adult males the average weight is about 150 gm, in adult females it is 135 gm. Superiorly they are at the level of upper border of twelfth thoracic vertebra and inferiorly at the level of third lumbar vertebra. But the right kidney is about 1.25 cm lower than the left in recumbent posture. The hilar centre is opposite the lower border of the spinous process of first lumbar vertebra. The fetal kidney has about 12 lobules, but these are fused in adults to present a smooth surface, though traces of lobulation may remain. In cross-section, the parenchyma of kidney consists of outer cortex and inner medulla. Normally, the structures seen at the renal hilum from before backwards are renal vein, renal artery and renal pelvis; but variations are very commonly seen in the arrangement of these structures [1].

Dimensions of kidney vary greatly from birth to childhood. The deviation of renal parameters from established normal values is an important criterion in diagnosing kidney disease [2]. Changes in kidney weight, length, parenchymal width (PW), cortical width (CW) or volume can be associated with hypertension, atherosclerotic renal diseases, arterial hypertension, atherosclerotic renovascular disease or diabetes mellitus or be indicative of these. The renal dimensions can also be an indicator for the unilateral glomerular filtration rate [3]. Atherosclerotic renal disease (ARD) has numerous etiologies including intraparenchymal arterial lesions. There are no specific clinical, biological, morphological or functional markers that demonstrate a causal relationship between a stenosis and the deterioration of renal function or that could be used to assess renal viability. There are no specific clinical symptoms of the atherosclerotic renal disease [4].

The gross morphological parameters combined with the coronal section study provide a good

knowledge in cases of chronic renal disease and set an idealistic criterion for renal transplantation. Few data is available in the literature on renal morphology which were obtained using ultrasonography, computed tomography (CT) scan, contrast enhanced CT, CT angiography, nuclear magnetic resonance and intravenous pyelography (IVP). But the anatomical studies on renal parameters are scarce and particularly from India are not much reported. Since the therapeutic decisions are often based on the results of measurements, accurate and reproducible normal parameters are of importance. Hence the objective of present study was to determine the anatomical renal dimensions in adult kidney. The purpose was to establish anatomical reference values for renal weight, length, width, thickness, cortical width, parenchymal width and position in relation to spine [2].

AIMS:

1. To assess the normal parameters of kidney from the cadavers.
2. To study the cross sectional anatomy of kidney.
3. To correlate the findings of the present study with the findings of the previous workers.

Objectives: Few data is available in the literature on renal morphology which were obtained using ultrasonography, computed tomography (CT) scan, contrast enhanced CT, CT angiography, nuclear magnetic resonance and intravenous pyelography (IVP). But the anatomical studies on renal parameters are scarce and particularly from India are not much reported. Since the therapeutic decisions are often based on the results of measurements, accurate and reproducible normal parameters are of importance. Hence the objective of present study was to determine the anatomical renal dimensions in adult kidney. The purpose was to establish anatomical reference values for renal weight, length, width, thickness, cortical width, parenchymal width and position in relation to spine.

MATERIALS AND METHODS

Study Sample: Human cadaveric kidneys.

Sample Size: 100 human Cadaveric kidneys from 50 human cadavers.

Source of Kidney: The kidneys will be obtained

from the cadavers donated to the medical college from western Maharashtra region.

Instrument Set:

1. Digital Weighing Machine.
2. Various instruments routinely used for dissection will be used: These includes
 - a. Forceps (plane and toothed 4" and 6" size)
 - b. Scissors (blunt, pointed, curved, 4" and 6" size)
 - c. Scalpels
 - d. Detachable blades (size 5*1 cm)
 - e. Knife f. Brush
 - g. Vernier calliper
 - h. Measuring tape, divider.

Other Materials: During the dissection surgical hand gloves (no 7), cotton gauze, thread, retractors, soap solution etc. will be used as and when required.

Methods of collection of data: The present study was undertaken on 50 embalmed human cadavers allotted to MBBS students selected from various medical colleges. Both male and female cadavers were included in the study. The cadavers were donated by relatives with consent and with death certificate. None of them had any pathological lesions, traumatic lesions or surgical procedures in the abdominal regions. In the present study, amongst 50 cadavers, 31 were male and 19 were female, 50 were right and 49 were left kidneys (one kidney was absent in a cadaver). The cadavers were fixed by injecting 10% formalin mixture and kept in 10% formalin tanks.

As per the Cunningham’s Manual of Practical Anatomy Volume- 2 (Thorax and Abdomen) a midline vertical incision was taken on the anterior abdominal wall and abdominal cavity opened. All the abdominal organs were removed for exposure of the posterior abdominal wall. Details of the position and external appearance of kidney in situ were noted. The kidneys were seen along the posterior abdominal wall in the lumbar region. The right and left kidneys and the surrounding tissues were removed en bloc with the adjacent part of aorta and inferior vena cava cleared and studied. Kidneys were removed from the abdomen along with renal artery, vein and pelvis and weighed by using electronic digital balance.

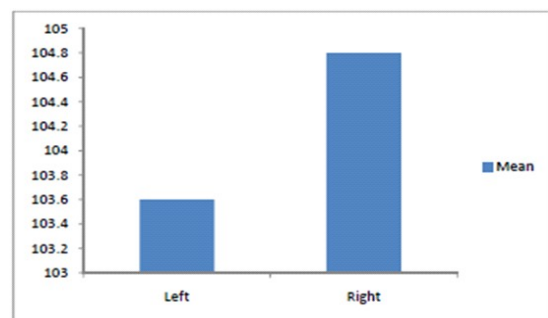
External parameters such as the pole to pole length and breadth at the hilum were measured by using thread and scale. Anterior wall of the renal sinus was removed beginning at the hilum and vessels entering the wall of sinus and the calices were defined. Now a clean coronal section is taken from the lateral marking of kidney through the sinus. The length of kidney was measured as the cranio-caudal diameter. Breadth was taken as a transverse diameter at the hilum. The thickness was taken at the region of maximum antero-posterior diameter.

Hilar structures were well identified and noted. Variations at hilum or variations of hilar structures were noted. Cortical width was measured from lateral border upto the renal pyramid and parenchymal width measured from renal pyramid upto the renal sinus. All these measurements were done using Vernier’s calliper. The results were presented as mean and SD. Dimensions were analysed between male and female, right and left kidneys. The statistical significance was set at $p < 0.05$. Analysis was performed by using the PRISM software.

OBSERVATIONS

Table 1: Showing the weight of Kidneys.

Weight (gms)	Mean	SD	Median
Left	103.6	30.45	101
Right	104.8	34.53	108

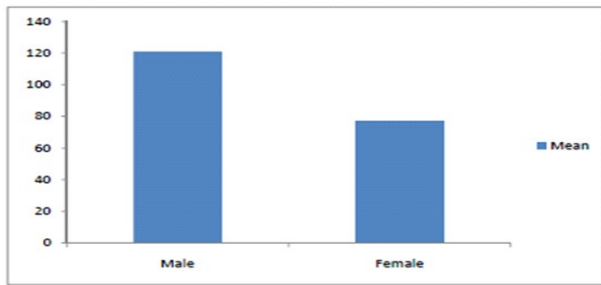


Graph 1: Mean weights (grams) of Kidney.

The mean and median weights of right kidneys was found to be greater than left kidneys but not statistically significant ($p > 0.05$).

Table 2: Sex wise distribution of weight of kidney (grams).

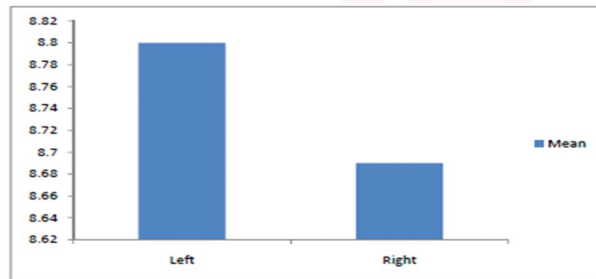
Weight (gms)	Mean	SD	Median
Male	121.03	27.17	125
Female	77.13	19.13	78.5



Graph 2: Mean weights (grams) in males and females. The mean and median weight of kidneys in males was found to be greater than that in females but not statistically significant ($p>0.05$).

Table 3: Mean and SD of length of kidneys.

Length (cms)	Mean	SD
Male	8.8	1.88
Female	8.69	1.34

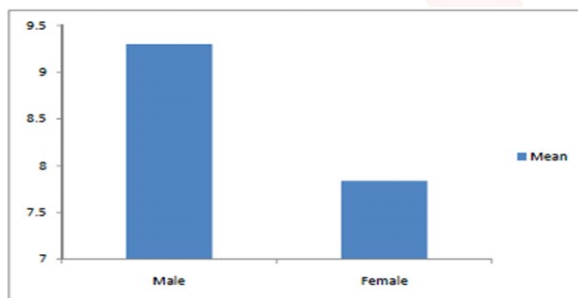


Graph 3: Mean lengths (cms) of Kidneys.

The mean length of left kidney was found to be greater than the right kidney. No statistical significance was found ($p>0.05$).

Table 4: Mean and SD of length of kidneys.

Length (cms)	Mean	SD
Male	9.3	1.08
Female	7.84	0.97

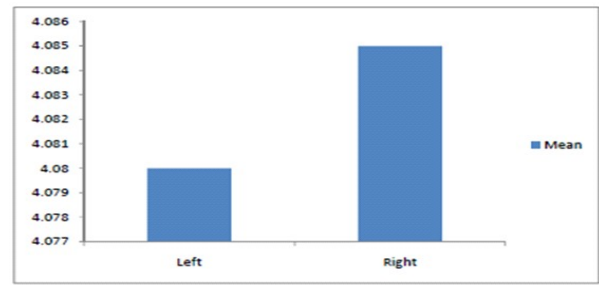


Graph 4: Mean lengths (cms) of kidneys.

The mean length of kidney was found to be greater in males than females. No statistical significance was found ($p>0.05$).

Table 5: Mean and SD of breadths of kidneys.

Breadth (cms)	Mean	SD
Left	4.08	0.57
Right	4.085	0.55

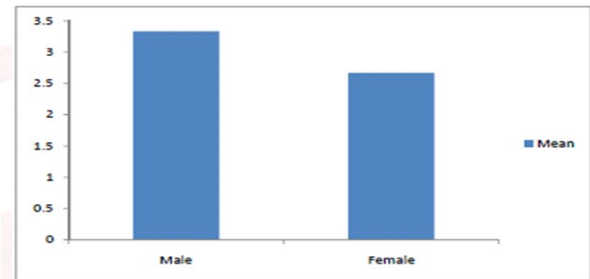


Graph 5: Mean breadths (cms) of kidneys.

The mean breadth of right kidney was found to be greater than the left kidney. No statistical significance was found ($p>0.05$).

Table 6: Mean and SD of breadths of kidneys.

Breadth (cms)	Mean	SD
Male	3.33	0.66
Female	2.67	0.66

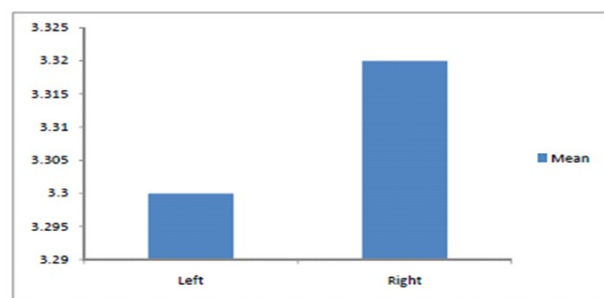


Graph 6: Mean breadths (cms) of kidneys.

The mean breadth of kidney was found to be greater in males than females. No statistical significance was found ($p>0.05$).

Table 7: Mean and SD of Thickness of kidneys.

Thickness (cms)	Mean	SD
Left	3.3	0.59
Right	3.32	0.66

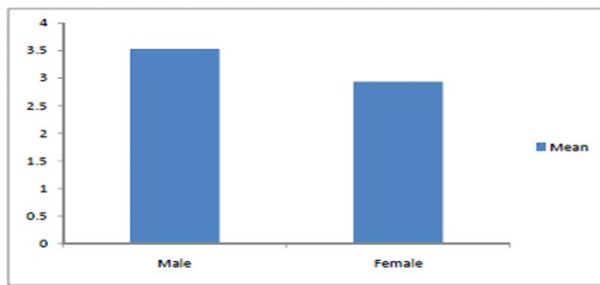


Graph 7: Mean Thickness (cms) of kidneys.

The mean thickness of right kidney was found to be greater than the left kidney. No statistical significance was found ($p>0.05$).

Table 8: Mean and SD of Thickness of kidneys.

Thickness (cms)	Mean	SD
Male	3.53	0.62
Female	2.94	0.39

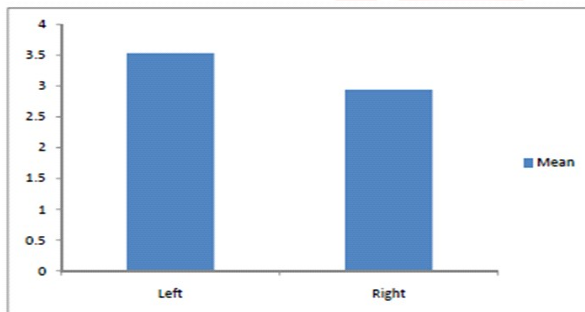


Graph 8: Mean thickness (cms) of kidneys.

The mean thickness of kidney was found to be greater in males than females. No statistical significance was found ($p>0.05$)

Table 9: Mean and SD of Cortical widths of kidney.

Cortical width (cms)	Mean	SD
Left	3.53	0.62
Right	2.94	0.39

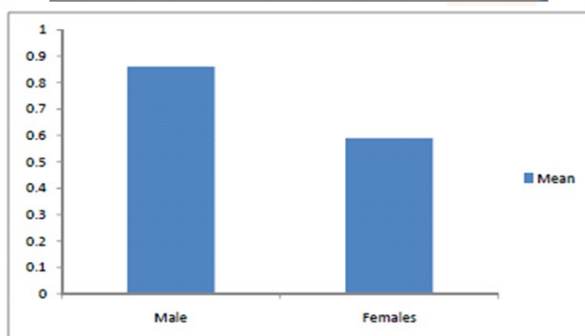


Graph 9: Mean cortical width (cms) of kidneys.

The mean cortical width of kidney was found to be greater than the right kidney. No statistical significance was found ($p>0.05$).

Table 10: Mean and SD of Cortical widths of kidney.

Cortical width (cms)	Mean	SD
Male	0.86	0.15
Female	0.59	0.21

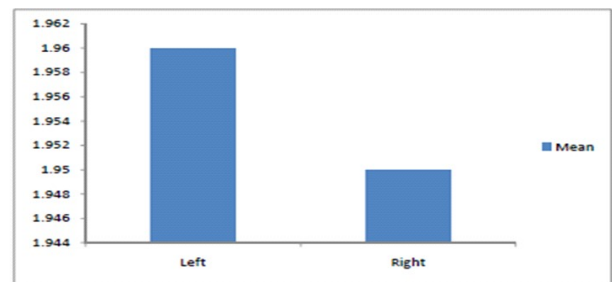


Graph 10: Mean and Cortical width (cms) of kidneys.

The mean cortical width of kidney was found to be greater in males than females. No statistical significance was found ($p>0.05$)

Table 11: Mean and SD of Parenchymal widths of kidneys.

Parenchymal width (cms)	Mean	SD
Left	1.96	0.38
Right	1.95	0.36

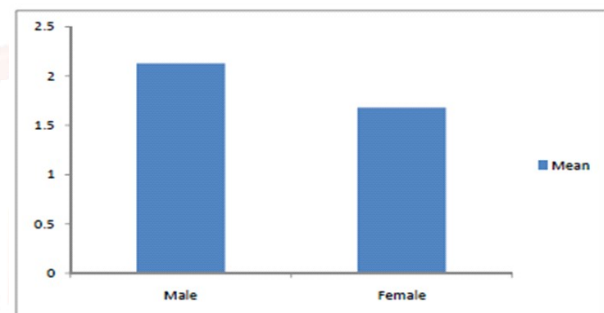


Graph 11: Mean parenchymal width (cms) of kidneys.

The mean parenchymal width of kidney was found to be greater than the right kidney. No statistical significance was found ($p>0.05$)

Table 12: Mean and SD of Parenchymal widths of kidneys.

Parenchymal width (cms)	Mean	SD
Male	2.13	0.31
Female	1.68	0.28



Graph 12: Mean Parenchymal width (cms) of kidneys.

The mean parenchymal width of kidney was found to be greater in males than females. No statistical significance was found ($p>0.05$)

RESULTS

The mean weight of left kidney was found to be 103.6 gm with a median of 101 gm and that of right kidney was 104.8 gm with a median of 108 gm. The mean weight of kidney in males was 121.03 gm with a median of 125 gm and in females the mean and median was 77.13 gm and 78.5 gm respectively. The mean lengths of left and right kidneys were 8.80 +/- 1.88 cm and 8.69 +/- 1.34 cm respectively.

Similarly, the mean lengths in males and females were 9.30 +/- 1.80 cm and 7.84 +/- 0.97 cm respectively. The mean breadth of left and right kidney was 4.08 +/- 0.57 cm and 4.085 +/- 0.55 cm respectively. In males and females, breadths were 3.33 +/- 0.66 cm and 2.67 +/- 0.66 cm respectively. The mean thickness on left and right side were 3.30 +/- 0.59 cm and 3.32 +/- 0.66 cm respectively.

In males mean thickness was 3.53 +/- 0.62 cm and in females it was 2.94 +/- 0.39 cm. the mean

cortical width (CW) of left kidneys was 0.76 +/- 0.21 cm and that of right kidneys was 0.75 +/- 0.22 cm. In males, cortical width was 0.86 +/- 0.15 cm and in females 0.59 +/- 0.21 cm. The mean parenchymal width (PW) on left and right side was 1.96 +/- 0.38 cm and 1.95 +/- 0.36 cm respectively. In males and females, the mean parenchymal width was 2.13 +/- 0.13 cm and 1.68 +/- 0.28 cm respectively.

The variation in hilar structures was found in total 27 cadavers (15 males and 12 females) and 42 kidneys, of which 21 were right and 21 left. In 15.15% renal artery was present anterior to renal vein. Total of 12.12% of accessory renal arteries were found amongst which 9.09% were unilateral and 3.03% were bilateral. Segmented branches of renal arteries were seen before entering the hilum.

The variation in hilar structures was found in total 27 cadavers (15 males and 12 females) and 42 kidneys, of which 21 were right and 21 left. In 15.15% renal artery was present anterior to renal vein. Total of 12.12% of accessory renal arteries were found amongst which 9.09% were unilateral and 3.03% were bilateral. Segmental branches of renal arteries were seen before entering the kidney 14 on left and 13 on right side, total of 27.27%. Two or more renal veins were found 14 on left side and 13 on right side, amongst which 9 cadavers showed bilateral variation of renal veins. Amongst the 99 kidneys dissected, 5 kidneys were lobed, 5 were cystic 3 had triplicate pelvis and 1 had no ureter.

The statistically significant differences were not observed ($p > 0.05$) between the right and left renal parameters. But the differences which are frequently seen i.e. length of left kidney greater than the right was also found in the present study, resulting in greater breadth and thickness on the right side possibly due to presence of liver on right side which prevented its vertical growth, so the right kidney showed broadening and thickening. The gender based differences were also not found to be statistically significant, but male gender did have higher values compared to females.

DISCUSSION

Though there are few studies performed on the morphometry of kidneys in children, same are

scarce in adult subjects. Only a few reports have been published on renal measurements in adults [24]. It was reported that changes in kidneys length, width and volume could be associated with atherosclerotic kidney disease, arterial hypertension, renal vascular disease and diabetes mellitus or indicative of these [20]. The knowledge about renal dimensions is also useful in managing the patients with vesico-ureteric reflux which alters the morphometric profile of kidney [25]. Renal sizes depends on different factors, including gender, body size and body mass index. Ethnic differences due to above variables are therefore expected. While data at normal ranges of renal dimensions are available from western literature, little data are available from the Indian subcontinent [16].

Weight of Kidney: In the present study, there was a wide range in weight of kidneys as few kidneys were found to be atrophic and few were large and cystic. So both mean and median are calculated. The smallest kidney (Fig. 1) was 16 gm in weight, which appeared to be atrophic. The largest kidney was 206 gm in weight because of presence of a large solitary cyst (Fig. 2) at its upper pole.

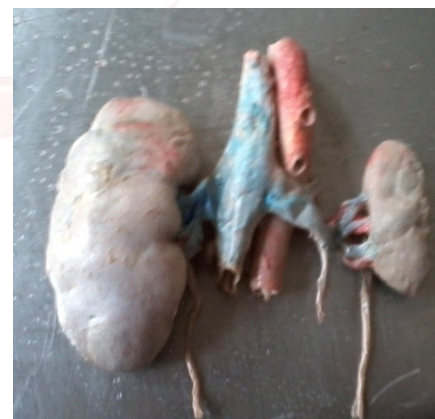

Fig. 1: Smallest Kidney (16gms).

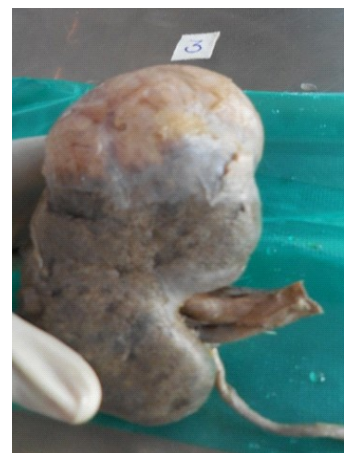

Fig. 2: Largest Kidney (206gms) with large solitary cyst.

The mean weight of left kidney came out to be 103.6 gm (S.D=30.45) Median of left kidney was 101 gm. The mean weight of right kidney was 104.8 gm (SD=34.53) Median of right kidneys was 108 gm. The average of means of the right and left kidneys was 104.2 gm.

Though age of cadavers is not taken into consideration in the present study, which is a shortcoming, but most of the cadavers are above 60 years of age. According to Alam [26], weight of kidneys increased up to 40yrs, and then declined. Kidneys weighed about 130 gm according to Sinnatamby [27]. Anderson et al said, kidney lose its functioning cells with age that do not have the ability to divide. From 4th decade to 8th decade of life, the human kidneys lose approximately a fifth of their weight as studied by Maclachlan [28], Basmajinan [29] stated that in adult, the kidney weighed about 130 to 150gms. Mullick [30] worked on Bangladeshi population and found the average weight of the kidney is 113gms. Hamida Khatun [5], too studied kidneys on Bangladeshi population and found the mean weight to be 92.08 gm and stated that their population had considerably lower weights in comparison to the western people. The current study too demonstrated mean weight of 104.2gms and had almost similar results like the above study.

Length of Kidney: In the present study the mean renal length on left side came out to be 8.80 ± 1.88 cms on the right side 8.69 ± 1.34 cms, and a range of 7-11.8 excluding the small atrophic kidney. Though not statistically significant but left was longer than the right kidney.

In the clinical setup, for everyday situations, measurements of renal length are recommended since the measurement is easy and the obtained values could be compared with values in the reference figures. Emamian et al [24] reported that the median renal lengths were 11.2 cm on left side and 10.9cm on right side. According to a study by Shin et al (2009), the mean right and left renal lengths were 10.7 ± 0.76 and 9.9 ± 0.72 cm respectively and left kidney was significantly ($p < 0.05$) longer than right kidney. According to Mounier-Vehier et al [4], the size of a renal kidney was variable from one to another, decreasing after the age of 70 [24]. The normal values

cited were 11 ± 0.2 cm, the kidney being considered small for any intervention if it is below 8 cm [31]. The average renal length observed by Buccholz et al [13] was 10.4 ± 0.8 cm and was probably a reflection of the relatively small body size of south east Asian. Autopsy findings of renal biometry in Indian population yielded comparable results with kidney length ranging between 9.1 – 9.9 cm (Sahni). In contrast, Nigerians had been reported to have larger kidneys lengths averaging 10.3 – 10.6 cm with likewise result in Mexican population [32,33]. Sampaio and Manderim-de-Lacerda [14] in 1989 studied renal morphometry stating average renal length 10.97cm and 11.21cm for the right and left kidneys respectively. In Bangladeshi's the average length was 9.9cm according to Mullick [30] and in a range of 7-11.5cm (Average 8.99 cm) according to Hamida [5].

The result of present study and other Indian studies as stated in Indian journal of Medicine in 2014 and a study by Murlimanju [2] was that the mean renal length in an Indian population was smaller than Caucasians, Brazilians, Koreans and Japanese Population, but closer to Pakistanis, Malaysians, Nigerians, Jamaicans and Bangladeshis. The reasons for this was ascribed to be due to difference in height, weight, BSA, BMI and other anthropometric measurements amongst races. The authors have shown a positive correlation between renal lengths and weight, height, BMI [16] and this had been corroborated other study [34]. It was also worthy to note that no significant difference were found between the mean left and right renal lengths or gender dependent differences [16], whereas such differences were observed in studies on western population [20]. Presence of liver on right side with less spatial growth of the corresponding kidney and greater blood flow to the left kidney on account of a shorter left renal artery were explanations hypothesized [24].

So, a standard for Indian population should be set on the basis of South East Asian or Indian Studies. Renal size of 9cm, widely accepted as the cut-off to indicate irreversible renal disease in most populations [13,20] was a size mainly seen in normal and healthy Indian adults [16]. Asymmetry indicated a renovascular etiology,

especially when associated with chronic renal failure, hypertension or low-grade proteinuria [35, 36, 37, 38].

Breadth and Thickness of kidney: The breadth of the kidney in the present study came out to be 4.08 ± 0.57 on left side and 4.085 ± 0.55 on right side. The thickness of kidneys in present study was 3.30 ± 0.59 on left side and 3.32 ± 0.66 on right side, demonstrating a considerable thickening of right kidney compared of left. The mean breadth of kidney as studied by Muthsami [16] was 4.5 ± 0.42 . Mullick³⁰ observed breadth and thickness as 4.6cm and 3.7cm respectively in Bangladeshis, Hamida Khatun [5] got the values of breadth and thickness as 4.08cm (3.65cm) and 1.78cm (1.14-2.87cm) respectively. Murlimanju [2] studied the upper and lower pole separately. The mean width at superior pole of right kidney was 5 ± 0.7 cm. the width at inferior pole of the right and left kidneys were 4.8 ± 0.6 cm and 4.5 ± 0.7 cm respectively. The mean thickness of the superior pole of the right and left kidneys were 3 ± 0.4 cm and 3.2 ± 0.5 cm respectively. And the mean thickness of the inferior pole of the right and left kidneys of the inferior pole of the right and left kidneys were 3.1 ± 0.4 cm and right and left kidneys were 3.1 ± 0.4 cms and 3.2 ± 0.5 cm respectively. This study showed no statistical significance between right and left kidneys related to width and thickness. The present study was quite consistent with the above study.

A study by C. Surcel [3] stated the values of breadth as 5.19 ± 0.78 cm in right kidney and 5.17 ± 0.82 cm in left kidney; anteroposterior diameter or thickness of right kidney was 5.37 ± 0.8 cm and left kidney was 5.29 ± 0.82 cm and showed a statistical significance ($p < 0.001$) between right and left kidneys. The kidneys became wider and thicker with age, possibly because of relaxation of abdominal wall with age, so that kidneys are less squeezed in older individuals. Right kidneys squeezed more because of liver, so wider [24].

Position of kidney in relation to spine: The present study had showed that most of the cadavers (69.38 %) had right kidneys at a lower level than the left (Fig. 3). But some cadavers presented both kidneys at the same level. This could be possibly because of smaller size of

kidneys which remained caudal in their location. The influence of kidney position on its size is obvious, as it is positioned further cranial and dorsal, the longer the kidney is. These data are known in particular with cases of pelvic kidney localization [39, 40].



Fig. 3: Position of Kidney in relation to spine (right lower than left).

Helm found that the right kidney was lower than the left in two-thirds of cases, and that in males, the kidneys were approximately one-half of the height of a vertebral body higher than in females. In most cases, the upper pole of the kidney was at the level of T11-T12 while the level of lower pole varied from the top of L3 to L3-L4 interspace. Budinger studied that in most cases, the upper poles were at the level of T11-T12 and the lower poles were opposite L3-L4. Moody and Van Nuys studied roentgenographically that in males, the upper and lower poles on the right were at the level of T12-L1 and L3-L4 respectively, while the upper and lower poles on the left were at the level of T11-T12 and L2-L3 respectively. In females, the corresponding levels on the right were T12-L1 and L3-L4 and those on the left were T11-T12 and L2-L3. Edsman [41] evaluated roentgenographically that the centre of right kidney was on an average 0.2 unit cranial to the upper third of L2 and the left kidney was 0.5 unit caudal to the lower third of L1. Guido Currarino [17] stated the position of renal pelvis in relation to spine with most common location between L1-L2 interspace and lower half of L2 on right side, and the lower half of L1 and upper half of L2 on left side.

In the present study, hilum of right kidney was mostly at the level of upper border of L2 and between L1-L2. On the left side, the hilum of

most kidneys was at the level of lower border of L1 (Figure 3).

Table 13: Position of Kidney in Relation to Spine.

Position of Kidney with Relation to Spine	
At Same Level	15 (30.61 %)
Right Kidney at Lower Level	34 (69.38 %)

Cortical Width: The present study results of mean cortical width came out to be 0.76 +/- 0.21cm on left side and 0.75 +/- 0.22 cm on right side.

Mounier-Vehier et al [4] studies that cortical thickness was a good morphological marker for the diagnosis of acute renal disease. According to his study, the mean cortical thickness on right side was 0.91 +/- 0.06cm and on left side was 0.92 +/- 0.1cm in control kidneys had mean cortical thickness of 0.66 +/- 0.16cm and the contralateral non-stenotic kidneys had mean cortical thickness of 0.79 +/- 0.14cm. this study suggested that cortical thickness is a good marker of ARD, considering that they occur earlier than the reduction of kidney size. It also revealed significant lesions in contralateral kidneys without stenosis displaying the consequences of atherosclerotic disease and chronic hypertension [35,36,42,43,44] According to C. Surcel [3], the mean cortical width of right kidney was 0.65 +/- 0.19cm and of left kidney was 0.64 +/- 0.2cm. He stated that length cortical width, parenchymal width remains high until fifth decade of life and thereby decrease for both sexes. There are linear correlations between height of an individual and BMI Cortical width and Parenchymal width.

Renal atrophy could be a direct consequence of renal hypoperfusion [45,46]. Activation of renin-angiotensin system due to hypoperfusion has several deleterious effects such as inducing tubule-interstitial atrophy [35,36,46,47] and renal vascular lesion like nephrosclerosis [37,43,44,45,46,47]. Mean cortical thickness could help clinician recognize when revascularization is indicated. Prince et al studied the cortical area and identified a threshold of 800 mm² that allowed to distinguish between control kidneys from post-stenotic kidneys. Similarly, Mounier-Vehier⁴ identified a threshold of 8mm for mean cortical thickness.

Very few Indian based studies are available in

context with cortical thickness, but going with the study by C. Surcel [3] and Glodney [20] and considering the ethnic differences our kidneys were comparatively smaller and threshold value should be set at a lower limit. In this study 9 kidneys out of 99 demonstrated very low cortical width of less than 0.31cm.

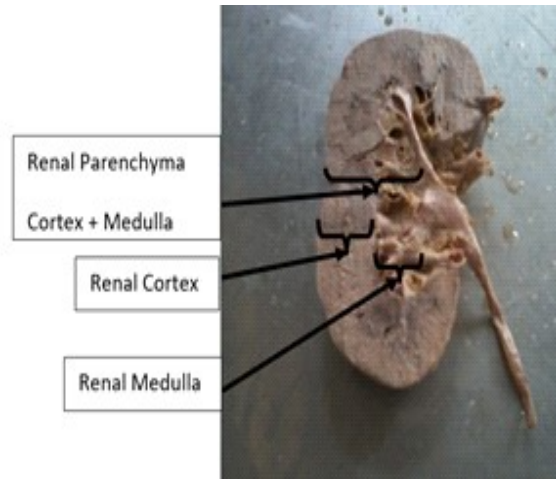


Fig. 4: Cross-section of Kidney.

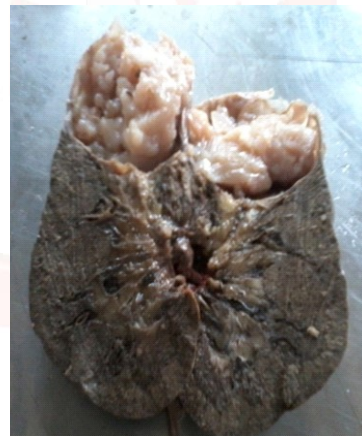

Fig. 5: Compression of parenchyma by a large cyst.

Table 14: Showing No. of Kidneys with low Cortical Width.

Cortical Width	Right	Left
	Normal	45
Less Than Normal	5	4

Parenchymal width: In this study, the mean PW on right side came out to be 1.95 +/- 0.36 and on left side 1.96 +/- 0.38cm consistent with various other studies. 8 out of 99 kidneys had very less parenchymal width. i.e. below 1.47 cm.

Table 15: Showing No. of Kidneys with low Parenchymal Width.

Parenchymal Width	Right	Left
	Normal	47
Less Than Normal	3	5

Glodney [20] studied the morphometrical dimensions of kidney and stated a mean parenchymal width of 1.54 +/- 0.28 on right side and 1.58 +/- 0.27 on left side. In men it was 1.63 +/- 0.27 on right side and 1.65 +/- 0.24 on left side. In women, it was 1.45 +/- 0.26 on right and 1.5 +/- 0.24 on left side. Gender BMI height absence of contralateral kidney is the factors influencing cortical width, parenchymal width and length of the kidney. A study by Muthuswami¹⁶ gave a mean value of parenchymal width to be 2.04 +/- 0.2 cm and demonstrated a significant difference between right and left kidneys, but no gender difference. Age-group wise analysis showed significant decrease in parenchymal width beyond seventh decade.

According to Okoye [15] the range of values of RPT was 1.40-2.4 and the corresponding mean values were 1.91 +/- 0.20 and 1.95 +/- 0.19cm for the left and right kidneys respectively. It also showed a strong positive correlation between RPT and RL. It stated that renal parenchymal thickness of 1.40 cm or less should not be biopsied. No gender difference in RPT was found.

Roger [48] stated that like renal length, parenchymal thickness gives an indication of the chronicity of renal failure. However, some patients with parenchymal thickness 1.5cm or less still have potential for improvement. So this measurement alone should not be used to obviate renal biopsy.

Polycystic kidney disease significantly replaced the parenchyma and caused its thinning and fibrosis. A few polycystic kidneys had been found in the present study with parenchymal thinning (Figure 5).

CONCLUSION

It can be concluded that ethnicity considerably affects the parameters, so more Indian based studies are to be done so that they could be used as a reference. Establishing anatomical dimensions is necessary for defining the pathological changes in the kidney. The present study can be used as a reference for anatomical dimensions of kidney to surgeons, radiologists and nephrologists.

Similarly, the knowledge of renal-vascular anomalies is of immense importance in various

renal surgeries. This could help the clinician in its prior recognition and due protection accordingly during renal surgeries or interventions like radiological imaging's, renal transplant, renal artery embolization, endovascular hypertension and radical renal surgery.

Conflicts of Interests: None

REFERENCES

- [1]. Healy JC. Urogenital system in Standring S, editor. Gray's anatomy 40th ed. The Anatomical Basis of Clinical Practice. London: Churchill Livingstone Elsevier; 2008; 1225-1313.
- [2]. Murlimanju BV, Buraje MK, Kumar N, Prashanth KU, Rao CP, Guru A et al. Morphometric parameters of the human adult kidney: An anatomical study. *Int. J. Morphol.* 2014; 32(2): 656-9. <https://doi.org/10.4067/S0717-95022014000200045>
- [3]. Surcel C, Mirvald C, Gingu C, Udrea A, Savu C, Sinescu I. Morphological aspects of the kidney: Can normality be predicted? *Rom J Morphol Embryol.* 2011;52(4):1325-30. <http://www.ncbi.nlm.nih.gov/pubmed/22203941>.
- [4]. Mounier-Vehier C, Lions C, Devos P, Jaboureck O, Willoteaux S, Carre A et al. Cortical thickness: an early morphological marker of atherosclerotic renal disease. *Kidney Int.* 2002;61(2):591-8. <https://doi.org/10.1046/j.1523-1755.2002.00167.x> PMID:11849401
- [5]. Khatun H, Sultana Z, Nur-A-Farhana Islam, Kibria GM, Tawfiq- E-Elahi Chy. Morphological Study of the Kidney in Relation to Age. *Bangladesh J. Anat.* 2009;7(1) :19-21. <https://doi.org/10.3329/bja.v7i1.3012>
- [6]. Mandal S, Mandal P, Basu R. Bilateral Accessory Renal Arteries, Additional Right Renal Vein and Retroaortic Left Renal Vein- A Case Report. *Int J Health Sci Res.* 2013;3(2):88-93.
- [7]. Benny Holmberg Umeå University Medical Dissertations New series No 1574 - ISSN 0346-6612 - ISBN 978-91-7459-554-3, 2013.
- [8]. Naveen kumar S, Seema M, Atoofa J, Sireesha JV. A study of accessory renal arteries and their incidence. *Indo American Journal of Pharm Research.* 2014;4(02).
- [9]. Gava AL, Freitas FPS, Meyrelles SS, Silva IV and Graceli JB. Gender-dependent effects of aging on the kidney. *Braz J Med Biol Res* 2011;44(9):905-913. <https://doi.org/10.1590/S0100-879X2011007500101> PMID:21956533
- [10]. Simon AL. Normal Renal Size: An Absolute Criterion. *Am J Roentgenol Radium Ther Nucl Med.* 1964; 92:270-2.
- [11]. Kadioglu A. Renal measurements, including length, parenchymal thickness, and medullary pyramid thickness, in healthy children: what are the normative ultrasound values? *AJR Am J Roentgenol.* 2010;194(2):509-15. <https://doi.org/10.2214/AJR.09.2986> PMID:20093617

- [12]. de Lucas C, Nocea A, San RJ, Espínola B, Ecija JL, Vázquez Martul M. [Solitary kidney. Study of renal morphology and function in 95 children]. *Nefrologia*. 2006;26(1):56-63.
- [13]. Buchholz NP, Abbas F, Biyabani SR, Afzal M, Javed Q, Rizvi I, Talati J. Ultrasonographic renal size in individuals without known renal disease. *J Pak Med Assoc*. 2000;50(1):12-6.
- [14]. Sampaio FJ, Mandarim-de-Lacerda CA. [Morphometry of the kidney. Applied study in urology and imaging]. *J Urol (Paris)*. 1989;95(2):77-80.
- [15]. Okoye IJ, Agwu KK, Eze CU. Relationship between sonographic renal length and renal parenchymal thickness in normal adult southeast Nigerians. *West Afr J Med*. 2006 ; 25(3):231-4. <https://doi.org/10.4314/wajm.v25i3.28284> PMID:17191425
- [16]. Muthusami P, Ananthkrishnan R, Santosh P. Need for a nomogram of renal sizes in the Indian population- findings from a single centre sonographic study. *Indian J Med Res*. 2014 May;139(5):686-93.
- [17]. Currarino G, Winchester P. Position of the kidneys relative to the spine, with emphasis on children. *Am J Roentgenol Radium Ther Nucl Med*. 1965 Oct;95(2):409-12. <https://doi.org/10.2214/ajr.95.2.409> PMID:5832189
- [18]. Gourtsoyiannis N, Prassopoulos P, Cavouras D, Pantelidis N. The thickness of the renal parenchyma decreases with age: a CT study of 360 patients. *AJR Am J Roentgenol*. 1990 Sep;155(3):541-4. <https://doi.org/10.2214/ajr.155.3.2117353> PMID:2117353
- [19]. Bax L, van der Graaf Y, Rabelink AJ, Algra A, Beutler JJ, Mali WP; SMART Study Group. Influence of atherosclerosis on age-related changes in renal size and function. *Eur J Clin Invest*. 2003 Jan;33(1):34-40. <https://doi.org/10.1046/j.1365-2362.2003.01091.x> PMID:12492450
- [20]. Glodny B, Unterholzner V, Taferner B, Hofmann KJ, Rehder P, Strasak A, Petersen J. Normal kidney size and its influencing factors - a 64-slice MDCT study of 1.040 asymptomatic patients. *BMC Urol*. 2009 Dec 23;9:19. <https://doi.org/10.1186/1471-2490-9-19> PMID:20030823 PMCid:PMC2813848
- [21]. Johnson S, Rishi R, Andone A, Khawandi W, Al-Said J, Gletsu-Miller N, Lin E, Baumgarten DA, O'Neill WC. Determinants and functional significance of renal parenchymal volume in adults. *Clin J Am Soc Nephrol*. 2011 Jan;6(1):70-6. <https://doi.org/10.2215/CJN.00030110> PMID:20847095 PMCid:PMC3022251
- [22]. Wang X, Vrtiska TJ, Avula RT, Walters LR, Chakkera HA, Kremers WK, Lerman LO, Rule AD. Age, kidney function, and risk factors associate differently with cortical and medullary volumes of the kidney. *Kidney Int*. 2014 Mar;85(3):677-85. <https://doi.org/10.1038/ki.2013.359> PMID:24067437
- [23]. Venkataramulu M, Vinaykumar N, Prasanna LC. Renal vascular morphology and their significance in predicting accessories. *Int J Res Med Sci* 2014;2:506-9.
- [24]. Emamian SA, Nielsen MB, Pedersen JF, Ytte L. Kidney dimensions at sonography: correlation with age, sex, and habitus in 665 adult volunteers. *AJR Am J Roentgenol*. 1993 Jan;160(1):83-6v. <https://doi.org/10.2214/ajr.160.1.8416654> PMID:8416654
- [25]. Dixit PK, Sahai SB, Rath B, Garg A, Chowdhury V. Norms for renal parenchymal volume in Indian children. *Indian Pediatr*. 1994 Sep;31(9):1059-64.
- [26]. Alam MZ. Gross morphological and histological features of kidneys in Bangladeshi people [thesis] 1994: Department of Anatomy, IPGM and R.
- [27]. Sinnatamby CS. Last's anatomy regional and applied. 10th ed. Edinburg: Churchill Livingstone 1999:p.267-280.
- [28]. MacLachlan MSF. The aging kidney. *Lancet* 1978;11:143-6. [https://doi.org/10.1016/S0140-6736\(78\)91522-2](https://doi.org/10.1016/S0140-6736(78)91522-2)
- [29]. Basmajian JV, Slonecker CE. Grant' method of anatomy. 11th ed. Baltimore: William and Wilkins 1989:p.182-187. [https://doi.org/10.1016/0003-2697\(89\)90740-9](https://doi.org/10.1016/0003-2697(89)90740-9)
- [30]. Mullick MH. The arterial pattern of human kidney. *Journal of Pakistan medical association* 1970;XX(3):77-83.
- [31]. Aitchison F, Page A. Diagnostic imaging of renal artery stenosis. *J Hum Hypertens*. 1999 Sep;13(9):595-603. <https://doi.org/10.1038/sj.jhh.1000871> PMID:10482969
- [32]. Okoye IJ, Agwu KK, Idigo FU. Normal sonographic renal length in adult southeast Nigerians. *Afr J Med Med Sci*. 2005 Jun;34(2):129-31.
- [33]. Oyuela-Carrasco J, Rodríguez-Castellanos F, Kimura E, Delgado-Hernández R, Herrera-Félix JP. [Renal length measured by ultrasound in adult mexican population]. *Nefrologia*. 2009;29(1):30-4.
- [34]. Arooj A, Lam J, Wui YJ, Supriyanto E. Comparison of renal size among different ethnicities. *Int J Biol Biomed Eng*. 2011;5:221-9.
- [35]. Preston RA, Epstein M. Ischemic renal disease: an emerging cause of chronic renal failure and end-stage renal disease. *J Hypertens*. 1997 Dec;15(12 Pt 1):1365-77. <https://doi.org/10.1097/00004872-199715120-00001> PMID:9431840
- [36]. Meyrier A, Hill GS, Simon P. Ischemic renal diseases: new insights into old entities. *Kidney Int*. 1998 Jul;54(1):2-13. <https://doi.org/10.1046/j.1523-1755.1998.00968.x> PMID:9648058
- [37]. Bijlstra PJ, Postma CT, de Boo T, Thien T. Clinical and biochemical criteria in the detection of renal artery stenosis. *J Hypertens*. 1996 Aug;14(8):1033. <https://doi.org/10.1097/00004872-199608000-00015>
- [38]. Krijnen P, van Jaarsveld BC, Steyerberg EW, Man in 't Veld AJ, Schalekamp MA, Habbema JD. A clinical prediction rule for renal artery stenosis. *Ann Intern Med*. 1998 Nov 1;129(9):705-11. <https://doi.org/10.7326/0003-4819-129-9-199811010-00005> PMID:9841602

- [39]. Davidovits M, Eisenstein B, Ziv N, Krause I, Cleper R, Bar-Sever Z. Unilateral duplicated system: comparative length and function of the kidneys. *Clin Nucl Med*. 2004 Feb;29(2):99-102. <https://doi.org/10.1097/01.rlu.0000109331.37224.5f> PMID:14734907
- [40]. Luke PP, McAlister VC, Jevnikar AM, House AA, Muirhead N, Cross J, Hollomby D, Chin JL. Use of a pelvic kidney for living transplantation: case report and review of the literature. *Am J Transplant*. 2003 Feb;3(2):235-8. <https://doi.org/10.1034/j.1600-6143.2003.00046.x> PMID:12603220
- [41]. Edsman G. Angionephrography and suprarenal angiography; a roentgenologic study of the normal kidney, expansive renal and suprarenal lesions and renal aneurysms. *Acta Radiol Suppl*. 1957;(155):1-141.
- [42]. Prince MR, Schoenberg SO, Ward JS, Londy FJ, Wakefield TW, Stanley JC. Hemodynamically significant atherosclerotic renal artery stenosis: MR angiographic features. *Radiology*. 1997 Oct;205(1):128-36. <https://doi.org/10.1148/radiology.205.1.9314974> PMID:9314974
- [43]. Karasch T, Rubin J. Diagnosis of renal artery stenosis and renovascular hypertension. *Eur J Ultrasound*. 1998 Jul;7 Suppl 3:S27-39. [https://doi.org/10.1016/S0929-8266\(98\)00029-9](https://doi.org/10.1016/S0929-8266(98)00029-9)
- [44]. Kasiske BL. Relationship between vascular disease and age-associated changes in the human kidney. *Kidney Int*. 1987 May;31(5):1153-9. <https://doi.org/10.1038/ki.1987.122> PMID:3599655
- [45]. Lerman LO, Schwartz RS, Grande JP, Sheedy PF, Romero JC. Noninvasive evaluation of a novel swine model of renal artery stenosis. *J Am Soc Nephrol*. 1999 Jul;10(7):1455-65.
- [46]. Textor SC. Revascularization in atherosclerotic renal artery disease. *Kidney Int*. 1998 Mar;53(3):799-811. <https://doi.org/10.1038/ki.1998.37> PMID:9507232
- [47]. Goldblatt H, Lynch J, Hanzal RF, Summerville ww. Studies on experimental hypertension : The production of persistent elevation of systolic blood pressure by means of renal ischemia. *J Exp Med*. 1934 Feb 28;59(3):347-79. <https://doi.org/10.1084/jem.59.3.347>.
- [48]. Roger SD, Beale AM, Cattell WR, Webb JA. What is the value of measuring renal parenchymal thickness before renal biopsy? *Clin Radiol*. 1994 Jan;49(1):45-9 [https://doi.org/10.1016/S0009-9260\(05\)82913-7](https://doi.org/10.1016/S0009-9260(05)82913-7)
- [49]. Gujar SM; Parmar JK. A study of morphological variations in renal artery. *International Journal of Biomedical and Advance Research*, [S.l.], 2012;3(11):815-817. <https://doi.org/10.7439/ijbar.v3i11.824>
- [50]. Gillaspie C., Miller L.I., and Baskin M.; Anomalous renal vessels and their surgical significance, *Anat Rec.*, 1916;11:77. <https://doi.org/10.1002/ar.1090110304>
- [51]. Praveen Kumar DR, Janaki CS, Vijayaraghavan V, Usha K, Chandrika T, Ambareesh: Bilateral variations of renal vasculature : a case report. *Int J Med Res Health Sci*. 2013;2(3): 678-681. <https://doi.org/10.5958/j.2319-5886.2.3.054>
- [52]. Dyson M. Urinary system in Williams PL, Bannister LH, Berry MM, Collins P, editors. *Gray's anatomy*. 38th ed. Newyork, Edinburgh, London: Churchill Livingstone; 1995.
- [53]. Moore KL, Persuad TVN. The developing human: Clinically oriented embryology. 8th ed. Philadelphia: Saunders Elsevier; 2008. P. 243-56.
- [54]. Hamilton WJ, Boyd and Mossman. *Human Embryology*. 4th ed. The University of Michigan; Heffer Publication; 1972.p. 383-93.
- [55]. Sadler TW, editor. *Langman's medical embryology*. 9th Ed. Baltimore; Lippincott Williams and Wilkins; 2006.p. 229-38.
- [56]. Drake RL, Vogyl W, Mitchell AWM. *Gray's Anatomy for Students*. 1st ed. London: Churchill Livingstone Elsevier; 2005.p. 314-24.
- [57]. Eroschenko VP, editor. *diFlore's Atlas of Histology with functional correlations*. 11th ed. Maryland, Philadelphia: Wolter Kluwer Health/Lippincott Williams and Wilkins; 2008.p. 355-73.

How to cite this article:

Shweta B Shambharkar, Shabana Borate, Amandeep Kaur Ratta, Suresh Gangane. MORPHOLOGICAL STUDY OF KIDNEY IN CADAVERS OF WESTERN MAHARASHTRA REGION. *Int J Anat Res* 2020;8(3.2):7680-7691. DOI: 10.16965/ijar.2020.188