CLINICO MYCOLOGICAL STUDY OF TINEA CAPITIS

Dissertation submitted in fulfillment of the University regulations for

MD DEGREE IN

DERMATOLOGY, VENEREOLOGY AND LEPROSY

(BRANCH XX)

APRIL 2012

THE TAMILNADU DR. M.G.R. MEDICAL UNIVERSITY

CHENNAI

CERTIFICATE

Certified that this dissertation entitled **"CLINICO MYCOLOGICAL STUDY OF TINEA CAPITIS"** is a bonafide work done by **Dr.K.GEETHA**, Post Graduate Student of the Department of Dermatology, Venerology and Leprosy, Madras Medical College, Chennai – 600 003 during the academic year 2010-2012. This work has not been submitted previously for the award of any degree.

Prof. Dr. S.JAYAKUMAR, M.D., D.D.
Professor and Head of Department,
Department of Dermatology & Leprology,
Madras Medical College,
Chennai – 600 003.

Prof. Dr .V.KANAGASABAI, M.D.,
Dean,
Madras Medical College &
Rajiv Gandhi Govt. General Hospital,
Chennai – 600 003.

DECLARATION

I, **Dr.K.GEETHA,** solemnly declare that dissertation titled, **"CLINICO MYCOLOGICAL STUDY OF TINEA CAPITIS"** is a bonafide work done by me at Department of Dermatology and Leprosy, Madras Medical College, Chennai-3 during the period of June 2010 to October 2011 under the supervision of my **Prof. Dr.S.JAYAKUMAR, M.D, D.D,** Professor and HOD, The Department of Dermatology and Leprosy, Madras Medical College, Chennai. The dissertation is submitted to Tamilnadu Dr. M.G.R. Medical University, towards partial fulfilment of requirement for the award of **M.D. Degree (Branch-XII A) in DERMATOLOGY, VENEREOLOGY AND LEPROSY**.

Signature of the Candidate

Place: Chennai

Date:

SPECIAL ACKNOWLEDGEMENT

I gratefully acknowledge and sincerely thank **Prof.Dr.V.KANAGASABAI, M.D.,** Dean, Madras Medical College and Rajiv Gandhi Government General Hospital, Chennai-600 003, for granting me permission to utilize the resources of this institution for my study.

Place: Chennai

Date:

ACKNOWLEDGEMENT

It is with immense pleasure and gratitude that I thank **Prof.Dr.V.KANAGASABAI, M.D., Dean**, **Madras Medical College,** for bestowing on me the permission and privilege of presenting this study and for enabling me to avail the institutional facilities.

I am gratefully indebted to **Prof. Dr. S.JAYAKUMAR, M.D.,D.D.,** Professor and Head of Department of Dermatology and Leprology for his invaluable guidance and motivation.

I express my deep sense of gratitude to **Prof. Dr. SUDHA, M.D., D.V., D.D.,** Professor and Head of Department of Venereology and **Dr. P.ELANGOVAN M.D.,D.V.,** Professor, Department of Venereology for their constant support and motivation.

I am grateful to **Dr. R.ARUNA DEVI, M.D., D.D**., Professor and Head of Leprology for her support and inspiration. Words will not suffice the gratitude I owe to my guide **Dr.C.JANAKI, M.D., D.D.,** Professor Department of Dermatology for her peerless guidance and endless patience in moulding of the study. I am grateful to **Dr. V.SAMPATH, M.D., D.D.,** Professor of Dermatology for his guidance and support.

I sincerely thank **Prof. Dr. S.NIRMALA, M.D., D.D.,** Professor and Head of the Department of Occupational Dermatology and Contact Dermatitis for her valuable advice. I express my earnest gratitude to **Dr.S.PRIYAVATHANI, M.D., D.D., D.N.B.,** Associate Professor, Department of Occupational Dermatology and Contact Dermatitis for her helpful suggestions and support.

I would like to express my sincere and heartfelt thanks to former professor **Dr. D. PRABAVATHY**, **M.D.,D.D.,** Department of Dermatology, for her guidance and encouragement. I extend my sincere and special thanks to **Dr. S.V. SOMASUNDARAM, M.D.,D.D,** Former professor, Department of Occupational Dermatology and Contact Dermatitis for his notable guidance.

I sincerely thank **Dr. MADHU, M.D., D.C.H.,** Assistant Professor, for her valuable guidance and support. I thank all our Assistant Professors, Department of Dermatology, **Dr. J. MANJULA, M.D.,DNB., Dr. G. K.THARANI**, **M.D.,D.D., Dr. C. VIJAYABASKAR, M.D.,D.C.H., Dr. S.J. DANIEL, M.D.,D.V.L., Dr. S. SARAVANAN, M.D.,D.V.L., Dr. S. MATHAVI, M.D.D.V.L.,** for their enthusiasm in motivating me with their competency to materialise this study.

I am inclined to thank **Dr.V.THIRUNAVUKARASU, M.D., D.V., Dr.P.MOHAN**,**M.D.,D.V., Dr.V.N.S.AHAMED SHARIFF, M.D.,D.V.L., Dr. P. PRABHAKAR, M.D.,D.V.L., Dr. K. UMAMAHESWARI, M.D.,D.V.L.,Dr. R.SOWMIYA, M.D.,D.V.L., Dr.C.VIDHYA, M.D.,D.V.L.,** assistant professors, Institute of Venereology, for their help and suggestions.

I thank my former assistant professors **Dr.S.KUMARAVEL, M.D., D.D., Dr. A.HAMEDULLAH**, **M.D.,D.D., Dr.AFTHAB JAMEELA WAHAB, M.D.,D.D., Dr. N. HEMA,M.D., Dr.K.VENKATESWARAN, M.D.,D.V., Dr.S.KALAIVANI, M.D.,D.V., Dr.S.ARUNKUMAR, M.D.,** for their valuable support.

Due credit goes to the staff members and my colleagues for their support throughout my study.

I am profoundly grateful to all my patients and their parents for their whole hearted participation.

CONTENTS

INTRODUCTION

Tinea capitis is also known as “Ringworm of the hair/scalp”, “Tinea tonsurans”, and “Herpes tonsurans” [1]. It is a superficial fungal infection of the scalp and scalp hair that is caused by dermatophytes belonging to the genera *Trichophyton* and *Microsporum* [2, 4].

The causative fungi may vary with geography and time. Tinea capitis is predominantly an infection of children, although adult cases are also seen. It may be caused by any pathogenic dermatophyte except *E.floccosum*, *T.concentricum* and *T.mentagrophytes var interdigitale*[1,2] . The most common cause worldwide is *M.canis* whereas in the United States it is *T.tonsurans* and it is *T.violaceum* in south India [2, 5, 6, 73].

In any given location, the species may change with time particularly as new organisms are introduced by immigration [5]. Hence a study was undertaken in Rajiv Gandhi Government general Hospital, Chennai to identify the various etiological agents, various clinical types, to study the epidemiological aspects and to determine the clinico-mycological correlation of tinea capitis.

REVIEW OF LITERATURE

TINEA CAPITIS

HISTORY:

In 400AD Cassius Felix first coined the term “Tinea” to mean “ringworm” in Latin[6] .Sabouraud the father of modern mycology stated that the word “Tinea” indicated the insect whose larvae feed on clothes and books [2, 5].

Systematic study of superficial fungal infections began more than 150 years ago when Remak described the mycelial nature of the clinical disease favus. In 1841, Gruby isolated the organism of favus in culture and experimentally reproduced the disease with inoculation in normal skin [1, 5] . However it was not until 1910, that Raymond Sabouraud published his seminal treatise “Les Tiegnes”, classifying the dermatophytes into four genera based on their microscopic and clinical characteristics. In 1934, Emmon’s clinical review of dermatophyte taxonomy resulted in three genera known today, namely *Microsporum*, *Epidermophyton*, and *Trichophyton* [1, 4].

In 1892, Sabouraud discovered the main types of tinea capitis. He described simple culture methods that were easily reproduced and by the end of the 19th century, his method had been adopted worldwide [1, 3, 5]. Sabouraud in his dissertation, demonstrated the endothrix type of tinea capitis[5].

Treatment using X-ray epilation was reported in 1904. Effective treatment of tinea capitis by griseofulvin became available in the 1950's [5, 27]

EPIDEMIOLOGY:

Tinea capitis is worldwide in distribution. Various studies have been conducted on tinea capitis all over the world [7].

Tinea capitis occurs predominantly in pre pubertal children over the age of six months; though it can occur in all age groups [11, 27].It is found most commonly in children in the age group of 3 to 14 years [71].It is uncommon in adults. The youngest age reported was 2nd, 5th, 6th, and 8th day old neonates [19,58].The increased incidence among the Pre pubertal children has been attributed to absence of sebum containing fatty acids which have a fungi static property [11].In *M.audouinii* infection, the disease is self limited and seldom extends beyond puberty . *T.tonsurans* infection extends into the adult population, more commonly than *M.audouinii* infection[81].

Boys outnumbered girls in a ratio of 5:1. The shortness of hair in boys and the ease with which the spores can reach the scalp used to explain the increased incidence in boys as compared to girls who generally have long hair[2,11]. *Trichophyton tonsurans* infection of the scalp affects girls and boys equally, but favours female in adults [5, 81].

Transmission is increased with poor personal hygiene, overcrowding and low socio-economic status [3, 77]. Organisms responsible for the tinea capitis have been cultured from fomites such as combs, caps, pillow cases and theatre seats[3, 68]. Even after shedding, hair may harbor infectious organisms for over a year [71]. Asymptomatic carriers are common making tinea capitis difficult to eradicate [1,2,3,12].It was earlier believed that tinea capitis was rare or nearly absent in India due to the use of vegetable oils by the Indians on the scalp for hairdressing,[8] but it was later observed that tinea capitis was by no means rare. A study in the rural areas of south India found that the incidence of tinea capitis was28.5% and was mainly due to *T.violaceum*[72]. In 1941, Dey and Maplestone isolated *T.tonsurans* for the first time in India [74,78].

In 1971, Kamalam and Thambiah observed that tinea capitis was endemic in school children in Madras and about 81% of cases were due to *T.violaceum*. According to them, trauma to the scalp during shaving of the head for religious purposes was an important contributory factor [11].

Bhardwaj et al found tinea capitis to be very common in Kashmir[14]. Studies in Delhi have shown that around 68% of patients came from overcrowded areas with low socio- economic and poor hygienic status [3, 15, 16]. Protein deficiency has also been blamed along with vitamin A deficiency, as predisposing to dermatophyte infections [17].

Vegetable oils were believed to be a protective factor to tinea capitis. Mustard oil, which is used in north and north east India for hair dressing was found to have an inhibitory effect on fungi in tinea capitis, but coconut oil had no such effect [18, 35, 76, 77]. Wetting agents in shampoos were thought to be detrimental to dermatophytes in a group with lower incidence of tinea capitis[84]. Frequent hair baths could probably be protective to tinea capitis in children [86].

Tinea capitis is a communicable fungal infection transmitted by intimate personal contact. Apart from close personal contact, transmission can occur through shared brushes, combs, bed linen as well [3,23]. The presence of fungal spores within the scalp is not sufficient for onset of infection on its own. Trauma in any form including that due to hair care habits may lead to penetration of fungi into the stratum corneum and onset of infection [1]. Reservoir of asymptomatic infection has been demonstrated and this has epidemiologic significance in the form of spread of infection to others and re infection to self [2,34].

The source of infection depends on whether the causative organism is geophilic, zoophilic or anthropophilic[1,4]. These factors play a part in determining the degree of clinical inflammation. Anthropophilic organisms maintain their virulence in human to human transmission, thereby making endemecity a prominent feature of these infections [24].

Tinea capitis can occur as intra familial infection. Large quantity of spores in the non-inflammatory type of tinea capitis was responsible for this intra familial infection [25, 72]. The incidence of tinea capitis is high in the siblings of infected children [81].

Racial factors also play an important role. *M.canis* was the dominant organism in some parts of Europe and *T.tonsurans* in urban communities in the USA [1,11]. A similar rise in the prevalence of *T.tonsurans* has recently been recorded in urban areas of the UK and some other European countries[26]. *Trichophyton violaceum, T.schoenleinii* and *T.soudanense* were set to be originally from Africa [1,83].

Racial variation was found in the induction of inflammation in dermatophytoses[84]. Molecular structure of Keratin varies from species to species and probably different keratinases have been evolved with specificity to a particular host and this factor may also be responsible for the racial preferences of some anthropophilic dermatophytes[84].A survey of tinea capitis conducted in 2 different schools with children belonging to the communities of gypsies and snake charmers showed a high incidence of the disease of 59.7% and 25% respectively[82]. A probable genetic predisposition to tinea capitis could not be ruled out in those communities[85].

STUDIES ON THE PREVALENCE OF TINEA CAPITIS IN INDIA

TABLE: 1

S.NO	Author and Year	Place of Study	Common Isolates
1	Gokhale and Padhye 1965	Poona	*T.violaceum* and *T.tonsurans*
2	Mahajan and Mahpatra 1968	Delhi	*T.violaceum* and *T.tonsurans*
3	Nagbushanam et al 1972	Hyderabad	*T.violaceum, T.rubrum* and *T.mentagrophytes*
4	Kamalam and Thambiah 1979	Madras	*T.violaceum*
5	Sehgal et al 1985	Delhi	*T.violaceum, T.rubrum, T.mentagrophytes* and *T.tonsurans*
6	Bharadwaj et al 1987	Kashmir	*T.violaceum* and *T.rubrum*
7	Reddy et al 1991	Pondicherry	*T.violaceum, T.tonsurans T.rubrum* and *T.mentagrophytes*
8	Kalla et al 1995	Jodhpur	*T.violaceum* and *T.mentagrophytes*
9	Seema Bose et al 2011	Maharastra	*T.mentagrophytes,M.gypseum* and *T.rubrum*

STUDIES ON PREVALENCE OF TINEA CAPITS OUTSIDE INDIA: TABLE: 2

S.NO	Author and Year	Place of Study	Common Isolates
1	Barbara J.Reid and Michael B.Shimkin 1968	Philadelphia	*M.audouinii* and *T.tonsurans*
2	H.I.Fathi and A.I.Samarai 2000	Iraq	*T.tonsurans, M.audouinii* and *M.canis*
3	Shahindokht Bassiri-jahromi et al 2000-2005	Iran	*T.tonsurans* and *T.violaceum*
4	Maha Aldayel and Iqbal Bukhari 2004	Saudi Arabia	*M.canis* and *T.violaceum*
5	Ijaz Ahmed and Zaffar Ahmed 2006	Pakistan	*T.violaceum* and *M.canis*
6	Mohammed El-Benhave et al 2007	Qatar	*M.canis, M.ferrugineum* and *T.violaceum*
7	Ameneh Yazdanfar 2009	Iran	*T.verrucosum*
8	Williams JV, Honig PJ	Philadelphia	*T.tonsurans* and *M.canis*

AGENTS CAUSING TINEA CAPITIS ANDTHEIR GEOGRAPHIC DISTRIBUTION:

Tinea Capitis is caused by variety of dermatophytes belonging to the genera *Trichophyton* and *Microsporum*. Though *Epidermophyton* is not traditionally considered as a causative agent for tinea capitis, it has been isolated lately in few cases. *Trichophyton concentricum* and *E.floccosum* never invades a hair shaft [1,11]. The etiological agent varies widely in different geographical regions [27,75] as following given in table 3[4].

TABLE: 3

Species	Type	Distribution
I) Ectothrix		
M.audouinii	Anthropophilic	Sporadic
M.canis	Zoophilic	Worldwide
M.fulvum	Geophilic	Worldwide
M.gypseum	Geophilic	Worldwide
M.ferrugineum	Anthropophilic	Africa and Asia
T.mentagrophytes	Anthropophilic/ Zoophilic	Worldwide
T.rubrum	Anthropophilic	Worldwide
T.verrucosum	Zoophilic	Worldwide
T.megninii	Anthropophilic	Europe
II) Endothrix		
T.tonsurans	Anthropophilic	United States, Europe, Central America and Australia
T.violaceum	Anthropophilic	Africa, Europe and Asia
T.soudanense	Anthropophilic	Central and West Africa
T.gourvilli	Anthropophilic	Central and West Africa
T.yaoundei	Anthropophilic	Central and West Africa
T.schoenleinii	Anthropophilic	Africa, Eastern Europe and United States

Dermatophytes are usually classified by the morphology of the large multicellular macroconidia. In the genus *Microsporum*, the macro conidia are rough, usually thick walled and range from fusiform to obovate in shape with 1-12 or more septa. Those of *Trichophyton* species are thin walled, smooth and may be cylindrical, fusiform or clavate in shape, with up to 12 transverse septa. In *Epidermophyton*, the macroconidium is clavate, broadened and rounded at its distal pole, thin walled and has up to five septa, the conidia are smooth when first formed, but as the colony becomes old, discrete wall thickenings may be observed[1].

Classifying superficial fungi by their habitat is useful for understanding their various clinical presentations and patterns of transmissions[82]. Geophilic organisms grow in the soil and only sporadically infect humans, when they do, the result is usually inflammatory[1,3].

Zoophilic species are found on animals, but are also transmitted to humans sporadically. Domestic animals and pets are becoming an increasing source of these infections in urban areas. Transmission may occur through direct contact or indirectly by infected animal hair carried on clothing [3]. Exposed areas such as scalp, beard, face and arms are favoured sites of infection. Although human infection with zoophilic

organism is suppurative often, animal infection may be clinically silent, demonstrating the unique adaption of fungi to their animal hosts [1,30].

Anthropophilic species have adapted to human as hosts. Unlike the sporadic geophilic and zoophilic infections, anthropophilic infections are often epidemic in nature. They are transmitted from person to person via direct contact or fomites. Markedly inflammatory reactions can occur because of variability in virulence as well as host susceptibility. Kerion formation, suppuration or other manifestations of inflammatory tinea capitis facilitate early diagnosis. Non-inflammatory infection, in contrast, results in a clinically silent carrier state that serves to delay diagnosis and propagate the infection[1,3,4].

Host variability also affects the clinical presentation. Immuno compromised individuals are more susceptible to severe or refractory dermatophytosis and an increase in infections by previously non-pathogenic dermatophytes [31]. The severity of dermatophytosis is increased with HIV disease and not the prevalence. Age, sex and race are the additional important epidemiologic factors[4,80].

PATHOGENISIS

H.G.Adamson, a London dermatologist showed in detail that the dermatophyte is confined to the keratinized portion of the hair and that

the direction of the growth is downwards towards the bulb. The downward growing hyphae do not penetrate the bulb, but terminate above it in a fringe of hyphal endings known as ‘Adamson’s fringe’. Later in 1952-56, Albert M.Klingman studied the pathogenesis of Tinea capitis and found that susceptibility to infection coincided with the second half of the growth period during mid to late anagen phase [3, 36]. Trauma assists inoculation, which is followed, after approximately 3 weeks, by clinical evidence of hair shaft infection, spread to other follicles proceeds, then for a period of variable duration the infection persists but does not spread further. Later there is a period of regression with or without an inflammatory phase. In dermatophyte infections involving the hair, the fungus invades the follicle from the adjacent stratum corneum and follows one of the several precise patterns of growth [1].

In case of ectothrix infection, the fungus penetrates the keratinized hair at about mid-follicular level having grown down on the skin surface. It then grows downwards within the hair towards the bulb, until the zone of incomplete keratinization is reached. Growth is then arrested or rather slowed and resisted, and equilibrium is established, the fungal mycelium invading new, fully keratinized hair shaft at the same rate as it is formed, but never growing down into the incompletely keratinized tissue. Further up the shaft, hyphae from the existing mycelium grow outwards from inside the hair and proliferate on its surface. These secondary extrapilary

hyphae are tortuous, they fragment into small arthroconidia, which rapidly round up to become spherical structures and are seen as a packed mosaic of spores coating the surface of the hair. The hair shaft fractures a few millimeters above the surface [1,3].

Small spored ectothrix infection produces small arthroconidia of 2-3µm in diameter, each one is rounded off and spherical. It is caused by *Microsporum canis, M.audouinii, M.ferrugineum* and *M.equinum*[1,3].

Large spored ectothrix infection produces larger arthroconidia of 5-8µm in diameter, spherical and are arranged in straight chains. It is caused by *Microsporum gypseum, M.fulvum, M.nanum, Trichophyton verrucosum, T.mentagrophytes var mentagrophytes, T.mentagrophytes var erinacei, T.megninii* and *T.rubrum* (rarely) [1,3].

In case of the endothrix infection, the intrapilary hyphae inside the hair fragments completely into a mass of relatively large arthroconidia, which are retained entirely within the hair shaft. The hair is fragile and with trauma breaks at its weakest point, the surface of the scalp where it loses the supporting follicular wall. Endothrix type of infection is caused by *Trichophyton tonsurans, T.violaceum, T.soudanense, T.yaoundei, T.gourvilii* and *T.rubrum* (rarely) [2,3,47].

In case of favus type of infection caused by *Trichophyton schoenleinii*, the hyphae within the hair are fewer in number than in other endothrix infections and do not break up into mass of arthroconidia but run intact through the hair, forming tunnels around the hyphae initially filled with air, form the characteristic airspaces seen. In favus, the infected hair commonly grows to normal lengths[1,2].All these parasitic patterns are very different from the mode of growth of dermatophytes on hair in vitro. If plucked hair is inoculated with any of the *T.mentagrophytes* varieties, for example, frond like fungal hyphae develop on the surface and lift the cuticle cells. Conical pits are then formed perpendicular to the surface of the hair as penetration of the keratinized hair cortex occurs. Intrapilary growth follows along the hair shaft in both directions, and micro and macro conidia may be produced. There are no linear chains of arthroconidia on the surface[1].

If a hair parasitized in vivo, is plucked and then cultured in vitro, the specialized growth pattern initially established will cease and the saprophyte phase, with development of micro and macro conidia, will follow rapidly[2].

CLINICAL FEATURES:

The clinical appearance of ringworm of the scalp is most variable, depending on the type of hair invasion, the level of host resistance and the

degree of inflammatory host response[37]. The appearance may vary from little dull grey, broken off hairs with a little scaling, to a severe painful inflammatory mass covering most of the scalp. Itching mayor may not be present. The cardinal features are partial hair loss with inflammation of variable intensity [1].

Non inflammatory types of tinea capitis are the grey patch, black dot, seborrhoeic type, smooth patch of baldness and the adult type (glabrous type). Inflammatory types of tinea capitis are kerion, abscess, favus, agminate folliculitis and pustular types [6]. Mixed type may be a combination of both the non inflammatory and inflammatory types[4,5,6]. Non inflammatory tinea capitis is more common than inflammatory or kerion type. Of the non inflammatory types, grey patch is the most frequent clinical variety[2,38].

Grey patch or non inflammatory, human or epidemic type:

This pattern is seen most commonly with the anthropophilic ectothrix organisms *M.audouinii, M.ferrugineum, M.canis, T.tonsurans,* and *T.violaceum*. The lesion begins as a small erythematous papule surrounding a single hair shaft and spreads centrifugally, encompassing nearby hairs. Scaling is usually present, but inflammation is minimal. Hairs in the affected area turn grey and lusterless secondary to their sheath of arthroconidia and break off just above the level of the scalp.

These lesions frequently appear as one or more well demarcated patches on the occiput or posterior neck[2,4].

Black dot type:

It is caused by the endothrix organisms *T.tonsurans*, *T.violaceum*, *T.yaoundei* and *T.simii*. In this type, hair loss may or may not occur. When it does, hairs broken at the level of the scalp leave behind grouped black dots. Diffuse scaling is again usually present, but inflammation varies from minimal to severe. Affected areas are usually multiple or polygonal with poorly demarcated, finger like margins. Normal hairs commonly remain within patches of alopecia[4].

Seborrhoeic type:

It is mainly caused by *T.tonsurans* and it is characterized by more scaling with less loss of hair[1,5].

Smooth patch of baldness:

This type resembles alopecia areata with mild scaling[1,4].

Glabrous type:

It is the commonest type seen in adults. Here the lesion may extend from the face, occiput, and nape of neck or from cheek to the frontal and

temporal areas. This type is mainly caused by *T.rubrum* and *T.mentagrophytes*[1,6].

Inflammatory types of tinea capitis are usually seen with zoophilic and geophilic pathogens. The spectrum of inflammation ranges from pustular folliculitis to kerion. Organisms causing the inflammatory types are *Microsporum audouinii, M.canis, M.gypseum, M.nanum, Trichophyton mentagrophytes, T.tonsurans, T.schoenleinii* and *T.verrucosum*[1,4].

Kerion type:

It is a boggy mass studded with broken hairs and follicular orifices oozing with pus. It may rarely result in scarring alopecia. There may be sinus formation, thick crusting with matting of adjacent hairs [4]. Lymphadenopathy is frequently associated. It is often associated with secondary bacterial infections. Auto eczematization or id eruption occurs frequently and generally after initiating treatment for kerion, which is manifested by fine lichenoid papules from scalp to the trunk[3]. Rarely erythema nodosum has been reported with kerion[39].

Abscess type:

It is characterized by smooth erythematous boggy swelling without follicular pustules [1].

Agminate folliculitis type:

It is a less severe inflammatory type consisting of sharply defined, dull red plaques studded with follicular pustules. This is usually caused by zoophilic organisms. Pustule formation represents an inflammatory response to the fungus[1,4,40].

Favus Type:

It is an inflammatory type of tinea capitis that begins early in life and commonly extends into adulthood [1,41]. It is seen sporadically in a variety of countries such as South Africa, Ethiopia, Middle East, Pakistan, USA, UK and Australia [2,42]. In India, it is reported to be endemic in Kashmir [43]. It is characterized by the presence of yellowish cup shaped crusts known as scutula. Each scutulum develops round a hair, which pierces it centrally. Adjacent crusts enlarge to become confluent and form a mass of yellow crusting. Extensive patchy hair loss with cicatricial alopecia and atrophy among patches of normal hair may be found in long standing cases and much of the hair loss is irreversible[1,44] .In such cases, the glabrous skin is commonly affected by the development of similar yellowish crusts. Families with several generations affected are well recognized[4,45]. Unusal cases of tinea capitis could present with clinical resemblance to cutaneous lupus erythematoses

or lichen planus which could be easily solved by routine mycological investigations [87].

Ravaghi in 1976 described superficial and deep granulomatous lesions presenting as erythematous scaly plaques in arm, chest and abdomen with ulceration, fistula and destruction of sterna bone [88]. Another study reported a griseofulvin resistant encapsulated T.violaceum abscesses in the skin involving dermis and subcutis in a 11 year old male in association with a defective cell mediated immunity, malnutrition and hypoadrenalism [69].

DIFFERENTIAL DIAGNOSIS:

The differential diagnosis of tinea capitis includes all conditions that cause patchy baldness and inflammatory changes of the scalp. The differential diagnosis of minimally inflammatory, scaly tinea capitis includes seborrhoeic dermatitis, atopic dermatitis and psoriasis. Pronounced alopecia may resemble conditions like alopecia areata, trichotillomania, secondary syphilis and pseudopelade. Inflammatory tinea capitis must be differentiated from the bacterial pyodermas, folliculitis decalvans, perifolliculitis capitis abscedens et suffodiens. The differential diagnosis of scarring alopecia includes discoid lupus erythematosus, lichen planopilaris, pseudopelade and radiation dermatitis[4].

Atopic dermatitis is rarely associated with localized scalp ivolvement and clinical examination reveals more typical generalized findings.Alopecia areata may show erythema and it is not a scaly condition, and it may co-exist with seborrhoeic dermatitis. Exclamation mark hairs must be distinguished from broken hairs of tinea capitis. Traumatic alopecia from hair dressing procedures and trichotillomania with varying lengths may also be confused. Seborrhoeic dermatitis is usually more diffuse than tinea capitis, but in tinea amiantacea the changes are often localized. In psoriasis, hair loss is found only occasionally, and again broken off hairs are not usually present[1,2].

In impetigo, which may be secondary to pediculosis of the scalp, loosening of the hair is not normally present, but matting and crusting may cause confusion with inflammatory ringworm. A carbuncle of the scalp is much more acutely painful, and shedding of loosened hairs much less evident than in kerion [1,2].

LABORATORY DIAGNOSIS:

The laboratory diagnosis mainly relies on the direct microscopical observation of the pathogen in samples, followed by culture and species identification of the fungus[2].

Collection of material:

Disposable scalpel blades of the solid type held vertically to the skin are used to obtain scrapings. The hairs should be removed with the roots intact, cut hairs are unsuitable. The affected hairs may be recognized as dull and broken hairs. Where the hairs break off very short as in black dot infections, a scalp scraping may yield best result[1,3].

Woods light examination:

The hair infected by certain dermatophytes produced a characteristic fluorescence in UV light filtered by wood's glass. The hair remains fluorescent after the fungus has ceased to be viable. The chemical nature of the fluorescent material is due to pteridine [3,49] .Hairs infected by *M.canis* and *M.audouinii* produce a brilliant green fluorescence. *M.gypseum* and *M.nanum* occasionally do so. *T.schoenleinii* causes a paler green fluorescence of infected hair [1,4] .In areas where *Microsporum* infections are prevalent; the wood's light is an essential tool in the diagnosis and treatment. It can be taken to schools or institutions for the rapid examination of contacts. The utility of wood's light has been reduced since *T.tonsurans* infection is wood's light negative [47,48,57].

Direct examination:

For routine examination, scales and hair are mixed with 10% and 40% potassium hydroxide (KOH) solution respectively and examined microscopically for the evidence of fungal hyphae and spores. Several stains like methylene blue, cotton blue, Congo red, periodic acid-schiff, parker's stain can be used to enhance the contrast of the fungal hyphae stained[1,3].

Histopathology:

In histopathology of tinea capitis with methenamine silver and PAS stains hyphae around and within hair shaft are seen. The dermis demonstrates a perifollicular infiltrate of mixed lymphocytes, histiocytes, plasma cells and eosinophils. Follicular disruption leads to an adjacent foreign body giant cell reaction [1,4,21].

Markedly inflammed lesions such as kerion demonstrate a more intense infiltrate of polymorphonuclear leucocyte abscess within the dermis and follicle [4,50]. Organisms are difficult to visualize but fungal antigens are detectable with immunofluorescent techniques[3].

Culture:

Sabouraud's dextrose agar containing dextrose 40gm, agar 20gm, and peptone 10gm distilled water adjusted to pH 5.5 to 1000ml is the

most commonly used isolation medium. High concentration of sugar and a low pH (4.5-5.5) prevents growth of most bacteria and makes it selective for fungi. Emmon's modification of SDA contains 2% dextrose and has pH of 6.8[1,3]. Commercial variations of this agar are Mycosel and Mycobiotic. Dermatophyte test medium (DTM) contains the pH indicator phenol red; it remains yellow with the growth of most saprophytes, but turns red when dermatophyte proteolytic activity increases the pH to 8 or above. Species of trichophyton are differentiated by their nutritional requirements like thiamine, inositol, nicotinic acid etc[1,4]. Cultures are incubated at room temperature 26ºC to 30ºC for up to 4 weeks before being discarded as no growth. Both macroscopic and microscopic features of a fungal colony are used for identification[4].

Characteristics of Various Dermatophyte Species: [51,52]

The characteristics of various dermatophyte species like growth rate in culture, appearance of macro and micro conidia, hair perforation and urease tests and growth factor requirements are given in table 4.

TABLE: 4

	Genus & Species	Growth rate	Conidia		Hair Perforation	Urease (7 days)	Growth Factor Requirements
			Macro	Micro			
1.	*Trichophyton violaceum*	Very slow	Absent	Absent	Negative	Negative	Thiamine
2.	*T.mentagrophytes*	Moderately rapid	Club shaped, absent (or) ± numerous	Pyriform, round, numerous (or) rare	Positive	Positive	None
3.	*T.rubrum*	Slow to Moderately rapid	Cylindrical, absent (or) ±numerous	Club shaped, Pyriform, ± numerous	Negative	Negative	None
4.	*T.tonsurans*	Slow		Club shaped, balloon, Numerous	Negative	Positive	Thiamine
5.	*T.verrucosum*	Very slow		Club shaped, absent (or) rare	Negative	Negative	Thiamine ± inositol
6.	*T.yaoundei*	Very slow	Absent	Absent	Negative		None
7.	*T.concenticum*	Very Slow	Absent	Absent	Negative		None
8.	*T.schoenleinii*	Very slow	Absent	Absent	Negative		None
9.	*T.Soudanense*	Slow	Absent	Pyriform, ovoid rare (or) absent	Negative	Negative	None
10.	*T.equinum*	Moderately rapid	Club shaped, absent (or) rare	Pyriform, Numerous	Negative (Pos)	Positive	Nicotinic acid
11	*Microsporum audouinii*	Moderately rapid	Fusoid, deformed, very rare	Absent or numerous	Negative	Negative	Negative
12	*M.canis*	Rapid	Fusoid, apex recurved, numerous	Moderate numerous	Positive	Variable	
13	*M.ferrugineum*	Slow	Absent	Absent	Negative		
14	*M.gypseum*	Rapid	Fusoid, Symmetrical, numerous	Moderate numerous	Positive	Variable	
15	*E.floccosum*	Slow		Absent	Negative		None

***TRICHOPHYTON TONSURANS*:**

First discovered by Malmsten 1845 [53].

Synonyms: *Tricophyton acuminatum*- E.Bodin 1902

T.areolatum- Negroni 1929

T.cerebraforme- Sabour 1910

T.crateriforme- Sabour 1992

T.flavum- E.Bodin 1902

Ecology:

T.tonsurans is a cosmopolitan and anthropophilic dermatophyte commonly isolated in certain regions such as in Mexico, in other countries of Latin America and in large cities in the United States. *T.tonsurans* has recently been recorded in urban areas of the U.K and in some other countries [1,26,78].

Pathogenecity:

T.tonsurans is a causative agent of infections of the scalp and of the glabrous skin or nails. Infection of the animals is rare [20].

Macroscopic appearance of the colony:

The colony surface is velvety or powdery and may be grey, cream or yellow in colour, more rarely brown in the center. Some isolates produce very sparse surface mycelium, so that the reverse brown pigmentation shows through circular or radial holes are often present. The reverse is typically chocolate brown, mahogany or yellow[1].

Microscopy:

The most characteristic feature is the micro conidia that are variable in shape and larger than *T.mentagrophytes* or *T.rubrum*. They range from clavate to elongate, and swollen balloon micro conidia and stalked match stick micro conidia are also observed. In large number of isolates, chlamydoconidia are numerous and in some isolates spiral hyphae and macro conidia are present. Physiological test shows that it has a specific requirement for thiamine[1,4].

***TRICHOPHYTON MENTAGROPHYTES*:**

By (Robin) Blanchard in 1896[53]

Synonyms: *Trichophyton asteroides* - Sabour 1910

T.gypseum var asteroids - Sabour Fragner 1956

T.denticulatum - Castell and Chalm 1919

T.granulosum -Sabour 1909

Ecology:

Trichophyton mentagrophytes is a cosmopolitan dermatophyte, that requires keratin for growth and cause superficial infections of skin, hair and nails, which may be either anthrophilic or zoophilic in nature. The principle reservoirs of the zoophilic species are certain animal like rodents, hedgehogs and rabbits [1,3].

Pathogenecity:

T.mentagrophytes var interdigitale, the anthropophilic isolates are the frequent causative agents of chronic infection of the feet, nails and groins which does not involve the scalp. When infected with zoophilic species like *T.mentagrophytes var mentagrophytes* they produce inflammatory lesions of the scalp, glabrous skin, nail and beard region. There are 4 species identified[1,4].

***T.mentagrophytes var mentagrophytes*:**

Macroscopy of colony:

The colonies are fast growing with an intensely granular surface, which may be entirely white or develop a cream centre. The edge of the colony is thinner and may be spiky or stellate. The reverse is yellow, tan or red to brown.

Microscopy:

The spherical micro conidia are arranged in grape like bunches and to a lesser extent along the hyphae. Coiled spiral hyphae are usually present and in many isolates thin walled cylindrical macroconidia with up to eight cells may be present. The fungus is urease positive and penetrates human hair in vitro [1].

***T.mentagrophytes var erinacei*:**

Macroscopy:

The rapidly growing colonies have a flat white intensely granular surface. The reverse is bright canary yellow.

Microscopy:

Elongate micro conidia, even longer than those of *T.rubrum*, are arranged along the sides of the hyphae. Spiral hyphae and smooth thin walled macroconidia may be present in some isolates. Unlike other variants of *T.mentagrophytes*, this type is urease negative and penetrates the human hair in vitro.

***T.mentagrophytes var quinckeanum*:**

Macroscopy:

The surface is white, velvety or downy and often folded in the centre. The reverse is buff to cream. The colony has been reported to have a distinctive sour smell.

Microscopy:

Pyriform micro conidia are arranged along the sides of the hyphae. It produces wood's light positive hair infection in mice with characteristic scutula in mice.

***T.mentagrophytes var interdigitale*:**

It does not cause tinea capitis.

Macroscopy:

The most typical isolates are rapidly growing and develop a pinkish surface. The reverse is tan or reddish brown, often with a paler edge. Microscopy:

Powdery isolates shows spherical micro conidia arranged in bunches, spiral hyphae and macro conidia. This variant is urease positive and penetrates human hair in vitro.

***TRICHOPHYTON VIOLACEUM*:**

By Bodin in1902[53].

Synonyms: *Bodinia glabra* - M.Ota and Langeron 1923

Trichophyton glabrum- (Sabour) 1910

Bodinia violacea - (Sabour) M.Ota and Langeron 1923

Trichophyton pterygoides var violaceum - (Sabour), 1931

Ecology:

It is an anthropophilic dermatophyte isolated commonly from North Africa and Middle East and also from certain parts of Europe. Some prevalent foci exist in South America and common in 5 to 15 years age[1]. It was endemic in South India and frequently occurred as intrafamilial infection[10,11].

Pathogenecity:

It is isolated mainly from tinea capitis, although it is capable of infecting glabrous skin, nails and soles of feet. Animal infection is rare[4].

Macroscopy of colony:

The colonies are slow growing, glabrous and have a waxy or leathery texture. They are usually deep red in colour, but rarely some cultures may take several weeks to pigment or may remain unpigmented.

Microscopy:

Microconidia and macroconidia are usually absent. Chlamydoconidia and distorted hyphae may be present. The growth of this species is stimulated by thiamine [1].

***TRICHOPHYTON RUBRUM*:**

By Castellani Sabouraud 1911 [53]

Synonyms: *T.circonvolutum* -Sabour 1911

T.marginatum -Mujis 1921

T.rubidum - Priestley 1917

Sabouraudites ruber - Castellani M.Ota and Langeron 1923

Ecology:

It is the most widespread species among the anthropophilic dermatophytes. It is characterized by chronic infection due to constant presence of the infected scales in human surroundings, which may lead to endemicity and pandemicity [1,3,22]. Intra familial infection of tinea capitis was found to be 6%[4,16].

Pathogenecity:

It is the most widespread agent and the common causative organism of fungal infection of the feet, hands, nails, groin and glabrous skin. The scalp is rarely infected. Animals are very infrequently infected. Several distinct colonial forms have been isolated.

Downy form:

It is the most commonly isolated form in temperate zones.

Macroscopy:

The surface of the colony is white, downy, cottony or domed. The reverse of the colony is dark brown with a pale cream border and it produces a deep red pigment after incubation for more than 3 weeks [1].

Microscopy:

Small, tear shaped, clavate or elongate microconidia are arranged along the sides of the hyphae. Rarely microconidia may be scanty. This variant is urease negative and does not perforate the human hair in vitro.

Melanoid form:

Macroscopy:

It produces a brownish melanoid pigment that diffuses into the medium that may mask the red pigment on the reverse of the colony.

Microscopy:

Small tear shaped micro conidia arranged along the sides of the hyphae.

Dysgonic form:

Macroscopy:

Slow growing tiny deep red colonies with a brittle texture. This form is relatively unstable and will quickly revert to the typical downy form.

Granular form:

Macroscopy:

The surface is powdery or granular, cream to pink and often raised and folded in centre. The reverse is red brown.

Microscopy:

Numerous smooth thin walled cylindrical or pencil shaped macro conidia are produced, some macro conidia may have constricted septa. Tear shaped micro conidia are also seen. This variant is urease positive and may penetrate human hair in vitro.

Yellow form:

Macroscopy:

The surface is smooth, leathery and yellow and the reverse is yellow.

Microscopy:

Tear shaped microconidia are seen[1].

***TRICHOPHYTON VERRUCOSUM*:**

By Bodin in 1902 [53]

Synonyms: *Ectotrichophyton verrucosum* - Castell and chalm 1919

T. faviforme var album- Sabour, Georg

T.discoides- Sabour 1908

T.octraceum- Sabour 1910

Ecology:

Trichophyton verrucosum is a cosmopolitan zoophilic dermatophyte commonly isolated from cattle and horses[4].

Pathogenecity:

Trichophyton verrucosum is a common causative agent of dermatophytosis infection of cattle and other farm animals. Humans, when contracted of *Trichophyton verrucosum* from an infected animal, may experience a strong inflammatory infection which may typically occur in the scalp, the beard region, or the glabrous skin [1,2].

Macroscopy:

This is a very slow growing fungus, and after incubation at 26ºC, the White or grey waxy colonies may still be barely visible. Growth is better at 37ºC. Therefore incubation at both temperatures is recommended [1].

Microscopy:

Colonies incubated at 26ºC show short hyphae with terminal chlamydoconidia. Clavate micro conidia are seen along the sides of the hyphae. Rat tailed macroconidia may be seen. At a higher temperature of 37ºC long chains of chlamydoconidia are seen.

TREATMENT:

The ideal drug used in the treatment of tinea capitis should have high efficacy with low relapse rate. It should be cost effective and highly safe.

The various drugs used are given in the table 5 [54]

TABLE : 5

Route of administration	Medication	Dose and Regimen	Comments
Topical	Ketoconazole shampoo or Selenium sulphide shampoo	Twice weekly	Adjunct therapy only. It reduces the fungal shedding.
Oral	Griseofulvin	10mg/kg/day for 12 weeks [1,2] 15-25mg/kg/day (microsize) [3] 10-15mg/kg/day (ultra microsize) for 6 to 8 weeks[3].	Continue for 2 weeks beyond clinical cure.
Oral	Ketoconazole	200mg/day for 12 weeks 3 to 6 mg/kg/day for 12 weeks[1] Usually not recommended in chidren[3,4]	
Oral	Itraconazole	100mg/day or 3 to5mg/kg/day for 4 to 6 weeks[1,3,4]	Avoid oral solution in children.
Oral	Terbinafine	62.5mg /day if wt<20kg 125mg/day if wt 20-40kg 250/day if wt>40kg Duration for 4 weeks[1,2,3]	
Oral	Fluconazole	50mg/day for 12 weeks or 5-6mg/kg/day for 6 weeks[2,3,4]	Oral solution

GRISEOFULVIN:

The usual dose of Griseofulvin is 1gm/day of the microcrystalline form or 0.5gm/day of ultramicronised form. The pediatric dosage is 10 to 20mg/kg/day of the ultra microsize form taken with a fatty meal for increasing the absorption [1,55] .Treatment is usually continued until clinical and mycological cure is documented, which is around 12 weeks. The dose may be increased to 20 to 25mg/kg/day for refractory infections [32].

Griseofulvin has poor compliance because of the length of treatment, photosensitivity and the gastrointestinal side effects. It also potently induces the cytochrome P450 enzymes [1,4,67].

FLUCONAZOLE:

The usual dose is 3-6mg/kg/day. The absorption of fluconazole is not affected by meals, and the gastrointestinal side effects are also uncommon [3,64]. Hepatitis has been reported rarely [4,56] .It is available as both tablets and as pleasant tasting liquid formulations. Liquid formulations are not available in many countries[1].

ITRACONAZOLE:

The usual dose is 3 to 5mg/kg/day for about 6 weeks. It effectively eradicates tinea capitis caused by either *Microsporum* or *Trichophyton*

species[1,91]. It may cause gastrointestinal upset, diarrhea with liquid preparations, and peripheral edema, when used along with calcium channel blockers. Hepato -toxicity is very rare. Routine monitoring of the hematological and hepatic functions are necessary if the treatment is continued beyond 4 weeks [11,66].

TERBINAFINE:

The usual dose is 62.5mg /day if wt<20kg, 125mg/day if wt 20-40kg and 250mg/day if wt>40kg. *Trichophyton* infections respond better to terbinafine, while *M.audouinii* infections respond better only to griseofulvin than terbinafine[1,2,3,92].

Terbinafine causes gastrointestinal side effects, ageusia and rarely hepatotoxicity. It causes tricyclic antidepressant toxicity due to inhibition of CYP2D6. But it causes fewer cytochrome P450 effects. Hepatic and hematological monitoring is needed only when the duration of treatment exceeds 6 weeks[65].

PULSE THERAPY:

Itraconazole pulse therapy for tinea capitis has been reported by Gupta et al. It is given as a dose of 5mg/kg/day for 7 days [3,33] . The

second and third pulse is given, if required on clinical grounds each at an interval of 2 to 3 weeks[2,3,93].

ADJUVANT THERAPY:

Oral antibiotics are used where secondary infection is suspected or established. Oral corticosteroids are used in markedly inflamed tinea capitis to reduce the incidence of scarring at a dose of 1mg/kg of prednisolone for a short period. Ketoconazole 2% shampoo or selenium sulphide 2.5% shampoo is used by all household members three times weekly to decrease the shedding of spores [2,3,94]. Removal of the matted crusts is done followed by shampooing. Examination of close contacts of the patients and pets for evidence of disease is a must. Children may attend school during treatment but they are counseled not to share caps, combs, toys etc. Concomitant nail infection may require 6 to 12 months of therapy [1,4,63].

CLINICO MYCOLOGICAL STUDY OF TINEA CAPITIS

AIMS OF THE STUDY

- To study the epidemiological aspects like age, sex and socioeconomic factors related to tinea capitis.
- To study the various clinical types of tinea capitis
- To study the various etiological agents causing tinea capitis
- To determine the clinico-etiological correlation of tinea capitis and to see if there is any change in trend.

MATERIALS & METHODS

All new patients with tinea capitis who attended the outpatient department, mycology section, Department of Dermatology, Rajiv Gandhi Government General hospital from the period of June 1st 2010 to October 2011 were selected for the study after KOH smear positivity.

Age, sex and duration of the disease were recorded. Detailed history with regard to socio economic status, tonsure/haircut, contact with pet animals, similar lesions in siblings or friends and associated systemic illness was taken.

Dermatological examination was done to look for the presence of scales, patchy hair loss or boggy swelling in various areas of scalp. Associated dermatophyte infection elsewhere in the skin and nails were noted. Presence of regional cervical lymphadenopathy was recorded. Examination for other associated dermatological and systemic disorders was done.

Scalp scrapings and hair root samples were analyzed by KOH wet mount. KOH positive specimens were cultured on Sabourauds dextrose agar with and without actidione. The rate of growth, colony morphology, pigment production on the reverse and microscopic examination in lactophenol cotton blue mount contributed towards confirmation of the isolates.

Inclusion criteria

All patients with tinea capitis, belonging to any age group and both sexes with KOH smear positivity.

Exclusion criteria

Patients who had taken topical antifungal treatment 2 weeks prior and systemic antifungal treatment 4 weeks prior to the study.

OBSERVATIONS

Age and sex distribution:

The youngest patient in the study was a 5 months old male baby, and the oldest patient was a 63 years old male. The most commonly affected age group was the 0 to 5 years with 41 children (41.8%) followed by the 6 to 10 years age group with 29 children (29.6%). Infection was less common in the age group above 16 years. The mean age in the study is 9.4 years.

The age and sex distribution is given in table 6 and figure 1.

TABLE: 6

Age	Males (n=68)	Females (n=30)	Total (n=98)	Percentage
0 to 5 yrs	27	14	41	41.8%
6 to 10 yrs	18	11	29	29.6%
11 to 15 yrs	13	4	17	17.3%
16 to 20 yrs	4	0	4	4.1%
21 yrs and above	6	1	7	7.2%

Figure:1

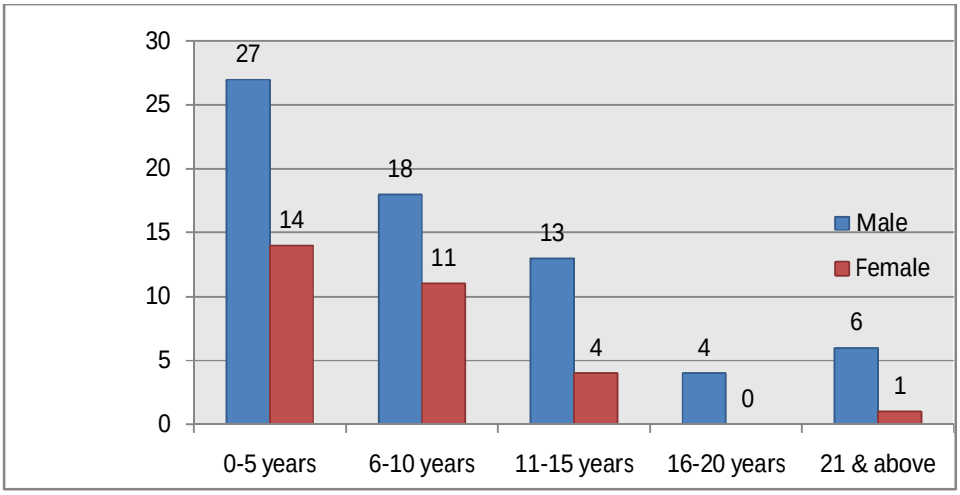

Sex distribution:

Out of the 98 patients enrolled into the study, 68 were males and 30 were females.

The male: female ratio is 2.3:1

The sex distribution is given in table 7 and figure 2.

TABLE: 7

Sex	Frequency (n)	Percentage (%)
Male	68	69%
Female	30	31%

Figure: 2

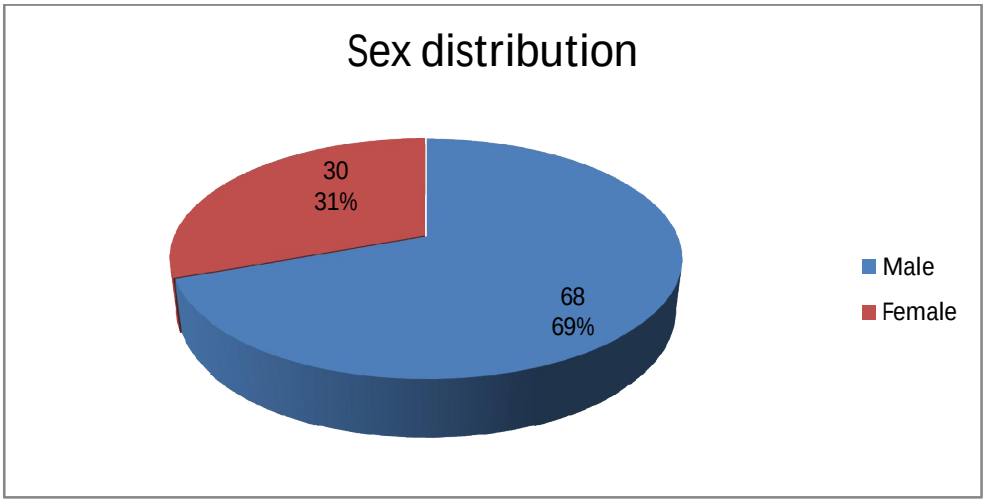

About 69 patients (70.4%) in the study group belonged to low socio-economic status with an average family income less than 2465 Rupees/month.

Personal and Social Factors :

The association between various personal and social factors and tinea capitis are shown in the table 8.

TABLE: 8

Personal and Social factors	Number of patients (n=98)
History of tonsure/haircut	46 (46.9%)
History of contact with pet animals	1 (1.1%)
History of sharing combs and caps	56 (57.1%)
Family history of dermatophyte infection	15 (15.3%)

History of tonsuring/haircut was present in 46 (46.9%) of the patients. Duration between the tonsure and the onset of infection ranged from 2 to 8 weeks. Most of them gave a history of onset of scaling and hair loss over the scalp of a period between 4 weeks (24.5%) and 8 weeks (14.3%). Family history of dermatophyte infection was found in 15 cases (15.3%). Intrafamilial infection of tinea capitis was found in 2 families. Out of the two families, one was a gypsy family with 3 sons and 1 daughter affected by tinea capitis. There were history of sharing combs and caps seen in 56 patients (57.1%).

Systemic Associations :

The various systemic associations and their frequencies are given in table 9.

TABLE: 9

Condition	Children (n=6)	Adults (n=4)	Total (n=10)
Epilepsy	1	1	2
Rheumatoid arthritis	-	1	1
Down's syndrome	1	-	1
Subnormal mentation	2		2
Pulmonary Tuberculosis	-	1	1
Bullous pemphigoid	-	1	1
Myeloproliferative disorder	1	-	1
Empyema	1	-	1

Systemic associations were observed in 10 patients (10.2%) and they are epilepsy, rheumatoid arthritis, Down's syndrome, subnormal mentation, pulmonary Tuberculosis, bullous pemphigoid, myelo proliferative disorder and empyema. Among those patients with systemic associations 6 were children and 4 were adults.

Association with other clinical types: (Table 10)

TABLE: 10

Type of Dermatophytosis associated	Number of Children (n=9)	Number of Adults (n=12)	Total (n=21)	Total Percentage (%)
Tinea faciei	1	1	2	9.5%
Tinea corporis	4	4	8	38%
Tinea cruris	4	-	4	19%
Tinea corporis & tinea cruris	-	2	2	9.5%
Tinea corporis & tinea faciei	-	1	1	4.8%
Tinea corporis & tinea pedis	-	1	1	4.8%
Tinea corporis, tinea faciei & tinea cruris	-	1	1	4.8%
Tinea cruris, tinea glutealis & tinea incognito	-	1	1	4.8%
Tinea corporis, tinea cruris & tinea barbae	-	1	1	4.8%

Association with other clinical types of dermatophytosis was observed in 21 patients (21.4%). Tinea capitis alone was seen in 77 patients (78.6%).

Among the associated dermatophyte infections tinea corporis was the most common accounting for 38.8% followed by tinea cruris (19%) and tinea faciei (9.5%).There was association with extensive dermatophyte infection in rest of the cases (33.5%).

Various clinical types of tinea capitis :

The various clinical types of tinea capitis observed were given in table 11 and figure 3.

TABLE: 11

S.No.	Type of tinea capitis	Frequency (n)	Percentage (%)
1	Non-inflammatory type	65	66.3%
2	Inflammatory type	23	23.5%
3	Mixed type	10	10.2%

Figure: 3

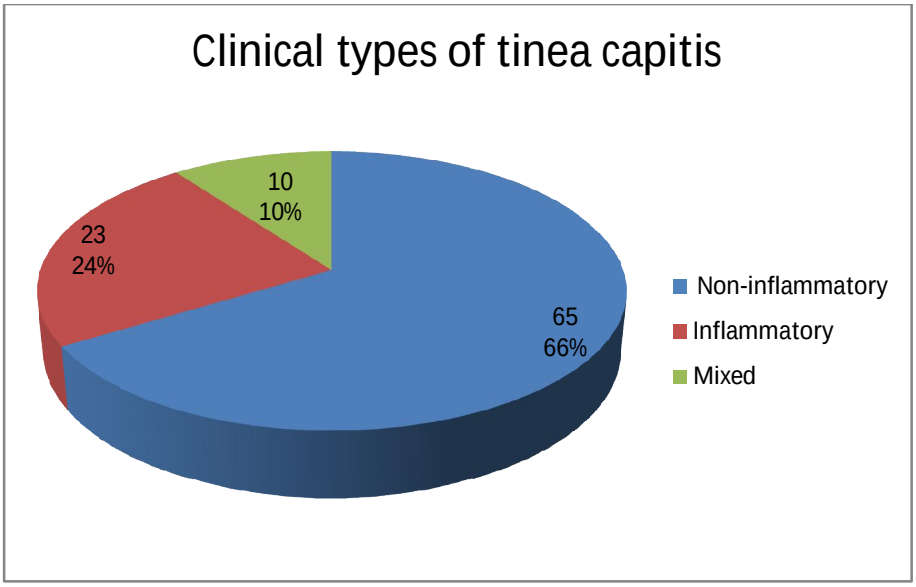

Non-inflammatory type was the most frequent clinical type noted in 65 patients (66.3%), followed by inflammatory type noted in 23 patients (23.5%) and mixed type in 10 patients (10.2%). Various clinical types observed are given in table 12. (Figure 9 to 18)

Among the total 98 cases , grey patch was the most common clinical pattern seen in 28.6% followed by kerion, smooth bald patch, glabrous, mixed, seborrhoeic, black dot, pustular and abscess types in 21.4%, 14.3%, 11.2%, 10.3%, 7.1%, 5.1%, 1% and 1% of patients respectively.

TABLE: 12

S.No.	Non-inflammatory types	Number of patients (n=65)	Percentage among non-inflammatory types (%)	Percentage among Total cases n = 98
1	Grey patch	28	43.1%	28.6 %
2	Smooth bald patch	14	21.5%	14.3 %
3	Glabrous type	11	17%	11.2 %
4	Black dot	7	10.7%	5.1 %
5	Seborrhoeic type	5	7.7%	7.1 %

S.No.	Inflammatory types	Number of patients (n=23)	Percentage among inflammatory types (%)	Percentage among Total cases n = 98
1	Kerion	21	91.4%	21.4 %
2	Pustular type	1	4.3%	1.0 %
3	Abscess type	1	4.3%	1.0 %

The various non-inflammatory types, inflammatory types and mixed types are shown in figure 5 and 6.

Figure: 5

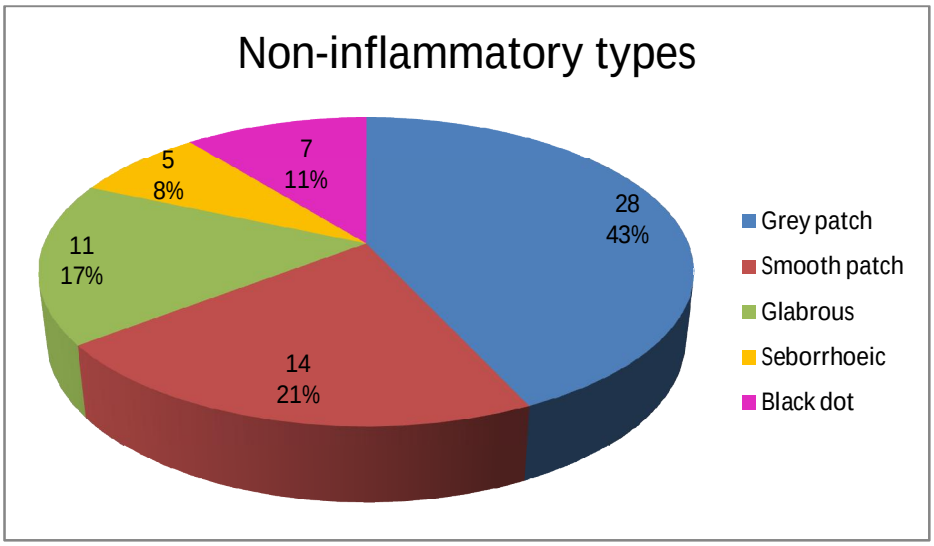

Figure: 6

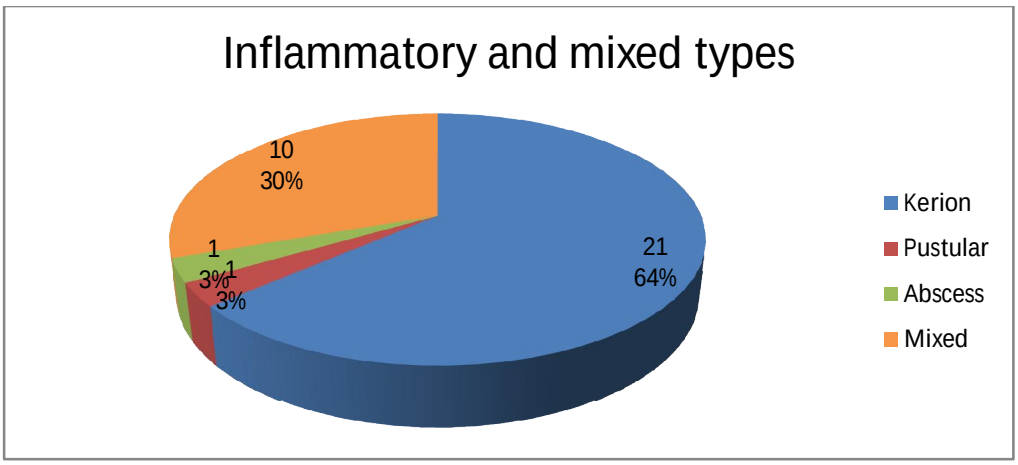

Of the non-inflammatory types, grey patch is the commonest type (43.1%) followed by smooth patch of baldness (21.5%), glabrous (17%), black dot (10.7%) and seborrhoeic type (7.7%) respectively. Among the inflammatory types, kerion is the commonest type (91.4%) followed by pustular (4.3%) and abscess types (4.3%).

Mixed type of tinea capitis was not seen in the age group more than 20 years. It was observed in 10 (10.3%) of patients. Coexistence of various non inflammatory and inflammatory types were found and among them grey patch with pustules was the commonest presentation. Various combinations seen in mixed type tinea capitis are tabulated in table 13.

TABLE: 13

S.No.	Mixed types	No. of patients (n=10)	Percentage (%)
	Non inflammatory and Non inflammatory		
1	Grey patch and black dot	2	20%
2	Grey patch and seborrhoeic	2	20%
	Non inflammatory and inflammatory		
1	Grey patch and pustules	3	30%
2	Grey patch and kerion	2	20%
	Inflammatory and inflammatory		
1	Kerion and abscess	1	10%

Non-inflammatory type was mainly observed in all the age groups when compared to the inflammatory type. Both the non inflammatory and inflammatory types were more common in age group less than 10 years. There was no statistically significant difference in the age distribution among the various clinical types. (p=0.05)

Age distribution in various clinical types :

Age distribution in various clinical types is given in table 14.

TABLE: 14

S. No.	Age group	Non-inflammatory (n=65)	Inflammatory (n=23)	Mixed (n=10)	Total (n=98)
1	0-5 years	26	12	3	41(41.8%)
2	6-10 years	21	6	2	29(29.6%)
3	11-15 years	7	5	5	17(17.3%)
4	16-20 years	4	0	0	4(4.1%)
5	Above 21 years	7	0	0	7(7.2%)

Tinea capitis lesions were seen mostly on the parietal region in 33 patients (33.7%) followed by temporal region in 27 patients (27.5%). There was associated cervical lymph node involvement in 14 patients (14.3%). One child with mixed type manifested with id reaction over the face, trunk and arms.

Laboratory investigations:

KOH mount:

Of the 98 specimens subjected to KOH mount, 46 (46.9%) showed endothrix spores and 11(11.3%) showed hyaline branched setate hyphae with spores and rest of the 41(41.8%) showed only spores.

Culture isolates:

Of the 98 specimens subjected to culture in Sabouraud's dextrose agar with actidione, positive isolates were obtained in 74 (75.5%). The various organisms isolated were *Trichophyton tonsurans*, *T. violaceum*, *T.mentagrophytes*, *T. rubrum* and *T.verrucosum*.

Trichophyton tonsurans (23.4%) showed the characteristic macroscopic morphology of creamy white colonies with concentric radial folding heaped up in the centre with reverse brown pigmentation (Fig: 19 &20). Microscopic morphology in lacto phenol cotton blue showed the intercalary and terminal chlamydoconidia and stalked match stick micro conidia (Fig: 21).

Trichophyton violaceum (19.4%) presented with waxy violet colony and reverse showing violet pigmentation with a slow growth (Fig: 22 & 23).Microscopic examination showed the characteristic chlamydoconidia and distorted bizarre hyphae (Fig: 24).

The macroscopic colony of *T.mentagrophytes* (19.4%) was rapidly growing with a white granular surface and reverse showing tan to brown colour. (Fig: 25 &26).Microscopic examination revealed thin walled cylindrical macro conidia and coiled spiral hyphae . (Fig: 27 &28).

The colony of *Trichophyton rubrum* (12.3%) showed a rapid growth with a white cottony surface and reverse showed deep red

pigmentation (Fig: 30 &31). Subcultures in corn meal agar produced diffusible red pigment characteristic of *T.rubrum*. Microscopic examinaton showed tear shaped and elongated micro conidia arranged along the sides of the hyphae in enthyce and engreppe distribution. (Fig: 32).

Trichophyton verrucosum (1%) showed very slow growth with small white waxy colonies (Fig: 33 &34). Microscopic examination showed long chains of chlamydoconidia (Fig: 35).

Distribution of various culture positive isolates (n=74) are given in table 15.

TABLE: 15

S. No.	Culture Isolates	No.of cases Percentage (n=74)	Non-Inflammatory Types(n=46)	Inflammatory Types (n=19)	Mixed (n= 9)
1	*T. tonsurans*	23 (31.1%)	18(24.3%)	4(5.4%)	1(1.4%)
2	*T. violaceum*	19 (25.7%)	8(10.8%)	6(8.1%)	5(6.8%)
3	*T.mentagrophytes*	19 (25.7%)	11(14.9%)	7(9.5%)	1(1.3%)
4	*T. rubrum*	12 (16.2%)	8(10.8%)	2(2.7%)	2(2.7%)
5	*T.verrucosum*	1 (1.3%)	1(1.3%)	0	0

Various agents in relation to the Non-inflammatory, inflammatory and mixed types are given in figure 7 and 8.

Figure: 7

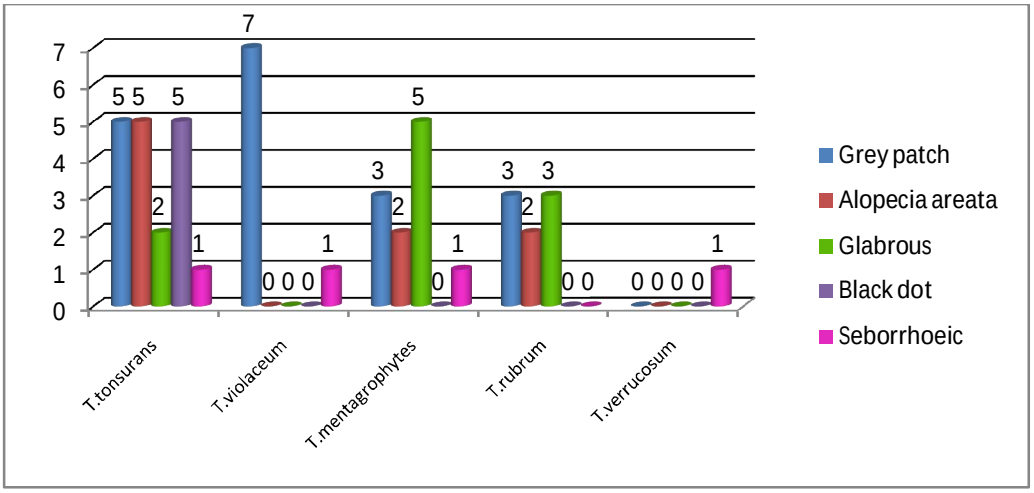

Figure: 8

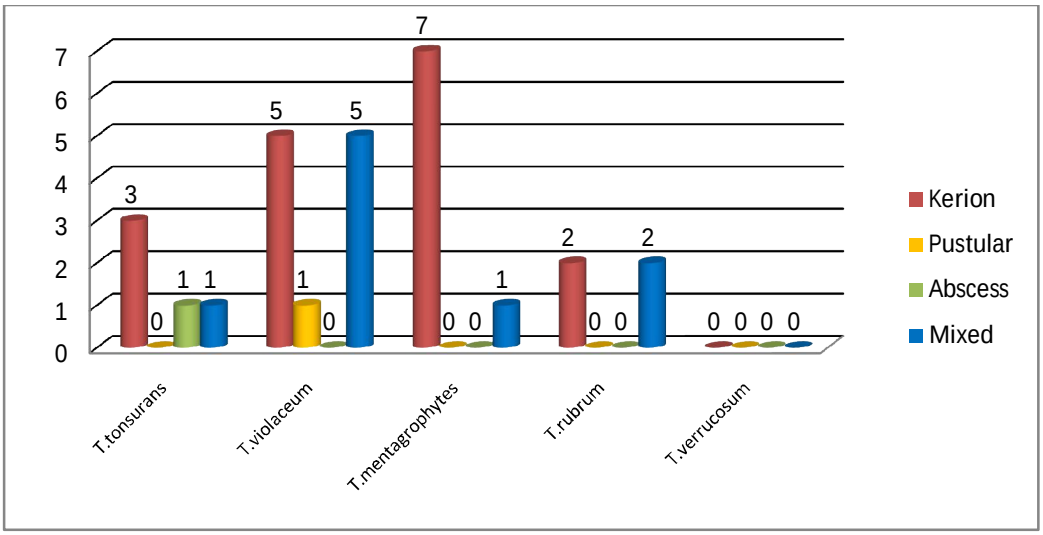

T.tonsurans (31.1%) was isolated from patients with non-inflammatory, inflammatory and mixed types of tinea capitis. *T.violaceum* (25.7%) and *T.mentagrophytes* (25.7%) were isolated predominantly from patients with non-inflammatory tinea capitis. *T.rubrum* (16.2%) was isolated from grey patch and glabrous type of non-

inflammatory tinea capitis. *T.verrucosum* (1.3%) was isolated from a single child. Among the mixed types, none of the specimens grew more than one fungal species.The correlation between the clinical types and the dermatophyte species is statistically significant. (p=0.01)

Sex wise distribution of the culture positive cases :

Among the males, *T.tonsurans* and *T.violaceum* were commonly isolated while among the females *T.tonsurans* and *T.mentagrophytes* were isolated. There was no statistically significant difference in the sex distribution among various species. (p=0.55) The sex wise distribution of the culture positive cases is given in table 16.

TABLE: 16

S. No.	Species isolated	Male n= 51(%)	Female n= 23(%)	Total n=74(%)
1	*T.tonsurans*	15 (20.3%)	8(10.8%)	23(31.1%)
2	*T.violaceum*	14(18.9%)	5(6.8%)	19(25.7%)
3	*T.mentagrophytes*	11(14.9%)	8(10.8%)	19(25.7%)
4	*T.rubrum*	10(13.5%)	2(2.7%)	12(16.2%)
5	*T.verrucosum*	1(1.3%)	0	1(1.3%)

Age wise distribution among culture positive isolates :

T.tonsurans was isolated more commonly in the age group of 0-4 years. Among the 5-10 years age group, *T.violaceum* was most commonly isolated. In adults with age more than 20 years, *T.rubrum* was the most commonly isolated agent followed by *T.mentagrophytes.* There was statistically significant difference in the age distribution among the various species isolated. (p=0.02) The age wise distribution among the various culture positive isolates are given in the table17.

TABLE: 17

S. No.	Species isolated	0-4 years (n=26)	5-10 years (n=33)	11-15 years (n=17)	16-20 years (n=4)	Above 20 years (n=6)	Total (n=74)
1	*T.tonsurans*	13	6	3	0	1	23
2	*T.violaceum*	6	8	5	0	0	19
3	*T.mentagrophytes*	5	5	6	2	1	19
4	*T.rubrum*	0	6	1	2	3	12
5	*T.verrucosum*	1	0	0	0	0	1

Clinico mycological Correlation : Table 18.

Table: 18

Clinical Types	T.tonsurans n =23(%)	T.violaceum n =19(%)	T.mentagrophytes n =19(%)	T.rubrum n =12(%)	T.verrucosum n =1(%)
Grey Patch (n=22)	5 (6.76%)	7 (9.45%)	3 (4.05%)	3 (4.05%)	0
Smooth Patch (n=13)	5 (6.76%)	0	2 (2.70%)	2 (2.70%)	0
Glabrous (n=11)	2 (2.70%)	0	5 (6.76%)	3 (4.05%)	0
Black dot (n=5)	5 (6.76%)	0	0	0	0
Seborrhoeic (n=5)	1 (1.35%)	1 (1.35%)	1 (1.35%)	0	1 (1.35%)
Kerion (n=18)	3 (4.05%)	5 (6.76%)	7 (9.45%)	2 (2.70%)	0
Pustular (n=1)	0	1 (1.35%)	0	0	0
Abscess (n=1)	1 (1.35%)	0	0	0	0
Mixed (n=9)	1 (1.35%)	5 (6.76%)	1 (1.35%)	2 (2.70%)	0
Total (n=74)	23 (n=31.1%)	19 (25.7%)	19 (25.7%)	12 (16.2%)	1 (1.3%)

In patients with non inflammatory types (n=65), culture positive were 46 and among them *T.tonsurans* was isolated in 18 (39.1%) followed by *T.mentagrophytes* in 11(23.9%), *T.violaceum* in 8(17.4%), *T.rubrum* in 8 (17.4%) and *T.verrucosum* in 1(2.2%) patient. Among the grey patch type (n=18), *T.violaceum* was isolated in 7 (38.9%) cases.

Among the smooth bald patch type (n=9), *T.Tonsurans* was the commonest isolated in 5 (55.5%) cases. In patients with glabrous type (n=10), *T.mentagrophytes* was isolated mostly in 5(50%) cases. In the black dot type (n=5), *T.tonsurans* was isolated in all the total 5 cases (100%). Among the seborrhoeic type (n=4), 4 different organisms were isolated. *T.verrucosum*, was isolated from a single child.

In patients with inflammatory types (n=23), culture positive were 19 cases and among them *T.mentagrophytes* was isolated in 7(36.8%) followed by *T.violaceum* in 6(31.6%), *T.tonsurans* in 4(21.1%) and *T.rubrum* in 2 (10.5%) patients. Among the kerion type (n=17), *T.mentagrophytes* was isolated in 7 (41.2%) cases. *T.violaceum* was isolated from the pustular type and *T.tonsurans* from the abscess type.

Among the mixed type (n=10), culture positive were 9 cases and among them *T.violaceum* was the most common agent isolated in 5(55.5%).

Non-inflammatory types of tinea capitis – Grey patch (Figure: 9)

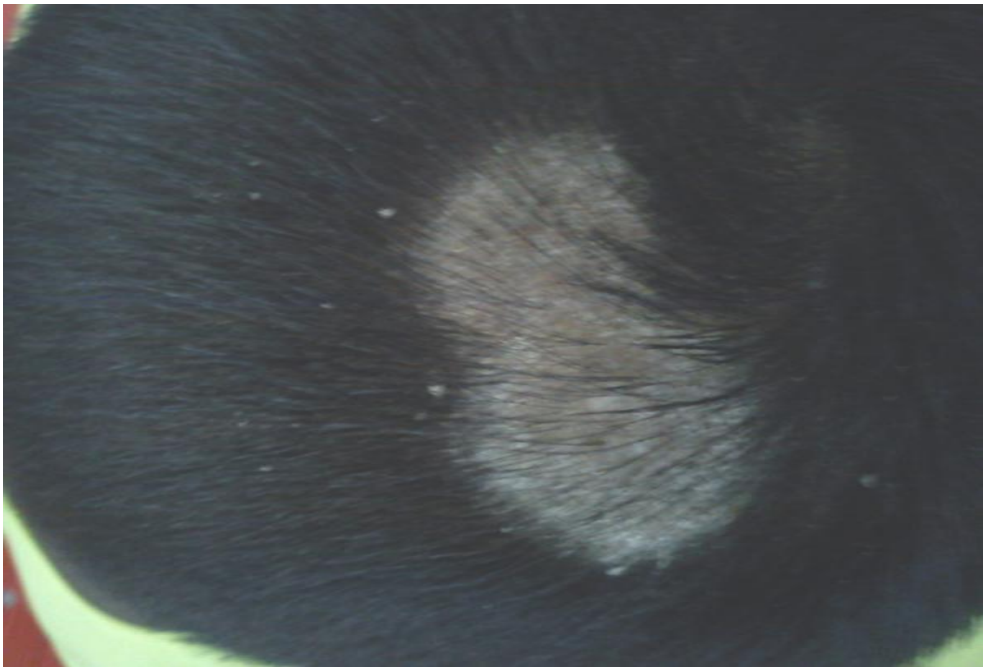

Multiple grey patches (figure: 10)

Black dot type (Figure: 11)

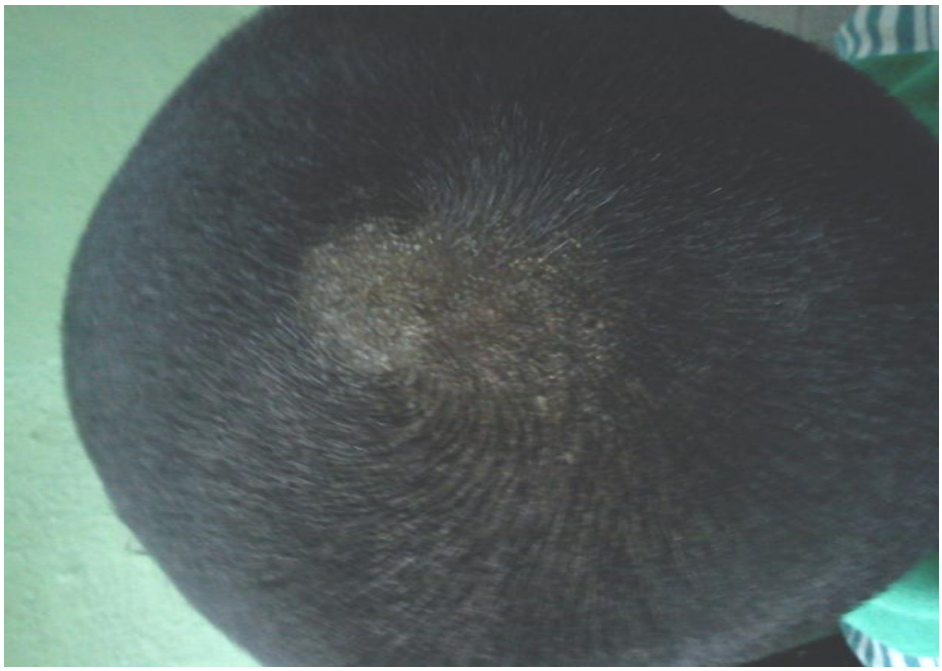

Glabrous type in adult patient(Figure: 12)

Smooth patch of baldness (Figure: 13)

Seborrhoeic type (Figure: 14)

Intrafamilial infection (Figure: 15)

Tinea capitis wih Id eruption and Cervical lymph node enlargement

(Figure: 16)

Inflammatory types of tinea capitis – Kerion (Figure: 17)

Abscess type (Figure: 18)

Trichophyton tonsurans (Figure: 19 & 20)

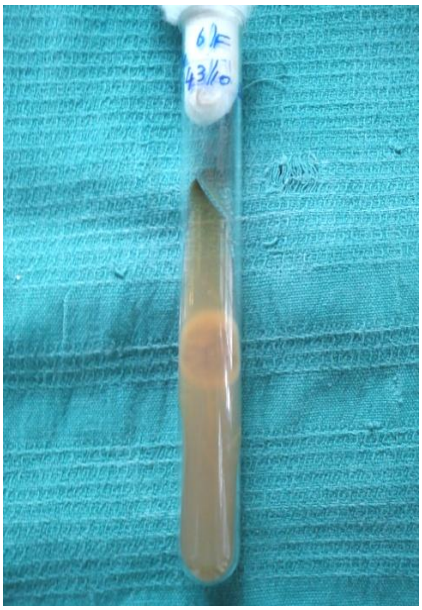

Creamy white colony with radial furrows and reverse buff coloured

Microscopy (Figure: 21)

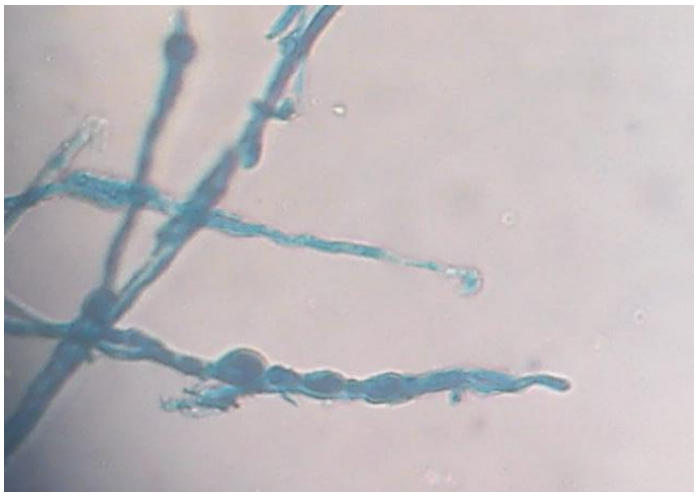

Intercalary and terminal chlamydoconidia and match

stick micro conidia

Trichophyton violaceum (Figure: 22 &23)

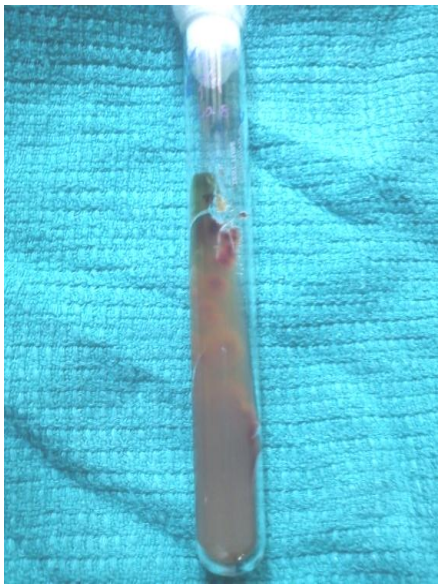

Waxy leathery violet colony on front and reverse

Microscopy (Figure: 24)

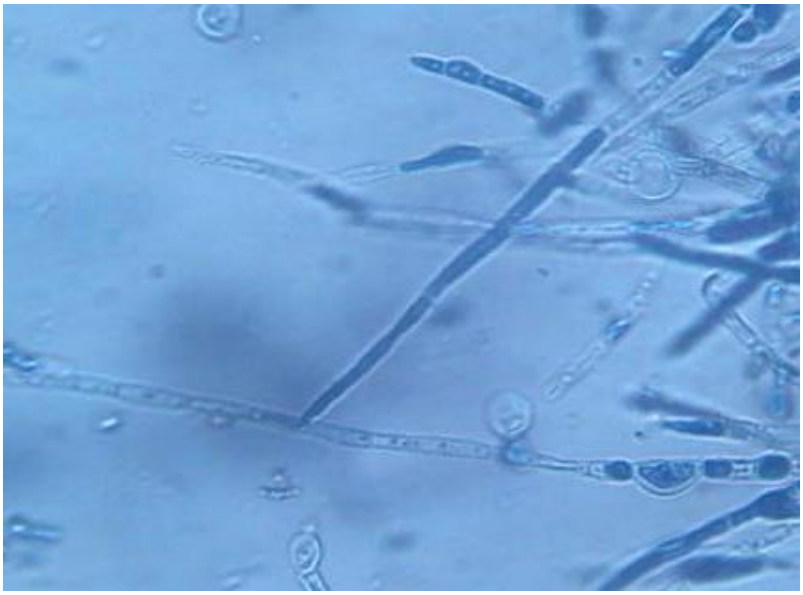

Chlamydoconidia and distorted hyphae

Trichophyton mentagrophytes (Figure: 25 & 26)

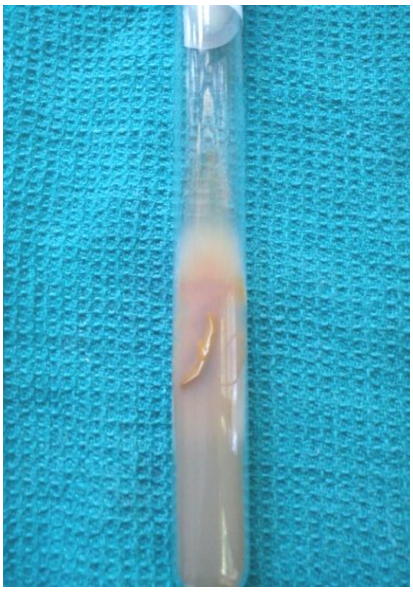

White granular colony with reverse brown colour

Microscopy (Figure 27 &28)

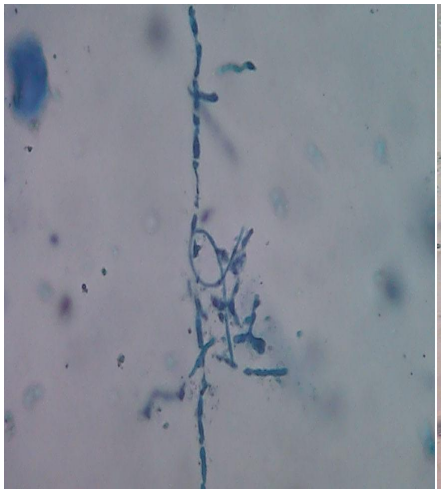

Coiled spiral hyphae and cylindrical macro conidia

Trichophyton rubrum (Figure: 30 &31)

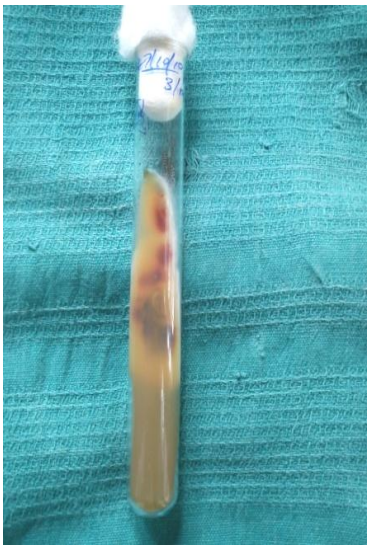

Surface white cottony colony with reverse deep red pigment

Microscopy (Figure: 32)

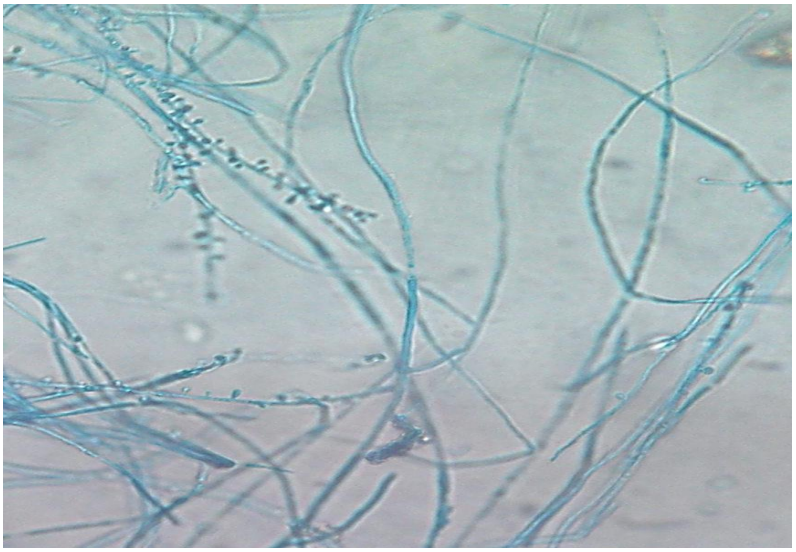

Small tear shaped micro conidia along the sides of hyphae

Trichophyton verrucosum (Figure: 33 &34)

White waxy colony

Microscopy (Figure: 35)

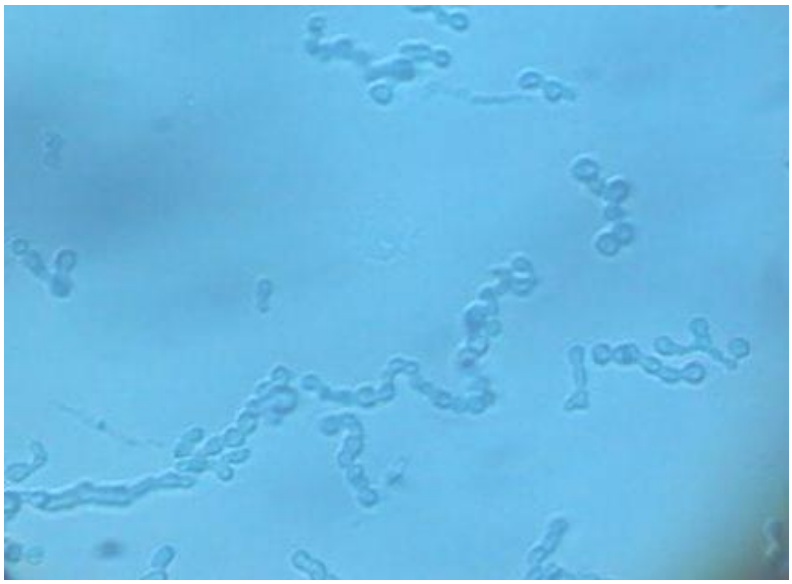

Long chains of chlamydoconidia

DISCUSSION

Tinea capitis occurs predominantly in children, although it can be seen in all age groups as observed by Kamalam et al, Vanbreuseghem, Kumari et al and Sehgal et al [1, 2, 5 ,11]. In this study, the common age group affected was 5 to 10 years while the infection was less common in the age group above 16 years. Patients aged 15 years and below account for 88.7% of cases of tinea capitis. Among all age groups, males outnumbered the females by a ratio of 2.3:1 close to the findings reported in literature and in studies done by Kamalam et al, Vanbreuseghem and Jagdish Chander et al [1, 5, 11, 81]. The male predominance could be due to the short hair when compared to girls[3].The study by Kamalam et al also showed that tinea capitis was most common in the 5-10 years age group and males were affected more than females with a ratio varying from 3:2 to 4:1[11].A similar observation of higher incidence between 5-10 years of age with a male preponderance was observed by Vanbreuseghem in his study [17].

History of tonsuring was present in 46.9% of the patients. Duration between the tonsure and the onset of infection ranged from 4 to 8 weeks. This is in concurrence with the studies done by Kamalam et al and Mubashir Maqbool Wani et al. Kamalam et al observed that in a considerable number of patients, the disease had begun following a scalp shave [6]. Mubashir Maqbool Wani et al reported that trauma assists

inoculation, which was followed, after approximately 3 weeks, by clinical evidence of hair shaft infection[7]. History of sharing combs and caps was found in 57.1% of patients. Similar observation of sharing combs and caps was found in 66% to 76% in a study by Barbara J Reid et al in their study[23]. Family history of other clinical types of dermatophyte infection was found in 15.3% of cases. Intrafamilial infection of tinea capitis was found in 2.3% of patients. Such observation of intra familial infection has been observed in various studies by Kamalam et al, Sentamilselvi and Phipot CM [3, 6, 24, 25, 72]. AS Thambiah and Kamalam found in their study that the intra familial incidence of tinea capitis varied from 3.6% to 80% [72].

Most of the patients in this study group (70.4%) belonged to low socio-economic status. Studies in Delhi by Kumari et al and Sehgal et al have shown that around 68% of patients came from overcrowded areas with low socio-economic status[15, 16].Thus personal and social factors play an important role in tinea capitis.

Systemic associations were observed in 10.2% of patients which were epilepsy, rheumatoid arthritis, Down's syndrome, subnormal mentation, pulmonary tuberculosis, bullous pemphigoid, myeloproliferative disorder and empyema. Among those patients with systemic associations 6 were chidren and 4 were adults. Similarly Vanbreuseghem reported increased incidence of tinea capitis in children with debilitating disease or nutritional deficiency [17]. Of the adult patients,

two were immune compromised due to treatment with steroids for bullous pemphigoid and rheumatoid arthritis, whereas the third patient had pulmonary tuberculosis. The duration of the infection varied from 2 weeks to 24 weeks in this study. Asymptomatic non-inflammatory types of tinea capitis are responsible for the longer duration of the disease as reported in literature[2, 3, 12].

In this study, tinea capitis alone was seen in 78.6% of patients and association with other clinical types of dermatophytosis was observed in 21.4% of patients .Among the children, tinea capitis was associated with tinea corporis, tinea cruris and tinea faciei in 9.1% of them .A study by Chandrasekaran et al also showed the association of tinea corporis and tinea faciei in children with tinea capitis [85]. Among the adult patients in our study, most of them had extensive dermatophytoses and presented with glabrous type of tinea capitis. Kamalam et al reported that combination of dermatophyte infection in other sites was more common among the adults than in children and that glabrous type contributed to a large number of adult tinea capitis [6].

Among the clinical types of tinea capitis, non-inflammatory type was the most frequent clinical type noted in 66.3% of patients, followed by inflammatory type noted in 23.5% of patients and mixed type in 10.2% of patients. Kamalam et al,Kumar AG et al, Maha Aldayel et al and Seema bose et al also reported a higher incidence of non inflammatory type of tinea capitis [3, 6, 8, 89].

Non-inflammatory type was mainly observed in all the age groups when compared to the inflammatory type. Both the non inflammatory and inflammatory types were more common in age group less than 10 years. Day and Maplestone also observed that, both the non inflammatory and inflammatory types were more common in age group less than 10 years with Tinea capitis [13].

T.tonsurans was commonly isolated in the 0-4years age group and *T.violaceum* was seen in higher preponderance in 5-10years age group. Unlike our study, the study by Seema bose et al showed that *T.mentagrophytes* was the common agent isolated from the 5-10 years age group [89].

Among the adults, *T.rubrum* was commonly isolated. In both males and females, *T.tonsurans* was the most common agent isolated. Kamalam et al also reported that *T.rubrum* and *T.mentagrophytes* was mainly responsible for the adult tinea capitis [11].

Of the 98 specimens subjected to KOH mounts 46.9% showed endothrix spores and 11.3% showed hyaline branched septate hyphae with spores and rest of the 41.8% showed only arthrospores. A similar observation of endothrix as the commonest pattern in KOH (58.8%) was noted by BSN Reddy et al in their study [60].Of the 98 specimens subjected to culture in SD Agar with actidion, positive isolates were obtained in 75.5%.

Among the non inflammatory types, grey patch was the most common type (43.1%) which is in concurrence with other studies by Kamalam et al,Sehgal et al and Maha aldayel et al[11, 16, 38]. The second commonest was smooth bald patch (21.5%) followed by glabrous type (17%). Black dot and seborrhoeic type were observed in 10.7% and 7.7% each respectively. A study by Chander grover et al reported equal level of frequency of both grey patch and black dot type [75]. Black dot type was the commonest clinical type in the study done by Kalla et al[76]. Smooth bald patch was reported in 6.5% of patients in a study by Singal et al [62], while in this study it is around 21.5%.Seema bose et al and Al Samarai A G M et al and Singal et al found seborrhoeic type of tinea capitis to be the most common presentation unlike in this study[62,89].

Among patients with non inflammatory types (66.3%), culture positive was seen in 62.1% of cases. Among them, *T.tonsurans* was isolated in 39.1% followed by *T.mentagrophytes* in 23.9%, *T.violaceum* in 17.4%, *T.rubrum* in 17.4% and *T.verrucosum* in 2.2% of patient. Kamalam et al reported that the non inflammatory types were mainly produced by *T.Violaceum* and *T.tonsurans* whereas in this study *T.violaceum* was only the third common organism [11].

In this study, among the patients with grey patch type, *T.violaceum* was isolated in 38.9% of cases, which is in concurrence with the observation by Kamalam et al. Among the smooth bald patch type, *T.tonsurans* was the commonest isolated in 55.5% of cases. In patients

with glabrous type, *T.mentagrophytes* was isolated in 50% and *T.rubrum* in 30% of cases. Similar observation was made by Kamalam et al who isolated *T.rubrum* and *T.mentagrophytes* from the glabrous type of tinea capitis[6].

In the black dot type, *T.tonsurans* was isolated in 100% of cases in this study, whereas Kamalam et al and Chander grover et al reported T.violaceum as the commonest agent in the black dot type [11, 75].Among the 4 patients with seborrhoeic type, 4 different organisms were isolated namely, *T.tonsurans, T.violaceum, T. mentagrophytes* and *T.verrucosum* .Whereas Kamalam et al reported *T.violaceum* , Seema bose et al reported *T.mentagrophytes* as the commonest etiological agent from the seborrhoeic type of tinea capitis in their studies [11,89].

Of the inflammatory types, kerion was the most common type (91.4%) as observed in other studies by Kamalam et al, Nath et al and Singal et al [3, 11, 34]. The second commonest was pustular type (4.3%) and abscess type (4.3%). Such observation of abscess type has been reported by Kamalam et al and pustular type by Chander Grover et al in their studies[11, 75].There was associated cervical lymph node involvement in 14.3% of patients and all were associated with inflammatory and mixed types. One child with mixed type manifested with id reaction over the face, trunk and arms. This is in concurrence with the previous studies by Kamalam et al and Attapattu MC. Kamalam et al reported similar

regional lymph node enlargement and id reactions in the kerion and abscess types of tinea capitis[6, 11, 86].

In patients with inflammatory types (23.5%), culture positive were 19.3% of cases and among them *T.mentagrophytes* was isolated in 36.8% followed by *T.violaceum* in 31.6%, *T.tonsurans* in 21.1% and *T.rubrum* in 10.5% of patients. Kamalam et al noted in their study that inflammatory types of tinea capitis were mainly produced by *T.violaceum* and *T.tonsurans* whereas *T.mentagrophytes* and *T.violaceum* were the commonest agents in this study[11]. Though *T.violaceum* and *T.tonsurans* are considered anthropophilic, they produced inflammatory lesions due to strain differences in pathogenesis [6]. Anthropophilic agents can produce inflammatory lesions depending on the immunological status of the patient[1, 6].

Among the kerion type (91.4%), *T.mentagrophytes* was isolated in 41.2% of cases. *T.violaceum* was isolated from the pustular type (4.3%) and *T.tonsurans* from the abscess type (4.3%). Similarly Kalla and Begra et al reported *T.mentagrophytes* as the commonest agent isolated from the kerion type followed by *T.violaceum* [76].

In this study, mixed type of tinea capitis was not seen in the age group above 20 years. It was observed in 11.6% of patients. Coexistence of various combinations of non inflammatory and inflammatory types was found and among them, grey patch with pustules was the commonest

presentation with *T.violaceum* isolated as the commonest agent. Combination of various non-inflammatory types denotes the various stages of single disease. Similar observation of mixed morphology was noted in 10% of cases by Chander Grover et al in their study with combination of black dot and grey patch, followed by grey patch with pustules. *T.violaceum* was the commonest agent in their study similar to this study [75].

Spores may be responsible for transmission of tinea capitis. The difference in host response to the infection at different sites of the scalp may produce non inflammatory and inflammatory response to the agent. Previous studies by Kamalam et al and Chander Grover et al have shown that clinical presentation is not correctly indicative of the type of dermatophyte causing the infection or vice versa, due to interference with various unknown factors [11, 75].

Trichophyton tonsurans was the predominant pathogen seen in 31.1% in this study followed by *T. violaceum* and *T.mentagrophytes* in 25.7% each, *T. rubrum* in 16.2% and *T.verrucosum* in 1.3% of cases. In tinea capitis, the distributions of various species are not static, and the range of species in some areas may change dramatically and quickly as reported in literature[1]. Tinea capitis is the dermatophytosis whose epidemiology has perhaps changed significantly, especially in Western and European countries with *T. tonsurans* emerging as the dominant agent [90]. In north India, *T. violaceum, T.schoenleinii* and *T.tonsurans* have

been reported to be the dominant agents[62]. In South India,studies have shown that *T. violaceum* is the principal infective agent, however *T. tonsurans* was the most common organism in this study[6,11,72] .

In any location, the species may change with time , particularly as new organisms are introduced, which explains the predominance of *T.tonsurans* in our study.

CONCLUSION

- Tinea capitis occurs predominantly in children, though it can occur in all age groups.
- Tinea capitis was observed more in boys compared to girls.
- Prevention of spread of infection can be aided by proper sterilization of instruments used for hair cut and tonsure, avoidance of sharing of combs, caps and other fomites. Intra familial and institutional infections in residential schools can be thus prevented.
- Early diagnosis and treatment of dermatophyte infection elsewhere may lead to prevention of spread to scalp and thus decrease the duration of treatment.
- Tinea capitis presents with varying clinical manifestations. Non-inflammatory types were more commonly observed than the inflammatory types.
- Grey patch was the commonest among the non-inflammatory types. Kerion was the most common type in the inflammatory group. Mixed type was also seen in a proportion of cases.
- *Trichophyton tonsurans*, an anthropophilic dermatophyte, was the most common agent which produced non-inflammatory, inflammatory and mixed types.

- *Trichophyton violaceum* and *Trichophyton mentagrophytes* were equally common following *Trichophyton tonsurans*. Both species caused inflammatory types in equal frequency. Among the non-inflammatory group, *Trichophyton violaceum* was the most common causative agent in grey patch type, whereas *Trichophyton mentagrophytes* was the commonest agent causing glabrous type of tinea capitis.

- *Trichophyton rubrum* was the causative agent in glabrous type and grey patch type tinea capitis.

- The clinico mycological correlation reveals that a single pathogen may give rise to various clinical types.

- *T. violaceum* was the most common agent isolated in South India, whereas *T. tonsurans* was isolated as the most common agent in this study.

- Further studies with a larger sample size are needed to confirm this changing trend in the predominance of the organisms.

BIBILIOGRAPHY

1) R.J. Hay & H.R. Ashbee, Mycology, Rook's textbook of Dermatology, 7th Ed, 2004, 31.19 to 31.59.

2) Drs William D James, Timothy G Berger and Dirk M Elston, Andrew's diseases of the skin, 11th Ed, 298-301.

3) Thomas P Habif. Clinical dermatology, Elsevier 2004, ch 13,Superficial fungal infections.

4) Michael M.Nelson, Ann.G.Martin, Superficial fungal infections,Freedberg IM, Eisen AZ, Wolff K, Goldsmith LK, Katz SI, Fitzpatrick's Dermatology in General Medicine 6th ed , volume 2 pages 1989-2004.

5) Elewski BE, Tinea capitis, a current prospective, J Am Acad Dermatol 2000, 42: 1-20.

6) Kamalam, A. Observations on the Gamut/Galaxy of the fungal infections in Tamilnadu state, Kavaka 1984; 12:15-36.

7) Mubashir maqbool wani, Quarat-ul-ain-kamli, Trends of Tinea capitis in population attending dermatology department of a tertiary health care facility in Kashmir, JK-Practioner 2006; 13(3); 131-133.

8) Powell A. Ringworm in Assam, Indian Med.Gazette, 1900; 35-109

9) Bose SR. Comments on rarity of Tinea capitis in India, Mycopathologica 1964; 322-29.

10) Kamalam A, Thambiah AS, *Trichophyton violaceum* infection in an Indian school. Int J Dermatol, 1976: 15(2): 136-139.

11) Kamalam A, Thambiah AS, Tinea capitis, an endemic disease in Madras, Mycopthologica; 1980; 70; 45-51.

12) Frieden IJ, Tinea capitis, asymptomatic carriage of infection, Pediatr infections, Newyork, Igaku-shoin-1992.

13) Dey NC, Maplestone PA, *Trichophyton crateriformis* in India, Indian Med Gazette, 1941; 410.

14) Bharadwaj G, Hajini GH, Khan IA, Masood Q, Khosa RK. Dermatophytoses in Kashmir, India, Mykosen, 1987; 30: 135-8.

15) Kumari S, Bagga SR, Singh R et al, A Clinicomycological study of dermatophytoses in Delhi, J Communicable Diseases, 1985; 17: 68-71.

16) Sehgal VN, Saxena AK, Kumari S.Tinea capitis: A clinic-etiological correlation. Int J Dermatol, 1985; 24: 116-9.

17) Vanbreuseghem R. Tinea capitis in Belgium Congo and Rwanda and Burundi; Trop Geogr Med 1958, 10:103-12.

18) Ajani GH, Kandahar KC, Mohapatra LN, Bhutani LK. Effect of hair oils and fatty acids on growth of dermatophytes and their in vitro penetration of scalp hair, Sabouraudia, 1970; 8:174-6.

19) MK Singh, Lalik K Gupta, BG Ghiya, Indian J Dermatol venereal leprol. Mar-Apr 2004; vol 70 Issue 2; 116-118.

20) Crozier WF, A 10 year survey on *Trichophyton tonsurans*, prevalence and strain types in general community and aborigines. Australian Journal of Dermatology 1989; 8: 174-6.

21) Kamalam A, Thambiah AS, Histological study in Tinea capitis,Mykosen. 1981; 24(7): 431-441.

22) Peachay, RDG and English MP, An outbreak of *Trichophyton rubrum* infection in a geriatric hospital. Br J Dermatol, 1974; 91(4):389-397.

23) Barbara J Reid, Michael B ShimkinStudy of Tinea capitis in Philadelphia using case and control groups, Public health reports. Vol 83; no.6; June 1968

24) Phipot CM, Some aspects of epidemiology of Tinea, Mycopathologica, 1977; 62: 3-13.

25) Sentamilselvi, G. Chapter 2; Chronic dermatophytosis- A clinical and etiopathological study. 1995; Ph D thesis submitted to University of Madras, 9-22.

26) Leeming J, Elliot TSJ, The emergence of *Trichophyton tonsurans* tinea capitis in UK, Br J Dermatol, 1995; 133: 929-31.

27) B Elewski, Dermatologic Clinics, 14, Tinea capitis, 23-31, 1996.

28) Emmons CW.Dermatophytes: Natural groupings based on the form of the spores and accessory organs. Arch Dermatol Syphilol 1934; 30: 337-62.

29) Greer DL: An overview of common dermatophytes. J AmAcad Dermatol 31: S112, 1994.

30) Aly R: Ecology and epidemiology of dermatophyte infections. J Am Acad Dermatol 31:S21, 1994.

31) Rinaldi MG: Dermatophytosis:Epidemiological and Microbiological update. J Am Acad Dermatol 43: S120, 2000.

32) Lee T. Nesbitt Jr. Treatment of Tinea capitis. Int J Dermatol 2000; 39(4): 261-262.

33) Gupta AK and Del Rosso JQ, An evaluation of intermittent therapies used to treat onychomycosis and other dermatophytoses with the oral antifungal agents. Int J dermatol 2000;39: 401-411.

34) Nath P and Agarwal PK, Some observations on mycotic infections in Lucknow. Indian Journal of Medical Research, 1971; 59(5): 675-682.

35) Kumari S, Bagga GR, Singh R,Agarwal DS and Ghosh GR,A clinic mycological study of dermatomycoses in Delhi. Journal of Communicable disease, 1985;17 (1):68-71.

36) Klingman A M, The pathogenesis of tinea capitis due to *Microsporum audouinii* and *M.canis*. J Invest Dermatol 1952; 18; 231-46.

37) Gugnani H C, Njoku-obi Anu. Tinea capitis in school children in East Nigeria. Mykosen; 1986, 29, 132-44.

38) Maha aldayel, Iqbal Buckhari, Pattern of Tinea capitis in a hospital based clinic in Alkhobar, Saudi Arabia, Indian J Dermatol; 2004; 49(2).

39) Martinez- Roig A, Llorens-Terol J, Torres JM. Erythema nodosum and Kerion of the scalp. Am J Dis Child. 1982; 136:440-2.

40) Birt AR, wilt JC. Mycology, bacteriology and histopathology of suppurative ringworm. Arch Dermatol 1957; 69: 441-8.

41) Khan KA, Anwar AA. Study of 73 cases of tinea capitis and tinea favosa in adults and adolescents. J Invest Dermatol 1968; 51: 474-77.

42) Scott DB, Scott FP. Dermatophytes in South Africa, Sabouraudia 1973, 11; 279-82.

43) Alteras, I, and Lehrer,N. A critical survey of 1000 cases of dermatophytoses in Tel-Aviv area during 1970-75; Mycopathologica, 1977; 62(2): 121-124.

44) Blank F.Human favus in Quebec. Dermatologica 1962; 125; 369-81.

45) Joly J, Delage G, Favus: 20 indigenous cases in province of Quebec .Arch Dermatol 1973; 114: 1647-8.

46) Pankajalakshmi V Venugopal and Taralakshmi V Venugopal, Mycotic infections in children in Saudi Arabia. Indian J Dermatol, 1993; 38(1).

47) LR Dasgupta, SC Agarwal and BMS Bedi, Tinea capitis in Pondicherry (South India). Journal of Medical mycology,1975 ;Vol 13(1):38-40.

48) Gupta AK, Summerbell RC,Tinea capitis, Medical mycology, 2000; 38(4):255-287.

49) Chattaway FW, Barlow AJE, Fluorescent substances produced by dermatophytes. Nature 1958; 181-281.

50) D Elder, R Elentiasas, C Jaworsky, B Johnson, Jr Philadelphia, Langley JB: Fungal diseases in Lever's Histopathology of the skin. 8th Ed Lippincott, 1997, P 577.

51) Henry D Isenberg ,De Houg GS, and J Guarro , 1995, Atlas of clinical fungi, central bureau voor schimmel cultures, Dielft, The Netherlands and Essential procedures for clinical microbiology

52) Henry D Isenberg, St Germain G and R Summerbell,1996. Identifying filamentous fungi. A clinical laboratory handbook. Star publing co, Belmont, clif from Essential procedures for clinical microbiology.

53) Irene Weitzman and Richard C.Summerbell , The dermatophytes. Clinical microbiology reviews, 1995;vol 8(2):240-259.

54) Van der straten MR, Hossain MA, Ghannoum MA,Infectious disease clinics of North America, 17, Cutaneous infections, dermatophytosis, onychomycosis and tinea versicolor, Elsevier publications.2003 ;87-112.

55) Howard R, Freiden IJ: Tinea capitis; New prospectives on an old disease. Semin Dermatol, 1995; 14:2.

56) Smith EB. The treatment of dermatophytosis; safety considerations. J Am Acad Dermatol 1997; 37:274.

57) Gupta AK, Hofstader SL, Adam P, Summerbell RC, Tinea capitis; an overview with emphasis on management. Paediatric Dermatology, 1999; 16(3): 171-189.

58) Romano C, Gianni C, Papini M, Tinea capitis in infants less than 1 year of age. Pediatr Dermatol 2001; 18(6):465-468.

59) Ijaz Ahmed, Zaffar Ahmed, Sarwat Nasreen, Prevalence of tinea capitis and asymptomatic carriage amongst school going children. Journal of Pakistan association of Dermatologists, 2006; 16:215-219.

60) BSN Reddy, G Swaminathan, Reba Kanungo, Mar D' Souza, Clinicomycological study of tinea capitis in Pondicherry. IJDVL 1991;57(3): 180-182.

61) A M Al Samarai and H I Fathi, Tinea capitis in Iraq- Laboratory results, Eastern Mediterranean health Journal, 2000; vol 6(1): 138-148.

62) Singal A, Rawats, Bhattacharya SN, Mohanty S, Baruah MC, Clinico mycological profile of tinea capitis in North India and response to griseofulvin. J Dermatol, 2001; Vol 28(1): 22-26.

63) Seale ER, Richardson JB. *Trichophyton tonsurans*: follow-up of treated and untreated cases. Arch Dermatol 1960; 81: 125–32.

64) Fernando Montero-Gei, Fluconazole in the treatment of tinea capitis. Int J Dermatol, 1998;37: 870-873.

65) Sanjeev Jain S, Virendran N and Sehgal VN. Terbinafine a unique oral antifungal, Current perceptions. Int J Dermatol 2000; 39: 412-423.

66) Boaz Amichai B, Marcelo H and Grunwald MH, Adverse drug reactionsof the new oral antifungal agents- terbiafine, fluonazole and iteaconazole. Int J Dermatol 1998; 37: 410-415.

67) Bennet ML, Fleisher AB, Loieless JW, Feldman SR, Oral griseofulvin remains the treatment of choice for tinea capitis in children. Dermatol clinics 2000; 18(1): 73-78.

68) Shimmura Y, Isolation of dermatophytes from human cases of dermatophytosis and from house dust. Japanese Journal of Medical mycology. 1985; 26(2):74-80.

69) Kamalam A, Yesudian P and Thambiah AS, Unusual presentation of *Trichophyton violaceum* infection. Br J Dermatol, 1977; 96:205-209.

70) Rapini, Ronald P, Bolognia, Jean L, Jorizzo, Joseph L, Dermatology volume set St.Louis Mosby, 2007; pp 1135.

71) Howard R, Frieden IJ, Tinea capitis , New perspectives on an old disease, Semin Dermatolol, 14:2, 1995.

72) Kamalam A, Thambiah AS, Tinea capitis in south Indian families, Mycoses vol 22(7): 251-254.

73) P Kannan, C Janaki, GS Selvi, Prevalence of dermatophytes and other fungal agents isolated from clinical samples. Ind Journal of Medical Microbiology, 2006; 24(3):212-5.

74) SN Dasgupta, SK Shome and SS Majundar, Medical Mycology in India, Mycopathologia, vol 13(4): 339-376.

75) Chander Grover, Pooja Arora and Vikas Machanda, Tinea capitis in pediatric population- A study from North India. IJDVL 2010; 76: 527-2.

76) G Kalla, B Begra, A Solanki, A Goyal and A Batra, Clinicomycological study of tinea capitis in desert district of Rajasthan, IJDVL, 61(6): 342-345.

77) Kumar V, Sharma R, Chander R, Clinicomycological study of tinea capitis. IJDVL, 1996; 62 (4): 207-9.

78) Abdel-Rehman et al, The prevalence of *Trichophyton tonsurans* in school children: The capitis study, Journal ofAmerican academy of Pediatrics, 2010; 125-966.

79) Sumon Singh, PM Beena, Profile of dermatophyte infections in Baroda, IJDVL, 2003; 69(4): 281-283.

80) Kaviarasan PK, Thappa DM, Jaishankar TJ, Sujatha S, Clinical variations in dermatophytes in HIV infected patients. IJDVL 2002; 68: 213-6.

81) Kanwar AJ, Manta, Jagdish Chander, Superficial fungal infections, Tinea capitis, In Valia RG, Valia AR. Eds. Textbook and Atlas of Dermatology. Vol 1, 2nd Ed., Bhalani publishing house, 2001;215-258.

82) Kamalam A and Thambiah AS, Occurrence of clinically different types of tinea capitis caused by *Trichophyton violaceum* in different schools, Indian Journal of Medical Research, 1979; 70: 403-406.

83) Badillet G, Influence of immigrants on the dermatophyte spectrum in Paris region. Bulletein de la Societe, Francaise de Mycologie Medicale, 1975; 4(1): 75-76.

84) Rippon JW, Cutaneous infections, Dermatophytosis and dermatomycosis – In Medial Mycology, Ed 3, WB Sauders, Philadelphia 1988; 169-275.

85) Kamalam A, Nanjappa Chetty G, Balasubramanian N, Chandrasekaran N and Thambiah AS, Tinea capitis in Moslem school, Indian Journal of Medical Research, 1979; 70:41-43.

86) Attapattu MC, A study of Tinea capitis in Srilanka, Journal of Medical and Veterinary Mycology, 1989; 27(1):27-32.

87) Kamalam A and Thambiah AS, Lupus erythematosus like Tinea capitis caused by *Trichophyton tonsurans*, Mykosen 1984; 27(6): 316-318.

88) Ravaghi M, Superficial and deep granulomatous lesions caused by *Trichophyton violaceum*, Cutis, 1976; 17(5): 976-977.

89) Seema bose, Sanjeev G Kulkarni, Irfaan Akhter, The incidence of tinea capitis in a tertiary care rural hospital- A study, Journal of Clinical and Diagnostic Research, 2011 Apr; Vol 5(2): 307-311.

90) Mahreen Ameen MD, Epidemiology of superficial fungal infections, Clinics in Dermatology (2010) 28; 197-201.

91) Lopez-Gomez S et al; Itraconazole versus griseofulvin in the treatment of tinea capitis: A double blind randomized study in children. Int J Dermatol 1994; 33: 743.

92) Fuller LC et al: A randomized comparison of 4 weeks of terbinafine Vs 8 weeks of griseofulvin for the treatment of tinea capitis. Br J Dermatol 2001; 144: 321.

93) Gupta AK, Adam P, Soloman R, Aly R, Itraconazole oral solution for the treatment of tinea capitis using the pulse regimen. Cutis 1999; 64: 192-4.

94) Allen HB, Honig PJ, Leyden JJ et al. Selenium sulphide: Adjunctive therapy for tinea capitis. Pediatrics 1982; 69:81-3

95) Ameneh Yazdanfar, Tinea capitis in primary school children in Hamedan (West of Iran). International journal of Medicine and Medical Sciences, Feb 2010; Vol 2(2): 29-33.

MASTER CHART

S. No	Age	Sex	Monthly income In Rupees Of the family	Duration of disease	History of Tonsure	Family history	Type of tinea capitis	Areas involved	Associated dermatophyte infection elsewhere	Associated Lymph nodes	Other associated systemic factors	Scraping in KOH	Culture
1	13	M	3000	12 weeks	-	-	Kerion	Parietal	-	-	-	Endothrix spores	T.violaceum
2	45	M	8000	8 weeks	-	-	Glabrous	Occipital & parietal	T.faciei, T.corporis & T.cruris	-	Epilepsy	Spores	T.rubrum
3	4	F	3500	8 weeks	Present	-	Mixed Grey patch & pustules	Occipital & parietal	-	-	-	Endothrixs pores	T.violaceum
4	6	M	4000	10 weeks	Present	Brother Tinea corporis	Alopecia areata	Temporal	-	-	-	Endothrix spores	-
5	6	F	2600	6 weeks	-	-	Alopecia areata	Parietal	-	-	-	Endothrix spores	-
6	4	F	5000	4 weeks	Present	-	Kerion	Parietal	-	2 cervical nodes	-	Spores	T.mentagrophytes
7	31	F	3000	8 weeks	-	-	Glabrous	Occipital	T.corporis & T.cruris	-	Rheumatoid arthritis	Spores	T.mentagrophytes

S No.	Age	Sex	Monthly income In Rupees Of family	Duration of disease	History of Tonsure	Family History	Type of tinea capitis	Areas involved	Associated dermatophyte infection elsewhere	Associated Lymph nodes	Other associated systemic factors	Scraping in KOH	Culture
8	14	M	2500	4 weeks	-	-	Glabrous	Occipital & parietal	-	-	-	spores	T.mentagrophytes
9	12	M	2000	8 weeks	-	-	Kerion	Parietal & Occipital	-	3 cervical nodes	-	spores	T.mentagrophytes
10	4	M	5500	12 weeks	Present	-	Black dot	Temporal	-	-	-	Endothrix spores	T.tonsurans
11	27	M	3000	4 weeks	-	-	Glabrous	Occipital	T.corporis & T.faciei	-	-	Spores	-
12	4	M	2750	6 weeks	Present	-	Alopecia areata	Temporal	-	-	Down's syndrome	Spores	T.tonsurans
13	8	F	2500	2 weeks	Present	-	Alopecia areata	Vertex	-	-	-	Spores	T.rubrum
14	11	F	3000	2 weeks	Present	-	Pustular	Vertex & temporal	-	Bilateral Cervical nodes	-	Endothrix spores	T.violaceum
15	6	F	4000	4 weeks	Present	-	Kerion	Parietal	-	2 cervical nodes	-	Spores	T.mentagrophytes
16	14	M	4500	3 weeks	-	-	Glabrous	Occipital	T.corporis & T.cruris	-	-	Endothrix spores	T.tonsurans

S No.	Age	Sex	Monthly income In Rupees Of family	Duration of disease	History of Tonsure	Family history	Type of tinea capitis	Areas involved	Associated dermatophyte infection elsewhere	Associated Lymph nodes	Other associated systemic factors	Scraping in KOH	Culture
17	4	F	4000	8 weeks	Present	-	Alopecia areata	Parietal	-	-	Subnormal mentation	Spores	T.mentagrophytes
18	11	F	3800	10 weeks	-	Mother Tinea cruris	Grey patch	Vertex	T.corporis	-	-	Hyaline hyphae & spores	T.mentagrophytes
19	20	M	1500	2 weeks	-	-	Glabrous	Parietal & Occipital	T.pedis & T.corporis	-	-	Spores	T.mentagrophytes
20	12	M	3000	4 weeks	-	-	Kerion	Vertex	-	-	-	spores	T.mentagrophytes
21	13	F	4500	5 weeks	-	-	Grey patch	Parietal	-	-	-	Hyaline filaments & spores	-
22	3	M	5000	4 weeks	Present	-	Grey patch	Temporal	-	-	-	Endothrix spores	T.violaceum
23	3	M	4000	3 weeks	Present	-	Kerion	Frontal	-	-	-	Endothrix spores	T.violaceum
24	2	F	2500	2 weeks	Present	-	Black dot	Parietal	-	-	-	Endothrix spores	T.tonsurans
25	1	M	2000	6 weeks	Present	Father Tinea corporis	Grey patch	Parietal	-	-	-	Spores	T.mentagrophytes

S No.	Age	Sex	Monthly income In Rupees Of family	Duration of disease	History of Tonsure	Family history	Type of tinea capitis	Areas involved	Associated dermatophyte infection elsewhere	Associated Lymph nodes	Other associated systemic factors	Scraping in KOH	Culture
26	8	M	2000	4 weeks	-	-	Black dot	Parietal	-	-	-	Endothrix spores	T.tonsurans
27	13	M	2750	2 weeks	-	-	Mixed Grey patch & Black dot	Parietal	-	-	Pulmonary TB	Spores	T.mentagrophytes
28	5	M	1500	3 weeks	Present	Mother Tinea faciei	Grey patch	Temporal	-	-	-	Endothrix spores	T.tonsurans
29	61	M	3500	3 weeks	-	-	Glabrous	Occipital	T.corporis	-	-	Endothrix spores	T.tonsurans
30	2	F	4000	6 weeks	Present	-	seborrhoeic	Temporal	-	-	-	Spores	T.mentagrophytes
31	10	F	2800	8weeks	-	-	Alopecia areata	Parietal	-	-	-	Spores	T.rubrum
32	6	M	2000	7 weeks	-	-	Kerion	Parietal	-	-	-	Endothrix Spores	T.rubrum
33	11	M	4500	3 weeks	-	-	Mixed Kerion & Abscess	Temporal	-	-	-	Spores	T.rubrum
34	5	F	3500	5 weeks	-	-	Multiple Grey patches	Parietal & Temporal	-	-	-	Endothrix spores	-

S No.	Age	Sex	Monthly income In Rupees Of family	Duration of disease	History of Tonsure	Family history	Type of tinea capitis	Areas involved	Associated dermatophyte infection elsewhere	Associated Lymph nodes	Other associated systemic factors	Scraping in KOH	Culture
35	5	M	2750	4 weeks	Present	-	Kerion	Parietal	T.faciei	Bilateral cervical nodes	-	Spores	T.mentagrophytes
36	16	M	1750	3 weeks	-	-	Grey patch	Temporal	-	-	-	spores	T.rubrum
37	10	M	1000	4 weeks	-	-	Alopecia areata	Parietal	-	-	Subnormal mentation	Endothrix spores	T.tonsurans
38	8	M	1200	16 weeks	-	-	Multiple Grey patches	Parietal & Temporal	-	-	-	spores	T.mentagrophytes
39	3	F	3000	2 weeks	Present	Sister Tinea corporis	Abscess	Parietal	-	-	-	Endothrix spores	T.tonsurans
40	10	F	2500	8 weeks	-	-	Black dot	Occipital	T.corporis	-	-	Endothrix spores	T.tonsurans
41	10	M	3000	8 weeks	-	-	Kerion	Occiput	-	-	-	Endothrix Spores	T.tonsurans
42	2	M	3000	12 weeks	Present	-	Grey patch	Temporal	-	-	-	Endothrix spores	T.tonsurans
43	4	M	4500	4 weeks	Present	-	Grey patch	Parietal	-	-	-	Endothrix spores	T.tonsurans

S No.	Age	Sex	Monthly income In Rupees Of family	Duration of disease	History of Tonsure	Family history	Type of tinea capitis	Areas involved	Associated dermatophyte infection elsewhere	Associated Lymph nodes	Other associated systemic factors	Scraping in KOH	Culture
44	12	F	2500	8 weeks	-	-	Kerion	Temporal	-	-	-	Spores	T.mentagrophytes
45	5	M	2000	16 weeks	Present	Father Tinea cruris	Kerion	Parietal	-	-	Seizures	Hyaline filaments & Spores	T.mentagrophytes
46	16	M	2500	3 weeks	-	-	Grey patch	Temporal	-	-	-	Hyalie filaments & Spores	T.rubrum
47	4	F	3500	4 weeks	Present	-	Kerion	Parietal	-	2 cervical nodes	-	Endothrix spores	T.tonsurans
48	6	F	2500	12 weeks	-	-	Glabrous	Occipital	T.corporis	-	-	Hyaline filaments & Spores	T.mentagrophytes
49	3	M	4000	4 weeks	Present	-	Alopecia areata	Temporal	-	-	-	Spores	T.mentagrophytes
50	8	M	6500	3weeks	Present	-	Kerion and abscess	Parietal	-	2 cervical nodes	-	Spores	T.rubrum
51	9	F	3500	5 weeks	-	-	Kerion	Temporal	-	Bilateral cervical nodes	-	Spores	T.violaceum
52	63	M	4000	20 weeks	-	-	Glabrous	Occipital	T.corporis	-	Bullous pemphigoid	Hyaline filaments & Spores	T.rubrum

S No.	Age	Sex	Monthly income In Rupees Of family	Duration of disease	History of Tonsure	Family history	Type of tinea capitis	Areas involved	Associated dermatophyte infection elsewhere	Associated Lymph nodes	Other associated systemic factors	Scraping in KOH	Culture
53	2.5	M	2750	4 weeks	-	-	Alopecia areata	Occipital & Parietal	-	-	-	Spores	-
54	12	M	2500	5 weeks	-	-	Grey patch	Temporal	T.cruris	-	-	Endothrix Spores	T.tonsurans
55 *f*	3	F	3000	24 weeks	Present	-	Mixed Grey patch & Seborrhoeic	Frontal & Temporal	-	-	-	Spores	T.tonsurans
56 *f*	4	M	3000	3 weeks	Present	Sister Tinea corporis	Grey patch	Occipital	-	-	-	Endothrix Spores	T.tonsurans
57	2.5	F	3300	3 weeks	-	-	Kerion	Temporal	-	Bilateral cervical nodes	-	Endothrix Spores	T.tonsurans
58	6	M	3500	12 weeks	-	-	Multiple Grey patches	Parietal & Temporal	-	-	Myelo-Proliferative disorder	Hyaline filaments & Spores	T.rubrum
59	13	M	2500	4 weeks	-	-	seborrhoeic	Parietal	T.corporis	-	-	Endothrix Spores	T.tonsurans
60	4	M	1500	5 weeks	Present	-	Black dot	Occipital	-	-	-	Spores	T.tonsurans
61	6	M	1750	5weeks	Present	-	Grey patch	Parietal	-	-	-	Endothrix Spores	-

S No.	Age	Sex	Monthly income In Rupees Of family	Duration of disease	History of Tonsure	Family history	Type of tinea capitis	Areas involved	Associated dermatophyte infection elsewhere	Associated Lymph nodes	Other associated systemic factors	Scraping in KOH	Culture
62 *f*	4	F	2000	4 weeks	Present	3 elder brothers	Grey patch	Parietal	-	-	-	Endothrix Spores	T.violaceum
63 *f*	7	M	2000	8 weeks	-	2 brothers & 1 sister	Grey patch	Parietal & Temporal	-	-	-	Endothrix Spores	T.violaceum
64 *f*	10	M	3000	8 weeks	-	2 brothers & 1 sister	Multiple Grey patches	Parietal & Temporal	-	-	-	Endothrix Spores	T.violaceum
65 *f*	6	M	2000	12 weeks	Present	2 brothers & 1 sister	Multiple Grey patches	Parietal & Temporal	-	-	-	Endothrix Spores	T.violaceum
66	0.5	M	1500	3 weeks	-	-	seborrhoeic	Parietal	-	-	-	Hyaline filaments & Spores	T.verrucosum
67	2	F	2500	2 weeks	Present	-	Alopecia areata	Temporal	-	-	-	Spores	T.tonsurans
68	20	M	1400	12 weeks	Present	-	Glabrous	Occipital	T.incognito, T.cruris & T.glutealis.	-	-	Spores	\ T.mentagrophytes
69	6	F	2800	8 weeks	Present	-	Grey patch	Parietal	-	-	-	Endothrix Spores	-
70	6	F	2750	2 weeks	-	-	Grey patch	Temporal	-	-	-	Endothrix Spores	T.violaceum

S No.	Age	Sex	Monthly income In Rupees offamily	Duration of disease	History of Tonsure	Family history	Type of tinea capitis	Areas involved	Associated dermatophyte infection elsewhere	Associated Lymph nodes	Other associated systemic factors	Scraping in KOH	Culture
71	2.5	M	3000	24 weeks	Present	Mother Tinea corporis	Grey patch & Kerion	Frontal	-	-	-	Endothrix Spores	T.violaceum
72	2	M	3250	6 weeks	-	-	Alopecia areata	Temporal	-	-	-	Spores	T.tonsurans
73	12	M	2750	4 weeks	-	-	seborrhoeic	Parietal	-	-	-	Hyaline filaments & Spores	-
74	4	M	3000	6 weeks	Present	-	seborrhoeic	Parietal	-	-	-	Endothrix Spores	T.violaceum
75	11	M	1750	4 weeks	Present	-	Grey patch & Black dot	Temporal	T.cruris	-	-	Endothrix Spores	T.violaceum
76	10	F	3000	8 weeks	-	-	Alopecia areata	Temporal	-	-	-	Hyaline filaments & Spores	T.tonsurans
77	7	M	1750	10 weeks	-	-	Kerion	Temporal	-	Bilateral cervical nodes	-	Spores	T.violaceum
78	5	M	3000	24 weeks	Present	-	Grey patch	Temporal	-	-	-	Endothrix Spores	T.violaceum
79	8	M	2000	4 weeks	-	-	Mixed Grey patch & pustule	Parietal	-	-	-	Endothrix Spores	-

S No.	Age	Sex	Monthly income In Rupees Of family	Duration of disease	History of Tonsure	Family history	Type of tinea capitis	Areas involved	Associated dermatophyte infection elsewhere	Associated Lymph nodes	Other associated systemic factors	Scraping in KOH	Culture
80	5	M	2150	16 weeks	-	-	Kerion	Parietal	-	2 cervical nodes	-	Spores	T.rubrum
81	30	M	3000	8 weeks	-	-	Glabrous	Occipital	T.corporis, T.cruris & T.barbae	-	-	Endothrix Spores	T.rubrum
82	5	M	2500	4 weeks	-	-	Kerion	Temporal	-	Bilateral cervical nodes	-	Endothrix Spores	T.violaceum
83	8	M	2250	6 weeks	-	-	Kerion	Frontal	-	-	-	Endothrix Spores	-
84	7	M	2450	3 weeks	-	-	Alopecia areata	Temporal	-	-	Empyema	Hyaline filaments & Spores	-
85	11	M	2500	4 weeks	Present	-	Mixed Grey patch & pustule	Parietal	-	-	-	Endothrix Spores	T.violaceum
86	12	M	3000	6 weeks	-	-	Mixed Seborrhoeic & Grey patch	Parietal & frontal	-	-	-	Endothrix Spores	T.violaceum
87	25	M	7000	6 weeks	Present	-	Alopecia areata	Occipital	T.corporis	-	-	Spores	-
88	7	F	1250	4 weeks	-	Father Tinea corporis	Grey patch	Parietal	-	-	-	Hyaline filaments & Spores	-

S No.	Age	Sex	Monthly income In Rupees Of family	Duration of disease	History of Tonsure	Family history	Type of tinea capitis	Areas involved	Associated dermatophyte infection elsewhere	Associated Lymph nodes	Other associated systemic factors	Scraping in KOH	Culture
89	5	M	2000	3 weeks	Present	-	Kerion	Frontal	-	2 cervical nodes	-	Endothrix spores	-
90	4	M	3000	5 weeks	Present	-	Black dot	Frontal & Temporal	-	-	-	Spores	-
91	2	F	3000	4 weeks	Present	Mother Tinea corporis	Grey patch	Temporal	-	-	-	Endothrix spores	-
92	3	M	2500	5 weeks	Present	-	Grey patch	Parietal	T.cruris	-	-	Spores	-
93	7	M	3000	6 weeks	-	-	Grey patch	Frontal	-	-	-	Endothrix spores	-
94	2	M	3000	3 weeks	Present	Brother Tinea cruris	Kerion	Parietal	-	-	-	Spores	-
95	5	M	4000	4 weeks	Present	-	Grey patch	Temporal	T.corporis	-	-	Spores	-
96	3	M	2500	5 weeks	Present	-	Black dot	Occipital	-	-	-	Spores	-

S No.	Age	Sex	Monthly income In Rupees Of family	Duration of disease	History of Tonsure	Family history	Type of tinea capitis	Areas involved	Associated dermatophyte infection elsewhere	Associated Lymph nodes	Other associated systemic factors	Scraping in KOH	Culture
97	4	F	3000	4 weeks	-	-	Kerion	Parietal	-	2 cervical nodes	-	Hyaline filaments & Spores	-
98	8	M	3500	5 weeks	Present	Father Tinea corporis	Grey patch	Temporal	T.cruris	-	-	Endothrix spores	-

M - Male

F -Female

T.corporis -Tinea corporis

T.cruris -Tinea cruris

T.faciei -Tinea faciei

T.barbae -Tinea barbae

T.incognito -Tinea incognito

T.glutealis -Tinea glutealis

Clinico mycological study of Tinea capitis

Proforma

S.No:

Name:

Address:

No. of Family members:

Occupation:

Socioeconomic status:

1. Presenting complaints and duration:

   Hairless patch: Scales/Smooth

   Itching

   Swelling over the scalp

   Pus discharge

   Scaling of the scalp

   Crusted and scaly lesions with matting of hair

   Swelling in the neck (lymph nodes)

   Pain/fever

   Skin rash

   Painful red swellings

2. History of hair cut/ tonsure: (Temple/Saloon)

   Duration between hair cut/ tonsure and the onset of symptoms.

3. History of contact with infected person/ animals

4. History of similar complaints in the past in the patient/ siblings/ other family members.

   If yes, was treatment taken and details of treatment.

5. Other relevant medical history
6. Family history
7. Personal history

   Sharing of caps / combs / bedding / clothes / towels.

   Contact with pets/ domestic animals.

   Bathing/ washing of hair (frequency).

General examination:

Nourishment Weight Other relevant findings

Local dermatological examination:

Description of the lesion:

Site Size Number

Type of lesion:

Grey patch	Kerion
Black dot	Abscess
Seborrhoeic	Favus
Smooth patch of baldness	Pustular
Glabrous	Agminate folliculitis

Mixed

Clinical diagnosis:

Investigations:

Scraping scalp

Hair root examination

Culture

Haemogram- HB, TC, DC, ESR, Platelets

LFT- Serum bilirubin, Total proteins, SGOT, SGPT, SAP

RFT- Blood urea, Serum creatinine

Random blood sugar