

Whole Body Thermochemotherapy in an Infant With Rhabdomyosarcoma and Pulmonary Metastases

P. Schippel, MD,¹ I. Lotz, MD,² K. Rothe, MD,³ C. Greiner, MD,⁴ and C. Mauz-Körholz, MD^{5*}

Key words: hemangiopericytoma; brachytherapy; childhood tongue cancer

Whole body hyperthermia (WBH) application in combination with chemotherapy has been proven to be effective in advanced malignancies. Using a radiation heating device, Robins et al. [1] studied the combined application of carboplatin and WBH (1 hr at 41.8°C) in 30 patients with chemotherapy refractory tumors. In 6/30 patients, a response to therapy could be achieved, in another two female patients with ovarian carcinoma normalization of tumor markers was obtained and in one patient with a gastrointestinal neuroendocrine tumor complete remission was induced. In addition, Wiedemann et al. [2] showed that WBH combined with ifosfamide, carboplatin, and etoposide is very effective in the treatment of advanced rhabdomyosarcoma in adults. In children, only limited experience exists with the combination of WBH and chemotherapy. In one study, hyperthermia was applied using a modified dialysis method with an extracorporeal heat exchanger [3] and in another study children were treated according to the Robins method with a radiative heating device [4]. However, in this study, lung metastases and age below 6 years were exclusion criteria.

Here, a girl at the age of 2 months presented with a botryoid rhabdomyosarcoma of the right greater labium at the external genital region. Initially, a microscopical R0 resection was performed followed by a chemotherapy regimen according to the cooperative sarcoma study (CWS-96 protocol) for low-risk patients. The girl, therefore, received two cycles of vincristine and dactinomycin. However, the response evaluation at the end of chemotherapy showed extended pulmonary metastases (Fig. 1). Then, the treatment was intensified with vincristine, ifosfamide, dactinomycin, epirubicin, carboplatin, and etoposide according to the high-risk arm B in the CWS-96 protocol [5]. Although the total volume of the pulmonary metastases was reduced to about 50% (Fig. 1), we decided to treat the patient with WBH and chemotherapy, since still numerous metastases were left. With a combination of WBH using a modified hemodialysis system as an extracorporeal heating device as previously described [3] and ifosfamide (2,000 mg/m²), carboplatin (300 mg/m²), and etoposide (100 mg/m²). The individual drug dosing together with the hyperthermia application is shown in Table I. Briefly, WBH application was carried out in general anesthesia with orotracheal intubation and mechanical ventilation. Anesthesia was induced with intravenous (i.v.) application of midazolam, propofol, and alfentanil and then continued with gamma-hydroxybutyrate and alfentanil. The blood glucose level was raised to 20 mmol/L and maintained throughout the hyperthermia procedure. The blood pressure, the heart rate, and the respiration were kept within age-related ranges without additional medication. With a fraction of inspired oxygen (FiO₂) between 0.4 and 1.0 the

oxygen saturation was always 98–100%. The electrolytes and the acid–base status were continuously monitored before during and after the treatment and could be balanced with the controlled infusion and extraction of electrolyte solutions by the hemodialysis technique. With the extracorporeal dialysis method the body temperature, measured by a sensor within a urinary catheter, was elevated from 36.5°C (median) to 41.8°C within a 1.2–2.8 hr warming-up period and was maintained for additional 2 hr at this plateau temperature, when carboplatin and etoposide were sequentially infused. Ifosfamide was already given at 39°C body temperature, since this prodrug has first to be metabolized into a biologically active compound. In order to cool down the body temperature to normothermia after the 2 hr plateau temperature, the blood flow of the hemodialysis was rapidly reduced and the heat exchanger was stopped. Then, the girl remained intubated for 24 hr after each session. Toxicity according to WHO criteria (grading 0–IV) occurred predominantly in the hematopoietic system and was grade II–IV regarding thrombocytopenia, neutropenia, and anemia. Therefore, after the second and third cycle a support of previously harvested autologous stem cells (1 × 10⁶ CD34+ cells/kg BW) was applied in order to shorten the duration of neutropenic intervals. After the fourth and fifth cycle transient elevation of liver enzymes, a short-term loss of attention and transient palsy and paresthesia of the lower limbs occurred. The first cycle of thermochemotherapy was administered on only one day for dose finding reasons. From the second cycle on the dose of carboplatin was escalated from 200 to 300 mg/m² and the drug combination of day 1 was repeated twice (day 2–3), however, without hyperthermia application. Due to toxicity reasons drug doses were reduced to 75% throughout all

¹Department of Anesthesiology, Leipzig University Medical Center, Germany

²Department of Diagnostic Radiology, Leipzig University Medical Center, Germany

³Department of Pediatric Surgery, Leipzig University Medical Center, Germany

⁴Department of Pediatrics, St. Georg Medical Center, Leipzig, Germany

⁵Division of Pediatric Hematology-Oncology and Hemostaseology, Department of Pediatrics, Leipzig University Medical Center, Germany

Grant sponsor: McDonalds Kinderhilfe-Stiftung; Grant sponsor: Elternhilfe für krebskranke Kinder Leipzig e.V.; Grant sponsor: Lions Club Saxonia Leipzig, Germany.

*Correspondence to: C. Mauz-Körholz, Division of Pediatric Hematology/Oncology, Department of Pediatrics, University of Leipzig Medical Center, Oststr. 21-25, D-04317 Leipzig, Germany.

E-mail: mauc@medizin.uni-leipzig.de

Received 11 December 2002; Accepted 9 April 2003

TABLE I. Therapy Regimen

WBH cycle no.	Anticancer drugs	Day 1 WBH (*)	Day 2	Day 3
I	Ifosfamide (2,000 mg/m ²) Carboplatin (200 mg/m ²) Etoposide (100 mg/m ²)	▼+* ▼+* ▼+*		
II–V (dose reduction to 75%)	Ifosfamide (2,000 mg/m ²) Carboplatin Etoposide (100 mg/m ²)	(300 mg/m ²) ▼+* ▼+*	(50 mg/m ²) ▼ ▼	(50 mg/m ²) ▼ ▼

In the first WBH cycle, thermochemotherapy was applied only on one day with a reduced dosage of carboplatin. In the second cycle, chemotherapy was given from day 1–3, while hyperthermia was applied only on day 1 and carboplatin was reduced to 50 mg/m² on day 2 and 3. In cycle no. II and III, a stem cell support (1 × 10⁶ CD34+ cells/kg BW) was given on day 7.

following cycles (Table I). After 5 cycles of combined WBH, an 80% reduction of the total tumor volume could be observed (Fig. 1). Although most of the thoracic metastases could be surgically removed, followed by high-dose chemotherapy with busulfan (300 mg/m²), melphalan (100 mg/m²), and low-dose IL-2 treatment (0.4 million U s.c. every other day for 2 weeks), the child died of progressive pulmonary metastases (Fig. 1) 1 year after relapse.

DISCUSSION

We here report on a child with pulmonary metastasized rhabdomyosarcoma who was treated with WBH combined with ICE chemotherapy. Experimental investigations demonstrated that hyperthermia enhances the efficacy of chemotherapy. This enhancement was shown to be mediated by different apoptotic signaling pathways in tumor cells [6,7]. Our patient tolerated the above described therapy regimen well, although she was of very young age and presented with extensive pulmonary metastases. Recently, a phase I study on WBH and ICE

chemotherapy in pediatric tumor patients has been published [4]. The reported side effects were: pulmonary toxicity with reversible pulmonary edema, paresthesia, ventricular extrasystoles, hematopoietic system toxicity WHO grade ≥ III, skin toxicity, grade II liver and renal toxicity, and reactivation of viral infections. Exclusion criteria in this study were age below 6 years and impaired lung function, e.g., due to pulmonary metastases. In contrast to the reported study, in our treatment regimen mechanical ventilation regularly was continued in patients up to 24 hr post WBH to possibly treat a pulmonary edema. Furthermore, we used an extracorporeal heating system first described by Willnow et al. [3]. The hemodialysis technique easily extracts toxic metabolic substances from the circulation, but possibly also dialyzes anticancer drugs. Motzer et al. [8] showed that under dialysis conditions about one third of the drug concentration of carboplatin will be extracted from circulation within a period of 2 hr. However, in our procedure carboplatin was applied at the end of the plateau phase, when the blood flow of the hemodialysis was dramatically reduced for cooling down of the body temperature.

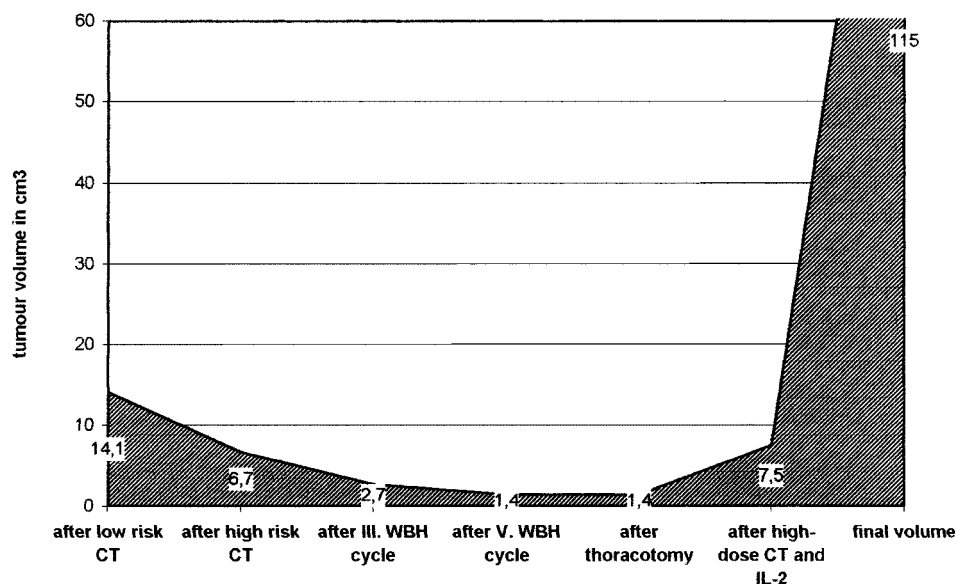


Fig. 1. Cumulative volume of the pulmonary metastases during treatment course. The cumulative volume of the pulmonary metastases was calculated in cm³ from measurement values out of high-resolution multi-sliced thoracic computed tomographic scans of the patient on the indicated time points. CT, chemotherapy; WBH, whole body hyperthermia; IL-2, Interleukin 2.

In conclusion, we demonstrated that WBH with ICE chemotherapy is a feasible and probably effective treatment even in small children with extended pulmonary metastases.

REFERENCES

1. Robins HI, Cohen JD, Schmitt CL, et al. Phase I clinical trial of carboplatin and 41.8°C whole-body hyperthermia in cancer patients. *J Clin Oncol* 1993;11:1787–1794.
2. Wiedemann GJ, d'Oleire F, Knop E, et al. Ifosfamide and carboplatin combined with 41.8°C whole-body hyperthermia in patients with refractory sarcoma and malignant teratoma. *Cancer Res* 1994;54:5346–5350.
3. Willnow U, Lindner H, Brock D, et al. Treatment of otherwise incurable tumor diseases in childhood using whole body hyperthermia and chemotherapy. *Dtsch Med Wschr* 1989;114:208–213.
4. Döll C, Wulff B, van Heek-Romanowski R, et al. Ganzkörperhyperthermie und Chemotherapie bei Kindern mit refraktären malignen Erkrankungen. *Kinder-und Jugendmedizin* 2001;1:A13.
5. CWS-96-Protokoll in der Gesellschaft für Pädiatrische Onkologie und Hämatologie (GPOH).
6. Mauz-Körholz C, Dietzsch S, Banning U, et al. Heat- and 4-hydroperoxy-ifosfamide-induced apoptosis in B cell precursor leukemias. *Int J Hyperthermia* 2003;19:444–460.
7. Mauz-Körholz C, Dietzsch S, Banning U, et al. Mechanisms of hyperthermia- and 4-hydroperoxy-ifosfamide-induced cytotoxicity in T cell leukemia. *Anticancer Res* 2002;22:4243–4248.
8. Motzer RJ, Niedzwiecki D, Isaacs M, et al. Carboplatin-based chemotherapy with pharmacokinetic analysis for patients with hemodialysis-dependent renal insufficiency. *Cancer Chemother Pharmacol* 1990;27:234–238.

Osteosarcoma in the First Decade of Life

Rajaram Nagarajan, MD,^{1*} Brenda J. Weigel, MD,² Roby C. Thompson, MD,³ and John P. Perentesis, MD⁴

Key words: bone tumors; early childhood cancer; osteosarcoma

Bone tumors are infrequent cancers in the pediatric population and represent approximately 5% of cancers under the age of 20 years. The incidence of bone tumors varies by age. Bone tumors under the age of 10 years account for 1.9% (3.2 cases per million) of all tumors in the pediatric population while they account for 8.7% (14.0 cases per million) of tumors between 10 and 19-year-old. Osteosarcoma, the most common pediatric bone tumor, also exhibits this pronounced age-associated change in incidence with an incidence of 1.7 per million in patients younger than 10 years of age at diagnosis, and an incidence of 8.2 per million in the 10–19 years age group. The overall 5-year disease-free survival in pediatric non-metastatic osteosarcoma of the extremity has improved over the last several decades from 20% to approximately 60% with current therapies.

The marked difference in the incidence of osteosarcoma before and after adolescence has prompted investigators to determine whether patients presenting with disease at a younger age have a different tumor biology that may also alter their prognosis. Multiple studies have attempted to answer this question with conflicting results. Several series have described a worse prognosis for those who are younger at the time of diagnosis (under the ages of 10, 12, or 15 years) [1–6]. Other investigators have reported equivalent rates of survival between younger patients with osteosarcoma and patients who are in adolescence or young adulthood [7–16]. Here, we report the experience of a single institution in the treatment of children 10-year-old and younger with contemporary chemotherapy regimens for osteosarcoma.

The University of Minnesota serves as a major referral center for pediatric orthopedic oncology. A retrospective search of the orthopaedic and pediatric oncology databases between the years 1974 and 1999 identified 20 patients diagnosed with primary osteosarcoma at 10 years of age or younger. Medical records were abstracted for tumor characteristics, treatment

modalities, and outcomes. All patients except one had surgical care at the University of Minnesota. Survival analyses were conducted using the Kaplan–Meier product limit estimate. Survival was defined to be the time from diagnosis until death or last contact. Patients alive at last contact were considered censored for survival at that point. Any comparisons using continuous variables were conducted using *t*-tests.

The 20 patients identified in our review with osteosarcoma ranged in age from 2.2 to 10.9 years (mean 7.6 ± 2.6 years) and were evenly divided between genders (10 males/10 females). The length of follow-up ranged from 0.8 to 25.8 years (mean 7.3 ± 7.1 years). A variety of primary tumor sites were involved: tibia/fibula (5), femur (12), humerus (1), rib (1), and 1 patient had multifocal disease. One patient had a preliminary diagnosis of malignant peripheral nerve sheath tumor that was subsequently revised to osteosarcoma. All patients received some form of chemotherapy, which included combinations of high dose methotrexate, doxorubicin, platinum

¹Department of Pediatrics, Division of Epidemiology and Clinical Research, University of Minnesota, Minneapolis, Minnesota

²Department of Pediatrics, Division of Hematology/Oncology/Blood and Marrow Transplant, University of Minnesota, Minneapolis, Minnesota

³Department of Orthopedic Surgery, University of Minnesota, Minneapolis, Minnesota

⁴Division of Hematology/Oncology, Cincinnati Children's Hospital Medical Center, Cincinnati, Ohio

Grant sponsor: National Childhood Cancer Fund—Research Fellowship, Arcadia, CA; Grant sponsor: American Society of Clinical Oncology-Young Investigator Award, Alexandria, VA; Grant sponsor: Children's Cancer Research Fund, Minneapolis, MN; Grant sponsor: National Institute of Health Training Grant; Grant number: (T32 CA09607-13).

*Correspondence to: Rajaram Nagarajan, Pediatric Hematology/Oncology/Blood and Marrow Transplant, University of Minnesota, Mayo Mail Code 484, 420 Delaware St. SE, Minneapolis, MN 55455. E-mail: nagar003@umn.edu

Received 15 April 2003; Accepted 7 May 2003