



Clinical research

Accuracy of thin-slice computed tomography in the detection of coronary stenoses

Eugenio Martuscelli^{a,*}, Andrea Romagnoli^b, Alessia D'Eliseo^a,
Cinzia Razzini^a, Marco Tomassini^b, Massimiliano Sperandio^b,
Giovanni Simonetti^b, Francesco Romeo^a

^a Department of Internal Medicine, Division of Cardiology, University of Rome "Tor Vergata", Viale Oxford 81, 00133 Rome, Italy

^b Department of Diagnostic Imaging, University of Rome "Tor Vergata", Viale Oxford 81, 00133 Rome, Italy

Received 3 December 2003; revised 18 March 2004; accepted 24 March 2004

KEYWORDS

Multislice spiral computed tomography;
Coronary artery disease;
Conventional coronary angiography

Aim Our aim was to investigate the accuracy of multislice spiral computed tomography (MSCT) in the detection of significant (>50%) coronary stenosis using a scanner equipped for 16×0.625 mm collimation.

Methods In 64 patients (59 male, mean age 58 ± 5 years) with suspected coronary artery disease, MSCT (GE Light Speed-16, collimation: 16×0.625 mm) was performed 20 ± 5 days before coronary angiography (CAG). Only angiographic segments >1.5 mm were considered for analysis.

Results In all patients, MSCT was carried out without complications. Three patients were excluded from the analysis. Of 729 angiographic segments, 613 (84%) were judged evaluable by MSCT. Considering only the segments judged evaluable, the sensitivity was 89%, specificity 98%, positive predictive value 90%, and negative predictive value 98%. Including all segments in the analysis (evaluable and non-evaluable), sensitivity was 78%.

Conclusions Using a scanner with a collimation of 16×0.625 mm, our study confirms the potential role of MSCT in the detection of significant coronary stenosis with a sensitivity of 89% and a very high specificity (98%). Exclusion criteria and less than full evaluability of the coronary arteries must still be considered limitations of the method.

© 2004 The European Society of Cardiology. Published by Elsevier Ltd. All rights reserved.

Introduction

Multislice computed tomography (MSCT) has been proposed as a means of evaluating coronary artery stenoses. The first generation of MSCT was characterised by 4-slice anisotropic acquisition, resulting in an inadequate spatial and temporal resolution for reliable assessment of coronary anatomy. With this technology, the reported sensitivity for the detection of significant stenosis was in the range of 55–86%.^{1–5} In recent years, technological ad-

vances have progressively improved spatial resolution. Current scanners can acquire 12–16 submillimetric slices with faster gantry rotation and minimum volumetric information (voxel) that is almost perfectly isotropic ($0.625 \times 0.59 \times 0.59$ mm on a GE LightSpeed 16 scanner). These machines, used with improved reconstruction algorithms, can create images of greatly superior quality from a shorter acquisition^{6–10} (see Figs. 1–3).

In spite of technological advances, important limitations remain. Movement artefacts preclude the use of the technique in patients incapable of breath holding for the duration of a scan acquisition (20–30 s) or in patients with atrial fibrillation, frequent ectopic beats, or a heart

* Corresponding author. Tel./fax: +39-066788409.
E-mail address: e.martuscelli@libero.it (E. Martuscelli).

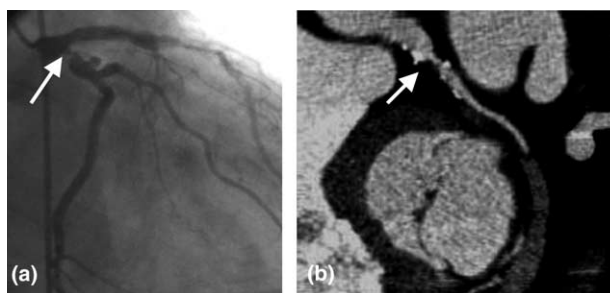


Fig. 1 (a) Angiogram shows a significant stenosis of the proximal circumflex (RAO projection). (b) MSCT (MIP) confirms the presence of a significant stenosis of the proximal circumflex artery. MIP: maximum intensity projection; MSCT: multislice computed tomography; RAO: right anterior oblique.

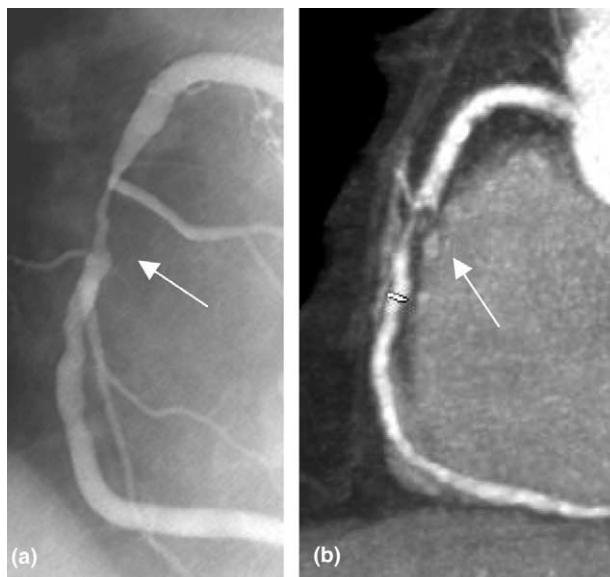


Fig. 2 (a) Angiogram (LAO projection) shows the presence of a significant stenosis in the middle part of the RCA. (b) MSCT (MIP) shows significant stenosis in the middle part of the RCA. LAO: left anterior oblique; MIP: maximum intensity projection; MSCT: multislice computed tomography; RCA: right coronary artery.

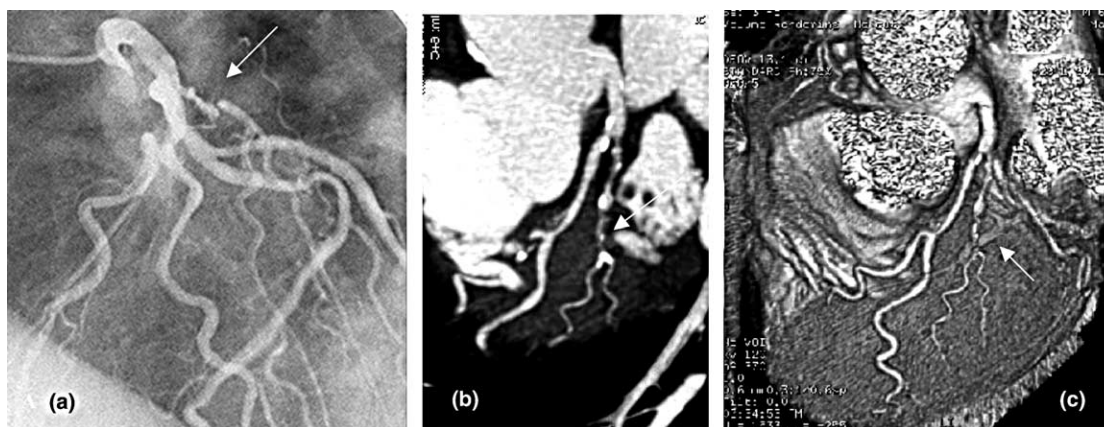


Fig. 3 (a) Angiogram (LAO, CC) shows the presence of multiple stenoses on the ramus intermedius. (b) MSCT (MIP) shows multiple stenoses on the ramus intermedius. (c) MSCT (volume rendering) shows multiple stenoses on the ramus intermedius. CC: cranio-caudal; LAO: left anterior oblique; MIP: maximum intensity projection; MSCT: multislice computed tomography.

rate of more than 80 bpm.^{11–13} Severe calcification reduces the ability to detect stenosis in the calcified segment.^{6,9,14} The role of MSCT in the clinical evaluation of patients with coronary disease is therefore still unclear.

Our aim was to investigate the accuracy of MSCT using a scan equipped with 16×0.625 mm collimation in 64 patients referred for conventional coronary angiography (CAG) because of suspected coronary artery disease.

Methods

Study group

Sixty-four patients (59 male, age 58 ± 5 years) were recruited from inpatients scheduled for CAG between March and October 2003. MSCT was performed 20 ± 5 days before CAG.

All patients were in sinus rhythm and clinically stable. We excluded patients with frequent ectopic beats, previous allergic reaction to iodine contrast agent, renal insufficiency, acute coronary syndromes, or heart failure. Patients with a history of percutaneous or surgical revascularisation were also excluded. All patients received atenolol 50–100 mg daily for at least 3 days before the procedure. The study protocol was approved by the department review board.

MSCT scan protocol

Multislice spiral computed tomography (MSCT) was performed with a General Electric LightSpeed-16 scanner (GE, Milwaukee, WI, USA). First, a localisation scan was performed without contrast to obtain an anteroposterior view of the chest. Using this, we positioned the imaging volume extending from the carina to the lower edge of the heart.

In a second step, the total amount of coronary calcium was determined from the retrospective ECG-gated scan without contrast media (8×2.5 mm collimation, tube voltage 120 Kv, tube current 320 mA).

In a third step, the volume dataset was acquired in spiral mode with simultaneous acquisition of 16 parallel slices, collimation 16×0.625 mm. The gantry rotation time was 500 ms, tube voltage 120 peak kilovolts (kVp), tube current 10–440 milliAmperes (mA) in 5-mA increments, and the table feed yielded an average value of 2.9 mm/rotation.

Dose measurement with a phantom showed an effective dose range of 8–9 mSv.

Scan delay was calculated by a bolus injection of nonionic contrast agent, considering the proximal part of the ascending aorta as the region of interest. Scan acquisition commenced soon after scan delay time. We injected continuously 120 mL of contrast agent at a rate of 4 mL/s into an antecubital vein during a 22–27 s period of breath holding. Image data were reconstructed using a snapshot algorithm if the heart rate was <60 bpm, with a single sector for image reconstruction and a temporal resolution of 250 ms. For a heart rate of 60–75 bpm, a snapshot burst algorithm was used with two sectors for image reconstruction and a temporal resolution of 125 ms.

Transaxial images were reconstructed with a slice thickness of 0.625 and 0.4 mm increments, optimising the position of the reconstruction window by increments/decrements of 10% of the cardiac cycle to minimise motion artefacts in a range of 50–80% of the cardiac cycle.

The image data with the fewest motion artefacts were transferred to a dedicated workstation (Advantage Windows 4.1, GE Milwaukee, WI, USA) for postprocessing.

The total amount of calcium in the coronary tree was quantified using specific software (SmartScorePro), according to a scoring system originally developed by Agatston for electron-beam computed tomography (Agatston Score Equivalent, ASE).^{14,15}

Depending on the coronary morphology and quality of the dataset, several postprocessing techniques were applied to assess the coronary arteries: maximum intensity projection (MIP), advanced vessel analysis (AVA), curved multiplanar reconstruction (MPR), and volume rendering (VR).

Two radiologists experienced in cardiac computed tomography evaluated the images independently without knowledge of the coronary angiograms.

The coronary segments were defined according to the American Heart Association classification¹⁶: the right coronary artery (RCA) was divided into proximal, middle, and distal parts (segments 1, 2, and 3); the posterior descending artery (PDA, segments 4 or 27) was considered arbitrarily as an independent segment because of the variability of its origin. The circumflex artery (CX) was divided into proximal and distal parts (segments 18 and 19); the left anterior descending coronary artery (LAD) was divided into proximal, middle, and distal parts (segments 12–14); the diagonal branches (DIA, segments 15, 16, and 29); obtuse marginal branches (OM, segments 20–22) and ramus intermedius (RI, segment 28) were considered as independent segments.

Data analysis

By visual estimation, readers classified the coronary arteries as evaluable or nonevaluable, depending on image quality. In the evaluable arteries the presence of significant stenosis (more than 50% diameter reduction) or complete occlusion was assessed.

In case of disagreement, a final decision was obtained by consensus.

Only vessel segments with a diameter >1.5 mm, as measured by quantitative coronary angiography, were accepted for analysis.

Conventional coronary angiography

Conventional coronary angiography (CAG) was carried out by a Philips Integris 5000 equipment (Medical Philips System (MPS), Netherlands, BV).

Angiograms were evaluated by an expert cardiologist and coronary vessel segments were classified as for MSCT.¹⁶

Quantitative coronary analysis was performed off-line by a resident MPS program using the catheter tip for calibration. Stenoses were quantified only in vessels more than 1.5 mm in diameter. A reduction in diameter of more than 50% was defined as a significant stenosis.

Statistical analysis

Conventional quantitative coronary angiography was regarded as the standard of reference.

Diagnostic accuracy of MSCT was expressed as sensitivity, specificity, negative predictive value, and positive predictive value in terms of overall accuracy and with reference to individual coronary segments.

The concordance between observers 1 and 2 for the detection of coronary lesions by MSCT was calculated by the Cohen *k*-value, according to the formula $k = (I_o - I_e) / (1 - I_e)$, where I_o is the observed concordance and I_e is the expected concordance.

Results

All patients completed MSCT without complications. Average heart rate was 59 ± 5 (range 54–74 bpm). Mean scan duration was 22 ± 2 s (19–24 s). On the basis of CAG, 43 patients had significant coronary disease (15 in 1 vessel, 15 in 2 vessels, and 13 in 3 vessels). Three patients were excluded from analysis: one due to a heart rate >70 bpm, one unable to hold breath during acquisition, and one because of failure to correctly understand breathing instructions.

Total amount of calcium, expressed as the ASE, had an average value of 260 (0–1430).

Of 729 angiographic segments estimated as more than 1.5 mm in diameter, 613 (84%) could be evaluated by MSCT. Impaired image quality of individual segments was due to severe calcification in 74 segments, cardiac motion artefacts in 29 segments, poor opacification in 9, and inability to discriminate the segment because of blending with veins in four segments.

Overall evaluability was 100% for the left main, 84% for left anterior descending artery, 82% for the circumflex, 85% for the right coronary artery, and 65% for the posterior descending artery. The evaluability was 68% for diagonal branches and 64% for marginal branches. Table 1 shows the evaluability for entire vessels and single segments. In evaluable segments, 93 stenoses were detected by angiography and 83 by MSCT; sensitivity was 89%, specificity 98%, positive predictive value 90%, and negative predictive value 98%.

Table 2 shows the accuracy of MSCT in the identification of individual lesions. Sensitivity was very high (>95%) in the proximal and middle part of the LAD and proximal RCA, and high (>85%) in the distal CX and middle part of RCA. Sensitivity was less than 70% in the distal part of LAD, diagonal branches, and distal RCA. Sensitivity was 100% in the PDA and proximal part CX, but the number of stenoses was low (only 1 in each case).

Table 1 Evaluability by MSCT of each coronary segment and entire vessel

Vessel	LM	LAD*	Prox LAD	Mid LAD	Distal LAD	Diag	Cx*	Prox Cx	Distal Cx	Marg	RI	RCA*	Prox RCA	Mid RCA	Distal RCA	PDA
Number of angiographic segments >1.5 mm	61	61	61	60	59	60	61	61	61	61	5	61	61	59	60	60
Number of segments evaluable by MSCT	61	51	60	59	51	41	50	52	50	39	4	52	53	52	52	39
Evaluability by MSCT (%)	100	84	98	98	86	68	82	85	82	64	80	85	87	88	87	65

Cx: circumflex artery; Diag: diagonal branch; LAD: left anterior descending artery; LM: left main; Marg: obtuse marginal branch; MSCT: multislice computed tomography; RCA: right coronary artery; RI: ramus intermedius; PDA: posterior descending artery; Prox: proximal.

*LAD, CX and RCA are used to indicate the entire vessel.

Table 2 Accuracy of MSCT in the detection of significant stenosis in each evaluable coronary segment and entire vessel

	LAD*	Prox LAD	Mid LAD	Distal LAD	Diag	CX*	Prox Cx	Dist Cx	Marg	RI	RCA*	Prox RCA	Mid RCA	Dist RCA	PDA
Mean diameter (mm)**		3.5	2.9	2.2	1.9		2.9	2.6	2.2	2.3		3.1	2.8	2.3	1.8
Number of angiographic stenoses in segments >1.5 mm	32	10	20	3	5	11	1	11	15	2	24	9	11	5	1
True positive	30	10	20	2	3	10	1	10	13	1	21	9	10	3	1
True negative	118	48	36	48	36	85	50	36	24	2	132	44	41	47	38
False positive	3	2	3	0	0	4	1	3	0	0	0	0	0	0	0
False negative	2	0	0	1	2	1	0	1	2	1	3	0	1	2	0
Sensitivity (%)	94	100	100	67	60	91	100	91	87	50	87	100	91	60	100
Specificity (%)	97	96	92	100	100	95	98	92	100	100	100	100	100	100	100
Positive predictive value (%)	91	83	87	100	100	71	50	77	100	100	100	100	100	100	100
Negative predictive value (%)	98	100	100	98	95	99	100	97	92	67	98	100	98	96	100

Cx: circumflex artery; Diag: diagonal branch; LAD: left anterior descending artery; Marg: obtuse marginal branch; MSCT: multislice computed tomography; RCA: right coronary artery; RI: ramus intermedius; PDA: posterior descending artery; Prox: proximal.

*LAD, CX, and RCA are used to indicate the entire vessel.

**Mean diameter is intended as average diameter of the proximal part of the segment (mm).

MSCT performed best in the detection of total vessel occlusion. In 18 instances of total occlusion, MSCT had a sensitivity of 100% and a specificity of 100%.

If all 729 angiographic segments were included in the evaluation of significant stenosis, values of diagnostic accuracy were obviously different: MSCT detected 83 of the 106 angiographic stenoses with an overall sensitivity of 78%.

The *k*-value for interobserver variation in the detection of significant coronary stenoses was 0.76.

Discussion

Assessment of significant coronary stenoses by first-generation, 4-slice MSCT has been reported with a sensitivity of 58–86% and a rate of nonevaluable arteries of up to 32%.^{1,2}

The new generation of scanners and improved reconstruction algorithms provide better spatial resolution, better temporal resolution, and a shorter scan time, permitting better image quality and reduced motion artefacts.

Ropers and Nieman,^{6,9} using a MSCT capable of acquiring 12 slices as thin as 0.75 mm, have shown that a new generation of MSCT offers relevant improvements over previous techniques in terms of evaluability and overall diagnostic accuracy. In our study we used a different scanner that permitted simultaneous acquisition of 16 slices as thin as 0.625 mm.

Sensitivity and specificity were 95% and 86% in Nieman's study, but evaluation was limited to branches more than 2 mm in diameter.⁶ In Ropers'⁹ study, in which arteries more than 1.5 mm in diameter were evaluated, sensitivity and specificity were 85% and 78%, respectively, in the detection of patients with any form of coronary artery disease, whereas accuracy in the detection of individual coronary stenoses yielded, in evaluable segments, a sensitivity and specificity of 92% and 93%, respectively.

In our study, in which arteries of more than 1.5 mm in diameter were evaluated, sensitivity was 89% with a very high specificity (98%), indicating an improved diagnostic accuracy of the method.

We do not know if this difference in specificity reflects differences in the study population or is due to a better spatial resolution of our scanner. The temporal resolution of our scanner was lower than that of the scanner used by Ropers (250 vs. 210 ms at low heart rate), but the spatial resolution was better (0.625 vs. 0.75 mm/slice thickness), which could facilitate the assessment of subcritical (<50%) stenosis. No study comparing the global performance of different scanners has yet been published.

The applicability and accuracy of 16-slice MSCT remains subject to several limitations. The presence of frequent ectopic beats or atrial fibrillation, a heart rate >70–80 bpm in spite of therapy, and inability to hold breath for the duration of scan acquisition can reduce image quality, rendering them clinically useless.

In our study the presence of severe calcifications impaired evaluability in 74 segments. It has been suggested that an Agatston Score Equivalent of more than 335 is a relative contraindication to 4-slice MSCT; "blooming artefacts" caused by hyperdense structures and the possibility of a partial volume effect can impair precise detection of the coronary lumen, making it nonevaluable.¹⁴ The availability of scanners with isotropic resolution and submillimetric slice acquisition could reduce this limitation.

The presence of severe calcification can still impair evaluability, even with a 16-slice MSCT. This may be a further limitation of the method in older patients or more extensive coronary artery disease.

In 29 coronary segments, analysis was impaired by motion artefacts. It is well known that atrial contractions in end-diastole can influence the movement of the right coronary and circumflex arteries because of their position in the atrioventricular groove; by selecting different phases of reconstruction it is usually possible to compensate for the difference in motion of the major coronary arteries.² In spite of this, 29 coronary segments in our study were judged not to be evaluable because of motion artefacts. Poor opacification or blending with veins can also impair evaluability.

Unlike CAG, MSCT cannot give any information about the flow characteristics of coronary circulation. This represents a substantial limitation if MSCT is to be used in acute coronary syndromes.

Clinical implications

Achenbach et al.¹⁷ recently evaluated MSCT for the detection and quantification of coronary plaques in patients without significant coronary stenoses for possible applications in risk stratification of asymptomatic individuals. Using intravascular ultrasound as the standard of reference, the sensitivity of MSCT in the detection of non calcified plaques was only 53%, which is inadequate for correct estimation of the plaque burden.

As far as the detection of significant stenoses on native coronary arteries is concerned, our study confirms the potential of MSCT using a new scanner capable of acquiring 16 slices as thin as 0.625 mm, but two important problems do not seem to be completely addressed. The first problem is that not all coronary segments may be fully evaluable, which is why the overall sensitivity of the method (all segments included) is reported to be 73–95% depending on the inclusion criteria and modality of analysis.^{6,9}

The second problem is that diagnostic accuracy can change depending on the diameter of the segment examined, the presence and extent of calcium deposition, poor opacification, and blending with veins.

Because of limitations in the method, MSCT cannot be considered an alternative to conventional coronary angiography, which remains the gold standard in coronary imaging.

The equipment and methods involved in MSCT are progressing rapidly and in the near future this method may well challenge the supremacy of coronary angiography in the evaluation of patients with suspected or proven coronary artery disease.

Study limitations

In our study, as in others, the coronary arteries were described by segments. This approach cannot be done as precisely for MSCT as for CAG, and its use with MSCT has not been validated; nevertheless we believe that it may be very useful for a correct understanding and interpretation of the overall diagnostic accuracy of MSCT.

Another limitation is the difference in the method of evaluation of coronary stenosis, which was based on quantitative analysis in CAG and on visual estimation in MSCT.

Our workstation Advantage Window 4.1 is equipped with software capable of automatically detecting the endoluminal coronary edge (AVA, Advanced vessel analysis), but this program has not been adequately validated for the assessment of significant coronary stenosis. Visual estimation has a subjectivity bias, with an estimated interobserver variability in this study corresponding to a k -value of 0.76.

Our study was also limited by the low number of significant stenoses in some segments, particularly the posterior descending artery, proximal circumflex, and ramus intermedius.

In terms of radiation exposure, we have no direct data on our patients, but it is known that scanners without Roentgen modulation deliver an effective dose of 8–9 mSv⁶, which is much higher than the effective dose of CAG.¹⁸ This can be a limitation if MSCT is to be used for serial assessment. Modulation of radiation by an ECG-controlled system seems to significantly reduce the effective dose.^{19,20}

Acknowledgements

Mark M. Gallagher, M.D., M.R.C.P.I., for his contribution to writing the manuscript.

References

- Achenbach S, Giesler T, Ropers T et al. Detection of coronary artery stenoses by contrast-enhanced, retrospectively electrocardiographically-gated, multislice spiral computed tomography. *Circulation* 2001;103:2535–8.
- Kopp F, Schroeder S, Kuettner A et al. Non-invasive coronary angiography with high resolution multidetector-row computed tomography. *Eur Heart J* 2002;23:1714–25.
- Nieman K, Oudkerk M, Rensing BJ et al. Coronary angiography with multi-slice computed tomography. *Lancet* 2001;357:599–603.
- Achenbach S, Ulzheimer S, Baum U et al. Non-invasive coronary angiography by retrospectively ECG-gated multislice spiral CT. *Circulation* 2000;102:2823–8.
- Becker CR, Knez A, Leber A et al. Detection of coronary artery stenoses with multislice helical CT angiography. *J Comput Assist Tomogr* 2002;26(5):750–5.
- Nieman K, Cademartiri F, Lemos PA et al. Non-invasive coronary angiography with fast submillimeter multislice spiral computed tomography. *Circulation* 2002;106:2051–4.
- Pantalone O, Palladino F, Lotito RM et al. Multirow CT angiography of coronary arteries. *Rays* 2003;28(1):13–9.
- Flohr T, Bruder H, Stierstorfer K et al. New technical developments in multislice CT, part 2: sub-millimeter 16-slice scanning and increased gantry rotation speed for cardiac imaging. *Rofo Fortschr Geb Rontgenstr Neuen Bildgeb Verfahr* 2002;174(8):1022–7.
- Ropers D, Baum U, Pohle K et al. Detection of coronary artery stenoses with thin slice multi-detector row spiral computed tomography and multiplanar reconstruction. *Circulation* 2003;107:664–6.
- Cademartiri F, Nieman K, Mollet N et al. Non-invasive 16-row spiral multislice computed tomography coronary angiography after one year of experience. *Ital Heart J* 2003;4(Suppl 7):587–93.
- Nieman K, Rensing BJ, van Geuns RJ et al. Non-invasive coronary angiography with multislice spiral computed tomography: impact of heart rate. *Heart* 2002;88(5):470–4.
- Flohr T, Prokop M, Becker C et al. A retrospectively ECG-gated multislice spiral CT scan and reconstruction technique with suppression of heart pulsation artefacts for cardio-thoracic imaging with extended volume coverage. *Eur Radiol* 2002;12(6):1497–503.
- Woodhouse CE, Janowitz WR, Viamonte Jr M. Coronary arteries: retrospective cardiac gating technique to reduce cardiac motion artefact at spiral CT. *Radiology* 1997;204(2):566–99.
- Kuettner A, Kopp AF, Schroeder S et al. Diagnostic accuracy of multidetector computed tomography coronary angiography in patients with angiographically proven coronary artery disease. *J Am Coll Cardiol* 2004;43(5):831–9.
- Agatston AS, Janowitz WR, Hildner FJ et al. Quantification of coronary artery calcium using ultrafast computed tomography. *J Am Coll Cardiol* 1990;15:827–32.
- The National Heart, Lung, and Blood Institute Coronary Artery Surgery Study (CASS). *Circulation* 1981;64 (Suppl 1):I1–I81.
- Achenbach S, Moselewski F, Ropers D et al. Detection of calcified and noncalcified coronary atherosclerotic plaque by contrast-enhanced, submillimeter multidetector spiral computed tomography. A segment-based comparison with intravascular ultrasound. *Circulation* 2004;109:14–7.
- Cusma JT, Bell MR, Wondrow A et al. Real-time measurement of radiation exposure to patients during diagnostic coronary angiography and percutaneous interventional procedures. *J Am Coll Cardiol* 1999;33(2):427–35.
- Morin RL, Gerber TC, McCollough CH. Radiation dose in computed tomography of the heart. *Circulation* 2003;107:917–22.
- Poll LW, Cohnen M, Brachten S et al. Dose reduction in multi-slice CT of the heart by use of ECG-controlled tube current modulation ("ECG pulsing"): phantom measurements. *Rofo Fortschr Geb Rontgenstr Neuen Bildge* 2002;174(12):1500–5.