Ann Thorac Cardiovasc Surg 2012; 18: 370–374 doi: 10.5761/atcs.cr.11.01730

Case Report

Multiple Cardiac Perforations Following Radiofrequency Catheter Ablation: Case Report and Literature Reviews

Peng Liu, MD, PhD, Shiyan Ren, MD, PhD, Songyi Qian, MD, and Fei Wang, MD

Introduction: Multiple cardiac ruptures after radiofrequency catheter ablation that requires surgical repair are uncommon.
Methods and Results: We describe a 64-year old male patient with paroxysmal atrial fibrillation who had a cardiac tamponade following radiofrequency ablation. Surgical exploration demonstrated two ruptures in the left atrium, one in the right atrium, and one hematoma in the right atrium. MEDLINE, the Cochrane Library, and related databases were searched up to June 2011 without language restrictions, and related literature was reviewed and discussed. The patient has survived from prompt cardiac repair of cardiac ruptures and recovered from surgery without complications.
Conclusions: Urgent exploratory surgery with cardiopulmonary bypass is the key to salvage the patient.

Keywords: cardiac perforation, catheter ablation, cardiac tamponade, radiofrequency, cardiac repair

Introduction

Radiofrequency catheter ablation (RFCA) with pulmonary vein isolation has emerged as an effective therapy for symptomatic patients with atrial fibrillation, refractory to medical therapy, from infant to adults.[1,2] Yet, it could cause some fatal complications such as cardiac tamponade that necessitates prompt diagnosis, intensive care with hemodynamic monitoring, and early aggressive management including drainage of pericardial effusion, surgical pericardiotomy, and pericardiectomy.[1,2] There are limited reports on the cardiac perforation after RFCA that requires surgical repair. Here, we report a man with two ruptures in the left atrium, one in the right atrium, and one hematoma on the right atrium following the RFCA procedure has survived after urgent cardiac surgery. The incidence and causes of cardiac complications after RFCA were studied with a review of the literature in MEDLINE, the Cochrane Library and related databases.

Cardiovascular Center, China-Japan Friendship Hospital, Beijing, China

Received: July 11, 2011; Accepted: October 18, 2011
Corresponding author: Shiyan Ren, MD, PhD. Cardiovascular Center, China-Japan Friendship Hospital, Beijing, 100039, China
Email: shiyanr@yahoo.com

Case Report

A 64-year-old man presented with a 3-year history of paroxysmal palpitations with progressive worsening for three months and a 20-year history of hypertension with poor medical control. In the recent three months prior to admission, he had experienced frequent episodes of atrial fibrillation despite the use of antiarrhythmic agents, such as amidarone. His admission diagnosis included hypertension, atrial fibrillation, hyperlipidemia and chronic gastritis. He underwent RFCA for his atrial fibrillation. A standard 6F pigtail catheter was placed into the femoral vein; an intracardiac echocardiography catheter was advanced via an 11 French sheath to the right atrium, to visualize the interatrial septum, left atrium and pulmonary

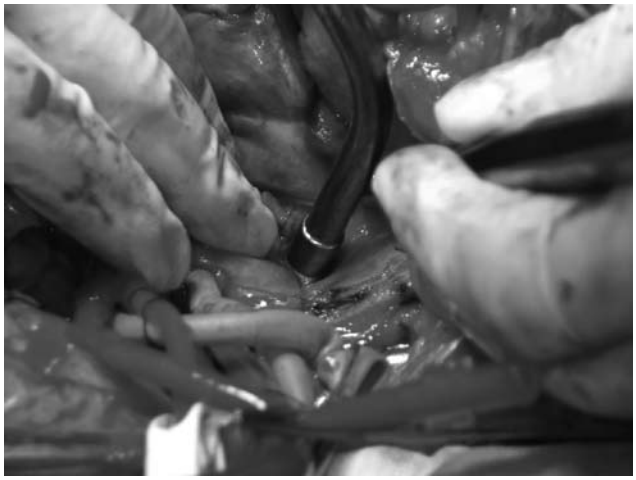

Fig. 1 Cardiac perforation in the left atrial appendage (5 mm in diameter), the aspirator is on the exact site of cardiac perforation to control the massive hemorrhage.

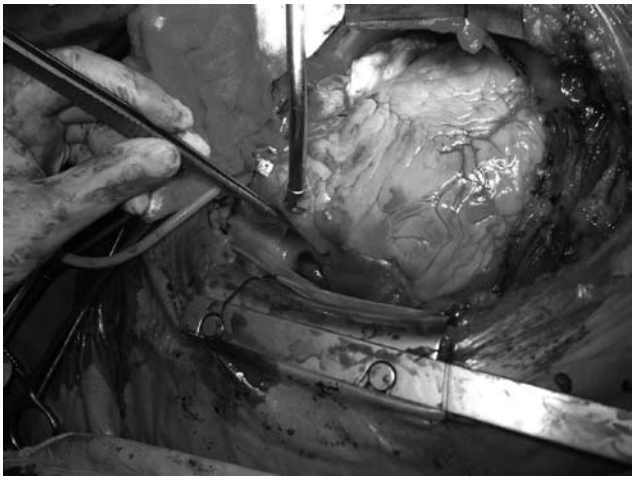

Fig. 2 Cardiac perforation 1 cm in diameter on the right atrium near the root of ascending aorta.

veins. Heparin (10000 units) was administered intravenously, and the target of the activated clotting time, >350s, was then maintained by adjusting the dose of heparin. After administration of heparin, a double transseptal puncture with a conventional Brockenbrough needle was achieved for left heart catheterization, under fluoroscopic and ICE guidance. Mapping of pulmonary veins was performed with a circumferential mapping catheter. Cardiograph showed a normal shape of left and right pulmonary veins and left atrium with no structural heart disease. The electrophysiological study revealed that the atrial arrhythmias were due to the focus, firing irregularly and exhibiting a consistent and centrifugal pattern of activation. The atrial fibrillation was associated with runs of irregular atrial tachycardia or monomorphic extrasystoles. Pulmonary veins (PV) were isolated with circumferential linear radiofrequency ablation guided by a carto dimensional mapping system. The Carto guided wide circumferential ablation was achieved around PVs from the ostium of the right pulmonary veins in the left atrium and the ostium of the left superior pulmonary vein. After preferential, PV-left atrium (LA) electric inputs were defined, RFCA was performed until complete isolation of the PVs from the LA was achieved. The procedure lasted four hours, and the patient was returned to the ward with the hemodynamically stable conditions.

Thirty minutes after RFCA, the patient suddenly felt nausea, sweating, acute distress, then chest pain, agitation and urine incontinence. Physical examination revealed distant heart sounds, BP 80/50 mmHg and HR 105 mbp. Ultrasonography demonstrated cardiac tamponade, and pericardiocentesis was performed immediately while dopamine (300 mg) and atropine (0. 5 mg) were administered intravenously for homodynamic stabilization. A total of 800 ml of uncoagulated blood was aspirated from the cardiac sac, and an urgent exploratory thoracotomy was arranged without delay.

A median sternotomy was performed under general anesthesia. Approximately 200 ml of blood with clot was evacuated from the cardiac sac. Then, active bleeding from a rupture (5 mm in diameter) on the left atrial appendage was noted (**Fig. 1**), and the rupture was closed. Meanwhile, a second perforation in the left atrium dome, above the left atrial-ventricular sulcus, was noted to have fulminant bleeding. Because the bleeding was too overwhelming to be controlled, a cardiopulmonary bypass (CPB), with annulations to the ascending aorta and both superior and inferior vena cava, was established. Following cardioplegia, this perforation (1 cm in diameter) was closed with three stitches using 3/0 prolene; and the third perforation, 1cm in diameter, was found to be located on the right atrium near the root of the ascending aorta (**Fig. 2**); it was closed with two stitches using 3/0 prolene. In addition, a hematoma (3 cm × 4 cm) on the junction of a superior vena cava with the right atrium was found. After hemostasis with no active bleeding was ensured, the heart was resuscitated with 30 joules thrice, and the patent was weaned from CPB with an inotropic support and respirator. The bypass time was 40 minutes. During the operation, 1500 ml blood was lost, and 1200 ml blood was transfused.

Table 1 Incidence of pericaridal effusion, cardiac tamponade, cardiac rupture and surgical repair of cardiac rupture after radiofrequency ablation

Authors	Cardiac rupture	Surgical repair of cardiac rupture	Cardiac tamponade	Mild to moderate PE	Incidence of total PE	Overall complications
Chierchia	-	-	1.5% (2/133)	12.78% (17/133)	14.2% (19/133)	
Bunch TJ	2.4% (15/632)	0.32% (2/632)	-	-	-	-
Schaer BA	-	-	-	3.2% (16/510)	-	-
Abhishek F	-	-	0.62% (1/162)	0.625 (1/162)	-	-
Chen SW	-	-	-	10.3% (16/156)	-	-
Huang XM	-	0.05% (1/1832)	0.55% (10/1832)	-	-	-
Hoffmann	-	-	-	0.3%–0.8%	-	-
Bertaglia E			0.6 (6/1011)	0.8 (8/1011)	-	3.9% (40/1011)
Deisenhofer	-	-	-	5.3% (4/75)	-	22% (17/75)
Hahn G	2.2% (1/46)	-	-	-	-	2.2% (1/46)
Borger V	-	-	-	-	2% (3/151)	7.2% (11/151)
BorgerVrete M	-	-	-	-	-	29.1% (7/24)
Hsu LF	-	-	2.9% (10/ 348)	-	-	-

PE denotes pericardial effusion.

Table 2 Hospital mortality rate and long-term mortality rate of patients after radiofrequency catheter ablation

Authors	Hospital Death		Patients	Long-term Death		Patients
	mortality	n	n	mortality	n	n
Borger V	2.0%	3	151			
Mansourati J	4.40%	4	91	12%	11	91
Borger M	4.20%					
NICE	0.1%–0.2%*	1	24			
Klein A		1				

NICE denotes National Institute for health and Clinical Excellence.
Mortality of all complication after radiofrequency ablation

Results

After surgery, the patient was transferred to the ICU and ventilated, and he was weaned from the respirator on day 2 postoperatively. On day 11 after surgery, the chest radiograph showed pneumonia, and the white-cell count was 25.4×10^9/L, with 91.6 percent neutrophils. Cardiac effusion and frequent atrial fibrillation were shown on echocardiography and ECG. Cardiocentesis was performed, and antibiotics were administered empirically. Since then, his postoperative recovery was uneventful. He had been well on 5-month postoperative follow up.

Discussion

Radiofrequency catheter ablation (RFCA) is the treatment of choice for symptomatic patients with atrial fibrillation, unresponsive to medical treatment. It has been reported to be a safe and efficient procedure in appropriately selected patients.[3,4] However, because the complex technique requires trans-septal puncture or extensive manipulation in the thin walled left atrium some complications may happen (**Tables 1** and **2**). The overall complication rate after RFCA has been reported from 3.9% to 22%.[5] Major complications occur in 3.9% of patients who have RFCA procedures,[5] including thromboembolism in less than 1% and mortality in 0.1%–0.2% of all patients undergoing RFCA procedures.[6] The incidence of cardiac complications varies with the site and type of ablation.[6,7] Different authors have varied definitions of cardiac effusion. The incidence of total cardiac effusion from asymptomatic to cardiac tamponade requiring surgery is 14.2% (19/133).[1] The incidence of mild to moderate pericardiac effusion requiring no pericardiocentesis has been reported from 0.3% to 12.78% (**Table 1**). Cardiac tamponade after RFCA is reported from 0.1% up to 6%.[5,6,8] Vascular complications occur in approximately 2% to 4% of procedures, including retroperitoneal bleeding,

hematoma, vascular injury, transient ischemic attack and hypotension. Left atrial-esophageal fistula is an extremely fatal complication.[6)]

Cardiac perforation requiring surgery is a rare but fatal complication in RFCA for atrial fibrillation, and the incidence of cardiac perforation requiring surgery is reported from 0.05% to 0.32%.[2,9)] Until now, reports on the incidence and surgical repair of cardiac perforation have been scant. Cardiac perforation of the left atrium that led to pericardial effusion and cardiac tamponade was reported by Hahn et al in 1995.[10)] Cardiac rupture on the left ventricle after RFCA, requiring surgical repair was reported by Kino in 2005; the rupture was reported as starting from a small leak through the friable myocardium and gradually causing a blowing-out rupture.[11)] Puncture of the interatrial septum may cause perforation in the left atrium, coronary sinus, and root of the ascending aorta. In our patient, two perforations in the left atrium, one in the right atrium, and hematoma in the right atrium were found; this has rarely been reported in the literature. On mapping and ablation of left pulmonary veins, once the catheter has entered the left atrium appendage, further advancing of catheter might cause perforation of the left atrium appendages. In addition, the ablation catheter was filled with cold saline on ablation of cardiac tissue, and when energy was released in the coronary vein, explorative pressure might induce the cardiac rupture. Lower power and less time of ablation may reduce the risk of perforation. The pericardial effusion and myocardial ischemic events mainly occurred during RFCA using a retrograde aortic approach.[2)]

The mortality rate is high unless the cardiac rupture after RFCA is managed promptly. Until now, it has been reported that at least 20 patients have died after RFCA (**Table 2**). The RFCA procedure-related hospital mortality rate has been reported from 2% (3/151) to 4.2% (1/24).[12)] It was reported that one patient died from a rupture of the cardiac wall in the hospital; another two patients died at 2 and 21 months after RFCA, respectively.[13)] Mansourati et al. retrospectively reviewed 91 patients undergoing RFCA procedures, and the hospital mortality was 4.4% (4/91), whereas, the long-term mortality rate was 12% (11/91). Eight of 11 patients died from cardiac causes during a period of follow-up (14.5 ± 8.6 months).[14)] In addition, a 79-year old man died 3.5 hours after RFCA for atrial fibrillation due to tamponade. The autopsy and consecutive microscopic examination demonstrated electrothermical necroses topographically and adjacent to pulmonary veins in the left atrium and area of isthmus in the right atrium with rupture of the right atrium wall.[15)]

In this case, radiofrequency transseptal puncture was unsuccessful at the first attempt, the procedure had been performed for four hours, and an echocardiography was not performed during the RFCA procedure. All these unfavorable factors might be associated with risk of cardiac perforations and unprompted diagnosis. The intracardiac echocardiography offers a detailed visualization of the cardiac structures, in association with hemodynamic information. It can provide anatomic data on the left atrium and pulmonary veins, help in transseptal punctures, locate the ostium and antrum of the pulmonary veins, monitor tissue injury during radiofrequency use, and prevent esophageal injury.[16)] A reduction in the excursion of the cardiac silhouette on fluoroscopy has been reported as an early diagnostic sign of cardiac tamponade during RFCA.[9)]

The suspected reason of perforation in patients, based on surgical findings, might be due to inexperienced catheter manipulation before and after the transseptal access. The incidence of complications would be acceptably less or avoidable when it was performed by experienced personnel in an appropriately staffed and equipped surgical facility.[9)]

Delicate skills and meticulous maneuvers in the RFCA procedure are critical in reducing the risk of complications. Approaches for the early diagnosis of the cardiac tamponade include careful monitoring of the cardiac silhouette on fluoroscopy, utilization of real time intracardiac echocardiography with 2D and Doppler color flow imaging, and 3D electroanatomic mapping systems for better visualization of intracardiac structures.[16–18)]

New developments in the field of catheter ablation are likely to reduce the risk of perforation.[16–18)] Remote-controlled robotic catheter ablation using magnetic navigation (RMN), in conjunction with the electroanatomical mapping system, proved to be a valuable tool for performing a successful ablation.[19)] Compared to manual catheter navigation, catheter ablation, using irrigated tip magnetic catheter and the incorporation of contact pressure sensors into the catheter tips, is an effective and safe method for catheter ablation of AF. In addition, catheter irrigation alone without RF delivery reduced intramyocardial temperatures up to 4.9 , and the horizontal orientation produced a 2-fold greater area of tissue cooling than did the vertical orientation thereby reducing lesion volumes for irrigated RF catheters.[20)]

In our patient, fatal complications, such as multiple cardiac ruptures in radiofrequency catheter ablation,

might be prevented by careful maneuver during the procedure and earlier discovery by monitoring cardiac silhouette on fluoroscopy, the intracardiac echocardiography and postprocedural electrophysiological testing.

A high index of suspicion is required for the early diagnosis and treatment of cardiac tamponade. Once the diagnosis of cardiac tamponade is made, a pericardiocentesis should be performed immediately. Urgent cardiac surgery is indicated if hemodynamic instability still exists after pericardiocentesis. Cardiopulmonary bypass should be employed in cases of severe bleeding, or when hemorrhage is difficult to control, as was in our case.

Acknowledgement

We thank Dr. Yifeng Zhou for providing the surgical photographs.

References

1) Benito F, Sanchez C. Radiofrequency catheter ablation of accessory pathways in infants. Heart 1997; **78**: 160-2.
2) Belhassen B, Rogowski O, Glick A, et al. Radiofrequency ablation of accessory pathways: a 14 year experience at the Tel Aviv Medical Center in 508 patients. Isr Med Assoc J 2007; **9**: 265-70.
3) Chierchia GB, Capulzini L, Droogmans S, et al. Pericardial effusion in atrial fibrillation ablation: a comparison between cryoballoon and radiofrequency pulmonary vein isolation. Europace 2010; **12**: 337-41. Epub 2010 Jan 6.
4) Bunch TJ, Asirvatham SJ, Friedman PA, et al. Outcomes after cardiac perforation during radiofrequency ablation of the atrium. J Cardiovasc Electrophysiol 2005; **16**: 1172-9.
5) Schaer BA, Maurer A, Sticherling C, et al. Routine echocardiography after radiofrequency ablation: to flog a dead horse? Europace 2009; **11**: 155-7. Epub 2008 Dec 24.
6) Abhishek F, Heist EK, Barrett C, et al. Effectiveness of a strategy to reduce major vascular complications from catheter ablation of atrial fibrillation. J Interv Card Electrophysiol 2011; **30**: 211-5. doi: 10.1007/s10840-010-9539-8. Epub 2011 Feb 19.
7) Bertaglia E, Zoppo F, Tondo C, et al. Early complications of pulmonary vein catheter ablation for atrial fibrillation: a multicenter prospective registry on procedural safety. Heart Rhythm 2007; **4**: 1265-71. Epub 2007 Jun 21.
8) NICE. Percutaneous radiofrequency catheter ablation for atrial fibrillation. http://ukpmc.ac.uk/guidelines/HIR/125245 2011.
9) Deisenhofer I, Schneider MA, B?¶hlen-Knauf M, et al. Circumferential mapping and electric isolation of pulmonary veins in patients with atrial fibrillation. Am J Cardiol 2003; **91**: 159-63.
10) Hsu LF, Jais P, Hocini M, et al. Incidence and prevention of cardiac tamponade complicating ablation for atrial fibrillation. Pacing Clin Electrophysiol 2005; **28** Suppl 1: S106-9.
11) Huang XM, Hu JQ, Zhou F, et al. Early diagnosis and rescue pericardiocentesis for acute cardiac tamponade during radiofrequency ablation for arrhythmias. Is fluoroscopy enough? Pacing Clin Electrophysiol 2011; **34**: 9-14. doi: 10.1111/j.1540-8159.2010.02938.x. Epub 2010 Oct 28.
12) Hahn K, Gal R, Sarnoski J, et al. Transesophageal echocardiographically guided atrial transseptal catheterization in patients with normal-sized atria: incidence of complications. Clin Cardiol 1995; **18**: 217-20.
13) Kono T, Kitahara H, Sakaguchi M, et al. Cardiac rupture after catheter ablation procedure. Ann Thorac Surg 2005; **80**: 326-7.
14) Borger van der Burg AE, de Groot NM, van Erven L, et al. Long-term follow-up after radiofrequency catheter ablation of ventricular tachycardia: a successful approach? J Cardiovasc Electrophysiol 2002; **13**: 417-23.
15) Borggrefe M, Breithardt G, Podczeck A, et al. Catheter ablation of ventricular tachycardia using defibrillator pulses: electrophysiological findings and long-term results. Eur Heart J 1989; **10**: 591-601.
16) Mansourati J, Deharo JC, Graux P, et al. [Short and medium-term outcome after radiofrequency ablation of the atrioventricular junction]. Arch Mal Coeur Vaiss 1997; **90**: 945-51.
17) Klein A, Tsokos M, Puschel K. Atrial myocardial perforation due to catheter ablation of the cavotricuspid isthmus. Herzschrittmacherther Elektrophysiol 2006; **17**: 133-6.
18) Chen SA, Chiang CE, Tai CT, et al. Complications of diagnostic electrophysiologic studies and radiofrequency catheter ablation in patients with tachyarrhythmias: an eight-year survey of 3,966 consecutive procedures in a tertiary referral center. Am J Cardiol 1996; **77**: 41-6.
19) Ernst S, Chun JK, Koektuerk B, et al. Magnetic navigation and catheter ablation of right atrial ectopic tachycardia in the presence of a hemi-azygos continuation: a magnetic navigation case using 3D electroanatomical mapping. J Cardiovasc Electrophysiol. 2009; **20**: 99-102.
20) Wood MA, Goldberg SM, Parvez B, et al. Effect of electrode orientation on lesion sizes produced by irrigated radiofrequency ablation catheters. J Cardiovasc Electrophysiol 2009; **20**: 1262-8. Epub 2009 Jun 30.