

Seven nipples in a male: World's second case report

Tarang Goyal, S. K. Bakshi¹, Anupam Varshney²

Departments of Dermatology Leprology Venereology, ¹Medicine and ²Pathology, Muzaffarnagar Medical College and Hospital, Muzaffarnagar, Uttar Pradesh, India

We present a case of seven nipples in a 32-year-old male patient. The patient had two regular nipples along with five supernumerary nipples. Usually, supernumerary nipples develop along the two vertical "milk lines" which start in the arm pit on each side, run down through the typical nipples, and end at the groin. Our patient had six nipples which confirm to the "milk lines" and one nipple which was above the umbilicus in the midline and did not confirm to the "milk lines." To our knowledge, this is the second case report with seven nipples in the world.

Key words: Accessory nipples, kajava classification, milk lines, seven nipples, supernumerary nipples

least partially to differences in geographic regions, ethnic groups, and methodology, including methods of physical examination, as well as the age groups participating in the studies. The male-to-female ratio for supernumerary nipples differs in various studies, but, most often, the studies show a male predominance as high as 1.7:1. Usually, the supernumerary nipple remains undetected or asymptomatic. Occasionally, the supernumerary nipple is noticed only when hormonal changes during adolescence, menstruation, or pregnancy cause increased pigmentation, fluctuating swelling, tenderness, or even lactation.

Introduction

The first medical report of supernumerary nipples dates back to 1878 by Leichtenstern.^[1] Supernumerary nipples is listed as a "rare disease" by the Office of Rare Diseases (ORD) of the National Institutes of Health (NIH). This means that Supernumerary nipples, or a subtype of Supernumerary nipples, affect less than 200 000 people in the US population.^[2] The prevalence of supernumerary nipples varies with different reports. The prevalence is 0.22% in a Hungarian population,^[3] 1.63% in black American neonates,^[4] 2.5% in Israeli neonates,^[5] 4.7% in Israeli Arabic children,^[6] and 5.6% in German children.^[7] These variabilities are attributed at

Case Report

A 32-year-old male patient came to dermatology OPD with complaints of discoloration of chest and abdomen at five places. General physical examination of the patient revealed seven nipples in total, four over anterior chest wall (including two regular nipples) and three over abdomen. The patient was evaluated clinically for central nervous system (epilepsy, migraine, neurosis, intracranial aneurysm, neural tube defect, and developmental delay), gastrointestinal system (peptic ulcer, pyloric stenosis), ENT (laryngeal web, ear abnormalities), respiratory system (accessory lobe), skeletal system (hand malformation, vertebral anomaly, absence of rib, coronal suture synostosis, hemihypertrophy, arthrogryposis, scalp defects, and microcephaly), and cardiovascular system (essential hypertension, conduction defect, bundle-branch block, patent ductus arteriosus, congenital heart disease, mitral valve prolapse, atrial septal defect, and ventricular septal defect).

These findings are reported to be associated with supernumerary nipples in the literature and none

Access this article online

Quick Response Code:



Website:

www.ijhg.com

DOI:

10.4103/0971-6866.108051

of them were present in our patient. The laboratory investigations were normal. Dermoscopic examination of supernumerary nipple shows a pattern similar to dermatofibroma, with both showing central, white, scar-like areas and a peripheral fine-pigment network. Supernumerary nipple also has a cleft-like appearance in the central area, thus allowing differentiation from dermatofibroma.^[8]

The histologic features of a supernumerary nipple was identical to that of the regular nipple, including hyperpigmentation, slight hyperkeratosis with epidermal thickening, pilosebaceous structure of Montgomery areolar tubercles, smooth muscle bundles typical of the areola, and possible mammary glands and intradermal straight ducts.^[9]

Discussion

The classification established by Kajava^[10] divides the total cases of supernumerary into the following eight different types:

- Complete supernumerary nipple-Nipple, areola, and glandular breast tissue
- Supernumerary nipple-Nipple and glandular tissue (no areola)
- Supernumerary nipple-Areola and glandular tissue (no nipple)
- Aberrant glandular tissue only
- Supernumerary nipple-Nipple and areola and pseudomamma (fat tissue that replaces the glandular tissue)
- Supernumerary nipple-Nipple only (the most common supernumerary nipple)
- Supernumerary nipple-Areola only (polythelia areolaris)
- Patch of hair only (polythelia pilosa)

Although this classification is clear, encountering interchangeable terms and misnomers when dealing with the supernumerary nipple complex is not surprising because of the variability in morphologic patterns. Our case was unique because of combination of nipple and areola at as shown in Figure 1.

Approximately 5% of supernumerary nipples are ectopic, located outside of the milk line, such as on the

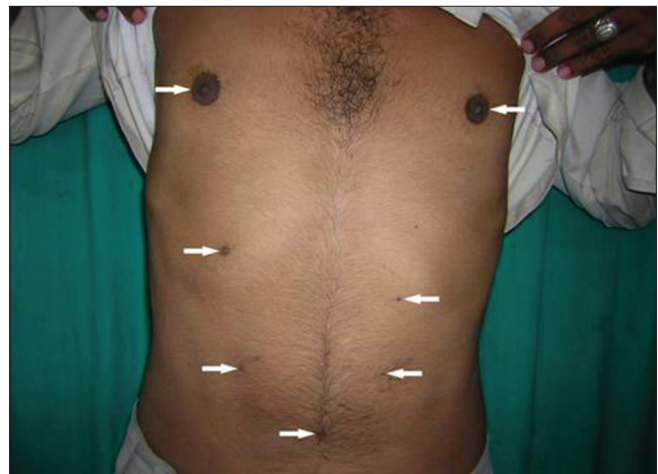


Figure 1: The patient with two regular and five supernumerary nipples

back,^[11] the shoulder,^[12] the limbs, the neck, the face, and the vulva and perineum. Most supernumerary nipples are single, and, when two or more supernumerary nipples are present, they are distributed bilaterally or unilaterally, symmetrically or asymmetrically. Most supernumerary nipples are located below the regular nipple, while approximately 13% appear above it along the milk line. A protruding (or erectile) supernumerary nipple that causes the patient embarrassment can be easily removed surgically, if desired. Removal using liquid nitrogen cryotherapy has been described.^[13] The removal of polymastia or a complete ectopic supernumerary nipple (with breast) is more involved but is indicated in women at high risk of developing breast cancer.^[14] To avoid an unsightly scar after the removal of a complete ectopic supernumerary nipple, the tumescent liposuction technique has been suggested.^[15]

Stephen Detsch of New Hampshire has a world-record of five nipples on his chest and two more in development. The nipples have been confirmed by his primary care physician.^[16] Our patient has seven nipples in total, all of them well-seen and developed and thus constitutes the second case report worldwide for maximum number of nipples in a male.

References

1. Leichtenstern D. Über das Vorkommen und Bedeutung Supernumerärer (accessorischer) Bruste und Brustwarzen. Arch Pathol Anat Physiol Klin Med 1878;73:222.
2. Available from: <http://rarediseases.info.nih.gov/Resources/>

- Rare_Diseases_Information.aspx. [Last accessed on 2011 May 16].
3. Mehes K. Association of supernumerary nipples with other anomalies. *J Pediatr* 1979;95:274-5.
 4. Rahbar F. Clinical significance of supernumerary nipples in black neonates. *Clin Pediatr (Phila)* 1982;21:46-7.
 5. Mimouni F, Merlob P, Reisner SH. Occurrence of supernumerary nipples in newborns. *Am J Dis Child* 1983;137:952-3.
 6. Jaber L, Merlob P. The prevalence of supernumerary nipples in Arab infants and children. *Eur J Pediatr* 1988;147:443.
 7. Schmidt H. Supernumerary nipples: Prevalence, size, sex and side predilection: A prospective clinical study. *Eur J Pediatr* 1998;157:821-3.
 8. Oztas MO, Gurer MA. Dermoscopic features of accessory nipples. *Int J Dermatol* 2007;46:1067-8.
 9. Shewmake SW, Izuno GT. Supernumerary areolae. *Arch Dermatol* 1977;113:823-5.
 10. Kajava Y. The proportions of supernumerary nipples in the Finnish population. *Duodecim* 1915;1:143-70.
 11. Hanson E, Segovia J. Dorsal supernumerary breast: Case report. *Plast Reconstr Surg* 1978;61:441-5.
 12. Schewach-Millet M, Fisher BK. Supernumerary nipple on the shoulder. *Cutis* 1976;17:384-5.
 13. Mimouni F, Merlob P, Reisner SH. Occurrence of supernumerary nipples in newborns. *Am J Dis Child* 1983;137:952-3.
 14. Madej B, Balak B, Winkler I, Burdan F. Cancer of the accessory breast: A case report. *Adv Med Sci* 2009;54:308-10.
 15. Fan J. Removal of accessory breasts: A novel tumescent liposuction approach. *Aesthetic Plast Surg* 2009;33:809-13.
 16. Available from: <http://www.chacha.com/askChaCha/session/7b317f51-276c-4163-b85d-ca05b7c7b0f8>. [Last Accessed on 2011 May 15].

Cite this article as: Goyal T, Bakshi SK, Varshney A. Seven nipples in a male: World's second case report. *Indian J Hum Genet* 2012;18:373-5.

Source of Support: Nil, **Conflict of Interest:** None declared.

