

*Original article*

## Beneficial Effects of Green Tea Extract in Gentamicin-Induced Acute Renal Failure in Rats

Milica Veljković<sup>1</sup>, Sonja Ilić<sup>1</sup>, Nenad Stojiljković<sup>1</sup>, Ljubinka Velicković<sup>2</sup>, Dragana Pavlović<sup>3</sup>,  
Mirjana Radenković<sup>1</sup>, Suzana Branković<sup>1</sup>, Dusanka Kitić<sup>3</sup>, Marija Gocmanac Ignjatović<sup>1</sup>

<sup>1</sup>University of Niš, Faculty of Medicine, Institute of Physiology, Serbia

<sup>2</sup>University of Niš, Faculty of Medicine, Institute of Pathology, Serbia

<sup>3</sup>University of Niš, Faculty of Medicine, Department of Pharmacognosy, Serbia

---

### SUMMARY

The aim of this study was to investigate whether green tea extract has beneficial effect on gentamicin-induced acute renal failure. The investigation was conducted on thirty-two Wistar rats divided into four groups of 8 animals each. Control (C) group received normal saline. GT group received green tea extract orally, 300mg/kg. GM group received gentamicin intraperitoneally, 100mg/kg and GT+GM group received both gentamicin and green tea extract.

Histological sections of kidney in GM group revealed necrosis of proximal tubules, vacuolization of cytoplasm and massive mononuclear inflammatory infiltrates in interstitium. Coadministration of green tea with gentamicin had renoprotective effect and showed only mild infiltrations, normal glomeruli and alleviated tubular degeneration. Analysis of biochemical parameters showed significantly higher urea and creatinine serum concentrations in GM group in comparison with C group and GT+GM group ( $p<0.001$ ). Plasma lipid peroxidation biomarker MDA was significantly higher in GM group than those in C group ( $p<0.001$ ), whereas the values for GT+GM group were significantly lower than MDA recorded for GM group ( $p<0.001$ ).

Beneficial effects of green tea on gentamicin-induced nephrotoxicity is explained through decrease of oxidative stress and lipid peroxidation. Our results indicate that green tea administration has nephroprotective effect on oxidative stress and acute renal failure caused by gentamicin.

**Key words:** gentamicin, green tea, extract, rats

Corresponding author:

Milica Veljković

phone: +381641939374

e-mail: milica.veljkovic@gmail.com

## INTRODUCTION

Gentamicin is a widely used aminoglycoside antibiotic with a low price and high effectivity in treatment of gram-negative and  $\beta$ -lactam resistant infections (1). However, its use has been limited because of its adverse effect of causing nephrotoxicity (2). Gentamicin-induced nephrotoxicity is an animal model for study of acute kidney failure in experimental research (3). Although the mechanism by which gentamicin causes nephrotoxicity remains unclear, proposed pathological mechanisms include induction of oxidative stress, apoptosis, necrosis, elevation of endothelin I and increase of monocyte/macrophages infiltration (3–5). Gentamicin-induced nephrotoxicity is clinically characterized by increased serum creatinine and blood urea nitrogen and decreased glomerular filtration rate (2,3) and morphologically by focal necrosis and apoptosis in tubular epithelium with extensive peritubular cell inflammation (2). Gentamicin increases generation of reactive oxygen species (ROS), such as super oxide anions (6), hydroxyl radicals, hydrogen peroxide and reactive nitrogen species in the kidney (3).

Most research studies on gentamicin-induced nephrotoxicity are focused on the use of various anti-oxidants (3). Green tea (*Camellia Sinensis*) contains the highest concentration of powerful antioxidants called polyphenols also known as green tea catechins (7). The important catechins contents of green tea are epicatechin, epicatechin-3-gallate, epigallocatechin and epigallocatechin-3-gallate (7,8). These polyphenols in green tea can neutralize free radicals and may reduce some of the damage caused by reactive oxygen species (ROS) (7). In this study, we aimed to evaluate green tea extract (GTE) as an inhibitory agent against gentamicin-induced acute renal failure because of its antioxidant property.

## MATERIALS AND METHODS

### Preparation of Ethanolic Green Tea extract (GTE)

Green tea leaves were reduced to a fine powder with ethanol (70% v/v) by percolation, as described in European Pharmacopeia 6.0 (Ph. Eur. 5, 2007). The ethanolic extract of *Camellia Sinensis* (commercial

sample from "Josif Pancic", Pancevo, Serbia) were obtained after evaporation to the dryness in vacuo under 40°C and extraction yield was 25%. Chemicals, reagents and solvents used in the experiment were of analytical grade.

### Animals

Thirty-two Wistar albino rats, weighing 200 – 250g, were selected for this study. The control group of rats (C group) received 1 ml saline solution per day intraperitoneally for 8 days. The green tea (GT) group received an oral administration of 300 mg/kg/day of green tea for 15 days using an intragastric enteral feeding protocol (1). The gentamicin (GM) group was injected subcutaneously with gentamicin (Actavis company, Leskovac, Serbia) 100 mg/kg/day for the last 8 days of experiment. The green tea and gentamicin group (GT+GM) group was treated orally with green tea 300 mg/kg/day for 15 days concomitantly with intraperitoneal injection of gentamicin, in the same dose like GM group, for the last 8 days of experiment. Fifteen days after the beginning of the experiment all animals were anaesthetized using 80 mg/kg ketamine (Ketamidol 10%, Richter Pharma AG, Wels, Austria) and sacrificed. Blood samples for biochemical analysis were taken from the aorta (2ml). The kidney was subsequently removed and cut into two pieces for biochemical analysis and light microscopy. All experimental procedures were conducted in accordance with the principles for the care and use of laboratory animals for scientific purposes contained in the European Union regulations and USA Guide for the Care and Use of Laboratory Animals.

### Histological analysis

After the kidneys were dissected, tissues were fixed in 10% paraformaldehyde (2), dehydrated in ascending graded series of alcohol and embedded in paraffin. Kidney tissues were cut into pieces of 5  $\mu$ m thickness using a HistoRange microtome (model: LKB 2218, LKB-Produkter AB, Bromma, Sweden) followed by staining with hematoxylin and eosin (HE) according to conventional staining protocols. The histological sections were examined under a light microscope Leica DMR (Leica Microsystems AG, Wetzlar, Germany)

### Biochemical analysis

Blood samples taken from the aorta were analyzed for markers of renal failure. Urea and creatinine concentrations in serum were measured using an automatic biochemical analyzer (A25 Biosystems, Barcelona, Spain) in the laboratory of the Clinic of Nephrology Clinical Center Niš.

### Estimation of lipid peroxidation

Serum malondialdehyde as a marker of lipid peroxidation was assessed by thiobarbitoric acid test, (3) spectrophotometrically. Homogenate absorption was measured at 532 nm. The malondialdehyde / lipid peroxidation end-product concentration was expressed per mg/protein using the molecular extinction coefficient of MDA ( $1.56 \times 10^{-5} \text{ mol cm}^{-1}$ ).

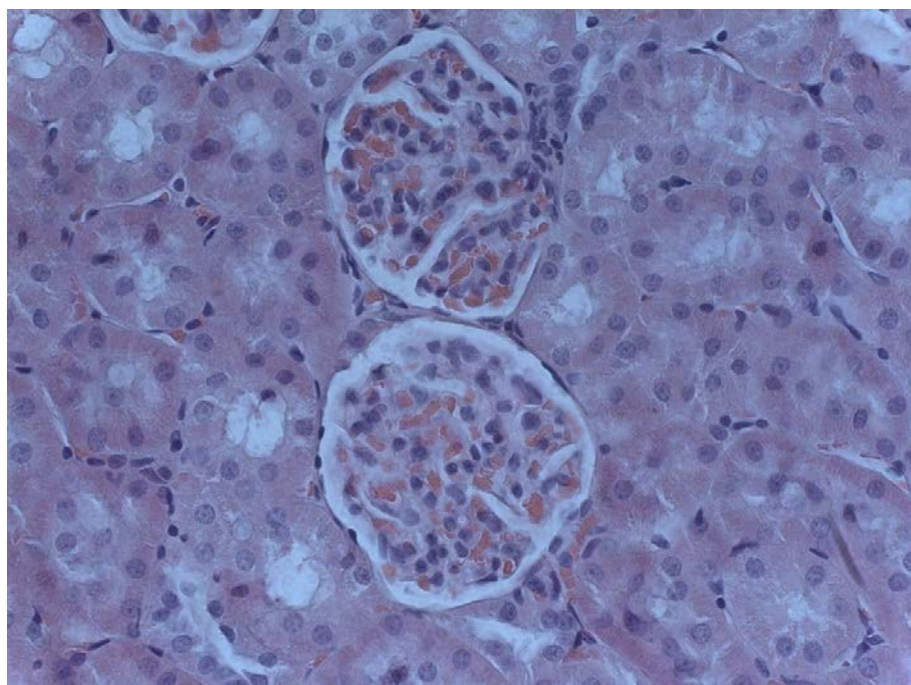
### Statistical analysis

All values are expressed as mean  $\pm$  SD. All data were compared between groups by one-way analysis of variance (ANOVA) followed by Tukey's post hoc test for multiple comparison (Graphpad Prism version 5.03, San Diego, CA, USA). The value less than 0.05 was considered significant.

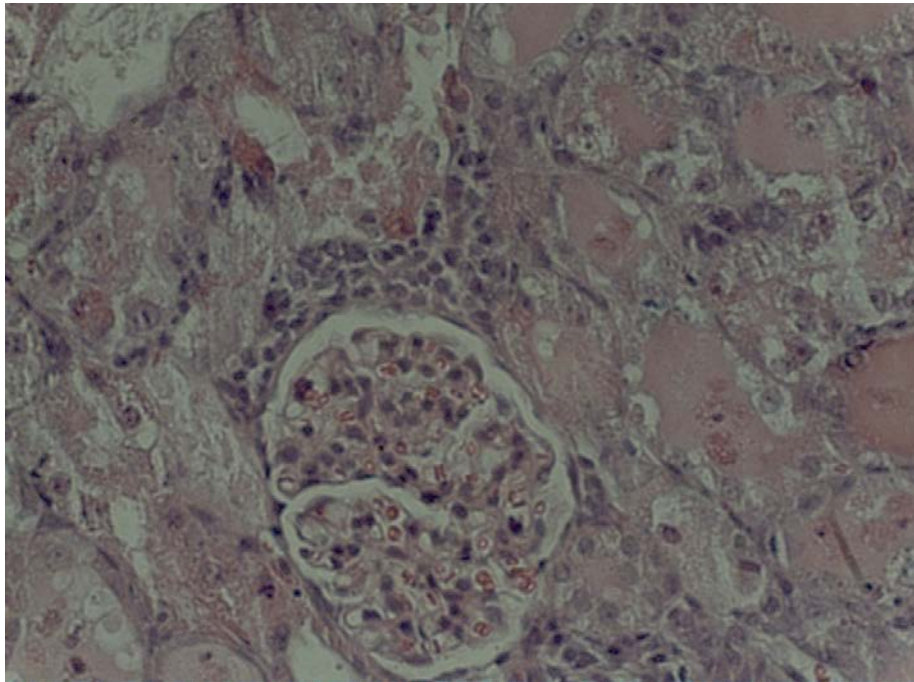
## RESULTS

### Histological analysis

Sections from control (C) group (Figure 1) shows normal histological structure of the glomeruli and renal tubules (7). In GM group (Figure 2) renal sections showed glomerular congestion, narrowed Bowman's space, periglomerular inflammation and hyaline cylinders. Proximal tubules were undergoing necrosis, vacuolization of cytoplasm and epithelial desquamation. Interstitium showed massive mononuclear inflammatory infiltrates.



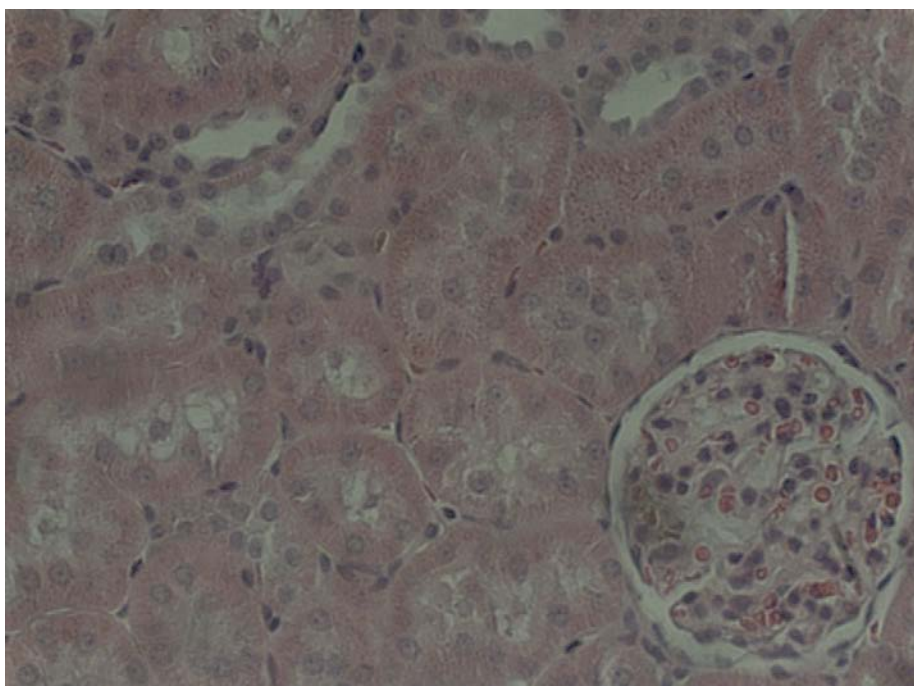
**Figure 1:** *Histopathological view of renal sections of C group of rats (HE x 200)*



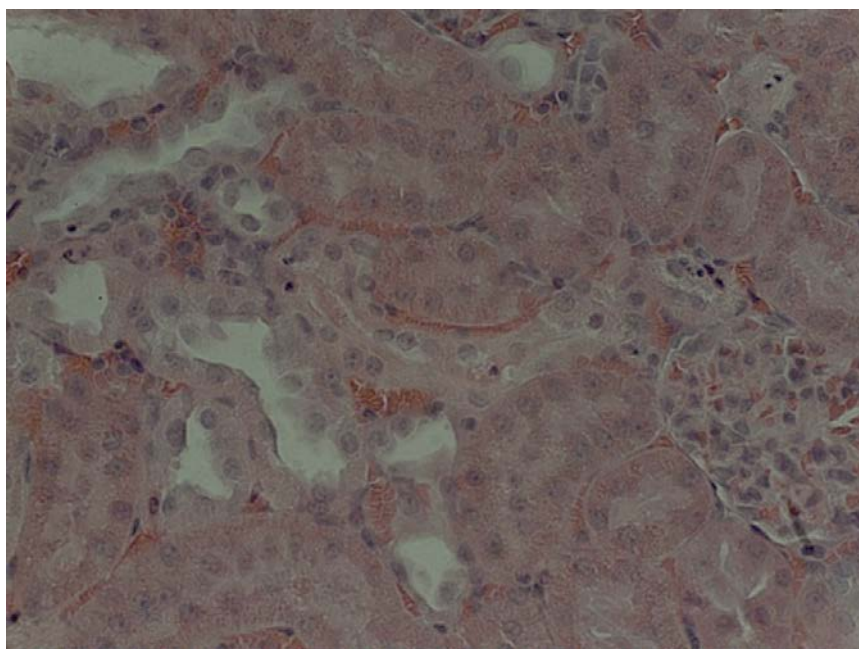
**Figure 2.** *Histopathological view of renal sections of GM group of rats (HE x 200)*

Green tea (Figure 3) reversed most of the histopathological alterations induced by gentamicin as seen from sections from GT+GM group (7). Figure 4 shows normal glomeruli, alleviated tubular degeneration and mild to moderate mononuclear inflammatory infiltrates. The rest of histopathological

changes produced by gentamicin were completely prevented by green tea treatment. There were no necrosis of the epithelial cells of proximal tubules and no hyaline cylinders. Green tea alone (GT group) was found to be safe and did not induce any histopathological changes in the kidney.



**Figure 3.** *Histopathological view of renal sections of GT group of rats (HE x 200)*



**Figure 4.** Histopathological view of renal sections of GT+GM group of rats (HE x 200)

### Biochemical analysis

In the GM group when compared to the C group, the analysis of biochemical parameters showed a significant increase of urea and creatinine serum concentrations ( $p < 0.001$ ) (Table 1). In the GT+GM group, creatinine concentrations were

elevated compared to the control group but not statistically, but these values were significantly decreased compared to the GM group ( $p < 0.001$ ). Levels of urea were not significantly elevated in GT+GM group in comparison with the C group and were significantly lower when compared to the GM group of animals ( $p < 0.001$ ).

**Table 1.** Biochemical analysis of rat serum creatinine and urea concentrations

SERUM CONCENTRATION	C group	GM group	GT group	GT+GM group
CREATININE ( $\mu\text{mol/L}$ )	$5.44 \pm 0.7127$	$268.4 \pm 55.39^{***}$	$46.31 \pm 7.665^{***}$	$86.14 \pm 20.57^{***}$
UREA (mmol/L)	$38.38 \pm 1.931$	$158.6 \pm 37.92^{***}$	$51.84 \pm 5.607^{***}$	$51.94 \pm 2.27^{***}$

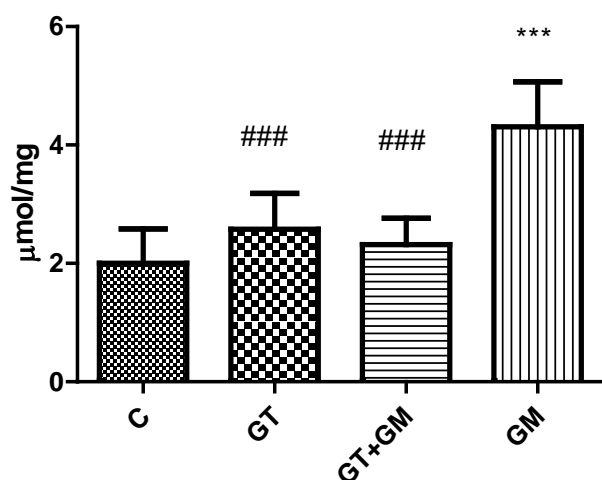
$^{***}p < 0.001$  VS. GM

$^{***}p < 0.001$  VS. C

### Estimation of lipid peroxidation

Gentamicin administration to rats significantly increased the MDA levels in the kidney tissue compared to C group ( $p < 0.001$ ). Coadministration of

green tea in the GT+GM group reduced lipid peroxidation, as evidenced by significantly decreased level of MDA when compared to the GM group ( $p < 0.001$ ) (Figure 5).



### $p < 0.001$  VS. GM

\*\*\* $p < 0.001$  VS. C

**Figure 5.** Values of kidney malondialdehyde in separate groups of treated rats

## DISCUSSION

Gentamicin is still considered to be an important antibiotic against life-threatening infections despite its nephrotoxic effect (7). Moreover, gentamicin-induced nephrotoxicity has been widely used as an animal model to study acute kidney failure in experimental research (3). It is suggested that the most important factor in pathogenesis of gentamicin-induced nephrotoxicity is oxidative stress and generation of reactive oxygen species (ROS). ROS induces tubular necrosis, decrease of glomerular filtration rate and inflammation by activating nuclear factor kappa B (3). We found that gentamicin caused marked elevations of serum creatinine and urea concentrations ( $p < 0.001$ ) compared with control group. Increased level of malondialdehyde ( $p < 0.001$ ) compared to control group indicates free radicals generation in gentamicin-induced nephrotoxicity. Increase of serum creatinine, urea and malondialdehyde were inhibited significantly in rats simultaneously treated with green tea and gentamicin compared to gentamicin-only treated rats. The majority of previous experiments studying protections against gentamicin-induced nephrotoxicity were focused on the use of different antioxidant substances, including the extracts from medicinal plants with antioxidant properties. However, none of these have been found to be safe/suitable for clinical practice (9).

Our results showed decrease in serum creatinine and urea in group that was simultaneously treated with green tea, which indicates that administration of green tea ameliorates glomerular function (3). The biochemical analysis of our study was confirmed by the histopathological analysis, where GM group show necrosis of proximal tubules, vacuolization of cytoplasm and massive mononuclear inflammatory infiltrates in interstitium. Coadministration of green tea with gentamicin had renoprotective effect and showed only mild infiltrations, normal glomeruli and alleviated tubular degeneration (1). The renoprotective effect of green tea extract has been previously reported by Salem EA et al (1) and Khan et al (10).

Tea, the most consumed beverage since ancient times, is known for its beneficial health effects. Green tea polyphenols, mainly catechins and their derivatives have been shown to have antimutagenic, anticarcinogenic, neuroprotective, antidiabetic and antibacterial health benefit. Their most important property, when it comes to our study, is their antioxidant action (10). These polyphenols include epicatechin, epicatechin-3-gallate, epigallocatechin and epigallocatechin-3-gallate, with the latter being the main polyphenol in green tea, acting protective against renal injury. It is suggested that epigallocatechin-3-gallate participates in the elimination of uremic toxins and prevention of renal failure. Also, green tea polyphenols inhibit synthesis of vasoconstrictor generation, such as thromboxane A<sub>2</sub> and prostaglandine D<sub>2</sub> (1) and inhibit inflammatory responses by attenuating NF kappa B activation.

## CONCLUSION

Our study showed that green tea reduces gentamicin-induced functional and histological kidney damage. These results may indicate that green tea is beneficial as a protective agent in gentamicin-induced nephrotoxicity, possibly by inhibition of lipid peroxidation and enhancing antioxidant activity.

## Declaration of interest

The authors report no conflicts of interest.

## References

1. Salem EA, Salem AN, Kamel M et al. Amelioration of gentamicin nephrotoxicity by green tea extract in uninephrectomized rats as a model of progressive renal failure. *Renal Failure* 2010;32(10):269:1210–5.
2. Stojiljkovic N, Stoilkovic M, Mihailovic D et al. Beneficial Effects of Calcium Oral Coadministration in Gentamicin-Induced Nephrotoxicity in Rats. *Renal Failure* 2012;34(5):622–7.  
<http://dx.doi.org/10.3109/0886022X.2012.664809>
3. Tavafi M, Ahmadvand H, Toolabi P. Inhibitory Effect of Olive Leaf Extract on Gentamicin-Induced Nephrotoxicity in Rats. *Iranian J Kidney Dis* 2012;6:25-32.
4. Bledsoe G, Crickman S, Mao J, et al. Kallikrein/kinin protects against gentamicin-induced nephrotoxicity by inhibition of inflammation and apoptosis. *Nephrol Dial Transplant* 2006;21:624-33.  
<http://dx.doi.org/10.1093/ndt/gfi225>
5. Balakumar P, Rohilla A, Thangathirupathi A. Gentamicin-induced nephrotoxicity: Do we have a promising therapeutic approach to blunt it? *Pharmacol Res* 2010;62:179-86.  
<http://dx.doi.org/10.1016/j.phrs.2010.04.004>
6. Yaman I, Balikci E. Protective effects of nigella sativa against gentamicin-induced nephrotoxicity in rats. *Exp Toxicol Pathol* 2010;62:183-90.
7. Abdel-Raheem IT, El-Sherbiny GA, Taye A. Green tea ameliorates renal oxidative damage induced by gentamicin in rats. *Pak J PharmSci* 2010;23:21-28.
8. Committee on Herbal Medicinal Products (HMPC). Assessment report on *Camellia sinensis* (L.) Kuntze, non fermentatum folium, EMA/HMPC/283629/2012. European Medicines Agency, 2012.
9. Priyamvada S, Medha Priyadarshini, N.A. Arivarasu, Neelam Farooq, Sheeba Khan, Sara A. Khan, Md. Wasim Khan, A.N.K. Yusufi. Studies on the protective effect of dietary fish oil on gentamicin-induced nephrotoxicity and oxidative damage in rat kidney. *Prostaglandins, Leukotrienes and Essential Fatty Acids* 2008;78:369-81.  
<http://dx.doi.org/10.1016/j.plefa.2008.04.008>
10. Khan SA, Priyaamvada S, Farooq N et al. Protective effect of green tea extract on gentamicin-induced nephrotoxicity and oxidative damage in rat kidney. *Pharmacol Res* 2009;59:254–62.  
<http://dx.doi.org/10.1016/j.phrs.2008.12.009>

## Povoljni efekti ekstrakta zelenog čaja na akutnu bubrežnu insuficijenciju uzrokovanu gentamicinom kod pacova

Milica Veljković<sup>1</sup>, Sonja Ilić<sup>1</sup>, Nenad Stojiljković<sup>1</sup>, Ljubinka Veličković<sup>2</sup>, Dragana Pavlović<sup>3</sup>,  
Mirjana Radenković<sup>1</sup>, Suzana Branković<sup>1</sup>, Dušanka Kitić<sup>3</sup>, Marija Gocmanac-Ignjatović<sup>1</sup>

<sup>1</sup>Univerzitet u Nišu, Medicinski fakultet, Institut za fiziologiju, Srbija

<sup>2</sup>Univerzitet u Nišu, Medicinski fakultet, Institut za patologiju, Srbija

<sup>3</sup>Univerzitet u Nišu, Medicinski fakultet, Departman za farmakognoziju, Srbija

### SAŽETAK

Cilj našeg istraživanja bio je da ispitamo efekat zelenog čaja na akutnu bubrežnu insuficijenciju uzrokovanu gentamicinom.

Istraživanje smo sprovedeli na trideset dva pacova Wistar soja koje smo podelili u četiri grupe od po 8 životinja. Kontrolna (C) grupa primala je fiziološki rastvor. GT grupa je primala oralno ekstrakt zelenog čaja u dozi od 300 mg/kg. GM grupa primala je gentamicin intraperitonealno u dozi od 100 mg/kg, a GT+GM grupa primala je zajedno gentamicin i ekstrakt zelenog čaja.

Histološki preparati bubrega pacova GM grupe pokazali su nekrozu proksimalnih tubula, vakuolizaciju citoplazme i masivni mononuklearni zapaljenski infiltrat u intersticijumu. Istovremena primena zelenog čaja sa gentamicinom imala je renoprotektivni efekat i pokazala samo blage infiltrate, normalne glomerule i smanjenu degeneraciju tubula. Analiza biohemijskih parametara pokazala je statistički značajno povećanje koncentracije uree i kreatinina u GM grupi, u poređenju sa C grupom i GT+GM grupom ( $p < 0,001$ ). Biomarker lipidne peroksidacije u plazmi MDA bio je značajno viši u GM grupi u odnosu na C grupu ( $p < 0,001$ ), dok su njegove vrednosti u GT+GM grupi bile značajno niže u poređenju sa GM grupom ( $p < 0,001$ ).

Korisni efekti zelenog čaja na gentamicinom uzrokovanu nefrotoksičnost mogu se objasniti smanjenjem oksidativnog stresa i lipidne peroksidacije.

Naši rezultati ukazuju da primena zelenog čaja ima protektivni efekat na oksidativni stres i akutnu bubrežnu insuficijenciju uzrokovanu gentamicinom.

*Ključne reči:* gentamicin, zeleni čaj, ekstrakt, pacovi