

Acute Fatty Liver of Pregnancy Mimicking Puerperal Sepsis: Report of a Case with Literature Review

Ibrahim Masoodi, Abed Al-Lehibi¹, Abdullah Wani¹, Adel Alqutub¹

Department of Internal Medicine, College of Medicine, Taif University, Taif, ¹Gastroenterology KFMC, Riyadh, Saudi Arabia

Correspondence: Dr. Ibrahim Masoodi, Department of Internal medicine, College of Medicine, Taif University, PO Box 888, Taif 21974 Saudi Arabia. E-mail: ibrahimmasoodi@yahoo.co.in

ABSTRACT

Puerperal pyrexia is defined as fever in a woman within 6 weeks of giving birth, which is $\geq 38^{\circ}\text{C}$. We describe the clinical scenario of fever and progressive jaundice in a 32-year-old female in the postpartum period. The laboratory data showed normal leukocytic counts and all her septic screen was noncontributory. While in the hospital, her bilirubin levels progressively increased and showed a mild elevation of liver enzymes. There was no evidence of biliary obstruction. A liver biopsy clinched the diagnosis of acute fatty liver. Acute fatty liver of pregnancy is a rare but serious complication of pregnancy. It typically presents in the third trimester and can lead to multi-organ failure and death. This report highlights the importance of liver biopsy and an atypical presentation of fatty liver of pregnancy.

Key words: Acute fatty liver of pregnancy, postpartum cholestasis, puerperal pyrexia

ملخص البحث :

يناقش الباحثون الأعراض السريرية لحالة حمى ويرقان لدى سيدة في الثانية والثلاثين من عمرها وضعت طفلها قبل أسبوعين. وكانت الفحوصات المخبرية طبيعية. وأثناء تواجدها بالمستشفى ارتفعت المادة الصفراء وأنزيمات الكبد. خضعت المريضة لأخذ عينة من الكبد والتي بينت التهاب كبدى دهني حاد. تعتبر هذه من الحالات النادرة من المضاعفات الخطيرة للحمل وعادة ما تحدث في الثلث الأخير منه وقد تسبب مضاعفات خطيرة تؤدي إلى الوفاة.

CASE PRESENTATION

A 32-year-old female presented with a history of high-grade fever and jaundice of 2 weeks duration following a lower section caesarean section in a local hospital. The patient had started icterus 1-week prior to the lower section caesarean section without any viral prodrome or offending drug intake. She denied any fever, pruritus or clay colored stools before surgery. There was no history of intake of any herbal medication. She underwent lower section caesarean section due to intrauterine death at 37 weeks of gestation. Apart from

bilirubin levels of 3 mg/dl, all her investigations were normal before surgery. She had delivered her first baby uneventfully 2 years earlier and had no other significant history. Examination in our hospital revealed an averagely built lady, conscious, and hemodynamically stable with no signs of chronic liver disease. She was icteric and had a temperature of 38°C . The scar of surgery was healthy with no local discharge. Her systemic examination was unremarkable. On evaluation, she had hemoglobin of 10.6 g/dl with a total leukocytic count of 7000/cu mm, a platelet count of 515×10^3 blood urea nitrogen, and serum creatinine were normal. Liver function test showed bilirubin levels of 8 mg/dl with a direct fraction of 6.8 mg/dl. Her serum glutamic oxaloacetic transaminase (SGOT), serum glutamic pyruvic transaminase (SGPT) levels were 43 and 24 IU respectively. Her alkaline phosphatase and gamma-glutamyltransferase were 117 and 55 respectively. The ultrasound showed gallstones with no intrahepatic biliary dilatation. In view of the gall stones, magnetic resonance cholangiopancreatography (MRCP) was done and biliary obstruction ruled out.

Access this article online

Quick Response Code:



Website:

www.sjmms.net

DOI:

10.4103/1658-631X.170894

All viral markers hepatitis B surface antigen (HBSAg), hepatitis A virus (HAV), anti-hepatitis C virus (HCV) and hepatitis E virus (HEV) were negative. HBSAg, Immunoglobulin M (Ig M) HAV, anti-HCV and Ig M HEV were negative. On further evaluation, her antinuclear antibody and anti-smooth muscle antibody levels were also negative. Her serum ceruloplasmin and serum ferritin levels were normal. Computed tomographic study of the abdomen and pelvic organs showed no abnormality and there was no collection to explain pyrexia. Her leukocytic counts on multiple occasions in the hospital course continued to be normal and all cultures were sterile. She was initially started on broad spectrum antibiotics which were stopped as there was no objective evidence of sepsis. During her hospital stay Bilirubin levels increased to 10 mg/dl, and liver enzymes SGOT/SGPT were 52 and 48 IU respectively. Coagulation parameters continued to be normal and fibrinogen degradation product levels were normal as well. Serum protein and serum albumin levels were normal. A liver biopsy was done which showed microvesicular steatosis and an oil red O staining the cytoplasmic vesiculation were seen as a result of microvesicular fat. The overall histological features were consistent with acute fatty liver of pregnancy (AFLP) [Figures 1 and 2]. She was managed conservatively and was discharged home in a stable condition after 12 days of hospitalization. She has been attending our clinic regularly for the past 1-year.

DISCUSSION

The physiological changes in liver function in pregnancy are commonly transient, rarely permanent. However, eclampsia, AFLP, hemolysis, elevated liver enzyme and low platelets (HELLP) syndrome can have serious implications.^[1] The index case presented with a febrile

illness and jaundice in the postpartum period. In view of the presence of gallstones discovered on ultrasonographic examination, it was necessary to rule out biliary system obstruction. Therefore, an MRCP was done and a biliary system obstruction was ruled out. The differentials in the postpartum period of fever and jaundice could include sepsis which was ruled out by appropriate investigations in the index case. The viral aetiology of her jaundice was also ruled out. Given the fact that the platelet count were normal HELLP syndrome was not considered a differential. Since she denied taking any hepatotoxic drug, and was not an alcoholic, it was necessary to do a liver biopsy in order to explain the rising direct hyperbilirubinemia. The liver biopsy decided the diagnosis of AFLP. The patient had elevated bilirubin levels in her third trimester of pregnancy, but there had been no suspicion of AFLP. AFLP, first described in 1934, has been linked to a deficiency of the enzyme long chain3 hydroxyacyl — coA dehydrogenase in the fetus, a disorder of mitochondrial fatty acid beta-oxidation.^[2] It is quite possible that the intrauterine fetal death of the child was caused by a severe deficiency of fatty acid oxidation enzymes in the fetus, however, it is difficult to prove this as no enzyme analysis was done in the fetus. Certainly the delivery by caesarean section averted complications and a fatal outcome related to AFLP of the mother. Studies have shown that prompt delivery can be life-saving in a given case of AFLP.^[3] The incidence of AFLP ranks from 1 to 20 thousand births, and it is more frequent in women with multiple pregnancies, though it can be seen during first pregnancy as well.^[4] In a retrospective analysis, ZHOU *et al.*, studied the clinical profile of 28 cases over a period of 5 years. In their study, the authors observed that the condition was more common in primipara, and began in the third trimester with anorexia and jaundice. They observed coagulopathy and leukocytosis to be uniformly

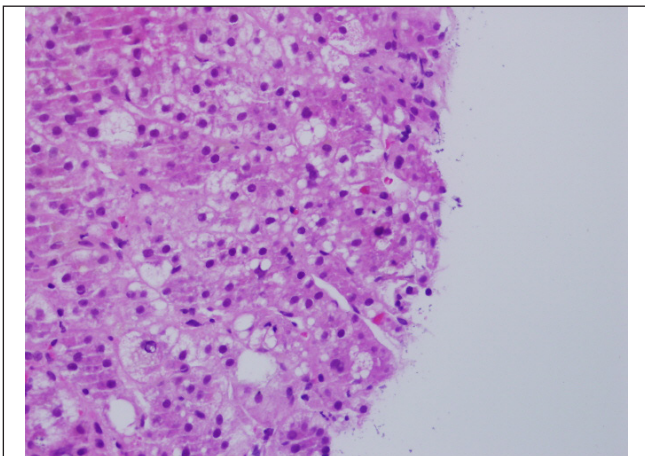


Figure 1: Acute fatty liver changes

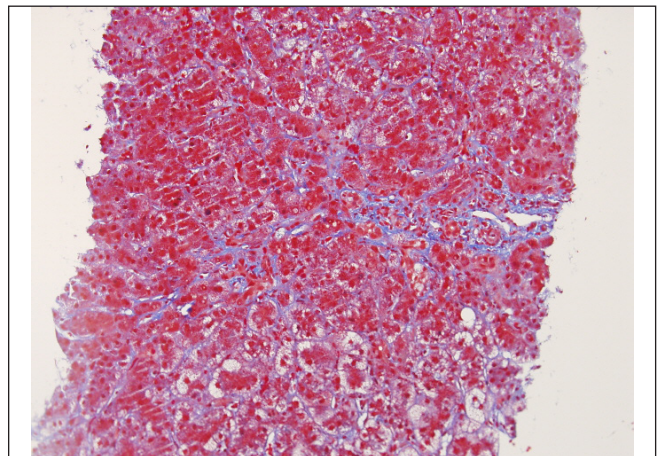


Figure 2: Fatty liver changes in liver

present in their series.^[5] The index case had normal leukocytic count and her coagulation profile were also normal. Besides, she had no disseminated intravascular coagulation (DIC) features. Similarly, data on eleven patients from China showed that the presentation of this rare condition starts in the third trimester with anorexia, nausea, and jaundice with almost all patients having elevated liver enzymes and hypoglycemia as was seen in 18% of patients in this series.^[4] The authors concluded that delivery of the baby positively affected the outcome of both mother and child. Hypoglycemia is considered a very important feature in this rare disorder and should help in deciding the diagnosis in an appropriate setting, but there was no hypoglycemia in our case. The possibility is that the liver damage had settled after delivery and so had not progressed to liver cell failure. A combination of hypoglycemia and hyperbilirubinemia was reported by Piligo *et al.* in the 37th week of gestation in a lady whose liver biopsy was suggestive of AFLP.^[6] Data on 18 patients from a Taiwan center with AFLP showed that majority of the patients (67%) were diagnosed in the postpartum period and the authors observed that apart from severe liver cell dysfunction, renal failure and disseminated intravascular coagulation, and hypoglycemia were among the most common complications.^[7] The authors observed a mortality rate of 11% in their series. Our case maintained her renal functions and had no DIC features. Husjung *et al.*^[8] observed that hyperuricemia preceded hyperbilirubinemia in AFLP and could be a pointer to the early detection of this fatal disease.

A delay in the diagnosis of this obstetric emergency may lead to a rapid progress to hepatic failure, (DIC), hemorrhage, encephalopathy, multiple organ failure, and finally death.^[9] There is no specific treatment, but screening the newborn at birth in pregnancies complicated by AFLP for this metabolic disorder can be life-saving with appropriate dietary modifications, and genetic counseling in subsequent pregnancies.

However, the mortality rate decreased dramatically from 80% in 1965 to 100% survival in 1999 according

to the latest reviews. This regression of the symptoms and signs together with normalization of the laboratory values has driven some authors to name this disease as the “reversible peripartum liver failure”.

CONCLUSION

The present case reflects an atypical presentation of AFLP, which sometimes mimics puerperal sepsis. Further, this case highlights the importance of high clinical suspicion and the role of liver biopsy in a patient with fever and jaundice after other causes have been ruled out.

REFERENCES

1. Jamjute P, Ahmad A, Ghosh T, Banfield P. Liver function test and pregnancy. *J Matern Fetal Neonatal Med* 2009;22:274-83.
2. Ibdah JA. Acute fatty liver of pregnancy: An update on pathogenesis and clinical implications. *World J Gastroenterol* 2006;12:7397-404.
3. Papafragkakis H, Singhal S, Anand S. Acute fatty liver of pregnancy. *South Med J* 2013;106:588-93.
4. Wei Q, Zhang L, Liu X. Clinical diagnosis and treatment of acute fatty liver of pregnancy: A literature review and 11 new cases. *J Obstet Gynaecol Res* 2010;36:751-6.
5. Zhou G, Zhang X, Ge S. Retrospective analysis of acute fatty liver of pregnancy: Twenty-eight cases and discussion of anesthesia. *Gynecol Obstet Invest* 2013;76:83-9.
6. Pliego Pérez AR, Zavala Soto JO, Rodríguez Ballesteros R. Fatty liver in pregnancy. A report of two cases and medical literature review Taiwan. *J Obstet Gynecol* 2010;49:156-9.
7. Lau HH, Chen YY, Huang JP, Chen CY, Su TH, Chen CP. Acute fatty liver of pregnancy in a Taiwanese tertiary care center: A retrospective review. *Taiwan J Obstet Gynecol* 2010;49:156-9.
8. Hsiung R, Hasselmann M, Lutun P, Gordji M. Acute fatty liver of pregnancy. Diagnostic value of hyperuricemia in the pre-jaundice stage. *J Gynecol Obstet Biol Reprod (Paris)* 1988;17:901-5.
9. Yücesoy G, Ozkan SO, Bodur H, Cakiroglu Y, Caliskan E, Ozeren S. Acute fatty liver of pregnancy complicated with disseminated intravascular coagulation and haemorrhage: A case report. *Int J Clin Pract Suppl* 2005;147:82-4.

How to cite this article: Masoodi I, Al-Lehibi A, Wani A, Alqutub A. Acute fatty liver of pregnancy mimicking puerperal sepsis: Report of a case with literature review. *Saudi J Med Med Sci* 2016;4:42-4.

Source of Support: Nil, **Conflicts of Interest:** None declared.