Ann Thorac Cardiovasc Surg 2012; 18: 297–305
doi: 10.5761/atcs.ra.12.01882

Review Article

Paraesophageal Hernia Repair

Toshiyuki Mori, MD FACS, Gen Nagao, MD, and Masanori Sugiyama, MD

Paraesophageal hiatal hernia (PHH), accounting for only 5% of all hiatal hernias, may result in potentially life threatening complications such as obstruction, acute dilatation, perforation, or bleeding of the gastric mucosa. It is traditionally believed that PHH is an indication for surgery. The repair of paraesophageal hernia is technically challenging and controversial. The purpose of this article is to overview the current status of indication of surgery; operative techniques including hernia sac resection, esophageal lengthening procedure, crural repair, and additional antireflux procedure. Results: All symptomatic patients should be surgically treated, when operation is possible. It seems reasonable that asymptomatic or minimally symptomatic patients do not necessarily require surgery and that a more selective approach should be used. The penetration rate is not high, laparoscopic approach is currently the standard care. The hernia sac should be excised and resected circumferentially. Collis-Nissen procedure continues to be the method of choice also in the laparoscopic era, when lengthening procedure of the shortened esophagus is in consideration. Although symptomatic recurrence after suture closure of the crura is uncommon, primary repair is associated with a high rate of anatomic recurrence. Prosthetic mesh repair is reportedly associated with a recurrence rate as low as 5%, at the price of rare but serious complications such as erosion and fibrosis. Although scientific proof is lacking, fundoplication is the most common procedure to be added after crural repair.

Keywords: paraesophageal hiatal hernia, laparoscopic surgery, crural repair, Collis-Nissen procedure

Introduction

Hiatal hernia has become a common diagnosis, especially it relates to gastro-esophageal reflux disease (GERD). More than 90% of hiatal hernia is type I hernia (sliding type) where the GEJ is displaced cranial to the hiatus.[1] Less commonly encountered is paraesophageal hiatal hernia (PHH) where the fundus and sometimes the whole stomach have migrated in the mediastinum alongside the esophagus (type II hernias). In type III, or mixed paraesophageal hernias, the GEJ and a large part of the stomach have migrated into the mediastinum. This type of hernia is often large, and the term of large or giant paraesophageal hernia is commonly used when more than 30% or 50% of the stomach is displaced above the diaphragm.[2,3] In type IV hernias the stomach, sometimes with other viscera such as the colon or spleen, migrates in the hernia sac, which may result in an "upside-down stomach."[4] Although PHH account for only 5% of all hiatal hernias,[5] it may result in potentially life threatening complications such as obstruction, acute dilatation, perforation, or bleeding of the gastric mucosa (riding ulcer).[6,7] It is traditionally believed that PHH is an indication for surgery. Nevertheless, patients with asymptomatic PHH are often identified by routine chest X-ray showing the

Department of Surgery, Kyorin University, Tokyo, Japan

Received: January 5, 2012; Accepted: February 14, 2012
Corresponding author: Toshiyuki Mori, MD, FACS. Department of Surgery, Kyorin University, 6-20-2 Shinkawa, Mitaka, Tokyo 181-8611, Japan
Email: mori@ks.kyorin-u.ac.jp

air-fluid level in the chest. It is questionable to plan surgery for all these patients. Censored observation policy is currently advocated for these asymptomatic cases. Although scientific comparison to traditional open approach is lacking, there would be no argument that laparoscopic repair is the current standard of care. The technique and approach of fixation continues to be one of the most controversial topics in the surgical literature.[8] Most of the debate is centered around the high recurrence rate after surgery and the complication that arises from implanting mesh as a buttress for the repair. However, several surgical principles seem to have gained consensus in these studies: reduction of the stomach into the abdomen, excision of the hernia sac, evaluation of the intraabdominal esophageal length, and adequate esophageal dissection, crural closure, and antireflux procedure.[2] The aim of this article is to review current literature and practice on these topics as they relate to hernia repair.

Indications for Surgery

The decision to surgically repair a large PHH is based on 3 factors: the patient's overall medical status, symptomatic complaints, and the chance of incarceration and strangulation.[9]

Traditionally, elective surgical repair has been recommended for all patients with PHH considered being medically operable.[10,11] Much of this recommendation is based on the classical studies such as that of Skinner et al,[12] who in 1967 found that type II PHH carried a 29% mortality rate in asymptomatic patients due to incarceration with strangulation. Some surgeons think that PHH enlarge with time making surgery more difficult and the increasing age of the patient, which may increase the risk of complications. Furthermore, emergency repair of PHH is reportedly associated with a high mortality rate. In 1973, Hill[13] reported a series of patients with gastric volvulus associated with PHH that had an operative mortality rate of 56%. This high mortality rate further propelled the policy to repair all PHH regardless of symptoms. In contrast, in a retrospective study by Allen et al.,[14] 23 of 147 patients were followed after refusing surgery and none of them developed a life-threatening complication from PHH. Only 4 of these 23 patients eventually developed progressive symptoms requiring an operation. This suggests that a selective approach to surgery is appropriate, with surgery reserved for symptomatic patients.[15,16] Mortality rate of emergency operation for PHH may also have been overestimated. Several recent reports, including pooled analysis by Stylopolos et al.[17] demonstrated a much lower mortality rate (5%–17%).

In light of this information, it seems reasonable that asymptomatic or minimally symptomatic patients do not necessarily require surgery and that a more selective approach should be used.[18,19] There remains little debate, however, that all symptomatic patients who are medically operable should be surgically treated.[19]

Operative issues

Open PHH repair, done thorough the left chest or the abdomen, is based on fairly standard technique that involves reduction of the hernia, excision of the sac, repair of the hernia, and fixation of the stomach.[20,21]

There are no randomized studies comparing open abdominal approaches with thoracic approaches in the repair of PHH. It is also difficult to compare the studies of these approaches, because of variable clinical and radiographic follow-up and different and inconsistent outcome measures.[22] Low et al. reported the highest rate of recurrence (18%) with the most recurrence being asymptomatic. This result likely represents a true estimates of anatomic recurrence based on the through follow-up investigations performed by the authors. Both transthoracic and transabdominal approaches reportedly have good outcomes with low postoperative mortality rates and acceptable rates of recurrence.[14,23–25]

The first report of laparoscopic repair of PHH was published in 1992.[26]

Many reports in various hernia size and surgical technique followed.[27–30] Although there is no randomized control study comparing laparoscopic surgery to open procedures, laparoscopic repair has already become a standard care. Nguyen et al.[31] has recently published a paper, which retrospectively compared 2069 laparoscopic, and 657 open repair of PHH. For elective procedures, utilization of laparoscopic repair was 81% and was associated with a shorter hospital stay (3.7 vs. 8.3 days, $P < 0.01$), less requirement for intensive care unit care (13% vs. 35%, $P < 0.01$), and lower overall complications (2.7% vs. 8.4%, $P < 0.01$), 30-day readmissions (1.4% vs. 3.4%, $P < 0.01$) and costs ($15,227 vs. $24,263, $P < 0.01$). The in-hospital mortality was 0.4% for laparoscopic repair versus 0.0% for open repair. In patients presenting with obstruction or gangrene, utilization of laparoscopic repair was 57% and was similarly associated with improved outcomes compared with open repair. Within the context of academic centers, the current practice of paraesophageal hernia repair is mostly laparoscopy. Compared with open

repair, laparoscopic repair was associated with superior perioperative outcomes even in cases presenting with obstruction or gangrene. Rathore et al.[32] published a meta-analysis of non-randomized series of laparoscopic PHH repair. Inclusion was restricted to those series with greater than 25 patients and follow up beyond 6 months. In 965 patients, the overall recurrence rate was 10.2%. Among those patients formally evaluated with a contrast esophagogram postoperatively, 25.5% had recurrence. Lower recurrence rates were noticed in those who underwent an esophageal lengthening procedure with a Collis Nissen gastroplasty versus those who did not (0% vs. 12%). Despite the wide adoption and good results of laparoscopic repair of PHH, a recent international survey of members of Cardio Thoracic Surgery Network revealed only 48% of members repair PHH laparoscopically, whereas 35% perform thoracotomy, and 17% perform laparotomy.[33]

Hernia sac resection

In some early reports on laparoscopic paraesophageal hernia, the hernia sac was not completely removed or not removed at all, because resection of the entire sac was the most technically demanding part of the procedure. In these series, fluid collection in the posterior mediastinum was reported.[34] Some were associated with dysphagia.[34] Leaving the sac in place was also clearly associated with a higher rate of recurrence.[34,36] Surgeons should divide and resect the sac and all of its attachment, circumferentially. By leaving a portion of the sac in place, especially if it is in continuity with the intra-abdominal peritoneum, a possible path may be left for development of a new hernia.[37]

Esophageal shortening

Esophageal shortening has long been a major issue of controversy in the diagnosis and management of hiatal hernia. Despite having been described over 50 years,[38] questions remain as to the existence and management of the shortened esophagus. Those who do not believe that a shortened esophagus exists claim that, in most patients, the esophagus appears shortened because the stomach is pushing it up into the chest and that if the anatomic arrangement is corrected, no lengthening procedure is needed.[38] On the contrary, Pierre et al.[39] reported a rate of 55 % of esophageal lengthening procedure for the shortened esophagus in his series of 203 patients with PHH. The true incidence of esophageal shortening in PHH is unknown, reportedly a rate of 0% to 60%,[39–43] and remain a major point of controversy (**Table 1**). Many of surgeons believe that although short esophagus is uncommon, it remains an important cause of recurrence after PHH repair.[15,44]

The most important risk factor for esophageal shortening is the presence of periesophageal inflammation resulting from long-standing GERD.[44] It is speculated that GERD leads to chronic irritation followed by healing and fibrosis. Fibrosis of the outer longitudinal muscle and its contraction may lead to shortening of the esophageus.[45] Other risk factors that may predispose a patient to develop esophageal shortening include Barrett esophagus, scleroderma, and Crohn disease.[44,45] It is problematic to identify patients with shortened esophagus preoperatively. Several techniques to measure the length of the esophagus either by an endoscopy or radiologic technique have been published.[46,47] Also, esophageal manometry is reportedly useful for identification.[48] Unfortunately, none of these are completely reliable at predicting a shortened esophagus at the time of operation.[47,49,50] The most reliable method of determining esophageal shortening is intraoperative assessment (e.g. GEJ >2.5 cm below the hiatus).[41,50] When the diagnosis of short esophagus is made, a lengthening procedure of the esophagus is necessary. This may be accomplished by further intrathoracic dissection and mobilization of the esophagus or by gastroplasty. In 1957, Collis[51]described gastroplasty for this purpose without fundoplication. Subsequently, fundoplication was added to prevent reflux and is referred to as Collis-Nissen.[52] Collis-Nissen procedure continues to be the method of choice also in the laparoscopic era, when lengthening of the esophagus is in consideration.[53,54]

Crural Repair

Closure of the hiatal gap, also termed crural repair,[55] cruroplasty and hiatoplasty,[56] is one of the key steps in the repair of hiatal hernias.

Cuschieri et al., in the first report of laparoscopic repair of PHH, closed the crural gap with continuous suture and fixed the fundoplication to the anterior margin of the hiatus.[26] Currently the most common method of primary repair is continuous or interrupted sutures on the hiatus, followed by a fudoplication. While initially gratifying, it soon became evident that recurrence rate, both in the small hernia repair in anti-reflux procedures and in PHH, is unacceptably high. Soricelli et al.[57] published a retrospective series of their experience from 1992 to 1995 with 93 patients repaired by interrupted Prolene sutures. The mean follow-up was 95.2 months, and the recurrence rate was 19 %, with 91% of patient satisfaction. Targarona et al.[58]

Table 1 Outcome of selected series of laparoscopic repair of PHH

Author	Year	no of patients	% Lengthening gastroplasty	% Anatomic recurrence	Follow Up (months)
Trus et al[27]	1997	76	8	11	15 (median)
Wiechmann et al[41]	2001	60	0	7	40 (mean)
Matter et al[28]	2002	116	5	43	18 (median)
Pierre et al[39]	2002	203	56	2	37 (mean)
Jobe et al[42]	2002	52	0	32	37 (mean)
Diaz e al[29]	2003	116	5	32	30 (mean)
Andujar et al[30]	2004	166	0	5	15 (mean)
Boushey et al[43]	2008	58	0	9	6 (mean)

Adapted from Parekh, Iannenttori MD. Lengthening gastroplasty for managing giant paraesophageal hernia. In: Ferguson MK, editor Difficult decisions in thoracic surgery: an evidence-based approach. 1st edition. London: Springer-Verlag; 2007.p318-22. With kind permission from Springer Science and Business Media (license number: 2933500244156)

published a meta-analysis in 2004, which featured 22 studies (1331 patients) of primary laparoscopic repair of PHH from the years 1997 to 2003. The range of recurrence was 0% to 40%, and the overall recurrence rate was 14%. Several mechanisms for failure have been proposed: inability to achieve a tension free repair, less than adequate closure of the crura, failure to mobilize the correct length of the esophagus, postoperative retching, the dynamic mobility of the hiatus, and lack of significant tendon reinforcement of the crura.[58–61] It should be noted that recurrent, severe symptoms, requiring surgical revision, account for no more than 3 % of these failures.[28,62,63] The use of prosthetic material to reinforce the hernia repair has been proposed either routinely or in case of large hiatal gap, in order to reduce hernia recurrence to rates well below 10%.[64–66]

However, there are several arguments against the use of prosthesis, mainly because available literature is not of a high level of evidence regarding study design and lack of long-term functional outcomes. Most studies report on the short-term outcomes of small series of patients with a variety of hiatal hernia type (sliding hernia type I also included) and size, and variety of prosthesis material, shape, and technique of application.[67,68] Furthermore, the safety of the use of the prosthesis is a matter of concern, because short- and long-term dysphagia as a result of reactive fibrosis around the esophagus, and erosion and fistulization of the foreign material to the viscera have been reported.[8,11,27,69] In order to minimize these adverse effects, a variety of materials have evolved. Different mesh shapes have also been appraised with regard to dysphagia and recurrence rates (**Table 2**, **Fig 1**).[56] Furthermore, mesh application without primary hiatorrhaphy, referred as tension-free hiatoplasty, has been postulated to be associated with lower recurrence rate as a result of the theoretically decreased tension and muscular fiber disruption of the crural pillars. Antoniou et al.[55] recently published a review article of mesh-reinforced hiatal hernia repair. Inclusion criteria were 20 patients or more in the series, 6 months or more of follow-up, description of prosthetic material, its application, and additional anti-reflux surgery. From 1990 to 2010, 23 studies (1446 patients) were included, 11 of which were prospective, including 2 randomized control trials; 8 were retrospective, whereas the study design was not specified in the remaining 4 studies. Polypropylene (PP) was the most commonly used mesh material, utilized by 52% of authors, followed by polytetrafluoroethylene (PTFE) or expanded PTFE (26%), collagen or titanium coated PP (9%), collagen coated polyethylene (4%), and polyglactin910 (Vicryl; 4%). Mesh shape and size varied significantly among different studies. The vast majority of authors placed the mesh posterior to the esophagus, and 22% of them performed a "tension-free" hiatoplasty. Half of the authors preferred to excise the hernia sac in order to achieve adequate mediastinal visualization, while fundoplication was the most commonly used procedure following hiatal hernia repair (91%). Recurrence rate ranged from 0% to 38.5%, whereas the incidence of postoperative dysphagia, ranged from 0% to 34.3% among the studies.[57,61,65–68,70–86] Polypropylene meshes seem to be associated with low recurrence rate (0%–22.7%, median 1.9%) and acceptable dysphagia rate (0%–21.%, median 3.9%). Higher dysphagia rates after polytetrafluoroethylene (PTFE) or expanded PTFE (ePTFE) mesh have been recorded (15.5%–34.3%). Some authors still advocate suture closure of the hiatal gap in all cases,[87] whereas biologic implant engineering represents a promising field in hiatal hernia surgery.

Table 2 Compositttion of the mesh-advantages and disadvantages

Material	Advantage	Disadvantage
Polypropylene	(1) Well and rapidly incorporated (2) Does not induce foreign-body reaction (3) Macroporous structure allows infiltration of granulocytes avoiding infection (4) Allows to visualize the underlying muscle when placing the sutures (5) Porous structure allows omission of sac excision, obviating the fear of causing a mediastinal retention cyst (6) Inexpensive (7) Easier to fix	(1) Maintains a rigid form (2) Tendency to form adhesions
Polytetrafluoroethylene	(1) Causes fewer adhesions (2) Allows tissue ingrowth without stimulating an extensive inflammatory response (3) Soft texture and pliability	(1) Expensive (2) Regular stapling with a hernia stapler is less useful (3) Opaque (4) Deformity on stapling due to thickness
Polyvinyl	(1) Inert to tissue reaction (2) Resilient, pliable (3) No tendency to excite fluid collections or abscess formation (4) Maintains flexibility	(1) Become fibrosed, contracted, and calcified
Teflon	(1) Maintain or increases strength (2) Easy to handle (3) Noninfective	
Bovine pericardium		(1) Expensive (2) Opaque (3) Deformity on stapling due to thickness
Porcine small intestine submucosa	(1) Pliable (2) Not synthetic (3) Resorbable (4) Easy to use	
Acellular dermal matrix	(1) Easy to handle and pliable (2) Rapid incorporation	

Adapted from Herbella FA, et al. Hiatal mesh repair--current status. Surg Laparosc Endosc Percutan Tech. 2011 Apr;21(2):61-6. with kind permission from Springer Science and Business Media (linsence number: 2933500027072)

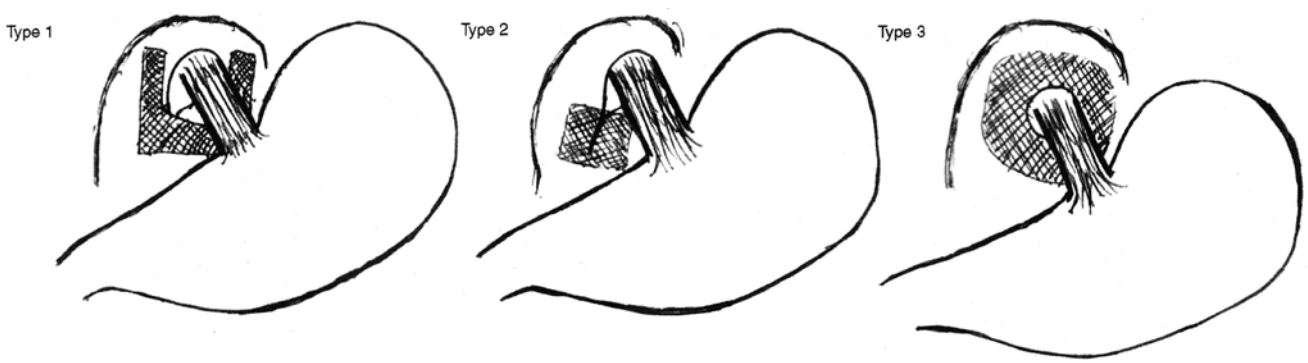

Fig. 1 Methods of mesh placement.
Adapted from Herbella FA, et al. Hiatal mesh repair--current status. Surg Laparosc Endosc Percutan Tech. 2011 Apr;21(2):61-6. with kind permission from Springer Science and Business Media (linsence number: 2933500027072)

Antireflux procedure

Although limited data confirm the need for fundoplication, most surgeons perform an antireflux procedure when repairing a PHH[11] because the fundoplication helps to anchor the stomach in the abdomen and because of the need to create a barrier to reflux. The extensive dissection necessary for full mobilization of the hernia sac and esophagus destroys anti-reflux mechanism and resulting in postoperative reflux. Incidence of postoperative reflux as high as 65 % in patients who did not receive a fundoplication has been reported.[38,88,89] These results have been dispute and a few argue that significant postoperative reflux is much less common in patients without fundoplication and, if present, can be managed with medical therapy.[90] Some authors believe that avoiding a fundoplication decreases the risk of postoperative dysphagia and operative complications and shortens the operative time for patients who are often elderly with significant medical comorbidities.[91] These authors suggest that fundoplication should be performed selectively in patients diagnosed with GERD on preoperative evaluation

Gastropexy/Gastrostomy

In many cases, reherniation occurs because of positive intra-abdominal pressure and negative intrathoracic pressure creating a cephalad force, rendering the stomach to migrate into the thorax. By anchoring the stomach below the diaphragm by gastropexy or gastrostomy, this migration may be avoided.[38] The technique is simple, however, a high rate of recurrence have been reported with this technique.[92–94] No prospective randomized study has proved that either of these two techniques reduces the rate of recurrence.

Summary

The repair of paraesophageal hernia is technically challenging and controversial. The approach to repair shifted from the thoracic to the open abdominal to the laparoscopic approach and the latter appear to be the current standard. High recurrence rates have been reported with laparoscopic repair, but these were found to be anatomic recurrence with much lower symptomatic rates. Symptomatic recurrence in the laparoscopic era appears similar to that seen with open procedures, but without the additional morbidity conferred by laparoscopy. In the last decade, several authors have improved the rate of recurrence using prosthetic meshes that have decreases even radiologic recurrence to fewer than 5%. However, this has come at the price of rare but serious complications such as erosion and fibrosis. Mesh repair appears to be associated with a higher perioperative rate of dysphagia. Biologic mesh has been implemented in an attempt to obtain the buttressing effect of prosthetic meshes without the complication of erosion or infection. Although scientific proof is lacking, fundoplication is the most common procedure to be added after crural repair.

References

1) van Herwaarden MA, Samsom M, Smout AJ. The role of hiatus hernia in gastro-oesophageal reflux disease. Eur J Gastroenterol Hepatol 2004; **16**: 831-5.
2) Mitiek MO, Andrade RS. Giant hiatal hernia. Ann Thorac Surg 2010; **89**: S2168-73.
3) Hazebroek EJ, Koak Y, Berry H, et al. Critical evaluation of a novel DualMesh repair for large hiatal hernias. Surg Endosc 2009; **23**: 193-6.
4) Hill LD, Tobias JA. Paraesophageal hernia. Arch Surg 1968; **96**: 735-44.
5) Dahlberg PS, Deschamps C, Miller DL, et al. Laparoscopic repair of large paraesophageal hiatal hernia. Ann Thorac Surg 2001; **72**: 1125-9.
6) Ellis FH, Crozier RE, Shea JA. Paraesophageal hiatus hernia. Arch Surg 1986; **121**: 416-20.
7) Tsuboi K, Tsukada K, Nakabayashi T, et al. Paraesophageal hiatus hernia, which has progressed for 8 years: report of a case. Hepatogastroenterology 2002; **49**: 992-4.
8) Davis SS. Current controversies in paraesophageal hernia repair. Surg Clin North Am 2008; **88**: 959-78, vi.
9) Sheff SR, Kothari SN. Repair of the giant hiatal hernia. J Long Term Eff Med Implants 2010; **20**: 139-48.
10) Naunheim DE, Limpert P. Paraesophageal hiatal hernia In Shields TW, LoCicero J, Ponn RB, et al. Editora. General Thoracic surgery 6th edition. Philadelphia; Lippincott Williams & Wilkins, 2004. p2190-9.
11) Draaisma WA, Gooszen HG, Tournoij E, et al. Controversies in paraesophageal hernia repair: a review of literature. Surg Endosc 2005; **19**: 1300-8.
12) Skinner DB, Belsey RH. Surgical management of esophageal reflux and hiatal hernia. Long term results with 1030 patients. J Thorac Cardiovasc Surgery 1967; **53**: 33-54.
13) Hill LD. Incarcerated paraesophageal hernia. A surgical emergency. Am J Surg 1973; **126**: 286-91.
14) Allen MS, Trastek VF, Dechamps C, et al. Intrathoracic stomach; presentation and results of operation. J Thorac Cardiovasc Surg 1993; **105**: 253-8.
15) Maziac DE, Pearson FG, Massive (paraesophageal) hiatal hernia. In Patterson GA, Cooper JD, Deslauriers J et al. Editors. Pearson's thoracic and esophageal surgery 3rd edition. Philadelphia; Chuchill Livingstone;

2008, p233-8.
16) Floch NR. Paraesophageal hernias; current concepts. J Clin Gastroenterol 1999; **29**: 6-7.
17) Stylopoulos N, Gazelle GS, Rattner DW. Paraesophageal hernias: operation or observation? Ann Surg 2002; **236**: 492-500; discussion 500-1.
18) Horgan S, Eubanks TR, Jacobsen G, et al. Repair of paraesophageal hernias. Am J Surg 1999; **177**: 354-8.
19) Rattner DW, Evans NR, Management of minimally symptomatic giant paraesophageal hernias. In Ferguson MK, editor. Difficult decision in thoracic surgery: an evidence based approach. 1st edition. London Springer-Verlag; 2007. p350-5.
20) Ellis FH. Diaphragmatic hiatal hernias. Recognizing and treating the major types. Postgrad Med 1990; **88**: 113-4, 117-20, 123-4.
21) Landreneau RJ, Johnson JA, Marshall JB, et al. Clinical spectrum of paraesophageal herniation. Dig Dis Sci 1992; **37**: 537-44.
22) Schiemann C, Grondin SC. Paraesophageal hernia: Clinical presentation, evaluation, and management controversies. Thorac Surg Clin 2009; **19**: 473-84.
23) Patel HJ, Tan BB, Yee J, et al. A 25-year experience with open primary transthoracic repair of paraesophageal hiatal hernia. J Thorac Cardiovasc Surg 2004; **127**: 843-9.
24) Martin TR, Furgason MK, Naunheim KS. Management of giant paraesophageal hernia. Dis Esophagus 1997; **10**: 47-50.
25) Geha AS, Massad MG, Snow NJ, et al. A 32-year experience in 100 patients with giant paraesophageal hernia: the case for abdominal approach and selective antireflux repair. Surgery 2000; **128**: 623-30.
26) Cuschieri A, Shimi S, Nathanson LK. Laparoscopic reduction, crural repair, and fundoplication of large hiatal hernia. Am J Surg 1992; **163**: 425-30.
27) Trus TL, Bax X, Richardson WS, et al. Complications of laparoscopic paraesophageal hernia repair. J Gastrointest Surg 1997; **1**: 221-8.
28) Mattar SG, Bowers SP, Galloway KD, et al. Long-term outcome of laparoscopic repair of paraesophageal hernia. Surg Endosc 2002; **16**: 745-9.
29) Diaz S, Brunt LM, Klingensmith ME, et al. Laparoscopic paraesophageal hernia repair, a challenging operation: medium-term outcome of 116 patients. J Gastrointest Surg 2003; **7**: 59-66; discussion 66-7.
30) Andujar JJ, Papasavas PK, Birdas T, et al. Laparoscopic repair of large paraesophageal hernia is associated with a low incidence of recurrence and reoperation. Surg Endosc 2004; **18**: 444-7.
31) Nguyen NT, Christie C, Masoomi H, et al. Utilization and outcomes of laparoscopic versus open paraesophageal hernia repair. Am Surg 2011; **77**: 1353-7.
32) Rathore MA, Andrabi SI, Bhatti M, et al. Mata-analysis of recurrence after laparoscopic repair of paraesophageal hernia. JSLS 2007; **11**: 456-60.
33) Management of giant paraesophageal hernia CTSNet. The CardioThoracic Surgery Network. Available at http://www.ctsnet.org/portals/thoracic/surveys/survey-results/survey_results_1008.html Published July 2008. Accessed December 24, 2011.
34) Edye M, Salky B, Posner A, et al. Sac excision is essential to adequate laparoscopic repair of paraesophageal hernia. Surg Endosc 1998; **12**: 1259-63.
35) Willekes CL, Edoga JK, Frezza EE. Laparoscopic repair of paraesophageal hernia. Ann Surg 1997; **225**: 31-8.
36) Wu JS, Dunnegan DL, Soper NJ. Clinical and radiologic assessment of laparoscopic paraesophageal hernia repair. Surg Endosc 1999; **13**: 497-502.
37) Oddsdóttir M. Paraesophageal hernia. Surg Clin North Am 2000; **80**: 1243-52.
38) Ponsky J, Rosen M, Fanning A, et al. Anterior gastropexy may reduce the recurrence rate after laparoscopic paraesophageal hernia repair. Surg Endosc 2003; **17**: 1036-41.
39) Pierre AF, Luketich JD, Fernando HC, et al. Results of laparoscopic repair of giant paraesophageal hernias: 200 consecutive patients. Ann Thorac Surg 2002; **74**: 1909-15; discussion 1915-6.
40) Herbella FA, Del Grande JC, Colleoni R. Short esophagus: literature incidence. Dis Esophagus 2002; **15**: 125-31.
41) Wiechmann RJ, Ferguson MK, Naunheim KS, et al. Laparoscopic management of giant paraesophageal herniation. Ann Thorac Surg 2001; **71**: 1080-6; discussion 1086-7.
42) Jobe BA, Aye RW, Deveney CW, et al. Laparoscopic management of giant type III hiatal hernia and short esophagus. Objective follow-up at three years. J Gastrointest Surg 2002; **6**: 181-8; discussion 188.
43) Boushey RP, Moloo H, Burpee S, et al. Laparoscopic repair of paraesophageal hernias: a Canadian experience. Can J Surg 2008; **51**: 355-60.
44) Gastal OL, Hagen JA, Peters JH, et al. Short esophagus: analysis of predictors and clinical implications. Arch Surg 1999 ; **134**: 633-6; discussion 637-8.
45) Horvath KD, Swanstrom LL, Jobe BA. The short esophagus: pathophysiology, incidence, presentation, and treatment in the era of laparoscopic antireflux surgery. Ann Surg 2000; **232**: 630-40.
46) Kalloor GJ, Deshpande AH, Collis JL. Observations on oesophageal length. Thorax 1976; **31**: 284-8.
47) Korn O, Csendes A, Burdiles P, et al. Length of the esophagus in patients with gastroesophageal reflux disease and Barrett's esophagus compared to controls. Surgery 2003; **133**: 358-63.
48) Gozzetti G, Pilotti V, Spangaro M, et al. Pathophysiology and natural history of acquired short esophagus. Surgery 1987; **102**: 507-14.
49) Awad ZT, Mittal SK, Roth TA, et al. Esophageal shortening during the era of laparoscopic surgery. World J Surg 2001; **25**: 558-61.
50) Madan AK, Frantzides CT, Patsavas KL. The myth of the short esophagus. Surg Endosc 2004; **18**: 31-4.
51) Madan AK, Frantzides CT, Patsavas KL. The myth of

the short esophagus. Surg Endosc. 2004; **18**: 31-4. Epub 2003 Nov 21.
52) Orringer MB, Orringer JS. The combined Collis-Nissen operation: early assessment of reflux control. Ann Thorac Surg 1982; **33**: 534-9.
53) Swanstrom LL, Marcus DR, Galloway GQ. Laparoscopic Collis gastroplasty is the treatment of choice for the shortened esophagus. Am J Surg 1996; **171**: 477-81.
54) Johnson AB, Oddsdottir M, Hunter JG. Laparoscopic Collis gastroplasty and Nissen fundoplication. A new technique for the management of esophageal foreshortening. Surg Endosc 1998; **12**: 1055-60.
55) Antoniou SA, Koch OO, Antoniou GA, et al. Mesh-reinforced hiatal hernia repair: a review on the effect on postoperative dysphagia and recurrence. Langenbecks Arch Surg 2012; **397**: 19-27.
56) Herbella FA, Patti MG, Del Grande JC. Hiatal mesh repair--current status. Surg Laparosc Endosc Percutan Tech 2011; **21**: 61-6.
57) Soricelli E, Basso N, Genco A, et al. Long-term results of hiatal hernia mesh repair and antireflux laparoscopic surgery. Surg Endosc 2009; **23**: 2499-504.
58) Targarona EM, Bendahan G, Balague C, et al. Mesh in the hiatus: a controversial issue. Arch Surg 2004; **139**: 1286-96; discussion 1296.
59) Morino M, Giaccone C, Pellegrino L, et al. Laparoscopic management of giant hiatal hernia: factors influencing long-term outcome. Surg Endosc 2006; **20**: 1011-6.
60) Granderath FA, Carlson MA, Champion JK, et al. Prosthetic closure of the esophageal hiatus in large hiatal hernia repair and laparoscopic antireflux surgery. Surg Endosc 2006; **20**: 367-79.
61) Lee YK, James E, Bochkarev V, Vitamvas M, et al. Long-term outcome of cruroplasty reinforcement with human acellular dermal matrix in large paraesophageal hiatal hernia. J Gastrointest Surg 2008; **12**: 811-5.
62) Hashemi M, Peters JH, DeMeester TR, et al. Laparoscopic repair of large type III hiatal hernia: objective followup reveals high recurrence rate. J Am Coll Surg 2000; **190**: 553-60; discussion 560-1.
63) Mehta S, Boddy A, Rhodes M. Review of outcome after laparoscopic paraesophageal hiatal hernia repair. Surg Laparosc Endosc Percutan Tech 2006; **16**: 301-6.
64) Carlson MA, Richards CG, Frantzides CT. Laparoscopic prosthetic reinforcement of hiatal herniorrhaphy. Dig Surg 1999; **16**: 407-10.
65) Frantzides CT, Madan AK, Carlson MA, et al. A prospective, randomized trial of laparoscopic polytetrafluoroethylene (PTFE) patch repair vs simple cruroplasty for large hiatal hernia. Arch Surg 2002; **137**: 649-52.
66) Granderath FA, Schweiger UM, Kamolz T, et al. Laparoscopic Nissen fundoplication with prosthetic hiatal closure reduces postoperative intrathoracic wrap herniation: preliminary results of a prospective randomized functional and clinical study. Arch Surg 2005; **140**: 40-8.
67) Champion JK, Rock D. Laparoscopic mesh cruroplasty for large paraesophageal hernias. Surg Endosc 2003; **17**: 551-3.
68) Granderath FA, Schweiger UM, Pointner R. Laparoscopic antireflux surgery: tailoring the hiatal closure to the size of hiatal surface area. Surg Endosc 2007; **21**: 542-8.
69) Tatum RP, Shalhub S, Oelschlager BK, et al. Complications of PTFE mesh at the diaphragmatic hiatus. J Gastrointest Surg 2008; **12**: 953-7.
70) Hawasli A, Zonca S. Laparoscopic repair of paraesophageal hiatal hernia. Am Surg 1998; **64**: 703-10.
71) Basso N, De Leo A, Genco A, et al. 360 degrees laparoscopic fundoplication with tension-free hiatoplasty in the treatment of symptomatic gastroesophageal reflux disease. Surg Endosc 2000; **14**: 164-9.
72) Kamolz T, Granderath FA, Bammer T, et al. Dysphagia and quality of life after laparoscopic Nissen fundoplication in patients with and without prosthetic reinforcement of the hiatal crura. Surg Endosc 2002; **16**: 572-7. Epub 2002 Jan 9.
73) Granderath FA, Schweiger UM, Kamolz T, et al. Laparoscopic antireflux surgery with routine mesh-hiatoplasty in the treatment of gastroesophageal reflux disease. J Gastrointest Surg 2002; **6**: 347-53.
74) Casaccia M, Torelli P, Panaro F, et al. Laparoscopic tension-free repair of large paraesophageal hiatal hernias with a composite A-shaped mesh: two-year follow-up. J Laparoendosc Adv Surg Tech A 2005; **15**: 279-84.
75) Gryska PV, Vernon JK. Tension-free repair of hiatal hernia during laparoscopic fundoplication: a ten-year experience. Hernia 2005; **9**: 150-5.
76) Oelschlager BK, Pellegrini CA, Hunter J, et al. Biologic prosthesis reduces recurrence after laparoscopic paraesophageal hernia repair: a multicenter, prospective, randomized trial. Ann Surg 2006; **244**: 481-90.
77) Ringley CD, Bochkarev V, Ahmed SI, et al. Laparoscopic hiatal hernia repair with human acellular dermal matrix patch: our initial experience. Am J Surg 2006; **192**: 767-72.
78) Turkcapar A, Kepenekci I, Mahmoud H, et al. Laparoscopic fundoplication with prosthetic hiatal closure. World J Surg 2007; **31**: 2169-76.
79) Jacobs M, Gomez E, Plasencia G, et al. Use of surgisis mesh in laparoscopic repair of hiatal hernias. Surg Laparosc Endosc Percutan Tech 2007; **17**: 365-8.
80) Lubezky N, Sagie B, Keidar A, et al. Prosthetic mesh repair of large and recurrent diaphragmatic hernias. Surg Endosc 2007; **21**: 737-41.
81) Zaninotto G, Portale G, Costantini M, et al. Objective follow-up after laparoscopic repair of large type III hiatal hernia. Assessment of safety and durability. World J Surg 2007; **31**: 2177-83.
82) Granderath FA, Granderath UM, Pointner R. Laparoscopic revisional fundoplication with circular hiatal mesh prosthesis: the long-term results. World J Surg

2008; **32**: 999-1007.
83) Hazebroek EJ, Ng A, Yong DH, et al. Clinical evaluation of laparoscopic repair of large hiatal hernias with TiMesh. ANZ J Surg 2008; **78**: 914-7.
84) Müller-Stich BP, Linke GR, Borovicka J, et al. Laparoscopic mesh-augmented hiatoplasty as a treatment of gastroesophageal reflux disease and hiatal herniaspreliminary clinical and functional results of a prospective case series. Am J Surg 2008; **195**: 749-56.
85) Varga G, Cseke L, Kalmar K, et al. Laparoscopic repair of large hiatal hernia with teres ligament: midterm follow-up: a new surgical procedure. Surg Endosc 2008; **22**: 881-4.
86) Zehetner J, Lipham JC, Ayazi S, et al. A simplified technique for intrathoracic stomach repair: laparoscopic fundoplication with Vicryl mesh and BioGlue crural reinforcement. Surg Endosc 2010; **24**: 675-9.
87) Zehetner J, Lipham JC, Ayazi S, et al. A simplified technique for intrathoracic stomach repair: laparoscopic fundoplication with Vicryl mesh and BioGlue crural reinforcement. Surg Endosc 2010; **24**: 675-9.
88) Treacy PJ, Jamieson GG. An approach to the management of para-oesophageal hiatus hernias. Aust N Z J Surg 1987; **57**: 813-7.
89) Pearson FG, Cooper JD, Ilves R, et al. Massive hiatal hernia with incarceration: a report of 53 cases. Ann Thorac Surg 1983; **35**: 45-51.
90) Williamson WA, Ellis FH, Streitz JM, et al. Paraesophageal hiatal hernia: is an antireflux procedure necessary? Ann Thorac Surg 1993; **56**: 447-51; discussion 451-2.
91) Morris-Stiff G, Hassn A. Laparoscopic paraoesophageal hernia repair: fundoplication is not usually indicated. Hernia 2008; **12**: 299-302.
92) Wolf PS, Oelschlager BK. Laparoscopic paraesophageal hernia repair. Adv Surg 2007; **41**: 199-210.
93) Ellis FH Jr, Crozier RE, Shea JA. Paraesophageal hiatus hernia. Arch Surg. 1986; **121**: 416-20.
94) Braslow L. Transverse gastropexy vs Stamm gastrostomy in hiatal hernia. Arch Surg 1987; **122**: 851.