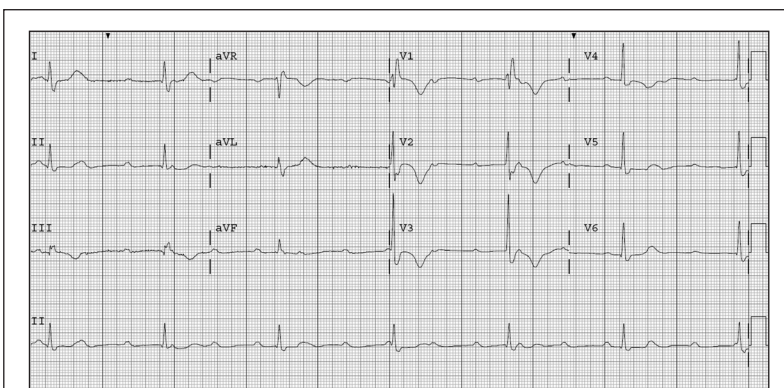


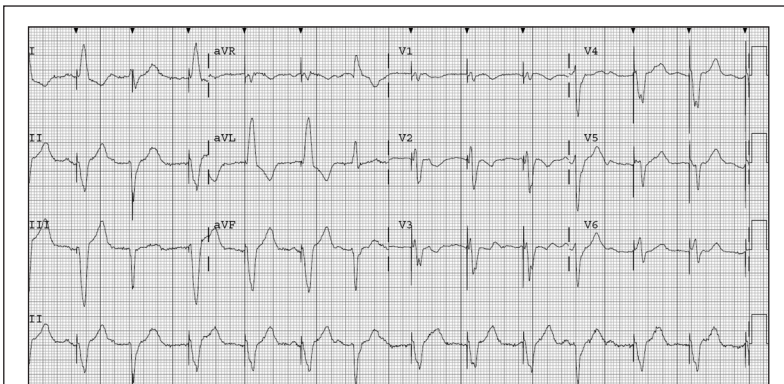
# ECG Diagnosis: Complete Heart Block

Joel T Levis, MD, PhD, FACEP, FAAEM



**Figure 1. 12-lead ECG from a woman, age 77 years, following a syncopal episode**

Demonstrates complete atrioventricular (AV) dissociation with a ventricular rate of 32 beats/minute and a right bundle branch block.



**Figure 2. 12-lead ECG from same patient following insertion of a transvenous pacemaker**

Demonstrates ventricular-paced complexes (pacer spikes before every QRS complex) with a ventricular rate of 78 beats/minute.

Third-degree atrioventricular (AV) block (also referred to as complete heart block) is the complete dissociation of the atria and the ventricles.<sup>1</sup> Third-degree AV block exists when more P waves than QRS complexes exist and no relationship (no conduction) exists between them.<sup>2</sup> The escape rhythm may arise within the AV node (resulting in a narrow QRS complex), or lower in the conduction system (producing a wide QRS complex). The ventricular rate (pulse) varies from 30-40 beats/minute.<sup>2</sup> Characteristically in third-degree AV block, the atrial rate is faster than the ventricular rate (60-100 beats/minute) presumably in response to the hemodynamic consequences of the block. Complete heart block complicates 10% of acute myocardial infarctions (AMI) and represents the most frequent unstable bradydysrhythmia encountered in the patient with AMI.<sup>3</sup> In most cases of persistent third-degree AV block, permanent pacing is required.<sup>1,2</sup> Treatment with atropine often fails to improve the ventricular rate, as vagal stimulation of the AV node is not thought to be the cause of this finding.<sup>1</sup> ❖

## References

1. Abraham M, Bond MC. Chapter 32: What are the electrocardiographic indications for temporary pacing? In: Brady WJ, Truweit JD, (eds). Critical decisions in emergency medicine and acute electrocardiography. West Sussex, UK: Wiley-Blackwell, 2007. p 281-2.
2. Budzikowski AS, Corsello AC, Daubert JP, et al. Third-degree atrioventricular block [monograph on the Internet]. New York: MedScape Reference; updated 2009 Jun 17 [cited 2011 Mar 6]. Available from: <http://emedicine.medscape.com/article/162007>.
3. Swart G, Brady WJ, DeBehnke DJ, Ma OJ, Aufderheide TP. Acute myocardial infarction complicated by hemodynamically unstable bradyarrhythmia: prehospital and ED treatment with atropine. Am J Emerg Med 1999 Nov;17(7):647-52.