

Potential role of metalloproteinase inhibitors from radiation-sterilized amnion dressings in the healing of venous leg ulcers

MAŁGORZATA LITWINIUK¹, BARBARA BIKOWSKA¹, JUSTYNA NIDERLA-BIELIŃSKA¹, JAROSŁAW JÓŹWIAK¹, ARTUR KAMIŃSKI², PIOTR SKOPIŃSKI^{1,3} and TOMASZ GRZELA^{1,4}

Departments of ¹Histology and Embryology, and ²Transplantology and Central Tissue Bank; ³2nd Department of Ophthalmology, Warsaw Medical University; ⁴Centrum Flebologii, Warsaw, Poland

Received February 15, 2012; Accepted June 15, 2012

DOI: 10.3892/mmr.2012.983

Abstract. Chronic wounds are a significant socio-economic problem, thus, the improvement of the effectiveness of their treatment is an important objective for public health strategies. The predominant stage of the chronic wound is the inflammatory reaction which is associated with the damage of tissues, possibly due to the excessive secretion and activation of matrix metalloproteinases (MMPs). Several reports have suggested that amnion dressing inhibits tissue destruction and accelerates wound healing. Our recent study revealed that sterilized amnion stimulates keratinocyte proliferation *in vitro*, while the present study focused on the clinical application of radiation-sterilized amnion in chronic venous leg ulcers and aimed to explain the possible mechanism of its *in vivo* action. The study involved 25 individuals suffering from venous leg ulceration with a surface area of 10-100 cm² and a healing rate below 10% per week, as verified during a 2-week screening period. The effectiveness of the amnion dressing was estimated following 4 weeks of treatment. The wound assessment, based on a modified Bates-Jensen Questionnaire, revealed a good and satisfactory response to the treatment in 23 of the 25 patients. The measurement of MMP-2 and MMP-9 activities in wound exudates revealed a decrease in activity in response to amnion application. This effect resulted from the presence of the potent MMP inhibitors, tissue inhibitor of metalloproteinases-1 (TIMP-1), type-1 plasminogen activator inhibitor (PAI-1) and thrombospondin-1 (TSP-1) in the amnion dressings, as shown by real-time fluorescence zymography and protein microarrays. Thus, unlike modern synthetic dressing materials, radiation-sterilized amnion dressings may have a multidirectional beneficial effect on chronic wounds.

Introduction

The chronic venous leg ulcer (CVLU) is a severe complication of venous insufficiency that is common worldwide. Besides the significant social and economical load, CVLU is currently recognized as a serious public health problem that affects 5-8% of individuals above the age of 65 years (1). Therefore, the improvement of the effectiveness of chronic leg ulceration treatment is of great importance.

CVLU is characterized by a chronic inflammatory reaction that involves the wound bed with surrounding skin and subcutaneous tissue. Chronic inflammation involves an incessant recruitment and activation of immune cells that is associated with the secretion of various mediators of inflammation, including cytokines, phospholipid metabolites, endogenous amines, free radicals and proteolytic enzymes, particularly matrix metalloproteinases (MMPs). They may all contribute to the extensive destruction of affected tissues but may also impair the process of healing (2,3). Therefore, it is clear that the shift of balance between the damage and healing of tissue towards the stimulation of repair should be considered as a key target for the successful treatment of CVLU. Notably, several studies as well as our recent one, suggest that an attractive solution to this issue may be the use of biological dressings prepared from the amniotic membrane (4,5).

The amnion is the innermost layer of the fetal membranes that surround the amniotic cavity and protect the embryo. It is covered by cuboidal epithelial cells, which produce numerous factors that may promote cell proliferation and/or migration. The amniotic membrane contains large amounts of hyaluronan polymer, which is known to accelerate the regeneration of damaged tissue and thus may facilitate wound healing (6). Therefore, the amnion is used as a dressing material, mainly in ocular surgery, but also as a substitute for pleura and pericardium, and in severe skin burns treatment. As mentioned previously, the amniotic membrane has also been used in the treatment of venous ulceration.

The use of fresh amnion is limited by its availability. Due to the possible biohazard it should be subjected to time-consuming microbiological tests, which are also associated with the serological screening of donors. Therefore,

Correspondence to: Dr Tomasz Grzela, Department of Histology and Embryology, Warsaw Medical University, Chałubińskiego 5, 02-004 Warsaw, Poland
E-mail: tgrzela@ib.amwaw.edu.pl; tomekgrzela@gmail.com

Key words: venous leg ulcer, metalloproteinase inhibitor, matrix metalloproteinase, amniotic dressing

various procedures for the preparation and sterilization of amnion have been developed. This processing may affect the biological properties of the amnion dressing and impair its clinical usefulness (7,8). However, findings of our recent study have shown that irradiation-sterilized, deep frozen amniotic membrane retained significant biological activity and effectively stimulated the proliferation of HaCaT keratinocytes *in vitro* (5). The aim of the present study was to verify this finding clinically. Thus, we assessed whether radiation-sterilized amnion dressing was able to improve the healing of hard-to-treat venous leg ulcers. Furthermore, we attempted to explain the possible mechanism of its action.

Materials and methods

Patients. The study involved 25 patients (16 women and 9 men, mean age 76.3±12 years) with CVLU (C6 according to the CEAP classification), attending the outpatient phlebology clinic (Centrum Flebologii, Warsaw, Poland).

Inclusion in the clinical experiment required the presence of a chronic wound (for a period of >6 months) with a surface area of 10-100 cm², with evident venous insufficiency etiology, further confirmed by a Duplex-Doppler ultrasound examination, with delayed healing (healing rate <10%/week) regardless of at least 2 weeks of treatment (screening period) using a hydrocolloid dressing (Granuflex Extra Thin; ConvaTec) and effective compression with short-stretch bandages (Pütterbinde; Hartmann). The exclusion criteria comprised evident signs of wound infection (odorous, purulent exudates, wound necrosis and significant pain), active deep vein thrombosis, leg ischemia with ankle/brachial index <0.8, poor tolerance of compression, pregnancy, diabetes and other systemic diseases (particularly significant heart insufficiency) in unstable stage and malignancy.

All individuals gave their informed consent to participate in the study, which was approved by the local ethics committee.

Amnion dressing application. The amniotic membrane specimens were obtained from the National Center of Tissue and Cell Banking, at the Center of Biostructure of the Medical University of Warsaw. The entire preparation procedure, including epidemiological screening and sterilization by irradiation with an accelerated electron beam, has been described in detail elsewhere (9). The dressings were stored at -70°C until use.

The amnion specimens were thawed immediately prior to use, applied directly onto the wound bed and covered by a secondary hydrocolloid dressing, followed by standard compression with short-stretch bandages. The dressings were changed once per week, however, in case of large exudates the outer wet dressing layers were changed when necessary.

The clinical assessment of wounds was carried out 2 weeks (-14 days) prior to the first application of the amnion dressing, at the time of its first application (day 0±1) and then following 4 weeks (day 28±1) of treatment. The overall wound condition, including wound edges, granular tissue formation, amount and appearance of exudate, symptoms of inflammation and epithelialization rate, was assessed using a modified Bates-Jensen questionnaire (B-JQ), with the maximal score (75 points) corresponding to the worst wound condition and the minimal

score (15 points) corresponding to a completely healed wound. The wounds were photographed and their surfaces were measured using the public domain image processing software, ImageJ, developed at the National Institutes of Health, USA (<http://rsbweb.nih.gov/ij>).

MMP assessment. Samples of wound exudates were collected on days 0 and 28, and centrifuged at 10,000 rpm. Supernatants were used for quantitative gelatin/SDS zymography to assess the activities of MMP-2 and MMP-9, according to the protocol described in detail elsewhere (10).

To verify the putative effect of the amniotic dressing on MMP activity, serial dilutions of amnion extracts were incubated for 15 min with 50 ng/ml human recombinant MMP-2 or MMP-9 (purchased from R&D Systems, Minneapolis, MN, USA), which, prior to use, were pre-activated with a 1 mM solution of 4-aminophenylmercuric acetate (Sigma-Aldrich, St. Louis, MO, USA), according to the instructions provided by the manufacturer. A fluorescein-labeled gelatin substrate (EnzCheck Gelatinase assay; Invitrogen/Molecular Probes, Eugene, OR, USA) was then added to a final concentration of 12 µg/ml and the mixture was incubated for 120 min at 37°C. The fluorescence of the sample was continuously monitored using a ABI PRISM 7500 Real-Time PCR device (Applied Biosystems, Foster City, CA, USA). The fluorescent substrate alone was used as a negative control, whereas pre-activated MMP-2 and MMP-9 with the fluorescent substrate but without amnion extracts, served as the 100% enzyme activity reference.

Protein array. The proteomic analysis of three randomly selected amnion specimens was performed using the Human Angiogenesis Proteome Profiler (R&D Systems), according to the detailed instructions provided by the manufacturer. Standardized amnion extracts (200 µl) were prepared as described elsewhere (5), then mixed with a cocktail of biotinylated detection antibodies and incubated overnight at 8°C, with nitrocellulose membranes spotted with the respective capture antibodies. Membranes were washed and incubated with streptavidin-horseradish peroxidase conjugate, followed by chemiluminescence detection reagent (ImmunoCruz Luminol Reagent, Santa Cruz Biotechnology, Inc., Santa Cruz, CA, USA). The membranes were then exposed to an X-ray film (Agfa-Geavert, Mortsel, Belgium) for 15-30 min, to achieve an optimal signal intensity. The film was scanned and the optical density of each analyzed spot was assessed using GelWorks 2D software (UVP, Cambridge, UK).

Results

Clinical assessment. Despite a poor response to standard treatment in the screening period, the application of amnion improved the overall healing rate (Fig. 1). When compared with the wound condition prior to the application of amnion, the most notable differences in the amnion-treated wounds concerned stimulation of granular tissue formation, less pronounced irritation of the skin surrounding the wound by the ulcer exudates and faster re-epithelialization (Fig. 2).

The use of a multi-factor assessment B-JQ score, allowed a more reliable evaluation of the effectiveness of the treatment

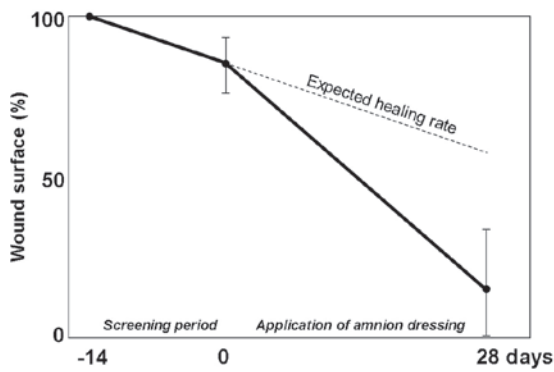


Figure 1. Mean wound healing rate expressed as a percentage of wound surface (\pm SD), where the initial wound surface corresponds to 100%. The dashed line shows the expected healing rate - a hypothetical wound surface reduction that would occur if the wound was not modified by the application of amnion dressing, extrapolated from that in the screening period.

and also enabled the comparison of various individuals. With an arbitrary threshold corresponding to double the median B-JQ score change observed in a screening period, it was found that almost half of the patients (13 of 25) had a good response to the treatment (B-JQ score change/week >3.5). A satisfactory response was observed in another 10 individuals (B-JQ score change/week 1.7-3.5), whereas the 2 remaining patients responded poorly to the treatment, with a B-JQ score change/week of <1.7 , which was similar to that during the screening period (Fig. 3).

MMP assessment. The quantitative SDS/substrate zymography revealed significant activities of MMP-2 and MMP-9 in all analyzed exudate samples. It was observed that the activities of the MMPs on day 0 were relatively high, with median levels of 251 ± 101 ng/ml for MMP-2 and 293 ± 96 ng/ml for MMP-9. The concentrations, measured on day 28, were lower than those on day 0 (median 178 ± 84 and 219 ± 113 ng/ml, respectively). Moreover, this difference appeared to be statistically significant (Fig. 4).

The MMP inhibition assay with fluorescein-labeled gelatin, human amniotic membrane extracts and pre-activated recombinant MMPs, revealed that the amnion extracts exhibited an inhibitory effect on MMP-2 and MMP-9 activities in a dilution-dependent manner. The dilution of the amniotic extract for 50% inhibitory activity of each MMP was calculated and was 0.4 for MMP-2 and 0.32 for MMP-9 (Fig. 5).

Protein array. The assessment of the amnion specimens using protein microarray technology confirmed the presence of various cell growth regulators. In addition, relatively large quantities of the tissue inhibitor of metalloproteinases (TIMP)-1 and the type-1 plasminogen activator inhibitor (PAI-1 or serpin E1) and less pronounced amounts of another potent MMP inhibitor, thrombospondin (TSP)-1, were detected (Fig. 6).

Discussion

Wound healing is a complex biological process, comprising a series of consecutive events that aim to repair injured tissue. It has been shown that any disturbances in the sequence or

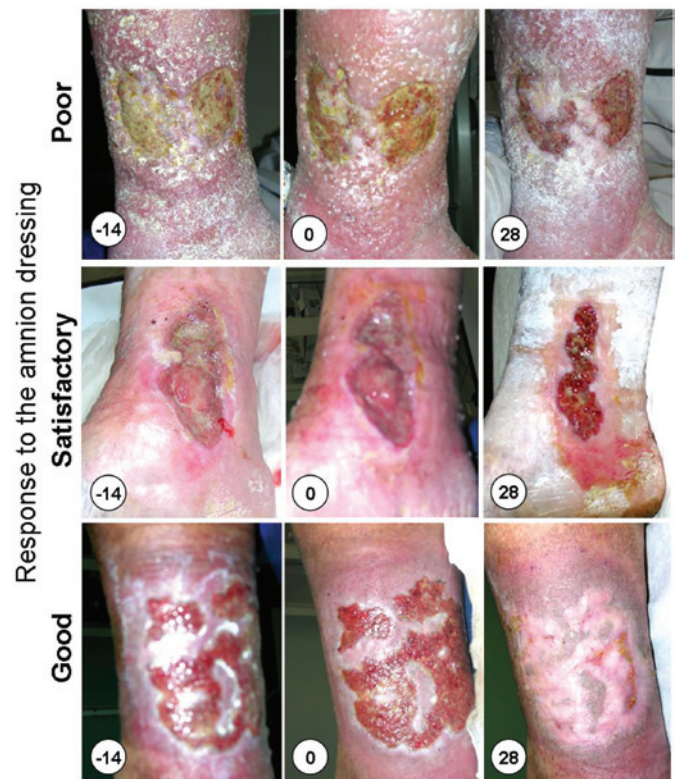


Figure 2. Wound images for representative patients from three groups corresponding to various treatment responses. The numbers indicate the day of the treatment. Day -14, start of screening period; day 0, start of amnion application; day 28, end of treatment.

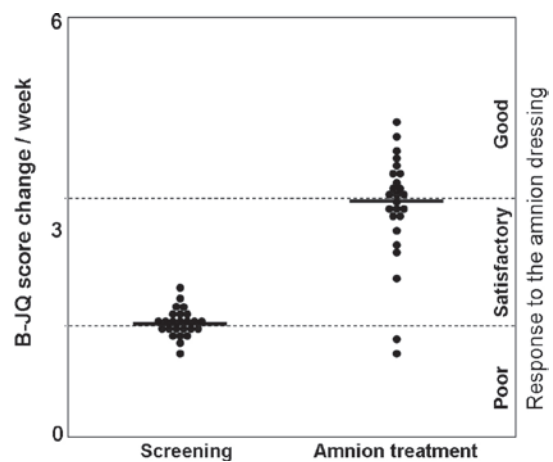


Figure 3. Results of the B-JQ score change/week calculated for the screening period (day 0) and for amnion treatment (day 28). Each dot represents 1 patient. The solid lines correspond to mean values, whereas dashed lines show median values. The median for the amnion treatment period is double the median for the screening period, which was considered as a threshold to assess the response to treatment. B-JQ, Bates-Jensen Questionnaire.

duration of these events may result in the persistence of the wound with a predominant chronic inflammatory reaction stage (2,3). This result may be due to colonization by bacteria, oxidative stress associated with repetitive ischemia/reperfusion injury and/or impaired tissue response to the stress conditions. Therefore, efforts have been undertaken to improve the effectiveness of wound healing. These concern

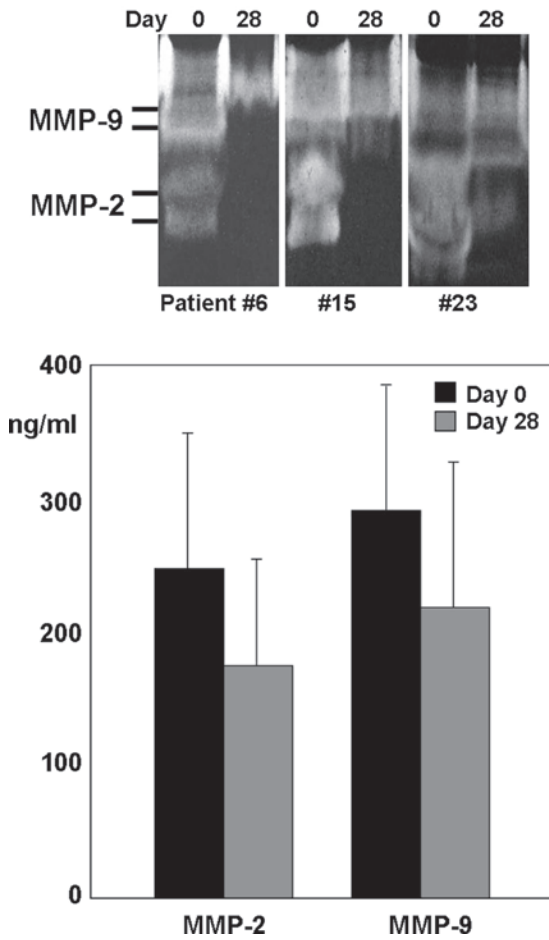


Figure 4. Results of the gelatin/SDS zymography of wound exudates collected at the beginning (day 0) and following 4 weeks of amnion treatment (day 28). The upper panel shows zymograms of three randomly selected individuals; the graph in the lower panel shows the mean values (\pm SD) of the gelatinolytic activity for MMP-2 and MMP-9, measured in wound exudates prior to (black bar) and following amnion application (grey bar). MMP, matrix metalloproteinase.

the elimination of detrimental factors (e.g., bacterial load, tissue ischemia or venous stasis), an attenuation of destructive inflammatory hyper-response and/or induction and promotion of cell proliferation, all of which may be achieved by providing a supporting dressing and/or by exogenous stimulation with certain growth factors. An attractive combination of both, a supporting scaffold for cell growth (11,12) and a rich source of various growth and differentiation factors, could be the human amniotic membrane (5,7). As reported by various authors, even preserved human amniotic membrane contains a number of growth factors, including EGF, TGF α , TGF β -1 and -2, KGF, HGF, bFGF, ANG and VEGF. These factors may enhance epithelialization and suppress the inflammatory reaction, which is beneficial for wound healing (4,8). In addition to the aforementioned cytokines, high molecular weight hyaluronan, a significant component of the amniotic membrane dressing, has also revealed potent anti-inflammatory properties (5,11).

Recent studies have shown that an excessive expression and hyperactivation of MMPs, particularly MMP-2 and MMP-9, may be important in the pathomechanism of delayed wound healing. Although the two MMPs are crucial for the remodeling of extracellular matrix and effective wound healing, when

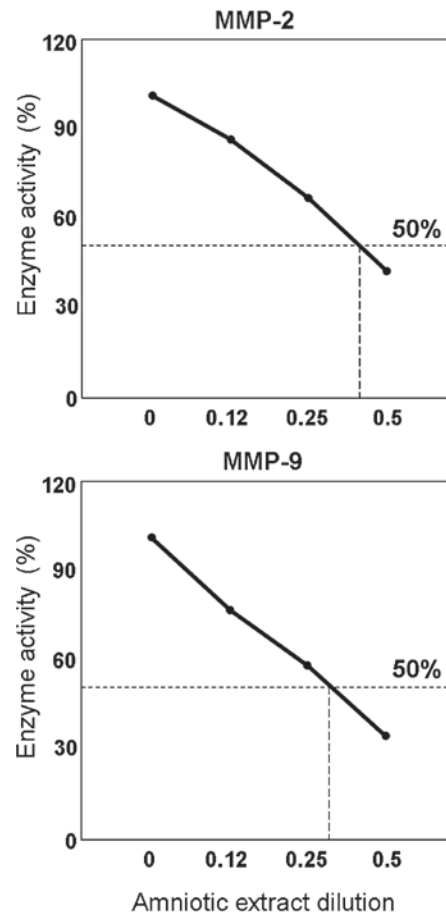


Figure 5. Results of the fluorescence zymography/MMP inhibition assay with amniotic extract samples in serial dilutions. Curves show the enzymatic activity of recombinant MMP-2 and MMP-9, pre-activated with APMA, in relation to the dilution of the amniotic extract. The units of extract dilution are the decimal fraction of the extract dilution, (0.5, 1 vol. amniotic extract in 2 vol. final reaction mixture and 0.25, 1 vol. amniotic extract in 4 vol. final reaction mixture). MMP, matrix metalloproteinase; APMA, 4-aminophenyl-mercuric acetate.

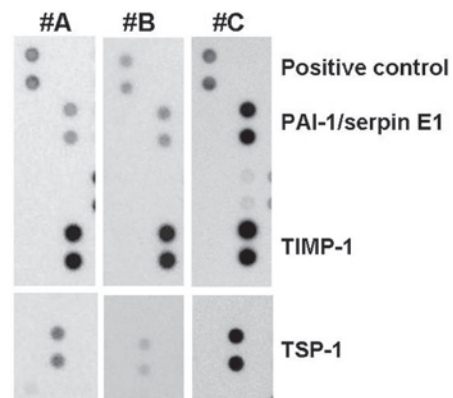


Figure 6. Results of the analysis of the amnion membrane samples of three donors, #A, #B and #C, by protein array (Human Angiogenesis Protein Profiler). Each protein is represented in duplicate by dark-grey dots. The densities of the dots correspond to the amount of protein. PAI-1, type-1 plasminogen activator inhibitor; TIMP-1, tissue inhibitor of metalloproteinases-1; TSP-1, thrombospondin-1.

overexpressed in affected tissue they act as potent injurious factors (13). It has been shown that increased MMP-9 activity correlates with the severity of the ulcer (14), whereas during

the healing process the levels of MMP-9 in wound fluids decreased relative to those observed in acute wounds (15). Therefore, the stabilization of the wound environment through the inhibition of MMPs may be an alternative option for effective chronic wound management.

In agreement with other reports (14,16), we found that chronic wound exudates contained significant amounts of MMP-2 and MMP-9. Notably, following 4 weeks of treatment with the amniotic membrane, the MMP activity decreased, as identified by SDS/gelatin zymography. This finding supports the hypothesis that the inhibition/stabilization of MMPs is necessary for wound healing. Moreover, the decrease in MMP activity may further synergize with the previously mentioned beneficial properties of amniotic dressing, including possible immunosuppressive activity of hyaluronan and the stimulatory role of various cytokines. It is plausible that these mechanisms contribute equally to the amniotic-induced wound healing effect.

The results of SDS/gelatin zymography do not allow us to discriminate between primarily active and artificially *in vitro*-activated MMPs. *In vitro* activation may occur during the contact of the latent form of the proenzyme with SDS in the gelatin/polyacrylamide gel (17). Furthermore, the observed difference in the activity of the MMPs, although statistically significant, requires further verification in a larger patient group. The standard SDS/gelatin zymography process does not enable any monitoring of the presumed interaction between MMPs and their inhibitors, therefore the investigation of this issue requires the use of other methods. Thus, to clarify the potent anti-MMP properties of the amniotic dressing, fluorescence real-time zymography was used instead of the SDS/gelatin PAGE method. It was found that amniotic membrane homogenates exerted a strong, dose-dependent, inhibitory effect, directed against the gelatinolytic activities of MMP-2 and MMP-9. The proteome analysis of the amniotic membrane extracts using protein microarray technology revealed the presence of significant amounts of three potent protease inhibitors, TIMP-1, PAI-1 and TSP-1, in all assessed samples. Although TIMP-1, a widely distributed natural inhibitor for most of the known metalloproteinases (18), is the best known, it is plausible that the remaining two factors may also contribute to the observed inhibition of MMPs.

PAI-1/Serpin E1, primarily produced by endothelial cells, is the principal inhibitor of two serine proteases, tissue plasminogen activator (tPA) and urokinase (uPA), and is therefore a suppressor of fibrinolysis. Studies focusing on the mechanism of cancer metastasis have shown that PAI-1 may also exhibit an inhibitory activity against MMPs (19,20).

TSP-1 was originally described as a natural inhibitor of neovascularization. It has been shown to control angiogenesis, particularly endothelial cell adhesion, motility and growth, in both a positive and negative manner. Depending on the particular domain involved in its action, TSP-1 interacts with a number of cell receptors, adhesion molecules and proteases. TSP-1 has also been postulated to inhibit MMP-2 and MMP-9 activation (21).

It is noteworthy that the protein array has revealed certain differences in the amounts of TSP-1 and PAI-1 between amniotic samples prepared from various donations. It is plausible that

this is one of the explanations for the difference observed in healing responses to the amniotic dressing. However, to clarify this issue it would be necessary to screen amniotic dressing samples, e.g., using a protein array system, prior to their clinical application.

Taken together, our previous study and the present study have demonstrated that radiation-sterilized amniotic membrane dressing exerts a beneficial effect on chronic wounds. In addition to the growth and differentiation factor-dependent stimulation of wound healing or the immunosuppressive properties of high molecular weight hyaluronan, amniotic dressings may also restore the tissue degradation/regeneration homeostasis by inhibiting MMPs. Therefore, despite the large number of modern dressing materials developed thus far, there is no synthetic dressing with such complex and multidirectional activities as have been revealed for the amniotic membrane.

References

- MacKenzie RK, Brown DA, Allan PL, Bradbury AW and Ruckley CV: A comparison of patients who developed venous leg ulceration before and after their 50th birthday. *Eur J Vasc Endovasc Surg* 26: 176-178, 2003.
- Mustoe TA, O'Shaughnessy K and Kloeters O: Chronic wound pathogenesis and current treatment strategies: a unifying hypothesis. *Plast Reconstr Surg* 117: S35-S41, 2006.
- Litwiniuk M, Grzela T and Brawura-Biskupski-Samaha R: Clinical Immunology: Chronic inflammation in venous leg ulcer - problems and perspectives. *Centr Eur J Immunol* 34: 247-251, 2009.
- Tauzin H, Humbert P, Viennet C, Saas P and Muret P: Human amniotic membrane in the management of chronic venous leg ulcers. *Ann Dermatol Venereol* 138: 572-579, 2011.
- Litwiniuk M, Bikowska B, Niderla-Bielińska J, Józwiak J, Kamiński A, Skopiński P and Grzela T: High molecular weight hyaluronan and stroma-embedded factors of radiation-sterilized amniotic membrane stimulate proliferation of HaCaT cell line *in vitro*. *Centr Eur J Immunol* 36: 205-211, 2011.
- Jiang D, Liang J and Noble PW: Hyaluronan in tissue injury and repair. *Ann Rev Cell Dev Biol* 23: 435-461, 2007.
- Wolbank S, Hildner F, Redl H, van Griensven M, Gabriel C and Hennerbichler S: Impact of human amniotic membrane preparation on release of angiogenic factors. *J Tissue Eng Regen Med* 3: 651-654, 2009.
- Russo A, Bonci P and Bonci P: The effects of different preservation processes on the total protein and growth factor content in a new biological product developed from human amniotic membrane. *Cell Tissue Bank* 13: 353-361, 2012.
- Tyszkiewicz JT, Uhrynowska-Tyszkiewicz IA, Kaminski A and Dziedzic-Gocławska A: Amnion allografts prepared in the Central Tissue Bank in Warsaw. *Ann Transplant* 4: 85-90, 1999.
- Grzela T, Brawura-Biskupski-Samaha R, Jelenska MM and Szmidi J: Low molecular weight heparin treatment decreases MMP-9 plasma activity in patients with abdominal aortic aneurysm. *Eur J Vasc Endovasc Surg* 35: 159-161, 2008.
- Niknejad H, Peirovi H, Jorjani M, Ahmadiani A, Ghanavi J and Seifalian AM: Properties of the amniotic membrane for potential use in tissue engineering. *Eur Cell Mater* 15: 88-99, 2008.
- Chem PL, Baum CL and Arpey CJ: Biologic dressings: current applications and limitations in dermatologic surgery. *Dermatol Surg* 35: 891-906, 2009.
- Bjarnsholt T, Kirketerp-Moller, Jensen P, *et al*: Why chronic wounds will not heal: a novel hypothesis. *Wound Repair Regen* 16: 2-10, 2008.
- Rayment EA, Upton Z and Shooter GK: Increased matrix metalloproteinase-9 (MMP-9) activity observed in chronic wound fluid is related to the clinical severity of the ulcer. *Br J Dermatol* 158: 951-961, 2008.
- Wysocki AB, Kusakabe AO, Chang S and Tuan TL: Temporal expression of urokinase plasminogen activator, plasminogen activator inhibitor and gelatinase-B in chronic wound fluid switches from a chronic to acute wound profile with progression to healing. *Wound Rep Reg* 7: 154-165, 1999.

16. Saito S, Trovato MJ, You R, *et al*: Role of matrix metalloproteinases 1, 2, and 9 and tissue inhibitor of matrix metalloproteinase-1 in chronic venous insufficiency. *J Vasc Surg* 34: 930-938, 2001.
17. Grzela T, Bikowska B and Litwiniuk M: Matrix metalloproteinases in aortic aneurysm - executors or executioners? In: *Etiology, Pathogenesis and Pathophysiology of Aortic Aneurysms and Aneurysm Rupture*. Grundmann R (ed.). Intech Publ, pp25-54, 2011. Available from: <http://www.intechopen.com/articles/show/title/matrix-metalloproteinases-in-aortic-aneurysm-executors-or-executioners->.
18. Fu X, Parks WC and Heinecke JW: Activation and silencing of matrix metalloproteinases. *Semin Cell Dev Biol* 19: 2-13, 2008.
19. Suzuki K, Nakayama H and Doi K: Kinetics of matrix metalloproteinases and their regulatory factors in mercuric chloride-induced tubulointerstitial fibrosis in Brown Norway rats. *Exp Toxic Pathol* 53: 337-343, 2001.
20. Duffy M: The urokinase plasminogen activator system: role in malignancy. *Curr Pharm Des* 10: 39-49, 2004.
21. Bein K and Simons M: Thrombospondin type 1 repeats interact with matrix metalloproteinase 2. Regulation of metalloproteinase activity. *J Biol Chem* 275: 32167-32173, 2000.