

Management Problems in Acute Hydrocephalus After Subarachnoid Hemorrhage

Djo Hasan, MD, Marinus Vermeulen, MD, Eelco F.M. Wijdicks, MD,
Albert Hijdra, MD, and Jan van Gijn, MD

In a consecutive series of 473 patients admitted within 72 hours after a subarachnoid hemorrhage, 91 (19%) had hydrocephalus on the initial computed tomogram. Consciousness was unimpaired in 25 of the 91 (28%). In 11 more patients acute hydrocephalus developed within 1 week after subarachnoid hemorrhage. Thirty-eight (8%) of all 473 patients subsequently showed clinical deterioration because of acute hydrocephalus; 11 of these 38 had fluctuations in the level of consciousness. Of the 66 patients with acute hydrocephalus and impaired consciousness on admission, 26 (39%) spontaneously improved within 24 hours. Ventricular drainage was performed in 32 (31%) of the 102 patients with acute hydrocephalus (7% of all 473 patients). Consciousness improved after ventricular drainage in 25 (78%) of the 32 patients. Ventriculitis developed in 12 of the 24 patients with external drainage, mainly after >3 days of drainage, and in none of the eight patients with an internal shunt. Among the 340 patients with aneurysmal subarachnoid hemorrhage and no long-term tranexamic acid treatment, the frequency of rebleeding in patients with ventricular drainage (43% of 23) was significantly higher than in hydrocephalic patients without drainage (15% of 52 patients; $\chi^2=5.009$, $p=0.025$) and patients without acute hydrocephalus (20% of 265 patients; $\chi^2=5.521$, $p=0.019$). We conclude that spontaneous improvement occurs in half of the patients with acute hydrocephalus and impaired consciousness on admission, which is usually apparent within 24 hours, and that the outcome of patients who need ventricular drainage will improve if rebleeding and infection after insertion of the ventricular drain can be prevented. (*Stroke* 1989;20:747-753)

Acute hydrocephalus after subarachnoid hemorrhage is not uncommon. The frequency depends on the criteria used for the diagnosis and ranges from 9%¹ to 67%.² In a consecutive series of 174 subarachnoid hemorrhage patients admitted within 72 hours after the initial hemorrhage to the University Hospital Rotterdam's Department of Neurology, computed tomography (CT scanning) showed ventricular enlargement (defined as a bicaudate index exceeding the 95th percentile for age) in 20%.³

The decision to treat acute hydrocephalus may be difficult to make for several reasons. First, impaired consciousness on admission may result from either

the impact of initial bleeding or from hydrocephalus. If the impairment of consciousness is caused by hydrocephalus, delay of ventricular drainage could lead to a general decrease in cerebral blood flow, precipitating cerebral ischemia. Second, when the decision to carry out ventricular drainage has been made, the question arises whether this should be done by external drainage or by internal shunting. Early shunting is probably not effective since blood and the high protein content of the cerebrospinal fluid (CSF) may block the shunt.⁴ Furthermore, not all patients require permanent shunting. On the other hand, external ventricular drainage may be accompanied by serious infections.^{5,6} Third, it has been suggested that early ventricular drainage may precipitate rebleeding,^{3,4,6} which could be a reason to postpone drainage until the aneurysm has been clipped.

We describe, from a consecutive series of 473 patients, the management problems of 91 patients with acute hydrocephalus after subarachnoid hemorrhage, as judged on the admission CT scan within 3 days after the initial subarachnoid hemorrhage,

From the Department of Neurology, University Hospital Dijkzigt, Rotterdam (D.H., M.V.), the University Department of Neurology, Utrecht (E.F.M.W., J.v.G.), and the Department of Neurology, Academisch Medisch Centrum, University Hospital, Amsterdam (A.H.), the Netherlands.

Address for correspondence: Djo Hasan, Department of Neurology, University Hospital Dijkzigt Rotterdam, 40 Dr Molewaterplein, 3015 GD Rotterdam, The Netherlands.

Received October 26, 1988; accepted February 1, 1989.

and of 11 patients who developed acute hydrocephalus later, but within 1 week after subarachnoid hemorrhage. In patients with a Glasgow Coma Score⁷ (GCS) of ≤ 12 on admission, ventricular drainage was immediately carried out if the impairment of consciousness was thought to be caused by hydrocephalus. In all other patients and in patients with unimpaired (GCS of 14) or slightly impaired (GCS of 13) consciousness on admission, ventricular drainage was performed only if consciousness deteriorated and if no other cause for this deterioration was found.

We tried to answer the following questions: 1) What is the clinical course in patients with acute hydrocephalus, and what proportion requires ventricular drainage? 2) Does spontaneous improvement occur in patients with acute hydrocephalus and an impaired level of consciousness? 3) Is the frequency of cerebral ischemia increased in patients with acute hydrocephalus? 4) Does early ventricular drainage precipitate rebleeding? and 5) What is the risk of infection in patients treated with external drainage without prophylactic antibiotics?

Subjects and Methods

During a period of 9 years and 5 months (from November 1977 until May 1987) we prospectively studied 473 consecutive patients who fulfilled the following criteria: clinical signs of subarachnoid hemorrhage, CT scan abnormalities suggesting a ruptured aneurysm⁸ or perimesencephalic hemorrhage,⁹ and admission to the Department of Neurology of the University Hospital Rotterdam within 72 hours after subarachnoid hemorrhage. Acute hydrocephalus in 34 of the first 174 patients has been reported previously, with emphasis on the diagnosis and predisposing factors.³

Events were recorded during a period of 28 days after the initial subarachnoid hemorrhage, or until death or surgical treatment of the aneurysm. CT scanning was carried out on admission and was repeated after any clinical deterioration. The level of consciousness was assessed by means of the 14-point Glasgow Coma Scale.⁷ The events were defined as probable delayed cerebral ischemia: gradual development of focal neurologic signs, with or without deterioration in the level of consciousness, without confirmation by a CT scan or an autopsy; definite delayed cerebral ischemia: deterioration of consciousness or development of focal signs, or both, with CT or autopsy confirmation of cerebral infarction; probable rebleeding: sudden deterioration and death, without the possibility of proof by a CT scan or if autopsy was refused; definite rebleeding: sudden deterioration with increased amount of blood on the repeated CT scan or at autopsy when compared with a previous CT scan; acute hydrocephalus: bicaudate index measured on the initial CT scan or on a repeated CT scan within 1 week after the initial subarachnoid hemorrhage exceeded the normal upper limit (95th percentile) for age (< 36

years of age, 0.16; 36–45 years, 0.17; 46–55 years, 0.18; 56–65 years, 0.19; 66–75 years, 0.20; and 76–85 years, 0.21^{3,10,11}); and deterioration from hydrocephalus: deterioration of consciousness with no cause other than hydrocephalus, confirmed by repeated CT scanning (relative bicaudate index [patient's bicaudate index divided by the normal upper limit for age] of > 1).

From November 1977 until January 1983 the patients were treated with tranexamic acid or placebo during a period of 28 days after admission or until aneurysm surgery (long-term tranexamic acid).¹² From January 1983 until March 1986 the patients did not receive tranexamic acid, and from April 1986 until May 1987 tranexamic acid was given during the first 4 days after admission (short-term tranexamic acid).

Until December 1982 the daily fluid intake was between 1.5 and 2 l and the patients were treated with fluid restriction ($< 1,000$ ml/24 hr) in case of hyponatremia, defined as a sodium level of ≤ 134 mmol/l on at least 2 consecutive days.¹³ From January 1983 onward the daily fluid intake was at least 3 l in all patients, and fluid restriction and diuretic medication after admission were avoided. Unless the patient was on antihypertensive medications on admission, this treatment was not given. When signs of cerebral ischemia developed, extra fluid in the form of albumin was administered.

Cerebral angiography and aneurysm surgery were performed depending on the patient's clinical condition. Aneurysm surgery was usually planned on Day 12.

There was a 3-month follow-up of the survivors, including those who underwent aneurysm surgery. The outcome was assessed according to the 5-point Glasgow Outcome Scale.¹⁴

The fourfold tables were analyzed with Yates' corrected χ^2 test. If the expected number in any cell was < 5 , the fourfold tables were analyzed with Fisher's exact probability test (two-sided).

Results

Acute hydrocephalus was measured on the CT scans on admission in 91 (19%) of the 473 patients. Of these 91 patients, 25 (28%) had no impairment of consciousness on admission (GCS of 14), 13 (14%) had a GCS of 13, and in the remaining 53 (58%) the GCS was ≤ 12 . The degree of ventricular enlargement was not clearly different among these groups (Figure 1). In another 11 patients (3% of the 382 patients without hydrocephalus on admission), ventricular enlargement was found on a repeat CT scan, after clinical deterioration had developed, within 1 week after subarachnoid hemorrhage.

Angiography was negative in nine of the 91 patients (10%) with acute hydrocephalus on admission, in one of the 11 patients who developed acute hydrocephalus within 1 week after subarachnoid hemorrhage, and in 36 of the remaining 371 patients. The proportion of ventricular enlargement on the

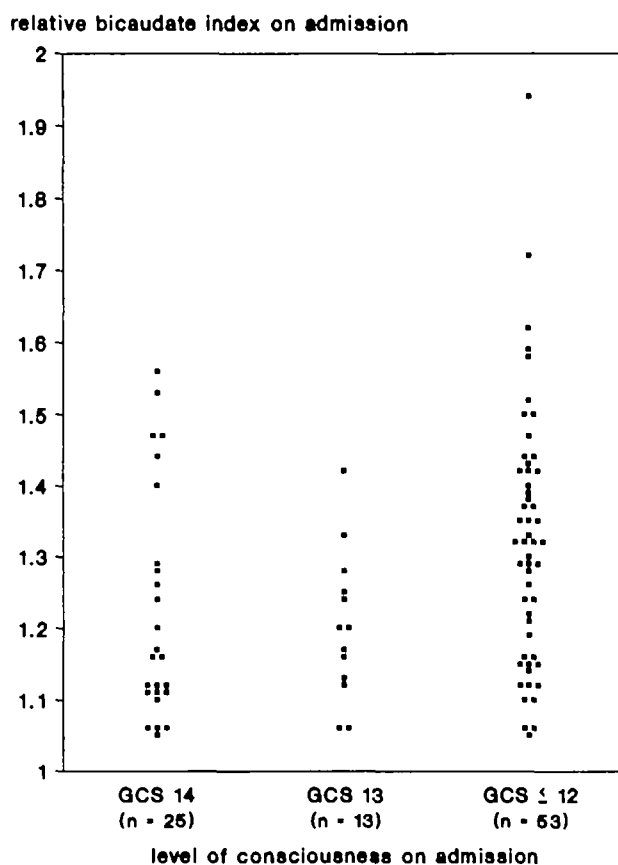


FIGURE 1. Scatter plot of relative bicaudate index (patient's bicaudate index divided by normal upper limit for age) on admission by level of consciousness on admission for 91 patients with acute hydrocephalus after subarachnoid hemorrhage. GCS, Glasgow Coma Score.

initial CT scan in patients with a negative angiogram is 20% (nine of 46 patients), which is similar to that in all 473 patients.

The clinical course of the 91 patients with ventricular enlargement on the initial CT scan and of the 11 patients who developed hydrocephalus within the first week after subarachnoid hemorrhage is shown in Figure 2.

Clinical deterioration from hydrocephalus occurred in 38 (37%) of the 102 patients, and fluctuations of the level of consciousness occurred in 11 of the 38. In three patients, the deterioration was of sudden onset, defined as <5 minutes, mimicking a rebleed; in the remaining 35 patients, the onset was gradual (at least hours).

There were also 38 patients with an unimpaired (GCS of 14; 25 patients) or a slightly impaired (GCS of 13; 13 patients) level of consciousness, of whom 28 (74%) did not show deterioration from acute hydrocephalus or fluctuations of the level of consciousness, despite ventricular enlargement on admission (Figure 2, A and B).

Of the 102 patients with acute hydrocephalus, 32 (31%) underwent ventricular drainage (7% of the total group of 473 patients). One of these 32 patients had a negative angiogram. Eight patients received a

primary internal shunt and 24 patients an external ventricular drain. The decision to treat hydrocephalus by external drainage or by internal shunting was influenced mainly by the interval since the initial bleeding. Thus, in only two of the eight patients who had internal shunting was the shunt implanted within 10 days after the hemorrhage compared with 22 of the 24 patients with external drainage. In nine of the 24 patients the external drainage was later replaced by an internal shunt. In 10 patients (Figure 2C), ventricular drainage was not considered because of massive intraventricular hemorrhage. All 10 patients were in a poor clinical condition (GCS of ≤ 8) and all died within 48 hours after admission.

Twenty-five (78%) of the 32 drained patients showed an initial improvement of consciousness after ventriculostomy. In the remaining seven patients ventricular drainage had no such favorable effect. One of these seven patients had been intermittently disoriented from 1 day after subarachnoid hemorrhage; 18 days later this patient remained disoriented for a prolonged period, and an internal shunt was inserted without success. In two patients clinical improvement after ventricular drainage was precluded by the development of definite cerebral ischemia (1 day before drainage in one patient and 5 days after drainage in the other). In two other patients, one did not show an immediate improvement of the clinical condition and the other developed ventriculitis 3 days after ventriculostomy. In both, the external drain was removed 3 days after insertion. This was followed by clinical deterioration and death in both patients, 8 and 25 days after subarachnoid hemorrhage. These two patients had not developed focal signs, and the CT scan showed no abnormalities other than hydrocephalus. Another patient rebled 1 day after the insertion of ventricular drainage and died. The seventh patient developed ventriculitis 2 days after drainage, which was successfully treated with antibiotics. However, this patient remained in a poor clinical condition and died 25 days after subarachnoid hemorrhage.

Twelve (50%) of the 24 externally drained patients, but none of the eight internally drained patients, developed ventriculitis (Figure 3) that was confirmed by positive bacterial cultures of the CSF (*Staphylococcus epidermidis* in most patients). In five (42%) of these 12 patients, the ventricular catheter was removed because of the infection. In one patient, ventriculitis was followed by a lethal septic shock. Two other patients suffered nonfatal deterioration from ventriculitis.

The factors known to affect the risk of rebleeding are long-term tranexamic acid treatment¹² and clipping of the aneurysm. No other factors (including short-term tranexamic acid treatment [unpublished data]) have been reliably identified.¹⁵ The frequency of rebleeding within the first 12 days was compared between groups of patients with aneurysmal subarachnoid hemorrhage with and without long-term

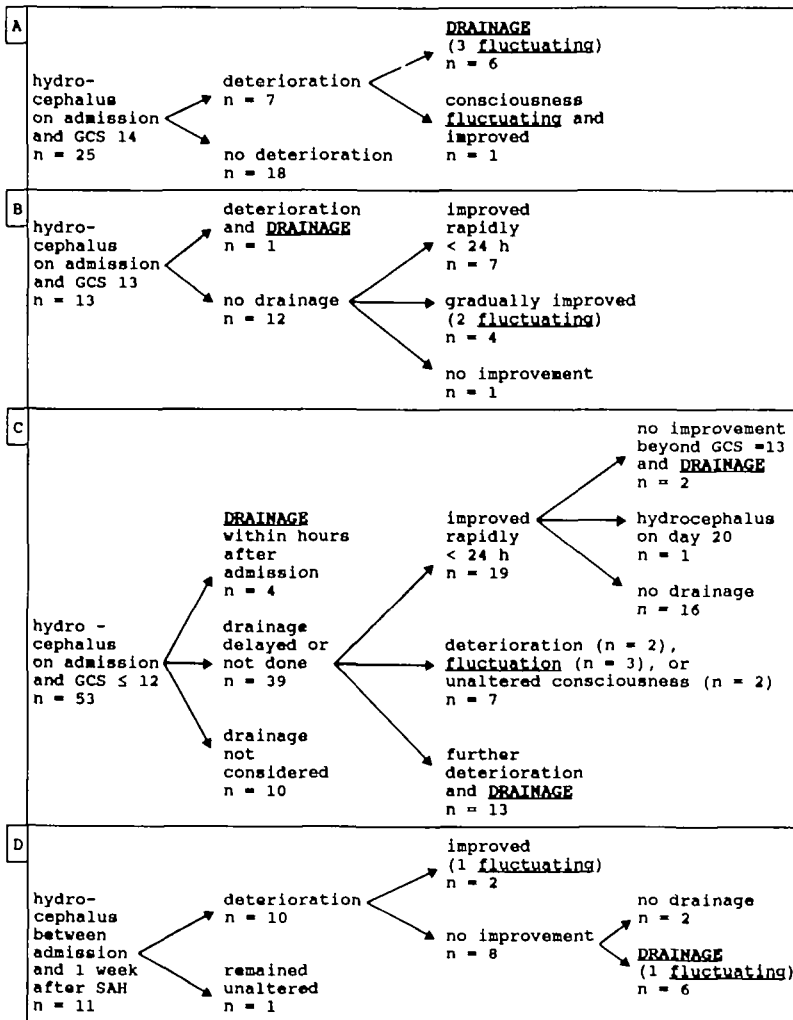


FIGURE 2. Clinical course of 102 patients with hydrocephalus after subarachnoid hemorrhage (SAH). GCS, Glasgow Coma Score.

tranexamic acid treatment (75 rebleeds, 27 ventricular drains; Table 1). In patients without long-term tranexamic acid treatment, the rebleeding rate of patients with ventricular drainage was significantly higher than that in patients without acute hydrocephalus (43% vs. 20%; $\chi^2=5.521, p=0.019$) and in patients with acute hydrocephalus without ventricular drainage (43% vs. 15%; $\chi^2=5.009, p=0.025$). In patients who were treated with long-term tranexamic acid, the numbers were too small for statistical comparison (Table 1).

Among the 427 patients with aneurysmal subarachnoid hemorrhage, delayed cerebral ischemia developed in eight (all definite) (26%) of the 31 hydrocephalic patients with ventricular drainage, in 18 (four probable and 14 definite) (30%) of the 61 hydrocephalic patients without ventricular drainage, and in 63 (19%) of the 335 patients without acute hydrocephalus (the two groups with acute hydrocephalus vs. that without acute hydrocephalus; $\chi^2=3.359, p=0.067$).

Outcome after 3 months in 427 patients with aneurysmal subarachnoid hemorrhage is shown in Table 2. The proportion of patients who were independent 3 months after subarachnoid hemor-

rhage was significantly lower in patients with acute hydrocephalus with or without ventricular drainage than in patients without acute hydrocephalus ($\chi^2=4.637, p=0.031$; Table 2). The higher proportion of patients without drainage dying of the initial hemorrhage was offset by the higher proportion of patients dying of complications after ventricular drainage (Table 2).

Only one of the 10 patients with acute hydrocephalus and negative angiography showed clinical deterioration from acute hydrocephalus and underwent ventricular drainage. Neither rebleeding nor delayed cerebral ischemia was observed, and the outcome of these patients after 3 months was invariably good.

Discussion

In our unselected consecutive series of 473 patients admitted to the Department of Neurology within 72 hours after subarachnoid hemorrhage, CT showed hydrocephalus on admission in 19%. The same frequency of acute hydrocephalus was found in a subgroup of 46 patients with clinical signs and symptoms of subarachnoid hemorrhage and blood in the basal cisterns but a negative angiogram. In

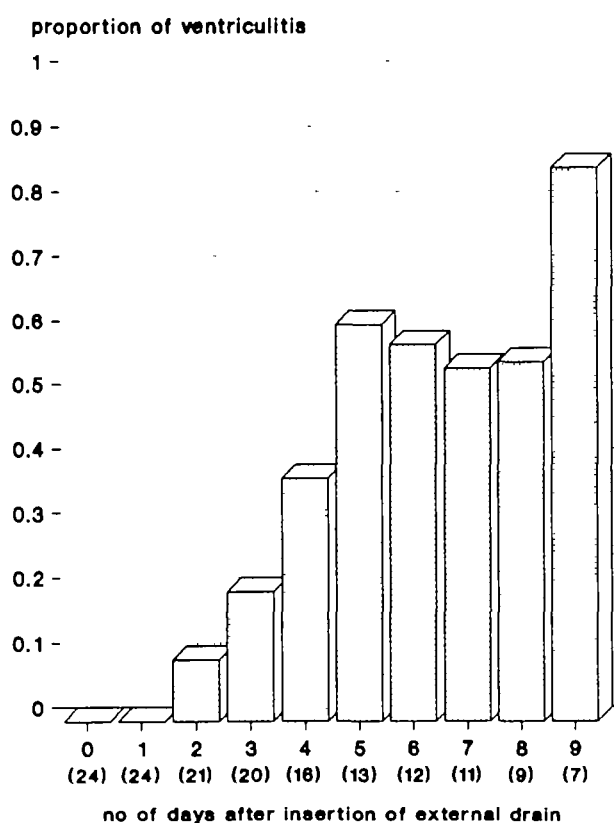


FIGURE 3. Bar graph of proportion of externally drained patients with hydrocephalus after subarachnoid hemorrhage developing ventriculitis over time. Number of patients with external catheter in situ in parentheses.

these 46 patients, acute hydrocephalus was the only cerebral complication.

The risk of deterioration from hydrocephalus between 3 days and 1 week after subarachnoid hemorrhage in patients without ventricular enlargement on admission is low (3%).

Acute hydrocephalus was not symptomatic in all 91 patients with enlarged ventricles on admission. The level of consciousness was unimpaired in 28%, slightly impaired in 14%, and moderately to severely impaired in 58%. There was no relation between the level of consciousness and the degree of enlargement of the ventricles. The majority of the patients with an unimpaired or a slightly impaired level of

consciousness did not subsequently deteriorate from acute hydrocephalus.

Of the 53 patients with a GCS of ≤ 12 , in 19% ventricular drainage was not considered because the ventricles were completely filled with blood; in 8% ventricular drainage was immediately performed. In the remaining 73%, the decision to treat acute hydrocephalus was delayed; half of these patients recovered spontaneously. The degree of ventricular enlargement did not predict spontaneous recovery.

A remarkable feature in the 38 patients with deterioration from acute hydrocephalus was that 29% had fluctuations in their level of consciousness. This made the decision to treat acute hydrocephalus difficult because our policy was to start treatment only if patients deteriorated from acute hydrocephalus or failed to improve; because any improvement was repeatedly considered as the beginning of spontaneous and lasting recovery, ventricular drainage was often delayed, which led in some cases to persistent impairment of consciousness.

In 31% of the 102 patients with acute hydrocephalus on CT (7% of all 473 patients with subarachnoid hemorrhage) ventricular drainage was performed. Ventricular drainage resulted in clinical improvement in 78%, but the outcome after 3 months remained poor.

The most frequent adverse events after ventricular drainage were rebleeding and infection. The risk of rebleeding was significantly increased after ventricular drainage, and in 42% of the 12 externally drained patients developing ventriculitis the drain had to be removed because of infection. After 3 months, the outcome of patients with acute hydrocephalus, with or without ventricular drain, was worse than that of patients without acute hydrocephalus.

The frequency of acute hydrocephalus in our series is in accordance with the findings of one other study⁶ and is different from those of many others.^{2,6,16-25} These differences can be explained by the less reliable criteria used for the diagnosis, by patient selection, and by timing of the investigations.

Remarkably, only little has been written on the indications for ventricular drainage in acute hydrocephalus after subarachnoid hemorrhage. In our series, the decision to treat acute hydrocephalus

TABLE 1. Rebleeds With or Without Long-term Tranexamic Acid Treatment in Relation to Acute Hydrocephalus and Ventricular Drainage in 427 Patients After Aneurysmal Subarachnoid Hemorrhage

Long-term tranexamic acid treatment	Ventricular drainage								
	No						Yes		
	No hydrocephalus			Hydrocephalus			Hydrocephalus		
	Rebleeds			Rebleeds			Rebleeds		
	n	no.	%	n	no.	%	n	no.	%
Yes	70	4	6	13	0	0	4	0	0
No	265	53	20*	52	8	15†	23	10	43

Hydrocephalus within 1 week after subarachnoid hemorrhage; drainage within 12 days after subarachnoid hemorrhage.

*† $p < 0.02$, < 0.03 , respectively, different from hydrocephalus with drainage without long-term tranexamic acid treatment.

TABLE 2. Outcome 3 Months After SAH in Relation to Acute Hydrocephalus in 427 Patients With Aneurysmal SAH

Outcome	Hydrocephalus					
	Yes					
	Ventricular drainage					
	Yes		No		No	
	no.	%	no.	%	no.	%
Dead	17	55	37	60	158	47
Initial SAH	0	0	8	22	35	22
Rebleeding	7	41	12	32	61	38
Delayed cerebral ischemia	3	18	7	19	22	14
Hydrocephalus	5*	29	2*	5*	4†	3
Other	2	12	8	22	36	23
Dependent	6	19	4	7	31	9
Independent	8	26	20	33‡	146	44
Total	31		61		335	

% of total. SAH, subarachnoid hemorrhage.

*Includes patients who died of ventriculitis or drain removal following ventriculitis.

†Hydrocephalus that developed >1 week after initial SAH.

‡ $p < 0.05$ different from no hydrocephalus.

was delayed in the majority of the patients. We found that most patients with an unimpaired level of consciousness on admission do not need ventricular drainage and that even patients with an impaired level of consciousness on admission may spontaneously improve. The delay of ventricular drainage need not be unduly long since the majority of patients who recover spontaneously do so within 24 hours after admission (Figure 2). Not only those who fail to recover within 24 hours, but also those who then again deteriorate without evidence of complications other than hydrocephalus, are serious candidates for ventricular drainage.

Could the higher rebleeding rate after ventricular drainage be explained by factors other than drainage? Probably not. Factors such as the level of consciousness and the amount of cisternal and intraventricular blood on admission are associated with delayed cerebral ischemia and outcome^{26,27}; short-term tranexamic acid treatment is associated with cerebral ischemia (unpublished data), but none of these factors are associated with rebleeding. No factor other than medical (long-term tranexamic acid) or surgical intervention have been reliably associated with rebleeding.¹⁵ After corrections for these factors, the rebleeding rate was significantly higher in patients with than in patients without ventricular drainage, with or without acute hydrocephalus.

In a previous report on the first part (37%) of this series,³ the frequency of delayed cerebral ischemia and mortality from cerebral ischemia was very high in patients with ventricular drainage. In this extended series, the frequency of and mortality due to delayed cerebral ischemia in patients with acute hydrocephalus was still higher, but no longer significantly so, than in patients without acute hydrocephalus, probably because fluid restriction was no longer applied in patients with hyponatremia,¹³ a frequent complication of hydrocephalus in subarachnoid hemor-

rhage.^{3,28} There was no difference in this respect between patients with or without ventricular drainage for acute hydrocephalus. Therefore, it is unlikely that a short delay in the treatment of acute hydrocephalus will result in an increased frequency of cerebral ischemia.

What can be done to improve the outcome of patients with acute hydrocephalus? Although the risk of rebleeding can be diminished by long-term antifibrinolytic treatment, the benefit is negated by an increased frequency of delayed cerebral ischemia.¹² To improve outcome, it might be necessary to combine antifibrinolytic agents with plasma volume expansion²⁹ or calcium antagonists,³⁰ but even if this treatment combination is effective, it remains to be seen whether such a combined regimen would be effective after ventricular drainage. An alternative could be to have treatment of hydrocephalus by ventricular drainage soon followed by, or simultaneously performed with, clipping of the aneurysm.⁶ Such a policy will improve outcome only if early surgery is not accompanied by increased mortality and morbidity.

It has also been suggested that rebleeding after ventricular drainage can be prevented if the CSF pressure does not fall below 15–25 mm Hg.^{4,31} We could not confirm this since the CSF pressures after drainage in our series were within this "safe" range.

Infection was a frequent complication in the externally drained patients, especially if drainage was maintained for >3 days. Ventriculitis as a possible serious complication after drainage in hydrocephalus following subarachnoid hemorrhage was discussed by Diaz in a comment on the paper by Milhorat.⁶ Diaz suggested that ventriculitis can be prevented by using a long subcutaneous tunnel. Others preferred antibiotic prophylaxis^{5,20,32} and a short duration of external drainage.^{5,32}

Another possibility might be to treat hydrocephalic patients with serial lumbar puncture,^{1,19,22} provided the CSF blockage is in the subarachnoid space and not in the ventricular system. The risk of infection with this procedure is small, and the fall in CSF pressure is probably more gradual. Whether patients with acute hydrocephalus after subarachnoid hemorrhage really benefit from this simple procedure is presently being investigated.

References

- Spallone A, Gagliardi FM: Hydrocephalus following aneurysmal subarachnoid hemorrhage. *Zentralbl Neurochir* 1983; 44:141-150
- Black PM: Hydrocephalus and vasospasm after subarachnoid hemorrhage from ruptured intracranial aneurysms. *Neurosurgery* 1986;18:12-16
- Van Gijn J, Hijdra A, Wijdicks EFM, Vermeulen M, Van Crevel H: Acute hydrocephalus after aneurysmal subarachnoid hemorrhage. *J Neurosurg* 1985;63:355-362
- Pickard JD: Early posthemorrhagic hydrocephalus. *Br Med J* 1984;289:569-570
- Mayhall CG, Archer NH, Lamb VA, Spadora AC, Baggett JW, Ward JD, Narayan RK: Ventriculostomy-related infections. A prospective epidemiologic study. *N Engl J Med* 1984;310:553-559
- Milhorat TH: Acute hydrocephalus after aneurysmal subarachnoid hemorrhage. *Neurosurgery* 1987;20:15-20
- Teasdale GM, Jennett B: Assessment of coma and impaired consciousness. A practical scale. *Lancet* 1974;2:81-84
- Van Gijn J, Van Dongen KJ: Computerized tomography in subarachnoid hemorrhage: Difference between patients with and without an aneurysm on angiography. *Neurology* 1980; 30:538-539
- Van Gijn J, Van Dongen KJ, Vermeulen M, Hijdra A: Perimesencephalic hemorrhage. A nonaneurysmal and benign form of subarachnoid hemorrhage. *Neurology* 1985;35:493-497
- Earnest MP, Heaton RK, Wilkinson WE, Manke WF: Cortical atrophy, ventricular enlargement and intellectual impairment in the aged. *Neurology* 1979;29:11383-1143
- Meese W, Kluge W, Grumme T, Hopfenmüller W: CT evaluation of the CSF spaces of healthy persons. *Neuroradiology* 1980;19:131-136
- Vermeulen M, Lindsay KW, Murray GD, Cheah F, Hijdra A, Muizelaar JP, Schannong M, Teasdale GM, Van Crevel H, Van Gijn J: Antifibrinolytic treatment in subarachnoid hemorrhage. *N Engl J Med* 1984;311:432-437
- Wijdicks EFM, Vermeulen M, Hijdra A, Van Gijn J: Hyponatremia and cerebral infarction in patients with ruptured intracranial aneurysms. Is fluid restriction harmful? *Ann Neurol* 1985;17:137-140
- Jennett B, Bond M: Assessment of outcome after severe brain damage. A practical scale. *Lancet* 1975;1:480-484
- Hijdra A, Vermeulen M, Van Gijn J, Van Crevel H: Rerupture of intracranial aneurysms: A clinicoanatomic study. *J Neurosurg* 1987;67:29-33
- Galera RG, Greitz T: Hydrocephalus in the adult secondary to the rupture of intracranial arterial aneurysms. *J Neurosurg* 1970;32:634-641
- Graff-Radford NR, Torner J, Adams HP, Kassell NF: Factors associated with hydrocephalus in subarachnoid hemorrhage (abstract). *Ann Neurol* 1987;22:137
- Knibestöl M, Karadayi A, Tovi D: Echo-encephalographic study of ventricular dilatation after subarachnoid hemorrhage, with special reference to antifibrinolytic treatment. *Acta Neurol Scand* 1976;54:57-70
- Kolluri SVR, Sengupta RP: Symptomatic hydrocephalus following aneurysmal subarachnoid hemorrhage. *Surg Neurol* 1984;21:402-404
- Kusske JA, Turner PT, Ojemann GA, Harris AB: Ventriculostomy for the treatment of acute hydrocephalus following subarachnoid hemorrhage. *J Neurosurg* 1973;38:591-595
- Park BE: Spontaneous subarachnoid hemorrhage complicated by communicating hydrocephalus: Epsilon amino caproic acid as a possible predisposing factor. *Surg Neurol* 1979;11:73-79
- Raimondi AJ, Torres H: Acute hydrocephalus as a complication of subarachnoid hemorrhage. *Surg Neurol* 1973; 1:23-26
- Steinke D, Weir B, Disney L: Hydrocephalus following aneurysmal subarachnoid hemorrhage. *Neurol Res* 1987; 9:3-9
- Vassilouthis J, Richardson AE: Ventricular dilatation and communicating hydrocephalus following spontaneous subarachnoid hemorrhage. *J Neurosurg* 1979;51:341-351
- Yasargil MG, Yonekawa Y, Zumstein B, Stahl HJ: Hydrocephalus following spontaneous subarachnoid hemorrhage. *J Neurosurg* 1973;39:474-479
- Adams HP, Kassell NF, Torner JC, Haley EC: Predicting cerebral ischemia after aneurysmal subarachnoid hemorrhage: Influences of clinical condition, CT results, and antifibrinolytic therapy. A report of the Cooperative Aneurysm Study. *Neurology* 1987;37:1586-1591
- Hijdra A, van Gijn J, Stefanko S, van Dongen KJ, Vermeulen M, van Crevel H: Delayed cerebral ischemia after aneurysmal subarachnoid hemorrhage. Clinicoanatomic correlations. *Neurology* 1986;36:329-333
- Wijdicks EFM, van Dongen KJ, van Gijn J, Hijdra A, Vermeulen M: Enlargement of the third ventricle and hyponatremia in aneurysmal subarachnoid hemorrhage. *J Neurol Neurosurg Psychiatry* 1988;51:516-520
- Finn SS, Stephensen SA, Miller CA, Droblich L, Hunt WE: Observations on the perioperative management of aneurysmal subarachnoid hemorrhage. *J Neurosurg* 1986;65:48-62
- Petruk KC, West M, Mohr G, Weir BKA, Benoit BG, Gentili F, Disney LB, Khan MI, Grace M, Holness RO, Karwon MS, Ford RM, Cameron GS, Tucker WS, Purves GB, Miller JDR, Hunter KM, Richard MT, Durity FA, Chan R, Clein LJ, Maroun FB, Godon A: Nimodipine in poor-grade aneurysm patient. *J Neurosurg* 1988;68:505-517
- Voldby B, Enevoldsen EM: ICP changes following aneurysm rupture. Part 3: Recurrent hemorrhage. *J Neurosurg* 1982;56:784-789
- Wyler AR, Kelly WA: Use of antibiotics with external ventriculostomies. *J Neurosurg* 1972;37:185-188

KEY WORDS • subarachnoid hemorrhage • cerebral ischemia • hydrocephalus

Management problems in acute hydrocephalus after subarachnoid hemorrhage.

D Hasan, M Vermeulen, E F Wijdicks, A Hijdra and J van Gijn

Stroke. 1989;20:747-753

doi: 10.1161/01.STR.20.6.747

Stroke is published by the American Heart Association, 7272 Greenville Avenue, Dallas, TX 75231

Copyright © 1989 American Heart Association, Inc. All rights reserved.

Print ISSN: 0039-2499. Online ISSN: 1524-4628

The online version of this article, along with updated information and services, is located on the
World Wide Web at:

<http://stroke.ahajournals.org/content/20/6/747>

Permissions: Requests for permissions to reproduce figures, tables, or portions of articles originally published in *Stroke* can be obtained via RightsLink, a service of the Copyright Clearance Center, not the Editorial Office. Once the online version of the published article for which permission is being requested is located, click Request Permissions in the middle column of the Web page under Services. Further information about this process is available in the [Permissions and Rights Question and Answer](#) document.

Reprints: Information about reprints can be found online at:
<http://www.lww.com/reprints>

Subscriptions: Information about subscribing to *Stroke* is online at:
<http://stroke.ahajournals.org/subscriptions/>