sulphurous mineral waters, alum, and dilute sulphuric acid have severally been given to decompose it into a sulphuret. Calomel and the iodide of potassium are also believed to possess eliminating powers, the latter being supposed to convert the lead into a more soluble compound. Opium has been given internally, and chloroform applied externally, to relieve the colic. Briquet has recently employed cutaneous faradization, followed by some of the above eliminating remedies, with good results. Galvanism and strychnine have been much prescribed for the removal of the muscular paralysis.

Chronic poisoning by the contamination of water with lead is a subject worthy of more than a passing allusion, connected as it *was* with our own water supply. Your time has, however, been already too much trespassed upon to admit of this.

III.—*Cases Illustrative of Diseases of the Ear.* By T. M'Call Anderson, M.D., F.F.P. & S., Physician to the Deaf and Dumb Institution, Physician to the Dispensary for Skin Diseases, &c.

(*Read before the Glasgow Medical Society.*)

No. V.

CRESCENTIC OPACITY OF THE MEMBRANA TYMPANI.

Of the protean forms of disease to which the membrana tympani is liable, there is none more curious than the affection described by Wilde under the name of "crescentic opacity of membrana tympani." This morbid process is quite unknown to the majority of the profession; and, indeed, if we are to judge from the omission of any notice of it in most standard works upon the ear, it has escaped the observation of many who devote special attention to the diseases of that organ.

In Wilde's work the following notice is taken of it, and it is to him, I believe, that the credit is due of having first observed, or at all events of having first described it. "There is a form of deafness with which I have been long familiar, which may be the result of some form of inflammation. In such cases, upon bringing the external membrane of the drum into view, we do not observe any general thickening or opacity of it, or any apparent alteration of its texture; but a crescent-shaped opacity about a line broad and three lines long, with a tolerably defined edge, and rather rough upon its surface, occupies the lower and usually the back portion of the membrane. It is generally more insensible than the rest of the membrane, and differs from the ordinary

opacity in the surrounding structure being apparently free from disease, in its almost invariable seat, its well-defined edge, and in its having a portion of unaffected membrane between it and the bony attachment of the membrana tympani. By a very slow and gradual process this disease spreads over the greater portion of the membrane, and produces permanent deafness. I am not aware of any remedy for it.*

Before proceeding further, it will be well to narrate shortly one or two cases illustrative of this curious appearance:—

A. M., aged 55, cotton-spinner, applied to me at the Dispensary on the 17th September, 1862.

He stated that, while swimming on his back in the river Clyde, seven or eight years ago, he was run over by a rowing boat, and was stunned and cut about the head. A few days after this he thought he observed a slight dulness of hearing on the right side. He never noticed that he was deaf on the left side, however; and while he was sometimes troubled with "ringing" in the right ear, he never experienced pain in either side, and could give no further history of himself. His general health was apparently pretty good.

On examination of the right ear the tick of the watch could be heard at the distance of three inches, but it was inaudible when the watch was pressed upon the temple or mastoid process.

The meatus auditorius was normal in appearance, though rather deficient in cerumen. The membrana tympani presented the appearance delineated in Fig. 9 (A), which it is therefore unnecessary to describe. The right eustachian tube was pervious, though more imperfectly than the left.

On examining the left ear, the deafness was found to be less considerable, the tick being faintly audible when the watch was pressed on the temple, and at a distance of six inches from the ear, but inaudible on the mastoid process. The meatus

Fig. 9 (A).

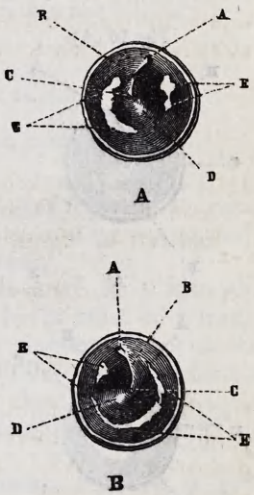

Fig. 9 (B).

Fig 9 (A).—Right membrana tympani—A, head; B, handle; C, end of handle of malleus; D, triangular bright spot; E E, deposit in the drum, of a yellowish tinge in the original.

Fig. 9 (B).—Left membrana tympani—The dotted lines from A B C D and E E lead to the same parts as the same letters in Fig. 9 (A).

* Practical Observations on Aural Surgery. By William R. Wilde, p. 284. London: Churchill, 1853.

externus was in the same state as the right; the drum presented the appearance observed in Fig. 9 (B), and the eustachian tube was quite free.

The nostrils were somewhat "stuffed," but the throat was nearly healthy.

Taking into account the history which the patient gave of the commencement of the deafness—though it is very probable that it dated further back than he was aware—and the occasional tinnitus in the right ear, I prescribed an eighth of a grain of the bichloride of mercury in a teaspoonful of compound tincture of cinchona twice daily, and recommended the mastoid processes to be blistered twice a week.

Fig. 10 (A).

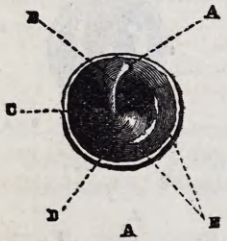

A

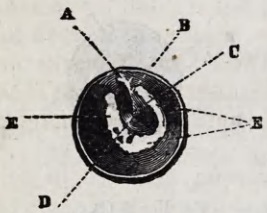

B

Fig. 10 (B).

Fig. 10 (A).—Right membrana tympani.—A, head; B, handle; C, end of handle of malleus; D, triangular bright spot; E, deposit in the drum, of a yellowish tinge in the original.

Fig. 10 (B).—Left membrana tympani.—The dotted lines from A B C D and E E lead to the same parts as the same letters in Fig. 10 (A).

On the 22nd November, 1862, I saw the patient again. He had taken the medicine regularly, and had blistered the mastoid surface six times without benefit. Indeed, on examining the membranæ tympanorum I found that the opacity was extending.

I may mention one other case to show the similarity of the symptoms.

Mrs. M., aged 67, consulted me on the 24th September, 1862. She stated that her hearing was "never so good on the left side as on the right," and that for the last few years she had observed deafness gradually coming on in both ears, but without either pain, tinnitus, or discharge.

She was the mother of two children, one of which died in infancy of "teething," and said that her general health had previously been very good. She stated, however, that she had been marked by a small, congenital, slightly elevated, vascular, nævus about the size of a pea, upon the right temple, which came in contact with the corner of a table three years ago. The skin "broke," suppuration and ulceration occurred, and the nævus degenerated into cancer. The growth, when the patient came under my observation, had a diameter of more than an inch, and was elevated about a quarter of an inch from the surface. It, however, caused no pain, and was hardly increasing in size at all.

In addition to this the patient complained of rheumatic pains "coming and going" for some years.

On examining the ears the tick was inaudible when the watch was pressed on the temples, mastoid processes, or upon the ears. The crack of the nails was, however, audible on both sides. Each meatus was rather deficient in cerumen, but otherwise healthy, each eustachian tube pervious, and the mucous membrane of the nostrils and fauces healthy. The tympanic membranes presented the exact appearances figured in the accompanying sketches.

In the absence of the slightest history or symptom of inflammatory action in the drums, and bearing in mind the evidence of the rheumatic diathesis, I prescribed the following mixture:—

℞. Iodidi potassii	ʒiv.	
Acetatis potassæ		
Bicarbonatis potassæ	āā ℥iss.	
Syrupi simplicis	℥j.	
Inf. cascarillæ	ad ℥xxiv.	M.

Sig.—A tablespoonful thrice daily.

On the 25th October, I saw this patient again, and in her case, as well as in the preceding one, the crescentic opacity was extending, especially in the left membrana tympani.

It will be well now to inquire a little more fully into the phenomena of this remarkable affection, but it must be remembered that, as I have never met with any account of it, with the exception of the short sketch of Mr. Wilde, my remarks are drawn from the cases which I have myself observed; and as these have not been numerous as yet, I shall not attempt to generalize much.

In the cases which I have seen, the disease occurred in persons pretty well advanced in years, but a more extended observation is required before this can be established as a rule, although it is very probable that the young are generally spared. Then again, it appears to me that the deafness is not sufficiently accounted for by the state of the drum alone, for we know well that there is often much less dulness of hearing when that membrane is in great part destroyed. So that, although I have never had an opportunity of examining the ear of any of these patients after death, nor am I aware that it has been done by others, I have little hesitation in expressing the opinion that the affection of the drum is the least important part of the change, and that it should be looked upon as symptomatic of a similar degeneration of the deeper-seated parts.

The tendency of this deposit in the drum to assume the crescentic shape in the cases observed, is a very curious circumstance; but it has its analogue in the skin where certain kinds of erup-

tion have a tendency to appear in a circular form. It is useless, however, to speculate upon the laws which govern the arrangement of these morbid deposits, as it is needless to expect that these shall ever be made known to us.

When the opacity in the drum makes its appearance, the deposit does not usually commence in the centre of the crescent, but the two horns are deposited first (see Fig. 9 A and B), though not always simultaneously, and these, by extending in the one case downwards and forwards, in the other downwards and backwards, unite below to form the complete crescent.

It is likewise interesting to observe how the edge of the drum always escapes in the first instance, the crescentic opacity being uniformly situated a little within the attachment of the margin of the membrane to the bone.

Examined by means of a good speculum, the portion of the drum unattacked by the deposits has a remarkably healthy appearance, especially if the usual age of the patient be taken into account; and the triangular bright spot, passing downwards and forwards from the point of the malleus, usually shines as in the normal membrane. On touching the membrana tympani gently with a probe, it appears throughout its whole extent to be considerably less sensitive than a healthy one; but I have not observed, with Mr. Wilde, that the opaque is less sensitive than the transparent portion.

The gentle contact of the probe with the drum gives to the fingers the sensation as if it was striking against a piece of dry parchment, and this sensation is exactly the same whether the opaque or the healthy portion is examined. The opacity communicates no hardness to the touch, such as occurs when a calcareous deposit in the drum is probed.

After the probe is removed, its previous point of contact with the membrane is generally indicated by a congested spot, and the portion of the drum in which the deposit is embedded appears to be equally prone to it with the transparent part. I have frequently detected a number of vessels running across the opacity after the use of the probe, but the congestion soon disappears, and the deposit ceases to exhibit any vascularity to the eye.

With regard to treatment I have little to say, as the means adopted in the cases which came under my observation were uniformly unsuccessful. Not only was the disease unchecked, but the opacity invaded new portions of the membrane during the administration of medicines. My experience coincides therefore in this respect with that of Mr. Wilde; and, indeed, if the view which I am about to propound with regard to the nature of the affection be a correct one, little benefit can accrue from medicines,

although a tonic and invigorating treatment is theoretically indicated.

We come then, lastly, to inquire into the nature of the affection. In the first case which came under my notice I mistook the deposit for calcareous degeneration. But it is certainly not a deposit of that nature; for, if touched with the probe, it is comparatively soft, like a piece of parchment, as I have said, while calcareous matter is perfectly hard, like bone. The former likewise has a yellowish colour, the latter is of a pure white; and, lastly, the form which the deposit assumes differs in the two cases—the calcareous matter being arranged either in a radiate form owing to degeneration of the radiate fibres of the drum, or a crescentic, the outer edge of the crescent being in contact with the edge of the drum. In the deposit under consideration, on the other hand, the outer edge of the crescent is a little within the edge of the drum.

Then, again, it can hardly be an inflammatory deposit, as, with the exception of tinnitus (a phenomenon not always present), which occurs in non-inflammatory as well as in inflammatory affections, there is no symptom of inflammation whatever, and no sign even of congestion of the part. Besides, the deposit is smoother on its surface, and its edge more abrupt than an inflammatory one.

Can it be a syphilitic deposit? Its circular form, corresponding to the shape which syphilitic eruptions upon the skin tend to assume, might lead to this opinion. But there are no other symptoms of syphilis, nor is there usually any history of that affection, although we must not put much faith upon this, for these are often absent or concealed in cases where typical syphilitic affections are under observation. But the most conclusive proof of its non-syphilitic nature is to be found in its not being influenced by anti-syphilitic remedies. I have prescribed both mercury and iodide of potassium in this affection, and not only have they not removed the deposit, but I have observed it extending during their administration.

It appears to me that we have here an instance of fatty degeneration attacking the drum, if one may judge from the unlikelihood of its being anything else, from the absence of all inflammatory symptoms, from the general appearance and yellowish colour of the deposit, from the usual age of the patients, the disease occurring at that time of life when fatty degeneration of other structures are most common, and from its analogy to the arcus senilis. Dr. Mackenzie thus speaks of the arcus senilis:—"In old people, the cornea, at a small but variable distance within its circumference, not unfrequently presents an opaque ring of a whitish colour, more or less broad, and more or less complete. The opacity is often semilunar, and is situated at the upper or lower edge of the

cornea. This *arcus senilis*, as it is termed, occurs without any previous inflammation, and has generally been ascribed to a diminished nutrition or marasmus of the part." If we substitute the word "drum" for "cornea" in this description, it applies almost word for word to the degeneration of the ear. Dr. Mackenzie goes on to say:—"Mr. Canton has demonstrated, what appears to have been surmised, that it (the arcus senilis) is a fatty degeneration, innumerable oil globules being found between the layers of the cornea at the part affected, on submitting a thin section of it to the microscope."* And I have little hesitation in expressing the opinion, that, when an opportunity is afforded of examining this degeneration of the membrana tympani after death, and with the microscope, some future investigator will demonstrate, what I have surmised, that it is a fatty degeneration, innumerable oil-globules being found between the layers of the membrana tympani, on submitting a thin section of it to the microscope; and likewise, that this affection of the drum is symptomatic of a similar degeneration of the deeper-seated parts.

IV.—*Case of Acute Phthisis, with Remarks.* By William Leishman, M.D., Dispensary Physician to the Royal Infirmary.

It is no part of my aim, in publishing a narrative of the following case of acute or sub-acute, phthisis, to claim for it an attention which it does not merit. Similar examples have undoubtedly come under the observation of every physician of experience; but I think I may venture to hope that the details of such a case, proceeding as it did so rapidly to a fatal result, and in which a *post-mortem* examination, disclosing some interesting pathological results, was permitted, may not be altogether devoid of interest.

On the 17th of June I was hurriedly summoned to see a girl of seventeen, healthy in appearance, but a member of a highly strumous family, who had been suddenly attacked with profuse hæmoptysis. A professional friend, who had been called in before my arrival, having prescribed gallic acid, this was continued for twenty-four hours, but without checking the hæmorrhage. Over the whole of the lower lobe of the right lung, but especially in front, there was dulness on percussion, with large crepitation. The respiratory murmur was puerile over the right apex, and natural over the left. The pulse was rapid and bound-

* A Practical Treatise on the Diseases of the Eye, by Wm. Mackenzie, M.D. 4th edition, p. 736. London: Longman, Brown, Green, and Longmans.