

Acquired Neuromyotonia Precipitated by Thyroid Surgery and Associated with Antiacetylcholine Receptor Antibodies

Zsolt Illes^b Angela Vincent^a Gabor G. Kovacs^c Hajnalka Merkli^b Attila Tordai^d
Samuel Komoly^b Ferenc Nagy^b

^aInstitute of Molecular Medicine, John Radcliffe Hospital, Oxford, UK; ^bDepartment of Neurology, University of Pécs, Pécs, ^cDepartment of Neuropathology, National Institute of Neurology and Psychiatry, and ^dDepartment of Molecular Diagnostics and Genetics, National Center for Hematology and Immunology, Budapest, Hungary

Dear Sir,

Receptors and ion channels of the neuromuscular junction are targets of several acquired immune-mediated diseases. Antibodies generated against acetylcholine receptors (AChR) result in myasthenia gravis (MG), while antivoltage-gated calcium channels are pathogenic in Lambert-Eaton myasthenic syndrome [1].

Since the description of Isaacs' syndrome in 1961, several phenotypic variants of acquired peripheral nerve hyperexcitability syndromes have been described [2]. In neuromyotonia, failure to relax voluntary muscle contraction ('pseudomyotonia') occurs together with muscle twitching or cramps. Muscle stiffness, increased sweating and hypertrophic calf muscles can be detected in some patients [2].

The association with other autoimmune diseases, especially MG, and the paraneoplastic origin in some cases, e.g. presence of thymoma, suggests an autoimmune origin. Indeed, plasma exchange alleviates the symptoms and the IgG of patients can transfer the disease. Antibodies against voltage-gated potassium channels (VGKC) can be detected in the peripheral blood of the majority of patients [3–5]. Interestingly, antibodies generated against

AChRs have also been described in some patients even in the absence of anti-VGKC antibodies, although their participation in the pathophysiology of the disease has not been investigated [6].

Case Report

The thyroid gland of a 62-year-old man was subtotally removed because of nodosal enlargement. Hyperthyroidosis was indicated by elevated free triiodothyronine, free thyroxine and decreased thyroid-stimulating hormone levels. Histology did not show any inflammation or tumor tissue, and he has been successfully treated with L-thyroxine. Two weeks after surgery, he realized that he could not relax his grip, and had generalized muscle stiffness. On neurological examination, signs of clinical pseudomyotonia with delayed relaxation were observed without any indication of neuropathy, myopathy or involvement of the central nervous system. No clinical symptoms and signs of MG were observed. Simultaneous concentric needle electromyography on superficial digital flexor, deltoid and abductor pollicis brevis muscles showed continuous spontaneous motor unit activity at rest with re-

petitive double, triple and multiple bursts, compatible with neuromyotonic and myokimic discharges (fig. 1a). Lidocaine blockade of the right median nerve did not modify the spontaneous discharges. The analysis of twenty motor units demonstrated normal duration of muscle potentials. Electromyographic recordings, including single-fiber electromyography and repetitive nerve stimulation, did not indicate any sign of MG, or Lambert-Eaton myasthenic syndrome. The sensory and motor conduction velocity, the compound muscle action potential, the sensory nerve action potential and F wave latency of the median nerve were normal. There was no indication of hereditary myotonia, periodic paralysis or any neurological disorder in his family or in his medical history. The hemogram, serum levels of thyroid and parathyroid hormones, calcium, phosphate, potassium, sodium, chloride, magnesium, creatinine, glucose, aldolase, lactate, liver function analysis, urinalysis were all normal. Creatinine kinase levels were slightly elevated (427 U/l). Total serum immunoglobulin, cryoglobulin, complement levels were in the normal range. A markedly elevated level of anti-AChR an-

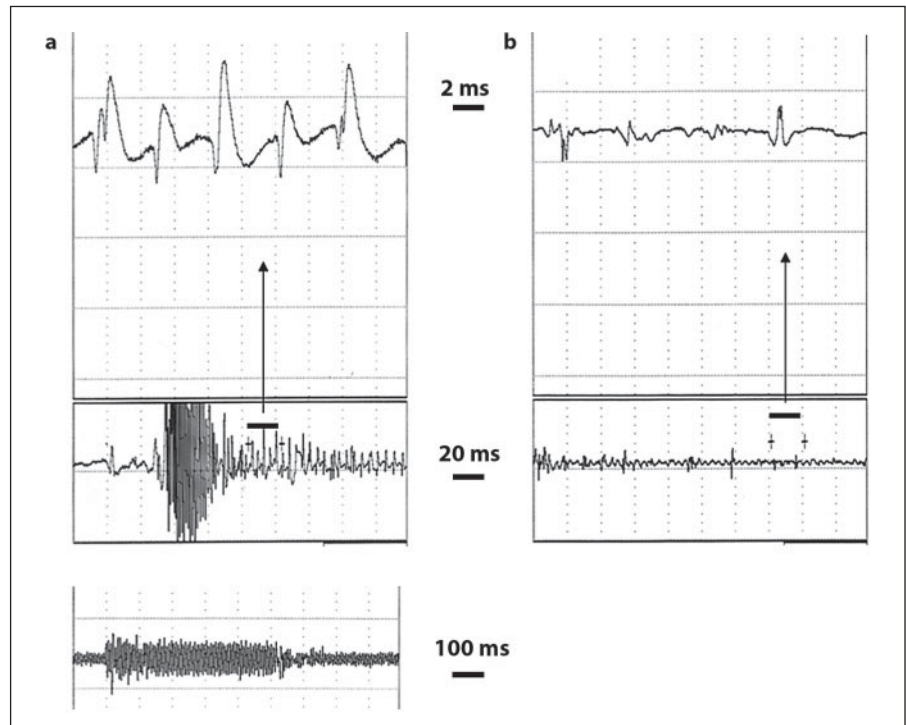


Fig. 1. Neuromyotonic discharges in deltoid (upper panel) and superficial digital flexor muscles (lower panel). Neuromyotonic discharges recorded 3 weeks after surgery (a) decreased after clinically effective treatment with mexiletine (b).

tibodies was found (3.8 pmol) in the serum, while no antibodies against VGKC were present. Routine antibodies and screening for cancer markers were all normal or negative. In addition, antitype 1 neuronal nuclear antibody (Hu), antitype 1 Purkinje cell antibody (Yo) and antineuronal nuclear antibody (Ri) could not be identified. Chest and mediastinal CT did not indicate lung cancer or thymoma. Muscle biopsy was unremarkable, except for a slight increase in the number of mitochondria. Direct sequencing of mitochondrial DNA did not show any mutation. Treatment with carbamazepine (1,200 mg daily) provided no clinical benefit. However, mexiletine (600 mg daily) dramatically reduced his signs and symptoms, including the repetitive discharges on EMG (fig. 1b).

Discussion

The clinical and electrophysiological signs and symptoms of this patient were fully compatible with acquired neuromyotonia. Although the disease can be paraneoplastic in origin, no primary tumor was identified. His previous medical and familial history, genetic analysis, laboratory and electrophysiological data and muscle biopsy were not suggestive of he-

reditary myotonia, myopathy or acquired neuropathy.

A markedly increased level of anti-AChR antibodies was detected in the serum. Since no other autoantibodies were found, it is unlikely that their presence were only coincidental indicating an autoimmune-prone state. Indeed, anti-AChR antibodies have been shown in other cases of neuromyotonia even without the presence of anti-VGKC antibodies, similar to our case [6]. In contrast to anti-VGKC antibodies, the contribution of anti-AChR antibodies to the mechanism of acquired neuromyotonia has not been clarified. Since the patient had no clinical or electrophysiological evidence of MG or thymoma, we may hypothesize that anti-AChR antibodies in neuromyotonia may have a stimulatory potential resulting in hyperexcitability in contrast to MG.

The onset of neuromyotonic symptoms was closely associated with the surgery on the thyroid gland. However, the appearance of symptoms only 2 weeks after the operation favors the possibility of a previous subclinical disease. One can also speculate that surgery might precipitate autoimmune disease similar to myasthenic crisis [7]. The close vicinity of the thymus and the increased levels of anti-AChR antibod-

ies may suggest that damaging the thymus and subsequent *in vivo* immunization with released thymic AChR might have also contributed. Indeed, MG was reported after cardiac surgery in 3 patients [8], although a recent search for anti-AChR and anti-VGKC antibodies did not demonstrate an increased prevalence of these antibodies after cardiac surgery [9].

Although carbamazepine has been proposed to treat symptoms of neuromyotonia especially with neuropathy [10, 11], it had no clinical effect in our case. However, we observed a dramatic clinical and electrophysiologic response to low-dose mexiletine, a sodium channel blocker, which has been suggested to relieve symptoms of hereditary autosomal dominant myotonias and pseudomyotonia [12]. Symptoms reappeared on withdrawal of the drug, indicating that the effects were attributed to the treatment and not related to spontaneous improvement of the disease. Different sodium-channel blockers thus may have a differential effect on acquired neuromyotonia.

Acknowledgements

Supported by a grant from the Hungarian Research Fund (OTKA T049463) and the Bolyai Janos Research Fellowship of the Hungarian Academy of Sciences (ZI).

References

- 1 Lang B, Vincent A: Autoantibodies to ion channels at the neuromuscular junction. *Autoimmun Rev* 2003;2:94–100.
- 2 Newsom-Davis J, Buckley C, Clover L, Hart I, Maddison P, Tüzüm E, Vincent A: Autoimmune disorders of neuronal potassium channels. *Ann NY Acad Sci* 2003;998:202–210.
- 3 Sinha S, Newsom-Davis J, Mills K, Birne N, Lang B, Vincent A: Autoimmune aetiology for acquired neuromyotonia (Isaacs' syndrome). *Lancet* 1991;338:75–77.
- 4 Shillito P, Molenaar PC, Vincent A, Leys K, Zheng W, van den Berg RJ, Plomp JJ, van Kempen GT, Chauplannaz G, Wintzen AR: Acquired neuromyotonia: evidence for autoantibodies directed against K⁺ channels of peripheral nerves. *Ann Neurol* 1995;38:714–722.
- 5 Nagado T, Arimura K, Sonoda Y, Kurono A, Horikiri Y, Kameyama A, Kameyama M, Pongs O, Osame M: Potassium current suppression in patients with peripheral nerve hyperexcitability. *Brain* 1999;122:2057–2066.
- 6 Hart IK, Maddison P, Newsom-Davis J, Vincent A, Mills KR: Phenotypic variants of autoimmune peripheral nerve hyperexcitability. *Brain* 2002;125:1887–1895.
- 7 Szobor A: *Myasthenia gravis*. Budapest, Akadémiai Kiadó, 1990, pp 97–119.
- 8 Scoppetta C, Onorati P, Eusebi F, Fini M, Evoli A, Vincent A: Autoimmune myasthenia gravis after cardiac surgery. *J Neurol Neurosurg Psychiatry* 2003;74:392–393.
- 9 Sleeman K, Rajani R, Chambers J, Vincent A: Autoimmune neurological disease after cardiac surgery. *J Neurol Neurosurg Psychiatry* 2004;75:1078–1079.
- 10 Lahrman H, Albrecht G, Drlicek M, Obendorfer S, Urbanits S, Wanschitz J, Zifko UA, Grisold W: Acquired neuromyotonia and peripheral neuropathy in a patient with Hodgkin's disease. *Muscle Nerve* 2001;24:834–838.
- 11 Hahn AF, Parkes AW, Bolton CF, Stewart SA: Neuromyotonia in hereditary motor neuropathy. *J Neurol Neurosurg Psychiatry* 1991;54:230–235.
- 12 Hudson AJ, Ebers GC, Bulman DE: The skeletal muscle sodium and chloride channel diseases. *Brain* 1995;118:547–563.