

Iris-Claw Intraocular Lens and Scleral-Fixated Posterior Chamber Intraocular Lens Implantations in Correcting Aphakia: A Meta-Analysis

Wu Jing,¹ Liang Guanlu,² Zheng Qianyin,³ Li Shuyi,¹ He Fengying,⁴ Liu Jian,² and Xu Wen¹

¹Eye Center, the 2nd Affiliated Hospital of Zhejiang University, College of Medicine, Hangzhou, Zhejiang, China

²Department of Ophthalmology, Zhejiang Hospital, Hangzhou, Zhejiang, China

³Department of Ophthalmology, Taizhou hospital, China

⁴Department of Ophthalmology, Huzhou Central Hospital, Huzhou, Zhejiang, China

Correspondence: Xu Wen, Eye Center, the 2nd Affiliated Hospital of Zhejiang University, College of Medicine, Hangzhou, Zhejiang, China; xuwenhz2002@aliyun.com.

Submitted: December 2, 2016

Accepted: February 12, 2017

Citation: Jing W, Guanlu L, Qianyin Z, et al. Iris-claw intraocular lens and scleral-fixated posterior chamber intraocular lens implantations in correcting aphakia: a meta-analysis. *Invest Ophthalmol Vis Sci*. 2017;58:3530-3536. DOI:10.1167/iov.16-21226

PURPOSE. A meta-analysis to compare iris-claw intraocular lens (IC-IOL) and scleral-fixated posterior chamber intraocular lens (SF-PCIOL) implantations in correcting aphakia without sufficient capsular support.

METHODS. Eligible studies were collected through PubMed, Web of Science, Embase, and the Cochrane library. The pooled relative risks (RR), pooled standardized mean difference (SMD), and their 95% confidence interval of the eligible studies were then calculated. Seven studies met our inclusion criteria, involving 232 and 158 eyes in IC-IOL and SF-PCIOL groups, respectively.

RESULTS. The pooled SMD of the mean postoperative corrected distance visual acuity (CDVA) (logMAR) was -0.25 . The pooled RR of the eyes achieving 20/40 or better postoperatively was 1.16. The pooled SMD of the surgical time was -2.97 . The pooled RR of the surgical complications was 0.86. The pooled RR of IOL dislocation, retinal detachment (RD), and cystoid macular edema (CME) between the two groups were 0.22, 0.63, and 0.64.

CONCLUSIONS. Implantation of IC-IOL has a more simple procedure and shorter learning curve than SF-PCIOL implantation in correcting aphakia without sufficient capsular support.

Keywords: IC-IOL, SF-PCIOL, SMD, PubMed, CDVA

Many reasons can lead to an aphakia without sufficient capsular support for a posterior chamber intraocular lens (PCIOL), such as intraoperative complications during phacoemulsification,¹⁻⁴ intracapsular cataract extraction (ICCE),^{5,6} ocular trauma,⁷ and lens dislocation caused by various reasons (e.g., Marfan Syndrome,^{8,9} congenital or secondary weakness of zonules, etc.). It has always been the focus of ophthalmologists to choose an appropriate treatment to handle these issues. During the past decades, many ways have been tried to treat these diseases. At present, visual rehabilitation of these patients includes spectacles, contact lenses (CLs), and primary or secondary IOL implantation. Spectacles are rarely used for visual rehabilitation of aphakia, because of the poor visual field and relative peripheral refractive error, and many patients are unsatisfied with the inconvenience and thickness of the glasses,^{10,11} or just use over the period before secondary IOL implantation.¹² Patients with anisometropia are thought to not be suitable for spectacles. Contact lenses are considered the most common treatment, as it is easy to get and effective to rehabilitate visual acuity of the aphakia. Therefore, CLs have been widely accepted.^{13,14} Complications in wearing CLs¹⁵ are always caused by poor maintenance, overextended wearing, and wearing in a polluted environment. Several corneal and conjunctival complications are also common, such as conjunctivitis, especially giant papillary conjunctivitis,¹⁶ corneal vascularization, corneal edema, corneal abrasions, chronic endothelial dysfunction, and relatively tricky microbial keratitis.

The major problem associated with CL-wearing is corneal hypoxia.

Most ophthalmologists agree that IOL implantation is the most appropriate treatment for visual rehabilitation and correction of aphakia. There are a variety of options¹⁷ for the correction of these aphakic patients lacking of adequate capsular support, such as angle-supported anterior chamber IOLs (ACIOLs); IC-ACIOLs; and SF-PCIOLs. The angle-supported ACIOLs have been used for decades and improved with many designs. However, with a high rate of conditions such as endothelial cell loss,¹⁸ secondary glaucoma, and severe uveitis,^{6,19} they are fading out from the field gradually. The IC- or lobster-claw (LC)-IOL (a biconvex PMMA IOL) was presented by Worst et al. in 1972²⁰ and was first used to treat myopia. Then many modifications were incorporated to this lens over time. Artiflex, Verisyse, and Artisan were designed and brought into the market for visual rehabilitation, and also used to correct aphakia with satisfactory results.²¹ One of the latest versions of IC-IOL designed for aphakia is the convex/concave model (Artisan Aphakia Model 205; Ophtec BV, Groningen, The Netherlands). According to the position of IOL fixation, IC-IOLs are classified into anterior chamber IC-IOLs and retropupillary IC-IOLs.^{22,23} The implantation of an IC-IOL is a time-saving surgery with low intrusiveness, and the operation technique is much easier than the implantation of a SF-IOL. The implantation of a retropupillary IC-IOL combines the advantages of a PCIOL and a short operation time as well as



an easy operation technique; both advantages were accepted by many surgeons.²⁴⁻²⁶ However, there are still some concerns over corneal endothelial stability and late dislocation, and it is also limited by the conditions of the iris as well as the anterior chamber depth (ACD). Implantation of SF-PCIOL²⁷ more closely simulates the normal physiologic and anatomic position of the crystalline lens, and so is considered to be implanted first in patients suffering from aphakia when the eye conditions allow. However, it requires experienced surgeons with skillful surgical techniques and a long operation procedure. Therefore, most surgeons consider the IC-IOLs first, and the SF-PCIOLs are an acceptable alternative in the cases of correcting aphakia without sufficient capsular support. Many complications may associate with both kinds of surgeries, such as lens tilt and decentration, hypotony, secondary glaucoma, hyphema, vitreous hemorrhage, suprachoroidal hemorrhage, choroidal effusion, CME, RD, and even endophthalmitis.²⁸ Several previous studies compared the outcomes of the two kinds of surgeries directly when patient's capsular support was lacking,²⁹⁻³¹ but there was no consensus of opinion. Thus, the present meta-analysis aimed to compare the clinical efficacy, safety, and complexity between both IOLs implantations in correcting aphakia without sufficient capsular support.

MATERIALS AND METHODS

Search Strategy

We searched appropriate articles by systematic queries in the PubMed, Web of Science, Embase, and the Cochrane Library, up to May 24, 2014. The terms of search strategy were "iris-fix*" OR "iris-claw" OR "artisan" OR "iris-clip" OR "verisyse" OR "iris suture*" combined with "scleral fix*" OR "transscleral fix*" OR "intrascleral fix*" OR "transscleral suture*" OR "sulcus fix*" OR "transscleral sulcus fix*" OR "scleral suture fix*", with no language restriction but restricted to clinical studies. The titles and abstracts were scanned firstly to exclude the clearly irrelevant studies. Then the full texts of the remaining articles were read to determine whether they contained information on our topic of interest.

Study Selection

Two researchers (JW, GL) independently read all the publications to determine whether the studies can be included when they met all the criteria as follows: (1) case control study, cohort study, and randomized control trial (RCT) published as an original article that associated an IC-IOLs and SF-PCIOLs implantation without adequate capsular support; (2) any causes result in absence of capsular support to implant a IOL; (3) reported the change in visual acuity and complication; and (4) reported the data that can evaluate the odds ratio (OR) or RR with their corresponding 95% CIs.

Qualitative Assessment

Articles were reviewed for quality using a modified version of the Quality Index Scale (QIS; Downs & Black). The quality index was initially developed to systematically rate the research quality of randomized and nonrandomized studies of healthcare interventions. The Downs and Black checklist in this study consisted of 26 items distributed between 5 subscales: reporting (9 items); external validity (3 items); confounding (6 items); power (1 item); and bias (7 items). The quality index scale has good reliability and validity for measuring the methodological quality of health research. A higher score indicates a better quality of the study. Our meta-analysis included both randomized controlled trials (RCTs) and

non-RCTs, so the quality index (also called Downs and Black quality method) that is used for the RCTs and non-RCTs was used as the qualitative assessment in our study.³² Of this study, the QIS of the seven articles can be divided into four subgroups, including subgroup with QIS ($n = 26-28$); QIS ($n = 20-25$); QIS ($n = 15-19$); and QIS ($n = \leq 14$). The articles with QIS ≤ 14 have been excluded from this study.

Data Extraction

The two researchers (JW, GL) independently extracted the relevant data from the included studies, and the conflict was resolved by discussion or by the final decision of a senior researcher (WX). The extraction information included were as follows: the first author of the study, the year of publication, the country of the study conducted, the study period, the number of studied eyes with either of the two types of IOLs implanted, the mean age of the patients in the two groups, the mean follow-up time, the study design, the visual acuity, and the intra- or postoperative complications of each IOL implantation. Then the two researchers analyzed the data and evaluated the effects. The data in this study were extracted from the original studies with the least number of modifications as possible. In the final analysis, these data were converted to the form that can be compared with each other.

Data Analysis

The relative risks were used to estimate the result of the complications and the number of eyes achieving 20/40 or better; a P value < 0.05 or a 95% CI not including value 1 was considered significant. We used the mean postoperative CDVA (logMAR) and surgical time to calculate the pooled SMD; a P value < 0.05 or the 95% CI not including value 0 was considered significant.

The data from all studies were analyzed based on the fixed-effects model with the Mantel-Haenszel method first when heterogeneity was negligible. If the heterogeneity was not negligible ($I^2 > 25\%$), a random-effects model with the Mantel-Haenszel method was applied.³³ We used the latter model, because in our meta-analysis, the heterogeneity of the seven studies included that these patients were from different clinical centers with different criteria and causes (e.g., lacking enough capsular support, different sample size, different length of follow-up, different outcome analysis, etc.). The heterogeneity between all studies was examined using Q -statistic and I^2 score.^{34,35} The null hypothesis was that the studies were homogeneous unless rejected for less than 0.05 in a P value for heterogeneity or greater than 25% in I^2 .

The Egger's³⁶ and Begg's tests³⁷ were then performed to evaluate the publication bias, and $P < 0.05$ for either Egger's or Begg's test was considered reaching a significant level of publication bias. Sensitivity analyses were also performed to exclude the study that may contribute the heterogeneity. We used commercial statistical software (Stata/SE 12.0; Stata Corp., College Station, TX, USA) for all data analysis in this study.

RESULTS

After searching the databases, 434 articles met our interest. Among them, 134 were duplicate references, and 6 animal experiments were excluded. A total of 266 articles were excluded after reviewing the titles and abstracts. Ultimately, after reading the full text of the remaining articles, we excluded another 21 articles that were: reviews of the operation of IC-IOLs and SF-PCIOLs without clinic data, case reports, letters to the editor, or articles with no relevant results

TABLE 1. Characteristics of Studies Included in the Meta-Analysis

Author/Year	Country	Types	Period	Eyes (IC-IOL/SF-PCIOL)	Mean Follow-up Time, mo	Mean Age, y	Causes	Quality
Zheng ³⁸ /2012	China	RCT	2004–2009	32/39	12	22.5/18.6	Marfan syndrome	21
Hazar ³⁹ /2013	Turkey	Retrospective study	2008–2011	(IC-IOL 35 and retro pupillary IC-IOL 24/ SF-PCIOL 31)	11.7	(IC-IOL 52 and retro pupillary IC-IOL 61/ SF-PCIOL 53)	Operative complications	17
Farrahi ³⁹ /2012	Iran	Prospective study	2008–2010	12/13	11.17 (IC-IOL)/21.54 (SF-PCIOL)	55.9/60.0	Operative complications, or Trauma	15
Menezo ⁴⁰ /1996	Spain	Retrospective study	1989–1994	Primary group, 34/13; secondary group, 41/13	14	Primary group, 54.7/62.0; secondary group, 53.8/ 65.5	ECCE or ICCE with lens subluxation, operative complications	16
Hara ⁴¹ /2011	Japan	Prospective study	N/A	11/21	6	62.2/(63.9 and 60.7)	Marfan syndrome or Trauma or Iatrogenic or Unknown	16
Saleh ³¹ /2013	France	Retrospective study	2009–2011	18/8	14	58.6/55.1	Trauma	18
Teng ²⁹ /2014	China	Prospective study	2008–2012	25/20	12	63.1/66.25	Aphakia after PPV and Lensectomy	20

ECCE, extracapsular cataract extraction; N/A, data not available; PPV, pars plana vitrectomy.

fitting our interest. Finally, seven studies^{29–31,38–41} met all the criteria and were used in the meta-analysis (Fig. 1).

The 7 included studies, involved a total of 390 eyes: 232 eyes (59.49%) in IC-IOLs group and 158 eyes (40.51%) in SF-PCIOLs group. Table 1 provides summaries of the study and the characteristics of participants. Because IC-IOLs are classified into anterior chamber IC-IOLs and retro pupillary IC-IOLs, this study merged the 2 types of IOLs implantation into 1 group.³⁰ Our outcome measures were the visual acuity, the surgical time, and the postoperative complications.

Visual Acuity

In the seven enrolled studies, only 5 studies^{30,31,38,39,41} provided data for calculating the SMD of the mean postoperative CDVA (logMAR). Table 2 shows the clinical data of the mean postoperative CDVA (logMAR) of these five studies. Subsequent data analysis indicated no difference between the IC-IOL and SF-PCIOL groups (SMD = -0.23 , 95% CI -0.49 to 0.03 , $P = 0.32$, $I^2 = 14.9\%$; Fig. 2A). In the five studies, one study just provided the mean postoperative week 1 CDVA (logMAR) but did not provide the final follow-up result. So we omitted this study of Hara et al.,⁴¹ to obtain the final results (SMD = -0.20 , 95% CI -0.51 to 0.12 , $P = 0.32$, $I^2 = 14.9\%$). The follow-up time of the other four studies was about 1 year. There was no statistically significant difference on the publication bias (Begg's test, $P = 0.73$; Egger's test, $P = 0.14$).

The number of eyes achieving 20/40 or better postoperatively was also an analysis of our interest, and four out of the seven studies^{30,31,38,39} provided available data of eyes of 20/40 or better postoperatively. The patients in the study of Menezo et al.⁴⁰ were divided into primary and secondary implantation groups, so we considered the data of eyes of 20/40 or better postoperatively were from independent studies (Table 3). We thought that the result could be used to estimate the surgical efficacy of the IC-IOL implantation and SF-PCIOL implantation. There was no significant difference between the IC-IOL implantation and SF-PCIOL implantation groups ($rr = 1.16$, 95% CI 0.92 – 1.47 , $P = 0.24$, $I^2 = 27.1\%$; Fig. 2B). There was no significant difference on the publication bias (Begg's test, $P = 0.09$; Egger's test, $P = 0.24$).

Surgical Time

We used the surgical time to estimate the complexity of the procedure. A longer surgical time indicates a more complex surgery, and also means a longer learning course and more resource consumption. Data from four studies^{29,31,38,41} were evaluated, and the results showed a statistically significant difference between the two groups (SMD = -2.97 , 95% CI -3.44 to 2.50 , $P = 0.00$, $I^2 = 92.6\%$; Fig. 2C). There was no significant difference on the publication bias (Begg's test, $P = 0.73$; Egger's test, $P = 0.28$).

Complications

We used the incidence of complications to estimate the safety of the 2 groups of IC-IOL implantation and SF-PCIOL implantation, and 5 out of the 7 studies^{29–31,39,41} provided available information on complications ($rr = 0.86$, 95% CI 0.61 – 1.20 , $P = 0.04$, $I^2 = 59.8\%$) (Fig. 2D). There was no significant difference on the publication bias (Begg's test, $P = 0.81$; Egger's test, $P = 0.58$). Then we estimated the incidence of some single common complications to evaluate the safety of the 2 groups. We found no significant difference on the IOL dislocation between both groups ($rr = 0.22$, 95% CI 0.10 – 0.50 , $P = 0.31$, $I^2 = 16.2\%$; Fig. 2E). Moreover, there was no evidence of publication bias (Begg's test, $P = 0.45$; Egger's test, $P = 0.97$).

PRISMA 2009 Flow Diagram

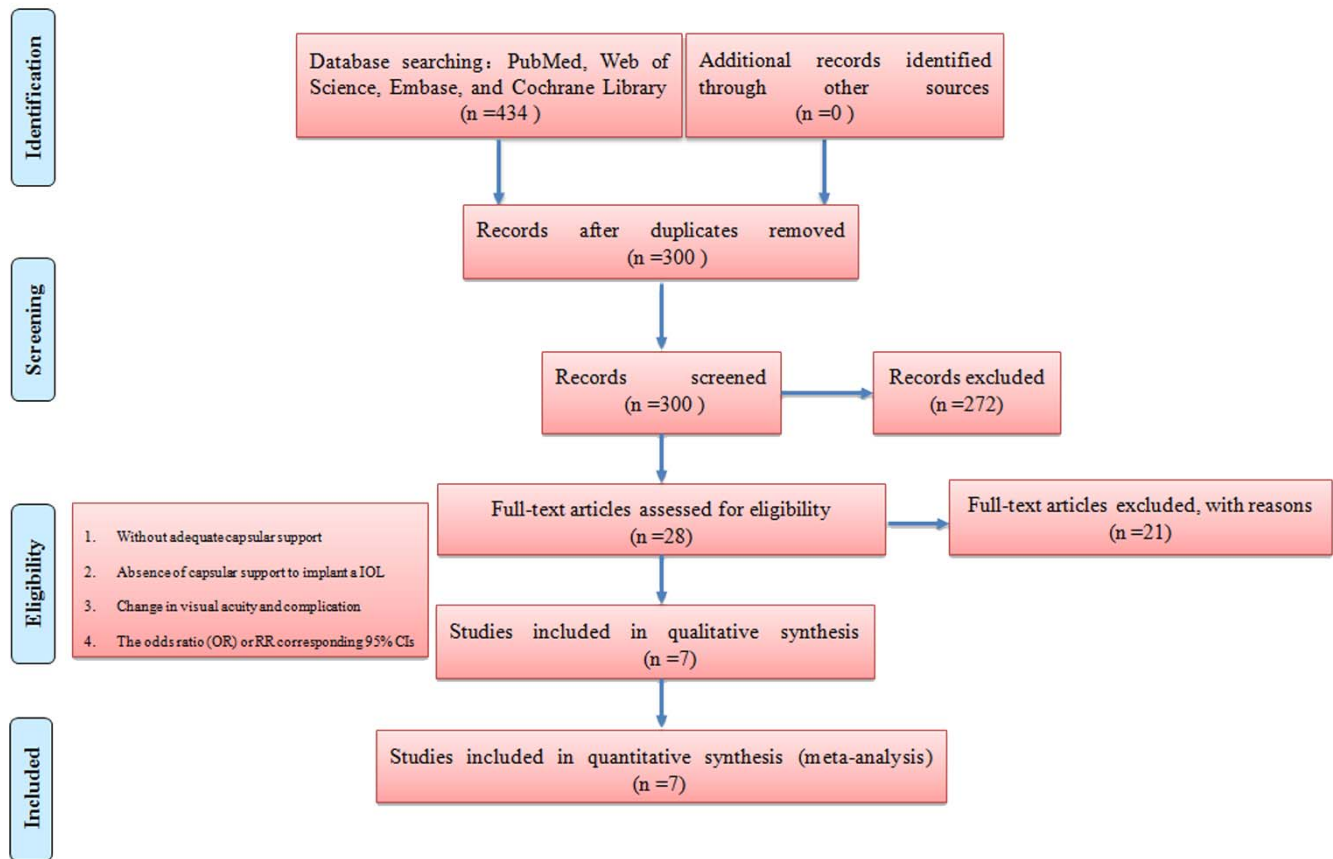


FIGURE 1. Flow chart of study selection process.

There were also no differences in RD between the 2 groups ($rr = 0.63$, 95% CI 0.18–2.22, $P = 0.62$, $I^2 = 0.0\%$; Fig. 2F), and no publication bias (Begg’s test, $P = 1.00$; Egger’s test, $P = 0.91$). Lastly, we estimated the incidence of CME, which showed no difference between the IC-IOL and SFPC-IOL groups ($rr = 0.64$, 95% CI 0.28–1.48, $P = 0.51$, $I^2 = 0.0\%$; Fig. 2G), without publication bias (Begg’s test, $P = 0.45$; Egger’s test, $P = 0.49$).

DISCUSSION

Implantations of IC-IOL and SF-PCIOL are the mainstream operation methods in visual rehabilitation to treat aphakia without sufficient capsular support to hold an IOL in the posterior capsule. Although there are several previous studies and reviews focusing on the surgical procedure and outcomes between IC-IOL and SF-PCIOL implantations,^{29–31} the conclusions are controversial, and no systematic review has

compared IC-IOL and SF-PCIOL implantations in treating aphakia without sufficient capsular support. Since each operation has advantages and specific complications, it is difficult to determine which is mostly suitable for the management of patients without sufficient capsular support to hold an IOL in the posterior capsule. Thus, we conducted a meta-analysis to compare the efficacy, safety, and complexity between IC-IOL and SF-PCIOL implantations in correcting aphakia without adequate capsular support.

In the seven enrolled studies, there was no significant difference in efficacy and safety between IC-IOL and SF-PCIOL groups, but the IC-IOL group had a significant shorter surgical time and learning curve the SF-PCIOL group. Treatments with IC-IOL involved corneal incision and IOL push-in; the IC-IOL could fix on the iris by its clamp, which can be helpful to shorten the operation time and to simplify the procedure. By contrast, SF-PCIOL treatments needed to fix the IOL by suture, which meant a more complicated and time-consuming

TABLE 2. Postoperative CDVA (logMAR) in IC-IOL and SF-PCIOL Groups at the Last Follow-Up Visit

Author	IC-IOL, mean ± SD		SF-PCIOL, mean ± SD		Follow-Up
	Before	After	Before	After	
Zheng ³⁸	0.10 ± 0.40	0.22 ± 0.28	0.00 ± 0.18	0.22 ± 0.20	1 y
Hazar ³⁰	0.99 ± 0.94/0.97 ± 0.83	0.48 ± 0.43	0.86 ± 0.75	0.51 ± 0.07	Final visit
Farrahi ³⁹	0.89 ± 0.22	0.24 ± 0.17	None	0.41 ± 0.22	6 mo
Hara ⁴¹	0.49 ± 0.46	0.41 ± 0.21	0.41 ± 0.41	0.59 ± 0.33	1 wk
Saleh ³¹	1.11 ± 1.13	0.32 ± 0.47	1.68 ± 1.15	0.55 ± 0.90	Final visit




FIGURE 2. (A) Forest plot of risk estimates of postoperative CDVA (logMAR; 95% CIs) from studies on IC-IOLs and SF-PCIOLs. (B) Forest plot of risk estimates of the number of eyes achieving 20/40 or better postoperatively associated with IC-IOLs and SF-PCIOLs. (C) Forest plot of risk estimates of complications associated with IC-IOLs and SF-PCIOLs. (D) Forest plot of risk estimates of complications associated with IC-IOLs and SF-PCIOLs. (E) Forest plot of risk estimates of IOL dislocation associated with IC-IOLs and SF-PCIOLs. (F) Forest plot of risk estimates of RD associated with IC-IOLs and SF-PCIOLs. (G) Forest plot of risk estimates of CME associated with IC-IOLs and SF-PCIOLs.

TABLE 3. Number of Eyes Achieving 20/40 or Better Postoperatively at the Last Follow-Up Visit Between IC-IOL and SF-PCIOL Groups

Author	IC-IOL		SF-PCIOL	
	Total	Achieving 20/40 or Better, n (%)	Total	Achieving 20/40 or Better, n (%)
Hazar ³⁰	59	34 (57.6%)	31	18 (58.1%)
Farrahi ³⁹	12	9 (75.0%)	13	5 (38.5%)
Menezo ⁴⁰ (primary implantation)	34	17 (50.0%)	13	7 (53.8%)
Menezo ⁴⁰ (secondary implantation)	41	32 (78.0%)	13	6 (46.2%)
Saleh ³¹	18	12 (66.7%)	8	6 (75%)

operation. We speculated that the more complicated and time-consuming operation could lead to a more invasive assault of the eyes, corresponding to more operative complications. Different operation methods could give rise to rarer operative complications. However, we did not confirm the direct relationship between complications and operation time in this study. Therefore, further study is needed to investigate the relationship between the two factors.

With regard to safety, there was no significant difference between the two groups. The iris claw-IOL was fixed on the iris by haptics. It might have a higher rate of various complications that are related to the iris and pupils (e.g., iris atrophy, pigment deposits, pigment dispersion, pupillary distortion, endothelial cell loss, etc.).⁴² Decentration of IOL, suture erosion, and macula edema occurred at a higher rate in patients with SF-PCIOL implantations.⁴³ Therefore we estimate the incidence of some single common complications (IOL dislocation, RD, and CME) to evaluate the safety of the two groups. Our results showed no significant difference between both groups. Four studies^{29,30,40,41} thought that there were no significant differences between the two groups. The study of Zheng et al.³⁸ found the following in the SF-PCIOL group: one eye with temporarily elevated IOP at day 1 that was immediately managed by laser peripheral iridotomy; four eyes with persistently elevated IOP, three of which were managed by antiglaucomatous medication, the last was managed by trabeculectomy. Farrahi et al.³⁹ mentioned that there were two patients with raised IOP in both IC-IOL and SF-PCIOL groups that was controlled with medication.

Corneal endothelial cells (ECs) approximately decrease 0.5% to 1% annually after the age of 2 years.⁴⁴ Thus, the cell density decreases from 6000/mm² at birth to 2000/mm² at age 60 years. The minimum cell density for maintaining a normal function is generally considered to be 300 to 500/mm². Corneal decompensation, corneal edema, bullous keratopathy, and even loss of vision will happen when the number of ECs is less than the minimum. Typically, having ECs less than 800 is a contraindication of intraocular surgery. The anterior chamber depths are more demanding in IC-IOL implantation for avoiding the direct friction with corneal endothelium. In the seven included studies, there was no available data for calculating pooled SMD to evaluate the difference between both groups. There were three studies^{29,30,38} mentioning that there was no statistically significant difference on postoperative endothelial cell loss between groups ($P > 0.05$). The follow-up time of the three studies was probably approximately 1 year. The endothelial cell loss changes very slowly, so more studies with longer follow-up time are needed to further confirm the findings.

The effects of patients' age and race, sample size, causes, and study design on heterogeneity should also be considered. However, due to the insufficient relevant information in the included studies, we could not analyze the influence of the above factors on the heterogeneity.

Our meta-analysis had several limitations. First, considering the strict inclusion criteria of meta-analysis, our research included a limited number of studies, which may affect the persuasion of the result. Unpublished articles were not included in our meta-analysis, which may affect the publication bias, although no significant evidence of publication bias was shown by Egger's and Begg's test. Our meta-analysis included several designs, and a limited number of randomized controlled trials were included to get a more convincing conclusion. Second, SF-PCIOL implantation was technically more difficult than IC-IOL implantation and had longer surgical time and longer learning curve, which may cause some surgeons to give up this kind of IOL when facing difficult cases. The deciding factor in choosing an IOL appeared to have no authoritative standard. This may contribute to the bias of outcomes. Third, when the heterogeneity was not negligible ($I^2 > 30\%$), the random-effects model with the Mantel-Haenszel method would be operated. Thus we performed a sensitivity analysis to confirm the robustness of our results. Fourth, the effects of age, disease etiology, preoperative CDVA, reasons of loss to follow-up, and other factors were not analyzed due to the insufficient information of enrolled studies.

Further studies of high quality and multicenter randomized controlled trials with long-term follow-up, larger sample, and more complete postoperative outcomes should be conducted to compare the outcomes of IC-IOL and SF-PCIOL implantations and to confirm our results. The results of our study indicated that IC-IOL and SF-PCIOL implantations are both satisfactory in correcting aphakia without sufficient capsular support to hold an IOL in the posterior capsule. Implantation with IC-IOL has a more simple procedure and shorter learning curve; however, surgeons should be careful in considering IC-IOL implantation in patients with smaller anterior chamber depth and endothelial cells less than 800/mm². When conditions allow, the treatment method should be decided by the patient and surgeon together.

Acknowledgments

Disclosure: **W. Jing**, None; **L. Guanlu**, None; **Z. Qianyin**, None; **L. Shuyi**, None; **H. Fengying**, None; **L. Jian**, None; **X. Wen**, None

References

1. Briszi A, Prahs P, Hillenkamp J, Helbig H, Herrmann W. Complication rate and risk factors for intraoperative complications in resident-performed phacoemulsification surgery. *Graefes Arch Clin Exp Ophthalmol*. 2012;50:1315-1320.
2. Chiu CS. 2013 update on the management of posterior capsular rupture during cataract surgery. *Curr Opin Ophthalmol*. 2014;25:26-34.
3. Bhagat N, Nissirios N, Potdevin L, et al. Complications in resident-performed phacoemulsification cataract surgery at New Jersey Medical School. *Br J Ophthalmol*. 2007;91:1315-1317.
4. Tarbet KJ, Mamalis N, Theurer J, Jones BD, Olson RJ. Complications and results of phacoemulsification performed by residents. *J Cataract Refract Surg*. 1995;21:661-665.
5. Kirby DB. Procedures in intracapsular cataract extraction: a new method. *Trans Am Ophthalmol Soc*. 1941;39:115-130.
6. Hennig A, Johnson GJ, Evans JR, et al. Long term clinical outcome of a randomised controlled trial of anterior chamber

- lenses after high volume intracapsular cataract surgery. *Br J Ophthalmol*. 2001;85:11-17.
7. Tabatabaei A, Kiarudi MY, Ghassemi F, et al. Evaluation of posterior lens capsule by 20-MHz ultrasound probe in traumatic cataract. *Am J Ophthalmol*. 2012;153:51-54.
 8. Konradsen TR, Zetterstrom C. A descriptive study of ocular characteristics in Marfan syndrome. *Acta Ophthalmol*. 2013; 91:751-755.
 9. Zadeh N, Bernstein JA, Niemi AK, et al. Ectopia lentis as the presenting and primary feature in Marfan syndrome. *Am J Med Genet A*. 2011;155A:2661-2668.
 10. Stein HA. Aphakia-selection of patients contact lenses, intraocular lenses or spectacles: review of 1,000 cataract operations. *Contact Intraocul Lens Med J*. 1981;7:210-218.
 11. Titiyal JS, Sinha R, Sharma N, Sreenivas V, Vajpayee RB. Contact lens rehabilitation following repaired corneal perforations. *BMC Ophthalmology*. 2006;6:11.
 12. Kim DH, Kim JH, Kim SJ, Yu YS. Long-term results of bilateral congenital cataract treated with early cataract surgery, aphakic glasses and secondary IOL implantation. *Acta Ophthalmol*. 2012;90:231-236.
 13. Chia A, Johnson K, Martin F. Use of contact lenses to correct aphakia in children. *Clinical Exp Ophthalmol*. 2002;30:252-255.
 14. Lindsay RG, Chi JT. Contact lens management of infantile aphakia. *Clin Exp Optom*. 2010;93:3-14.
 15. Beljan J, Beljan K, Beljan Z. Complications caused by contact lens wearing. *Coll Antropol*. 2013;1:179-187.
 16. Donszhik PC, Porazinski AD. Giant papillary conjunctivitis in frequent-replacement contact lens wearers: a retrospective study. *Trans Am Ophthalmol Soc*. 1999;97:205-220.
 17. Burkhard DH, Augustin AJ. Lens implant selection with absence of capsular support. *Curr Opin Ophthalmol*. 2001; 12:47-57.
 18. Hara T, Hara T. Ten-year results of anterior chamber fixation of the posterior chamber intraocular lens. *Arch Ophthalmol*. 2004;122:1112-1116.
 19. Sawada T, Kimura W, Kimura T, et al. Long-term follow-up of primary anterior chamber intraocular lens implantation. *J Cataract Refract Surg*. 1998;24:1515-1520.
 20. Worst JG, Massaro RG, Ludwig HH. The introduction of an artificial lens into the eye using Binkhorst's technique. *Ophthalmologica*. 1972;164:387-391.
 21. Lett KS, Chaudhuri PR. Visual outcomes following Artisan aphakia iris claw lens implantation. *Eye (Lond)*. 2011;25:73-76.
 22. Mohr A, Hengerer F, Eckardt C. Retropupillary fixation of iris claw lens in aphakia: one-year results of a new surgical technique. *Ophthalmologie*. 2002;99:580-583.
 23. Rijneveld WJ, Beekhuis WH, Hassman EF, Dellaert MM, Geerards AJ. Iris claw lens: anterior and posterior iris surface fixation in the absence of capsular support during penetrating keratoplasty. *J Refract Corneal Surg*. 1994;10:14-19.
 24. Schallenberg M, Dekowski D, Hahn A, Laube T, Steuhl KP, Meller D. Aphakia correction with retropupillary fixated iris-claw lens (Artisan) - long-term results. *Clin Ophthalmol*. 2014;8:137-141.
 25. Mohr A, Hengerer F, Eckardt C. Retropupillary fixation of the iris claw lens in aphakia. *Ophthalmologie*. 2002;99:580-583.
 26. De Silva SR, Arun K, Anandan M, Glover N, Patel CK, Rosen P. Iris-claw intraocular lenses to correct aphakia in the absence of capsule support. *J Cataract Refract Surg*. 2011;37:1667-1672.
 27. Yasukawa T, Suga K, Akita J, Okamoto N. Comparison of ciliary sulcus fixation techniques for posterior chamber intraocular lenses. *J Cataract Refract Surg*. 1998;24:840-845.
 28. Bellamy JP, Queguiner F, Salame N, Montard M. Secondary intraocular lens implantation: methods and complications. *J Fr Ophthalmol*. 2000;23:73-80.
 29. Teng H, Zhang H. Comparison of Artisan iris-claw intraocular lens implantation and posterior chamber intraocular lens sulcus fixation for aphakic eyes. *Int J Ophthalmol*. 2014;7: 283-287.
 30. Hazar L, Kara N, Bozkurt E, Ozgurhan EB, Demirok A. Intraocular lens implantation procedures in aphakic eyes with insufficient capsular support associated with previous cataract surgery. *J Refract Surg*. 2013;29:685-691.
 31. Saleh M, Heitz A, Bourcier T, et al. Sutureless intrascleral intraocular lens implantation after ocular trauma. *J Cataract Refract Surg*. 2013;39:81-86.
 32. Downs SH, Black N. The feasibility of creating a checklist for the assessment of the methodological quality both of randomised and non-randomised studies of health care interventions. *J Epidemiol Community Health*. 1998;52: 377-384.
 33. DerSimonian R, Kacker R. Random-effects model for meta-analysis of clinical trials: an update. *Contemp Clin Trials*. 2007;28:105-114.
 34. Zintzaras E, Ioannidis JP. Heterogeneity testing in meta-analysis of genome searches. *Genet Epidemiol*. 2005;28: 123-137.
 35. Lau J, Ioannidis JP, Schmid CH. Quantitative synthesis in systematic reviews. *Ann Intern Med*. 1997;127:820-826.
 36. Egger M, Davey Smith G, Schneider M, Minder C. Bias in metaanalysis detected by a simple, graphical test. *BMJ*. 1997; 315:629-634.
 37. Begg CB, Mazumdar M. Operating characteristics of a rank correlation test for publication bias. *Biometrics*. 1994;50: 1088-1101.
 38. Zheng D, Wan P, Liang J, Song T, Liu Y. Comparison of clinical outcomes between iris-fixated anterior chamber intraocular lenses and scleral-fixated posterior chamber intraocular lenses in Marfan syndrome with lens subluxation. *Clin Experiment Ophthalmol*. 2012;40:268-274.
 39. Farrahi F, Feghhi M, Haghi F, Kasiri A, Afkari A, Latifi M. Iris claw versus scleral fixation intraocular lens implantation during pars plana vitrectomy. *J Ophthalmic Vis Res*. 2012;7: 118-124
 40. Menezo JL, Martinez MC, Cisneros AL. Iris-fixated Worst claw versus sulcus-fixated posterior chamber lenses in the absence of capsular support. *J Cataract Refract Surg*. 1996;22:1476-1484.
 41. Hara S, Borkenstein AFM, Ehmer A, Auffarth GU. Retropupillary fixation of iris-claw intraocular lens versus transscleral suturing fixation for aphakic eyes without capsular support. *J Refract Surg*. 2011;27:729-735.
 42. Chen Y, Liu Q, Xue C, Huang Z, Chen Y. Three-year follow-up of secondary anterior iris fixation of an aphakic intraocular lens to correct aphakia. *J Cataract Refract Surg*. 2012;38: 1595-1601.
 43. Lanzetta P, Bandello FM, Virgili G, Crovato S, Menchini U. Is scleral fixation a safe procedure for intraocular lens implantation? *Doc Ophthalmol*. 1999;97:317-324.
 44. Bourne WM, Nelson LR, Hodg DO. Central corneal endothelial cell changes over a ten-year period. *Invest Ophthalmol Vis*. 1997;38:779-782.