CASE REPORT

Surgical Treatment of Persistent Vaginal Granulation Tissue Using CO_2 Laser Vaporization Under Colposcopic and Laparoscopic Guidance

Benjamin J. Steinberg, DO, Tiffany Mapp, DO, Saifuddin Mama, MD, Karolynn T. Echols, MD

ABSTRACT

Introduction: There have been many reports in the literature on vaginal mesh erosion as a complication of pelvic floor reconstructive surgery. Several reports describe successful surgical excision of the exposed mesh as a resolution. However, in rare cases of mesh erosion, poor surgical outcomes and multiple resection failures have been reported. We describe an innovative surgical approach to persistent vaginal mesh erosion using CO_2 laser vaporization under colposcopic and laparoscopic guidance.

Case Description: A 58-y-old postmenopausal woman first presented with a 3-y history of vaginal discharge and spotting after undergoing a Mentor ObTape transobturator sling (Mentor Corp, Santa Barbara, CA), for the treatment of stress urinary incontinence. Despite surgical removal of the mesh and multiple attempts at cauterization of persistent granulation tissue, her symptoms persisted.

Discussion: Using a CO_2 laser under colposcopic and laparoscopic guidance, we were able to safely expose and remove the remaining portion of retained mesh. To our knowledge, this is the first report describing CO_2 laser vaporization as a surgical approach for the successful treatment of recurrent mesh erosion.

Key Words: CO_2 laser, Vaginal mesh erosion, Granulation tissue.

Cooper University Hospitals, Division of Female Pelvic Medicine and Reconstructive Surgery, Camden, NJ, USA (Drs. Steinberg, Mama, Echols).

Peconic Bay Medical Center, River Head, NY, USA (Dr. Mapp).

Address correspondence to: Benjamin J. Steinberg, 6012 Piazza at Main Street, Voorhees, NJ 08043, USA. Telephone: (856) 325-6622, Fax: (856) 325-6522, E-mail: steinberg-benjamin@cooperhealth.edu

DOI: 10.4293/108680812X13462882736619

INTRODUCTION

The use of polypropylene mesh in midurethral slings for the treatment of stress urinary incontinence is becoming the new gold standard.[1] However, one of the known complications of vaginal mesh placement is mesh erosion with reported occurrences as high as 30%.[2] In cases of recurrent mesh erosions, poor surgical outcomes despite multiple resections have been reported. The purpose of this case report is to describe an innovative surgical approach using CO_2 laser vaporization under colposcopic and laparoscopic guidance for the treatment of persistent granulation tissue due to recurrent vaginal mesh erosion.

CASE REPORT

The patient is a 58-y old woman status post-Mentor ObTape placement in November 2005 who presented with a 3-y history of vaginal discharge and spotting. Physical examination in the office revealed a foreign body at the apex of the vagina. A 1-cm x3-cm portion of the graft material consistent with ObTape was excised in the office. Following this, despite conservative management with vaginal estrogen cream and silver nitrate cautery, the patient was noted to have persistent granulation tissue at the excision site. Subsequently, in April 2008, she underwent a surgical vaginal excision of the foreign body in the operating room. Due to persistent symptoms of vaginal discharge and spotting and subsequent discussions with the patient, a second vaginal mesh excision was repeated with extensive vaginal surgical exploration of her right space of Retzius in August 2008. Because both procedures were unsuccessful, a combined abdominal and vaginal approach was then considered to potentially alleviate these symptoms. Based on previous reports describing success using the CO_2 laser in gynecologic surgery, we performed CO_2 laser vaporization under colposcopic and laparoscopic guidance.

METHODS

The patient was taken to surgery in January 2009. She was placed in a low dorsal lithotomy position to enable access to the vaginal apex and space of Retzius laparoscopically.

Figure 1 demonstrates the preoperative transvaginal view of the apical granulation tissue. We first infiltrated the proposed infraumbilical incision with 5cc of plain 0.25% marcaine and entered the preperitoneal space with the Optiview Trocar (Ethicon Inc., Somerville, NJ). Opening pressures were kept at 12mm Hg. The space of Retzius was accessed by blunt dissection. Following this, right and left lower quadrant 5-mm trocars were introduced under direct visualization. This allowed the Nezhat-Dorsey (C.R. Bard Inc., Madison, GA) suction-irrigator with a unipolar cautery tip and the blunt probe to be inserted safely. The entire space of Retzius was then opened with particular attention being placed to the right side where Cooper's ligament was identified clearly. Accessory obturator vessels were identified **(Figure 2)**. The right paravaginal spaces were then dissected. A second left-sided 5-mm port was then introduced superior and slightly lateral to the left lower quandrant port. An atraumatic bowel grasper was used to deviate the bladder and the bladder neck medially, allowing better exposure to the paravaginal space. Careful dissection was performed until the pubic symphysis and pubic rami were reached. The Space of Retzius was filled with sterile water to protect the area from CO_2 laser injury during vaginal fulguration. Using the colposcope, the remaining granulation tissue located in the right paravaginal space was identified then fulgurated using the CO_2 laser under direct visualization set at a power of 5 W. We then connected the vaginal laser dissection with the suprapubic dissection, increasing the likelihood that the retained mesh could be exposed and removed in its entirety. After ablating a 2-cm x1-cm area of the vagina to a depth between 2mm to 4mm, the remaining 3-cm portion of ObTape was removed from the vagina and sent to pathology for analysis. The vaginal epithelium was reapproximated utilizing 2-0 Monocryl in an interrupted fashion **(Figure 3)**. Cystoscopy revealed a normal-appearing bladder and urethra, as well as efflux of dye from both ureteral orifices. There were no intraoperative complications. Pathology of the mesh confirmed a gross diagnosis of foreign material and fibrous tissue with chronic inflammation without specific pathologic change.

Figure 1. Preoperative trans vaginal view of the apical granulation tissue.

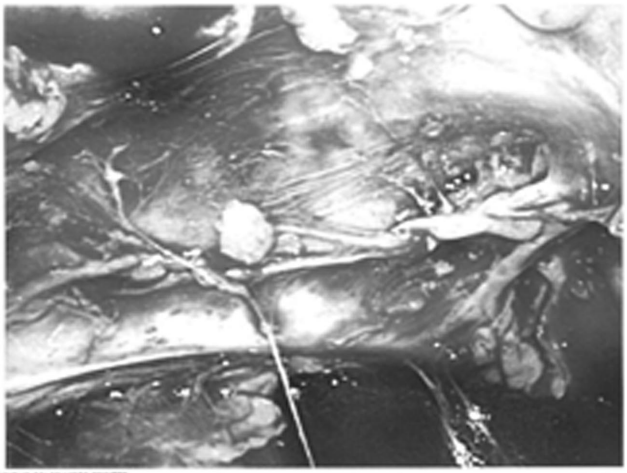

Figure 2. Accessory obturator vessels.

RESULTS

Postoperatively, the patient denied any symptoms of vaginal discharge, vaginal spotting, or dyspareunia. Four

Figure 3. Reapproximation of vigianl epithelium utilizing 2-0 monocryl.

weeks after surgical excision of the mesh, her examination revealed a well-healed vagina without any change in vaginal length. Currently, the patient is 18 mo postprocedure without any complaints of vaginal bleeding, vaginal discharge, or dyspareunia.

DISCUSSION

Vaginal mesh erosion can have a significant impact on a patient's quality of life in the postoperative period. Wohlrab et al.[3] described the most common presentation of vaginal mesh erosions following Merslene suburethral slings to be vaginal discharge, followed by vaginal bleeding, voiding dysfunction, and pain or dyspareunia, respectively. While vaginal estrogen cream may be considered first-line treatment for vaginal mesh erosion, 59% of patients will still require surgical intervention.[4]

Removing mesh from the vagina, particularly at the vaginal vault, can be a difficult task for many vaginal surgeons. A limited surgical field within the vagina results in poor exposure, inadequate visualization, and technically difficult dissections. This may explain previous reports of poor surgical outcomes after multiple attempts of mesh excision. To improve success rates in complicated cases of recurrent vaginal mesh erosions, visualization and exposure must be maximized. Thus, we describe a safe, successful, and reproducible surgical technique for the treatment of recurrent vaginal mesh erosion using colposcopy, laparoscopy, and the CO_2 laser.

In 1963, the development of carbon dioxide light amplification by stimulated emission of radiation (CO_2 LASER) by Kumar Patel[5] marked the beginning of a new age in minimally invasive surgery. A beam of infrared light produced from the CO_2 laser has a wavelength of 10,600nm. Water, a major component of biological tissues, absorbs this frequency of light, making it an effective tool in surgical procedures.

Our decision to utilize the CO_2 laser in this case of vaginal mesh erosion was based on several factors. Today, the CO_2 laser is considered a safe and effective surgical tool for the treatment of many gynecologic conditions, such as endometriosis, cervical intraepithelial neoplasia, condylomas, vulvar and vaginal lesions, as well as Bartholin's gland cysts. Also, advantages of the CO_2 laser in gynecologic surgery include accuracy, precision, rapid healing, minimal tissue destruction, and minimal scar formation.[6] Thus, our goal was to exploit these previously reported advantages of the CO_2 laser and apply them to the vaginal dissection portion of the procedure.

This patient had undergone 2 previous unsuccessful transvaginal mesh excisions in the operating room as indicated by her persistent postoperative symptoms. In both prior procedures, the vaginal epithelium was incised and sharply separated from the underlying adventitia and muscularis layers of the vagina. The Space of Retzius and right paravaginal space were then explored where the remaining piece of mesh was identified and thought to be entirely removed. However, due to her persistent vaginal discharge and granulation tissue postoperatively, we believed that further exploration and removal of any sinus tract or remaining mesh was necessary to resolve her symptoms. It has been our experience that achieving adequate exposure at the vaginal cuff with simultaneous control using a scalpel can be a technically difficult task during mesh excisions. By utilizing the CO_2 laser under colposcopic guidance, we were able to significantly enhance visualization, control, and precision. The colposcope improved vision by magnifying the surgical field, while the laser provided precision during the fulguration of the granulation tissue. Also, the laser provided precise depth control during the vaginal dissection, which helped in minimizing blood loss, as well as identifying the retained mesh.

To ensure patient safety during the vaginal fulguration portion of the procedure, we laparoscopically dissected into the Space of Retzius. This provided us with adequate visualization of the area being fulgurated. Also, filling this area with sterile water, we protected the paravaginal space by absorbing any light from the laser that may penetrate through the vaginal epithelium.

As evidenced by our case report, the CO_2 laser may be a useful tool for the successful treatment of persistent vaginal mesh erosions. In many of these cases, achieving adequate space, visualization, and access to the vaginal apex may be difficult. In these circumstances, the CO_2 laser may assist in overcoming these obstacles frequently encountered during vaginal mesh excisions. To ensure patient safety, we recommend the CO_2 laser under colposcopic and laparoscopic visualization in the hands of experienced surgeons for the treatment of recurrent mesh erosions.

References:

1. Bemelmans BL, Chapple CR. Are slings now the gold standard treatment for the management of female urinary stress incontinence and if so which technique? *Curr Opin Urol.* 2003; 13(4):301–307.

2. Sung VW, Rogers RG, Schaffer JI, et al. Graft use in transvaginal pelvic organ prolapse repair: a systematic review. *Obstet Gynecol.* 2008;112(5):1131–1142.

3. Wohlrab KJ, Erekson EA, Myers DL. Postoperative erosions of the Mersilene® suburethral sling mesh for antiincontinence surgery. *Int Urogynecol J Pelvic Floor Dysfunct.* 2009;20(4):417–420.

4. Deffieux X, Huel C, de Tayrac R, et al. Vaginal mesh extrusion after transvaginal repair of cystocele using a prosthetic mesh: treatment and functional outcome. *J Gynecol, Obstet Biol Reprod.* 2006;35(7):678–684 (French).

5. Patel CKN. Continuous-wave laser action on vibrational-rotational transitions of CO_2. *Phys Rev.* 1964;136(5A):A1187–A1193. doi:10.1103/PhysRev.136.A1187.

6. Adducci JE. Gynecologic surgery using the CO2 laser (light amplification by stimulated emission of radiation). *Int Surg.* 1978;63(2):72–74.