

Transvaginal ultrasound-guided radiofrequency myolysis for uterine myomas[†]

Chung-Hoon Kim^{1,*}, So-Ra Kim¹, Hyang-Ah Lee², Sung-Hoon Kim¹, Hee-Dong Chae¹, and Byung-Moon Kang¹

¹Division of Reproductive Endocrinology and Infertility, Department of Obstetrics and Gynecology, College of Medicine, University of Ulsan, Asan Medical Center, 388-1 Poongnap-dong, Songpa-gu, Seoul 138-736, South Korea ²Department of Obstetrics and Gynecology, Kangwon National University Hospital, Chuncheon-city, Kangwon-do, South Korea

*Correspondence address. Tel: +82-2-3010-3639; Fax: +82-2-3010-6944; E-mail: chnkim@amc.seoul.kr

Submitted on July 9, 2010; resubmitted on November 26, 2010; accepted on December 1, 2010

BACKGROUND: Myolysis is one of the procedures that is claimed to provide significant improvement in myoma status without hysterectomy. Myolysis procedures have been generally performed via laparoscopy, and there are limited data on transvaginal radiofrequency (RF) myolysis. This study investigated the feasibility, efficacy and safety of transvaginal ultrasound-guided RF myolysis.

METHODS: Transvaginal ultrasound-guided RF myolysis was performed on 69 premenopausal women with symptomatic uterine myomas as an outpatient procedure. Outcomes were assessed 1, 3, 6 and 12 months after RF myolysis. Myoma volumes were measured by ultrasonography. Menorrhagia was evaluated by the number of soaked normal-sized sanitary products used per menstrual period and overall symptoms were evaluated using the symptom severity subscale of the uterine fibroids symptom questionnaire.

RESULTS: Mean (\pm SD) age of patients was 39.8 ± 6.5 years. Mean baseline volume of the dominant myomas was 304.6 ± 229.1 cm³ and its volume at 3 months following RF myolysis decreased compared with the previous examination ($P = 0.002$). An improvement of menorrhagia occurred 1, 3, 6 and 12 months after operation (all $P < 0.001$ versus baseline). Overall symptoms at 1, 3, 6 and 12 months after RF myolysis also improved (all $P < 0.001$ versus baseline). No major complications were observed or reported. After 12 months, three patients had successfully conceived and delivered and there were no complications during labor or delivery.

CONCLUSIONS: Transvaginal ultrasound-guided RF myolysis might be a safe, effective and minimally invasive outpatient procedure for uterine myoma in terms of size reduction, symptom improvement and safety.

Key words: transvaginal ultrasound / radiofrequency myolysis / myoma

Introduction

Uterine myomas are the most common pelvic tumors in women of reproductive age. Most myomas are asymptomatic but nearly half of patients with uterine myomas have significant symptoms, including menorrhagia, pain and bulk symptoms. The traditional treatments for symptomatic myomas are laparotomy with hysterectomy or myomectomy, both of which involve considerable morbidity (Guarnaccia and Rein, 2001). In recent years, there is an increasing need for conservative options to treat symptomatic uterine myomas because of the wish to avoid major surgery, the desire to preserve fertility potential and the belief that the uterus plays a role in perceived sexual satisfaction. An ideal conservative treatment for uterine myomas should be

safe, eliminate symptoms, decrease the size of myomas, preserve fertility and have long-term effects. Several procedures including endometrial ablation, uterine artery embolization, high-intensity focused ultrasound and myolysis have been suggested or developed as a conservative treatment to avoid hysterectomy or myomectomy.

Myolysis was introduced in the late 1980s in Europe as a conservative treatment for uterine myoma (Donnez *et al.*, 2000). Myolysis refers to the destruction of uterine myomas by focused energy. Initially, neodymium:yttrium–aluminum–garnet (Nd:YAG) lasers were used to effect coagulative necrosis of myomas and destruction of vascularity by thermomyolysis (Goldfarb, 1992). Subsequently, bipolar electrode, monopolar electrode and cryoprobe have been used as energy sources (Goldfarb, 1995; Phillips *et al.*, 1997; Zreik

[†] Presented and preselected for the Clinical Science Award for poster presentation at the 25th meeting of the European Society of Human Reproduction and Embryology, Amsterdam, The Netherlands, 28 June–1 July 2009.

et al., 1998). Bergamini et al. (2005) reported that laparoscopic radio-frequency (RF) thermal ablation of symptomatic myomas successfully reduced myoma symptoms and volume. Since then, several investigators have reported on the efficacy and safety of the various myolysis techniques (Ghezzi et al., 2007). Among myolysis techniques, transvaginal RF myolysis can be performed as an outpatient procedure without requiring general anesthesia or additional laparoscopic procedures, which is not the case for thermomyolysis and cryomyolysis. However, there are limited data to allow a thorough evaluation of the effectiveness and safety of myolysis and the effects on fertility are uncertain. Moreover, there are few data on transvaginal myolysis because myolysis procedures have been generally performed via laparoscopy. Therefore, the present study was performed to investigate the efficacy and safety of transvaginal ultrasound-guided RF myolysis for the treatment of symptomatic uterine myomas.

Materials and Methods

From October 2004 to October 2008, 69 premenopausal women with symptomatic uterine myomas were enrolled in this study. Subjects who declined hysterectomy or myomectomy were offered transvaginal RF myolysis under transvaginal ultrasound guidance. The main indications for RF myolysis were menorrhagia (60.9%), pelvic pain (11.6%) and bulk symptom (10.1%), and patients were not responsive to medical therapies. Exclusion criteria were the presence of more than three uterine myomas, abnormal cancer screening test results, abnormal coagulation test results, recent pelvic inflammatory disease and current pregnancy. Myoma size was not considered as an exclusion criterion. Seven (10.1%) of all participating patients desired to become pregnant in the near future. All patients were counseled on the potential risks and benefits of transvaginal RF myolysis, and on possible alternative treatments. The institutional review board of the University of Ulsan College of Medicine, Asan Medical Center, approved the study, and all patients provided written informed consent.

Pretreatment evaluation included a transvaginal ultrasound assessment of the number, volume and location of the myomas. RF myolysis of uterine myomas was performed as an outpatient procedure under i.v. sedation using propofol sodium. Patients were placed in the lithotomy position, and monitored using an electrocardiogram and a pulse oximeter. Under transvaginal ultrasound guidance, a 35-cm long 18-gauge needle electrode with an exposed tip at the distal end (BTM 3520, 3530, RF Medical Co., Seoul, South Korea) was inserted through a needle guide that was attached to a transvaginal ultrasound probe. Finding the shortest and safest route under transvaginal ultrasound, the needle electrode was guided to the target myoma through the posterior fornix and/or myometrium and/or other myomas as appropriate. The middle of an exposed tip of the needle electrode was positioned at the center of the target myoma. For patients who anticipated pregnancy in the near future, the needle was inserted so as to avoid the endometrium to prevent endometrial damage.

The needle electrode was connected to a generator (M-2004, RF Medical Co.) that operates at 400 kHz with a maximum power of 120 W and at temperatures ranging from 40°C to 99°C. The generator displays the temperature of the electrode tip as well as tissue impedance characteristics and ablation time. The selected temperature to reach within the tissue was 85°C and the RF generator automatically adjusts the power to maintain the selected temperature. During ablation, cold saline was circulated through an internal water circulation system that applied to the RF generator. This system was applied to reduce the performance time with high output power performance by preventing carbonization between the RF electrode and contiguous tissue. The core of

the target myoma was ablated until the echo-enhanced area by ablation reached 80–90% of the myoma cross section in a real-time ultrasound.

Ultrasound and symptom assessment were performed just before RF myolysis (baseline), and at 1, 3, 6 and 12 months following the RF myolysis. When more than one myoma was treated in a single patient, only the characteristics of the dominant myomas were considered for analysis. The treated myomas could be distinguished and tracked by the location and characteristic changes such as echo-enhanced round zone and secondary cystic change. The evaluation of the uterus and measurement of the myomas were performed by a single researcher who participated in the study, to reduce interobserver variations.

All participants were instructed to use normal-sized pads or tampons as appropriate. Patients were asked how many soaked normal-sized sanitary products were used in a whole period. The number of soaked normal-sized sanitary products used per menstrual period was used to assess menorrhagia. The symptom severity subscale (SSS) of the uterine fibroids symptom (UFS) questionnaire was used to evaluate overall symptoms. Score of the SSS of the UFS addresses both the frequency and severity of symptoms (i.e. menorrhagia and non-bleeding symptoms, such as pelvic pressure, urinary frequency and back and pelvic discomfort), and was calculated from the scores of question numbers 1–8. Patients answered every question, and scores ranged from 1 to 5. Higher scores are indicative of greater symptom severity or bother (Spies et al., 2002).

We evaluated the occurrence of both intraoperative and post-operative minor and major complications in all patients. Minor complications were defined as temporary and self-limiting symptoms requiring no therapy without any clinical sequelae. Major complications were defined as those requiring further interventions and/or hospitalization.

Statistical analysis

All data are presented as mean \pm SD unless stated otherwise. Analysis of variance was used to compare the myoma volumes, the menorrhagia scores and the UFS scores. *P*-values < 0.05 were considered to indicate significance. All analyses were performed using the Statistical Package for the Social Sciences for Windows, version 11.0 (SPSS Inc., Chicago, IL, USA).

Results

The mean patient age was 39.8 ± 6.5 years and the mean BMI was 22.0 ± 2.8 kg/m². Eighteen (26.1%) of 69 subjects had a single uterine myoma and 51 patients (73.9%) had two or three myomas. The location of the dominant myoma was posterior in 36 patients (52.2%), anterior in 19 patients (27.5%), fundal in 10 patients (14.5%) and submucosal in 4 patients (5.8%). Of the 69 patients, 13 planned a pregnancy in the near future.

The mean operation time was 17.8 ± 5.4 min (range 6–35 min). There were no intraoperative complications.

The mean baseline diameter of the treated myomas was 7.9 ± 2.0 cm (4.5–12.5 cm) and the mean volume was 304.6 ± 229.1 cm³ (47.7–1022.1 cm³). Compared with the baseline measurement of the mean myoma volume, RF myolysis resulted in a significant decrease in volume 3, 6 and 12 months after operation (all *P* < 0.001) (Table I). Compared with the mean baseline myoma volume, the volume reduction rate was 19.4% at 1 month, 52.0% at 3 months, 68.6% at 6 months and 74.0% at 12 months postoperation.

Menorrhagia has significantly improved at 1, 3, 6 and 12 months after RF myolysis compared with the baseline assessment (all *P* <

Table I Myoma volume and percentage reduction from baseline after transvaginal RF myolysis in women with symptomatic uterine myoma.

	Baseline	1 month	3 months	6 months	12 months
Total (n = 69)					
Myoma volume (cm ³)	304.6 ± 229.1	245.5 ± 195.4	146.3 ± 127.4 ^{a,b}	95.6 ± 95.1 ^a	79.1 ± 81.7 ^a
Volume reduction	0	19.4%	52.0%	68.6%	74.0%
Patients with myoma <8 cm in a mean diameter (n = 37)					
Myoma volume (cm ³)	133.1 ± 42.8	105.3 ± 38.0 ^{a,c}	55.0 ± 26.8 ^{a,c}	28.8 ± 17.6 ^{a,b}	23.0 ± 14.4 ^a
Volume reduction	0	20.9%	58.7%	78.4%	82.7%
Patients with myoma ≥8 cm in a mean diameter (n = 32)					
Myoma volume (cm ³)	503.0 ± 192.9	407.6 ± 177.4	252.0 ± 115.2 ^{a,c}	172.7 ± 89.6 ^a	144.1 ± 79.3 ^a
Volume reduction	0	19.0%	49.9%	65.7%	71.4%

Values are mean ± SD unless stated otherwise.

^aP < 0.001 versus the baseline assessment.

^bP = 0.002 versus the previous assessment.

^cP < 0.001 versus the previous assessment.

Table II Menorrhagia scores assessed by the number of soaked normal-sized sanitary products used per menstrual period and overall symptom scores assessed by SSS of UFS questionnaire after RF myolysis.

	Baseline	1 month	3 months	6 months	12 months
Total (n = 69)					
Menorrhagia score	44.4 ± 12.0	34.7 ± 10.0 ^{a,b}	26.4 ± 6.7 ^{a,b}	21.2 ± 5.1 ^{a,c}	18.7 ± 4.1 ^a
Overall symptom score	57.0 ± 21.1	43.6 ± 18.2 ^{a,b}	27.0 ± 11.7 ^{a,b}	16.5 ± 9.3 ^{a,b}	12.1 ± 7.3 ^a
Patients with myoma <8 cm in a mean diameter (n = 37)					
Menorrhagia score	37.0 ± 9.2	28.0 ± 8.2 ^{a,b}	22.4 ± 5.6 ^{a,c}	18.7 ± 4.5 ^a	16.4 ± 3.0 ^a
Overall symptom score	42.9 ± 16.9	31.3 ± 13.7 ^{a,b}	20.0 ± 9.6 ^{a,b}	11.1 ± 7.2 ^{a,d}	8.3 ± 5.0 ^a
Patients with myoma ≥8 cm in a mean diameter (n = 32)					
Menorrhagia score	53.0 ± 8.7	42.3 ± 5.2 ^{a,b}	31.2 ± 4.4 ^{a,b}	24.1 ± 4.2 ^{a,b}	21.3 ± 3.5 ^a
Overall symptom score	73.3 ± 11.7	57.9 ± 10.7 ^{a,b}	35.1 ± 8.3 ^{a,b}	22.7 ± 7.6 ^{a,b}	16.6 ± 7.0 ^a

Values are mean ± SD.

^aP < 0.001 versus the baseline assessment.

^bP < 0.001 versus the previous assessment.

^cP = 0.002 versus the previous assessment.

^dP = 0.009 versus the previous assessment.

0.001) (Table II). Overall symptom scores assessed by the SSS of the UFS questionnaire also demonstrated a significant improvement in patients at 1, 3, 6 and 12 months postoperatively compared with the baseline assessment ($P < 0.001$, $P < 0.001$, $P < 0.001$, $P < 0.001$) (Table II).

All patients were discharged on the day of the operation. No post-operative major complications were observed. Lower abdominal pain developed in 32 (46.4%) patients, but spontaneously resolved within 12 h. Vaginal discharge was noticed in 12 (17.4%) patients who had submucosal myomas, but also spontaneously resolved within 2 weeks.

Subsequent to the operation, three (4.3%) patients became pregnant and delivered healthy babies (one Cesarean section and two vaginal deliveries). No patient reported complications during labor or delivery.

Discussion

The present study showed promising results of transvaginal ultrasound-guided RF myolysis in terms of myoma volume reduction and symptom improvement. The results of this study suggest that transvaginal ultrasound-guided RF myolysis may be an alternative to surgery for symptomatic uterine myomas, with encouraging efficacy and safety.

Myolysis using a bipolar RF electrical probe under laparoscopic guidance was described in the 1990s (Phillips *et al.*, 1997). Early studies reported the effectiveness of the procedure, with a marked decrease in myoma volume within 6 months of up to 50% of the original size (Phillips *et al.*, 1997; Bergamini *et al.*, 2005). Ghezzi reported that RF myolysis outcomes at 1–3 years showed encouraging durability

in symptom reduction and quality-of-life improvement (Ghezzi et al., 2007). Although no comparative study with other conservative treatments has been published, symptom improvement rate after myolysis compares favorably with that of myomectomy (Myers et al., 2002) or uterine artery embolization (Spies et al., 2005). The efficacy of myolysis using other energy sources has been reported, such as monopolar coagulation (Goldfarb, 1995), Nd:YAG laser (Nisolle et al., 1993), cryotherapy (Zupi et al., 2004) and MRg (magnetic resonance guided)-focused ultrasound (Stewart et al., 2006). Ghezzi et al. (2007) suggested that RF ablation is the best modality because it is fast, easy, predictable, safe and relatively cheap. They also listed several strengths compared with cryotherapy, such as a smaller probe diameter, a needle track ablation system and a shorter operating time (Ghezzi et al., 2007).

Other myolysis methods require laparoscopic procedures and general anesthesia. However, transvaginal ultrasound-guided RF myolysis can be performed as an outpatient procedure, and results in rapid recovery and resumption of normal activities. Hence, RF myolysis may be more cost-effective and convenient than other methods (e.g. thermomyolysis or cryomyolysis) or laparoscopic myolysis.

In the present study, patients were satisfied that admission was unnecessary. The mean reduction in myoma volume was 68.6% at 6 months post-procedure, which is comparable to the 77% (Bergamini et al., 2005) and 68.8% (Ghezzi et al., 2007) reductions reported for laparoscopic RF myolysis. The present improvement in symptoms at

6 months post-procedure was similar to those reported in previous studies (Phillips et al., 1997; Bergamini et al., 2005; Ghezzi et al., 2007).

There were no major complications, such as penetration or burn injuries of the bowel or bladder, sepsis and peritonitis, in the present group of patients. Donnez et al. (2000) reported a complication after laparoscopic myolysis with Nd:YAG laser involving dense fibrous adhesions between the myoma and the bowel. It has been postulated that the presence of multiple holes in the myoma serosa could increase the risk of post-operative adhesion formation (Donnez et al., 2000). We believe that multiple insertion of the needle electrode into the myoma should be avoided and single insertion of the needle electrode under transvaginal ultrasound guidance can reduce the risk of post-procedure adhesion. Further evaluations should be performed to assess whether RF myolysis might result in post-procedure adhesions (Fig. 1).

The safety of RF myolysis for women whose aim is future pregnancy has not been established. Reported cases of uncomplicated full-term pregnancies indicated that viable pregnancies were possible after laparoscopic myolysis (Phillips et al., 1997). However, several authors reported some adverse outcomes related to subsequent pregnancies, such as uterine rupture (Arcangeli and Pasquarrette, 1997; Vilos et al., 1998). Bergamini et al. (2005) suggested that local tissue destruction without surgical repair might increase the risks of suboptimal healing and the chance of uterine rupture during pregnancy after myolysis. Three patients experienced successful conception and childbirth after the RF myolysis procedure: those patients had intramural-type myomas that were not close to the endometrium, and the endometrium could be spared from coagulation. It is important to carefully select patients for RF myolysis, considering the size and location of the myoma, the age and pregnancy plans of patients.

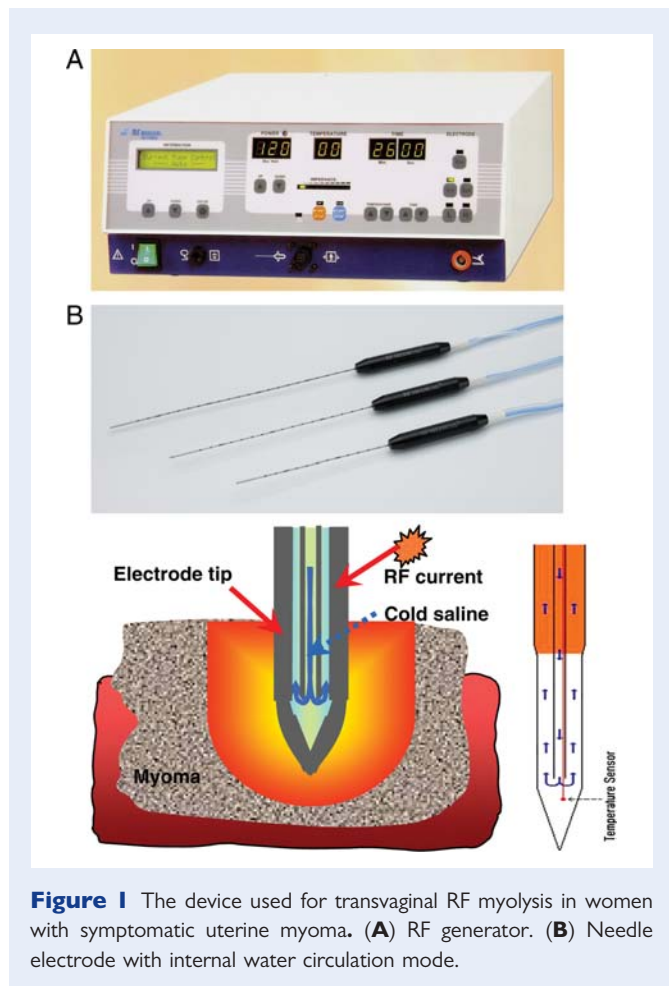
In conclusion, transvaginal RF myolysis for uterine myomas was safe and resulted in a reduction of myoma size and improvement in patient symptoms. RF myolysis seems to be a safe and effective minimally invasive outpatient procedure for uterine myomas. For the confirmation of safety and effectiveness of RF myolysis, more research is needed with randomized studies and longer follow-up.

Author's roles

C.-H.K.: participation in study design, execution in all process, analysis, manuscript drafting and critical discussion. S.-R.K.: participation in study execution as an assistant operator and manuscript drafting. H.-A.L.: participation in study execution as an assistant operator and instructor for patients' education. S.-H.K.: participation in patient selection, counseling of subjects, getting consent and data collection. H.-D.C.: participation in counseling of subjects, getting consent and data collection. B.-M.K.: participation in study design and execution as an operator.

References

- Arcangeli S, Pasquarrette MM. Gravid uterine rupture after myolysis. *Obstet Gynecol* 1997;**89**:857.
- Bergamini V, Ghezzi F, Cromi A, Bellini G, Zanconato G, Scarperi S, Franchi M. Laparoscopic radiofrequency thermal ablation: a new approach to symptomatic uterine myomas. *Am J Obstet Gynecol* 2005; **192**:768–773.



- Donnez J, Squifflet J, Polet R, Nisolle M. Laparoscopic myolysis. *Hum Reprod Update* 2000;**6**:609–613.
- Ghezzi F, Cromi A, Bergamini V, Scarperi S, Bolis P, Franchi M. Midterm outcome of radiofrequency thermal ablation for symptomatic uterine myomas. *Surg Endosc* 2007;**21**:2081–2085.
- Goldfarb HA. Nd:YAG laser laparoscopic coagulation of symptomatic myomas. *J Reprod Med* 1992;**37**:636–638.
- Goldfarb HA. Bipolar laparoscopic needles for myoma coagulation. *J Am Assoc Gynecol Laparosc* 1995;**2**:175–179.
- Guarnaccia MM, Rein MS. Traditional surgical approaches to uterine fibroids: abdominal myomectomy and hysterectomy. *Clin Obstet Gynecol* 2001;**44**:385–400.
- Myers ER, Barber MD, Gustilo-Ashby T, Couchman G, Matchar DB, McCrory DC. Management of uterine leiomyomata: what do we really know? *Obstet Gynecol* 2002;**100**:8–17.
- Nisolle M, Smets M, Malvaux V, Anaf V, Donnez J. Laparoscopic myolysis with the Nd:YAG laser. *J Gynecol Surg* 1993;**9**:95–99.
- Phillips DR, Milim SJ, Nathanson HG, Haselkorn JS. Experience with laparoscopic leiomyoma coagulation and concomitant operative hysteroscopy. *J Am Assoc Gynecol Laparosc* 1997;**4**:425–433.
- Spies JB, Coyne K, Guaou G, Gyaou N, Boyle D, Skyrmarz-Murphy K, Gonzalves SM. The UFS-QOL, a new disease-specific symptom and health-related quality of life questionnaire for leiomyomata. *Obstet Gynecol* 2002;**99**:290–300.
- Spies JB, Bruno J, Czeyda-Pommersheim F, Magee ST, Ascher SA, Jha RC. Long-term outcome of uterine artery embolization of leiomyomata. *Obstet Gynecol* 2005;**106**:933–939.
- Stewart EA, Rabinovici J, Tempany CM, Inbar Y, Regan L, Gostout B, Hesley G, Kim HS, Hengst S, Gedroyc WM. Clinical outcomes of focused ultrasound surgery for the treatment of uterine fibroids. *Fertil Steril* 2006;**85**:22–29.
- Vilos GA, Daly LJ, Tse BM. Pregnancy outcome after laparoscopic electromyolysis. *J Am Ass Gynecol Laparosc* 1998;**5**:289–292.
- Zreik TG, Rutherford TJ, Palter SF, Troiano RN, Williams E, Brown JM, Olive DL. Cryomyolysis, a new procedure for the conservative treatment of uterine fibroids. *J Am Assoc Gynecol Laparosc* 1998;**5**:33–38.
- Zupi E, Piredda A, Marconi D, Townsend D, Exacoustos C, Arduini D, Szabolcs B. Directed laparoscopic cryomyolysis: a possible alternative to myomectomy and/or hysterectomy for symptomatic leiomyomas. *Am J Obstet Gynecol* 2004;**190**:639–643.