

Imaging tools transform diagnosis of osteoporosis

May 06, 2010

By [Giuseppe Guglielmi, MD](#) [1] and [Giacomo Scalzo, MD](#) [2]

Bone mineral density measurements of the axial and appendicular skeleton are an important part of the diagnosis and follow-up of metabolic bone disease.

Bone mineral density measurements of the axial and appendicular skeleton are an important part of the diagnosis and follow-up of metabolic bone disease. This is particularly true for osteoporosis, a disorder characterized by compromised bone strength. The reduction in density and quality of bone leads to an increased risk of fracture.

The incidence of osteoporotic fractures increases with age. Osteoporosis could, consequently, become a significant social/healthcare problem in developed countries where the population is aging.

An early diagnosis of osteoporosis is fundamental to preventing complications and unnecessary suffering. This is now possible using precise imaging methods. The two main aims of imaging are to identify the presence of osteoporosis, and to calculate bone mass using semiquantitative or quantitative methods. Conventional radiography is typically used for the former, densitometric techniques for the latter.

The radiological appearance of osteoporosis is essentially always the same, irrespective of the cause. Osteoporosis is still most commonly diagnosed on conventional radiography, a modality that is widely available. This is despite the advent of newer, highly accurate and precise quantitative diagnostic imaging techniques, such as dual x-ray absorptiometry (DXA) and quantitative CT (QCT). Conventional radiography is useful, both alone and in conjunction with CT or MRI, when detecting complications of osteopenia (e.g., fractures), for the differential diagnosis of osteopenia, or for follow-up examinations in specific clinical settings, such as progression of soft tissue calcifications, or signs of secondary hyperparathyroidism and osteomalacia in renal osteodystrophy. It is relatively insensitive to the detection of early disease, though. A substantial amount of bone loss (~30%) must occur before it can be detected on x-ray images. Variations in radiographic exposure factors, film development, and patients' soft tissue thickness can also make it difficult to diagnose early signs of osteoporosis.

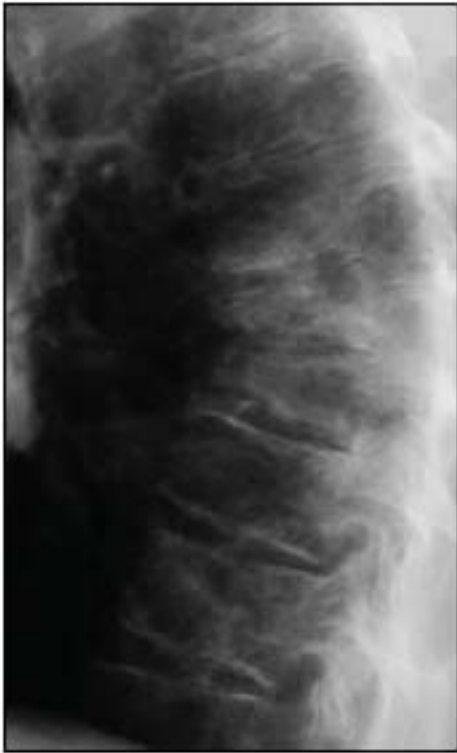

FIGURE 1. Lateral radiograph of dorsal spine shows severe osteoporosis with multiple fractures of vertebral endplates leading to biconcave deformities of vertebrae.

The main radiographic features of generalized osteoporosis are cortical thinning and increased radiolucency.¹ Vertebral fractures are a frequent complication of osteoporosis. Although osteopenia cannot be diagnosed reliably from plain-film x-ray images, spinal radiography can help considerably when diagnosing and following up vertebral fractures (Figure 1). Vertebral height measurements can also be made on plain-film x-rays, reducing subjectivity. Compression fractures can occur anywhere in the spine, although T4-L4 is the most common site. A vertebral fracture appears as an alteration in the shape and size of the vertebral body. A wedge is seen when the anterior vertebral body height is reduced in relation to posterior height. Reduced mid height in relation to posterior height is visualized as an endplate (mono- or biconcave), and when all heights of a vertebra are reduced in relation to the dimensions of adjacent vertebrae, this is seen as a crush, or collapse, vertebral deformity.

The posterior height of the thoracic vertebrae is normally 1 to 3 mm greater than the anterior height. A height loss of more than 4 mm is consequently considered a true vertebral fracture deformity. This criterion is also used for lumbar vertebrae, although differences between anterior and posterior heights are not as large in lumbar vertebrae as they are in the thoracic spine. The shape of vertebrae and their dimensions, as well as their posterior border, should be compared with those of adjacent vertebrae when defining a fracture.²

Another common method of defining fractures, specifically when looking at a vertical deformity in T4-L4, is a height loss of more than 20% together with a reduction in area greater than 10% to 20%.³ This fracture threshold, based on visual observations on radiographs, can then be used to grade the severity of a vertebral fracture semiquantitatively. Four grades may be differentiated:

Four grades may be differentiated:

- grade 0: no fracture;
- grade 1: mild fracture (reduction in vertebral height = 20% to 25%);
- grade 2: moderate fracture (reduction in vertebral height = 25% to 40%); and
- grade 3: severe fracture (reduction in vertebral height, >40%).

A spinal fracture index can be calculated from this semiquantitative assessment as the sum of all grades assigned to the vertebrae divided by the number of vertebrae evaluated. Involvement of multiple vertebral bodies leads to kyphosis of the thoracic spine, a clinically obvious deformity known as dowager's hump.

DXA

The likelihood of an osteoporosis patient suffering a fracture depends on several factors, including a propensity to fall, the nature of any falls that do occur, and the response to those accidents. The patient's bone density is also an important factor in predicting fracture. Approximately 60% to 70% of bone strength is related to bone mineral density.

Accurate and reproducible methods to quantify the bone density of the skeleton can help diagnose osteoporosis early, predict fracture risk, determine therapeutic intervention, and monitor response to therapy and changes with time. Judgments of bone mineral density made from plain-film x-rays can, however, be imprecise.

Dual-energy x-ray absorption (DXA) was introduced in 1987 and, to date, represents the most widely used method of diagnosing osteoporosis in clinical practice. The World Health Organization (WHO) used the DXA technique when defining its threshold levels for the diagnosis of osteopenia and osteoporosis.⁴ DXA-based measurements of bone densitometry are currently the gold standard for clinical diagnosis of osteoporosis.

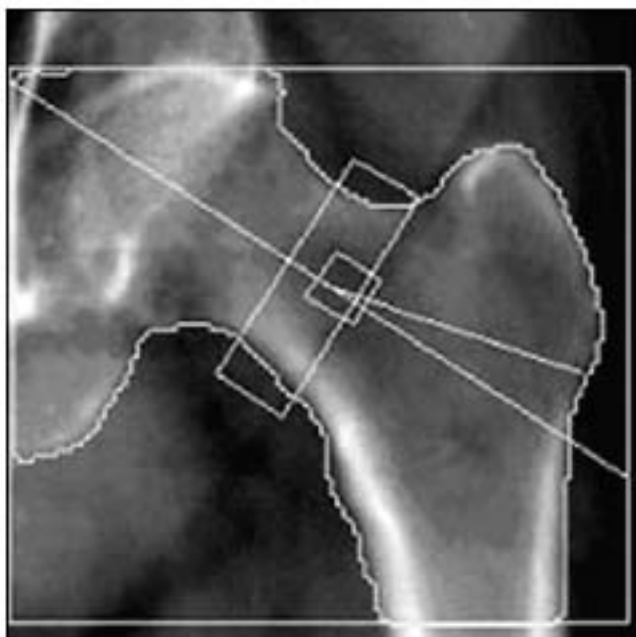


FIGURE 2. DXA Image of well-positioned left hip obtained with slightly abducted and internally rotated leg to avoid foreshortening of neck.

DXA can be applied to all skeletal sites where osteoporotic fractures occur. These include the lumbar spine (L1-L4) and proximal femur (total hip, femoral neck, trochanter, and Ward's area) (Figure 2) in the central skeleton. DXA can also be applied to peripheral skeletal sites, such as the forearm and calcaneus, using either full-sized or dedicated peripheral DXA scanners.

DXA provides the mass of bone mineral content (BMC) in grams and the projected area of the measured site in square centimeters. Bone mineral density (BMD) is taken as the bone mineral content divided by the area and is given in units of g/cm^2 . Densitometric findings are expressed as a planar density.

Bone mineral density results are provided as a "standard deviation" by means of a T-score and a Z-score. The T-score, which refers to the peak of bone mass, is calculated as the difference between the bone mineral density of the patient under examination and that of a healthy young adult. The Z-score is taken as the difference between the patient's results and the mean of age- and gender-matched controls.

The WHO classification on disease severity, based on T-scores, can be seen in the table on this page.

TABLE 1. WHO OSTEOPOROSIS SEVERITY CLASSIFICATION

Normal	T-score >-1
Osteopenia	T-score -1 to -2.5
Osteoporosis	T-score <-2.5
Severe osteoporosis	T-score <-2.5 with radiological evidence of one or more fractures

This definition applies to DXA measurements made in the lumbar spine, the proximal femur, and the forearm. Whole-body scanning can also be performed with the appropriate software. This will allow whole-body and regional bone mineral content to be determined, as well as whole-body and regional body composition, lean (muscle) mass, and fat mass.⁵

As the DXA image is a 2D image of a 3D object, this is an “areal,” rather than a true volumetric, density; the depth of the bones cannot be taken into account with a single anteroposterior projection. This illustrates one of the limitations of DXA, as the measurement is size-dependent. This is a particular problem in children, in whom bones change markedly in size as they grow, especially during puberty, and in patients whose disease might result in their being small in stature or having slender, small bones.

Another downside to DXA is the tendency for imaging artifacts to cause inaccuracies. These artifacts are most common in the lumbar spine, particularly in the more elderly population. All calcium in the path of the x-ray beam will contribute to the measured bone mineral density. Aortic calcifications, scoliosis, degenerative disc disease with osteophytes, osteoarthritis with hyperostosis of the facet joints, and/or vertebral fractures will all falsely elevate the bone mineral density measurement.⁶ Advantages of DXA include high precision, relatively low cost, and a low radiation dose (similar to that of natural background radiation).

QUANTITATIVE CT

QCT differs from DXA in that it provides separate estimates of the bone mineral density for trabecular and cortical bone. This is provided as a true volumetric mineral density in mg/cm³. The technique can be performed at axial sites and peripheral sites.

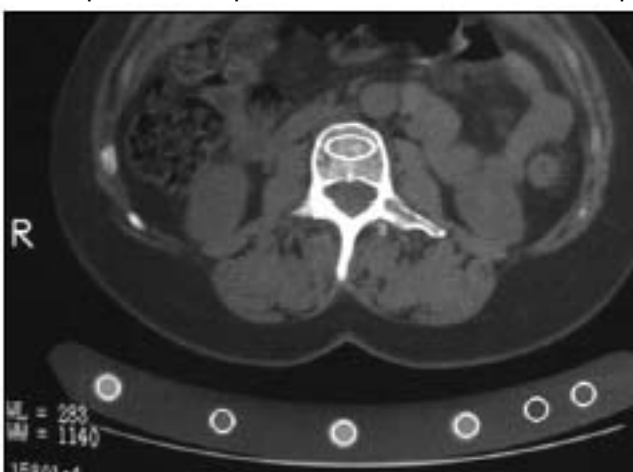

FIGURE 3. QCT axial view with region of interest placed in vertebral body and calibration device under patient.

Measurements of trabecular bone in consecutive vertebrae of the spine (usually two to four vertebrae between T12 and L4) can be made from axial CT images using a bone mineral reference standard to calibrate each scan (Figure 3). Results are usually given as T-scores and Z-scores, as for all bone densitometry techniques. The ability of QCT to predict vertebral fractures and provide serial measurements of bone loss is

excellent. Its sensitivity is generally better than projection methods, such as DXA, because it performs a selective assessment of metabolically active and structural trabecular bone in the center of the vertebral body. The selective trabecular measurement also makes QCT sensitive to changes over a short follow-up period. The density of trabecular tissue is considered the main factor determining compressive strength in the vertebrae. Another advantage of QCT over DXA is the exclusion of structures that do not contribute to the spine's mechanical resistance. These irrelevant structures will be included in DXA bone density measurements.⁷

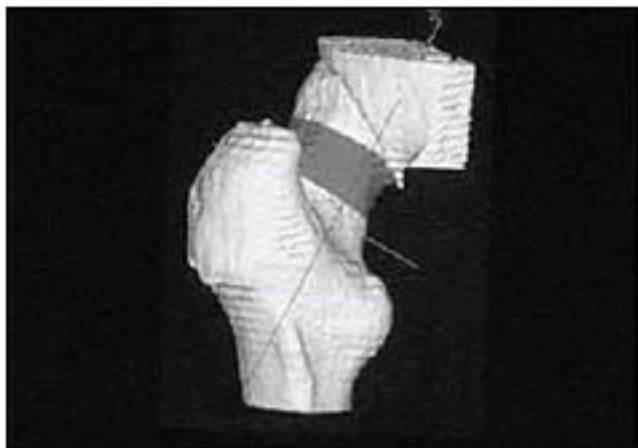


FIGURE 4. QCT 3D reconstruction of hip showing femoral neck region.

QCT measurements have traditionally been based on a two-compartment characterization of vertebral trabecular bone. Three-compartment, or volumetric, QCT is a new technique that can improve spinal measurements and extend QCT assessments to the proximal femur. Volumetric QCT devices acquire data on the entire object of interest as a series of stacked slices, or spiral CT scans. Anatomic landmarks can be used to generate relevant projections automatically (Figure 4). In addition to determining the bone mineral density of the entire bone or a subregion, such as a vertebral body or femoral neck, volumetric QCT can also provide a separate analysis of trabecular or cortical components.⁸

QCT has several disadvantages that have limited its widespread application. These include a high radiation dose, poor precision that limits the technique's applicability to longitudinal assessments, the high cost of scanners, a high degree of operator dependence, large area required to house the scanner, and limited access to the scanners. Access is limited because generally the CT unit is also used for other kinds of studies (head, neck, chest, abdomen, pelvis, etc.).

A peripheral QCT (pQCT) device has been developed to obviate the limitations of DXA and axial QCT. This device not only allows separate assessments of cortical and trabecular bone, but it also provides direct information on bone geometry at several appendicular sites. The analysis of cross-sectional images provided by pQCT yields information on the mass and distribution of bone material, which can be integrated into indices of bone stability in response to bending and torsional loads. These are the most important biomechanical measures of susceptibility to fracture and may improve accuracy in the prediction of fractures.

QUANTITATIVE ULTRASOUND

Quantitative ultrasound may also be used to measure parameters relevant to bone mineral density and to assess tissue properties. This method of assessing osteoporosis has many advantages. The modality is small, measurements can be made quickly and easily, no ionizing radiation is involved, and the cost of the device is low compared with DXA and QCT devices.

Most quantitative ultrasound devices are used to predict the risk of osteoporotic fracture at the moment. Ultrasound waves are affected by the elasticity and structure of the material they are passing through and can potentially yield information on bone fragility.

The skeletal site of measurement, precision, accuracy, variables measured, and normalized data vary among commercial quantitative ultrasound devices. For example, all devices rely on transit time velocity measurements, that is, the time needed for the ultrasound signal to arrive at the receiving transducer. The velocity parameter chosen, however, will depend on the system. The range includes bone velocity, heel velocity, speed of sound (independent of attenuation from the ultrasound), and amplitude-dependent speed of sound. Speed of sound is usually measured by

quantitative ultrasound methods applied to the calcaneus, radius, and tibia. Amplitude-dependent speed of sound is typically measured using a phalangeal device.

Broadband ultrasound attenuation is another important parameter. This is the slope at which attenuation increases with frequency and is generally measured in the frequency range 0.2 MHz to 0.6 MHz. Velocity and broadband ultrasound attenuation both provide quantitative information on the interaction between ultrasound and the medium.⁹ Theory suggests that broadband ultrasound attenuation is determined by bone density and bone microarchitecture, whereas speed of sound is influenced by the elasticity of bone and bone density. Studies of human calcaneal specimens have shown that quantitative ultrasound is a good indication of bone mineral density and, to a lesser extent, bone microarchitecture.¹⁰

The calcaneus is the most common skeletal site for quantitative ultrasound assessment. One reason is its high percentage of trabecular bone (95%), which is replaced more often than cortical bone, providing early evidence of metabolic changes. The calcaneus is also easily accessible and has mediolateral surfaces that are fairly flat and parallel, reducing repositioning error.

Several studies have defined and confirmed the role of quantitative ultrasound in the assessment of bone status in a large variety of situations and pathological bone conditions. The method can be applied to children, newborns, and preterm infants as well as to the adult population.

Basic science studies have tried to solve most issues related to quantitative ultrasound technique. For example, microimaging tools are being developed to examine specific aspects of bone quality. Once these new technologies are available in clinical practice, the efficacy of quantitative ultrasound methods in managing osteoporosis is expected to improve.

In summary, each of the different methods of measuring bone density has its own strengths and limitations. Radiologists should be aware of the artifacts that can cause inaccuracies, and understand the implications of measurement results for patient management.

Disclosures:**Source URL:**

<http://www.diagnosticimaging.com/articles/imaging-tools-transform-diagnosis-osteoporosis>

Links:

[1] <http://www.diagnosticimaging.com/authors/giuseppe-guglielmi-md>

[2] <http://www.diagnosticimaging.com/authors/giacomo-scalzo-md>