PHRENIC EVULSION IN THE TREATMENT OF PULMONARY TUBERCULOSIS.*

By B. W. ANDERSON, M.A., M.D., D.P.H.

THE history of phrenic evulsion, the anomalies of the phrenic nerve, the technique and possible dangers of the operation, are all, doubtless, sufficiently well known not to require any further mention. A brief reference to the action of the diaphragm will be made, as it is of some importance in considering the effect of the paralysis on the lung.

The effects on the lung of complete paralysis of the hemidiaphragm have been differently interpreted by various authorities. It was originally thought that the rising diaphragm compressed the base of the lung, and the operation was therefore held to be particularly applicable to cases of lower-lobe disease. There is no doubt that the diaphragm, by increasing the intrathoracic negative pressure, is concerned to some extent in the aeration of all areas of the lung: whether it has a greater effect on one area than another is a debatable point.

Sir Arthur Keith[1] has brought convincing evidence to show that the apex of the lung, and particularly the posterior part of the apex, is largely dependent on diaphragmatic action for its proper aeration. Sir Charlton Briscoe,[2] although differing with Keith on certain details, was of a similar opinion. The importance of the diaphragm in expanding the apex of the lung has not been disputed to any extent, and controversy has chiefly ranged round the question of the action of the diaphragm on the lower ribs. Keith, Briscoe, and Dally[3] all agreed with the original view of Duchenne that the action of the diaphragm on the lower ribs was to assist the external intercostal muscles in raising the ribs and widening the subcostal angle. Hoover[4] held that the action of the diaphragm was antagonistic to the external intercostal muscles, and that contraction of the diaphragm tended to pull the lower ribs towards the middle line and lessen the subcostal angle. He produced a mass of experimental and clinical evidence in support of his opinions.

If Hoover's contentions are correct, a unilateral phrenic evulsion ought to produce increased freedom of movement of the lower ribs and widening of the subcostal angle in the side

* Read at a Meeting of the Tuberculosis Society of Scotland on 21st April 1933.

of the operation, as the restraining action of the diaphragm will be lost and the external intercostal muscles free to act. In this series, 36 cases were carefully studied to see if any change in movement took place following evulsion of the phrenic nerve on one side. In 11 cases, or 34·4 per cent., there was definite increased freedom of movement of the costal margin and widening of the subcostal angle on the affected side; in 5, or 15·6 per cent., it was less well marked but present; in 6, it was indefinite; and in 10, no change took place. In the majority of those cases in which the change was indefinite or absent, there was extensive lung involvement with fairly marked contraction and fixation of the side. Where marked shrinkage and fixation of the chest is present, little change can be expected; and if it does occur, the asymmetry of the chest makes detection of the change difficult. One may regard the figures that increased movement was present in 50 per cent. of cases as an understatement; actually it was present in the majority of cases where the pathologic process was not too advanced or too chronic to prevent or obscure the change.

The clinical observations in this series certainly lend support to Hoover's explanation of diaphragmatic movement. The fact that the apex of the lung relies largely for its proper aeration on free diaphragmatic movement, and the fact that increased movement of the lower ribs on the side of paralysis follows phrenic evulsion, incline one to agree that unilateral paralysis of the diaphragm will produce a greater degree of rest in the apex of the lung than elsewhere. This point will again be referred to in discussing the actual cases.

Following phrenic evulsion, certain clinical changes occur which usually, if the case has been examined before and after operation, enable one to tell in the majority of instances whether paralysis has occurred. These signs—loss of the normal inspiratory propulsion of the epigastrium, increased freedom of movement of the lower ribs, loss on one side of the normal resistance felt on descent of the diaphragm, and rise of the lower limit of pulmonary resonance on one side—are not by themselves diagnostic of phrenic paralysis, and confirmation should be made in every case by X-ray.

Immediately on paralysis the diaphragm takes up the position of expiration and is maintained there by the positive intra-abdominal and negative intrathoracic pressures. Its fixation is, however, only relative, in that during inspiration

the descent of the acting half, by increasing intra-abdominal pressure, pushes the inert and paralysed half up; during expiration the movement is reversed. This so-called paradoxical movement, or Kienbock's phenomenon, is typical and diagnostic of paralysis. Where it is not well seen it can be elicited by asking the patient to sniff or to attempt to inspire with the mouth and nose closed (Bittorf's sign).

Accurate measurement of the actual rise of the diaphragm after phrenic evulsion is difficult, and this probably accounts in part for the variations in the results obtained by different workers. It is essential for comparison that successive radiograms of a case be taken under identical conditions and this is not always possible. In this series the average rise on the right side was 4·9 cm., and on the left 4·2 cm.; the greatest rise was 7·6 cm., occurring on the right, and the least 2 cm.; the greatest rise on the left was 7 cm. It has been the general finding to get a higher average rise on the right, but there is no reason why this should be so. Morriston Davies[5] reports more cases with a big rise occurring on the left side than on the right, and Moore[6] had, in his series, a higher average rise on the left.

The immediate rise of the diaphragm following operation is not necessarily maximum; it may continue to rise for several months. Following evulsion of the nerve, the paralysed hemidiaphragm cannot do more than assume the position of expiration. Abolition of the inspiratory tug of the diaphragm and the fall in intrathoracic negative pressure result in relaxation of the elastic tension of the lung and shrinkage of lung volume. The fall in intrathoracic negative pressure is felt by the whole lung and a degree of relaxation of the whole lung therefore occurs. Where a lesion is fibrosing, the effect of the relaxation of the elastic tension will be to increase its tendency to contract. Gradually increasing elevation of the diaphragm has been observed by serial radiograms in several cases, and in each, the gradual rise was seen to proceed side by side with increased shrinkage of a fibrosing lesion. How far the gradual elevation is due to atrophy of the hemidiaphragm and easier displacement upward by the positive intra-abdominal pressure, and how far due to the increased contraction of fibrosing lesions and reduction in lung volume, it is difficult to say. Probably both factors come into play, but it would appear that the latter is the determining factor in the ultimate height attained by the diaphragm.

Matson[7] declared that the benefit derived from the operation was dependent on the height to which the diaphragm rose. This statement is not acceptable. Of the cases in this series which showed a big rise, the majority certainly did very well, but they were all cases in which fibrotic change was established and in which marked shrinkage of the lesions took place: a few cases with a big rise did badly. The important factor is promotion of pulmonary rest and relaxation by abolishing diaphragmatic movement, and the ultimate height attained by the diaphragm may be regarded as an indication of the amount of contraction that has taken place. That cessation of movement is of primary importance does not necessarily mean that a diaphragm already raised and relatively fixed is a contra-indication to operation. Some writers (Yates,[8] Aycock and Habliston[9]) declare that no result can be expected with a fixed diaphragm. In one instance in this series, the right diaphragm was 3·9 cm. above the left and showing no movement before evulsion of the nerve: after operation it continued to rise until it was 10·2 cm. above the left, and great reduction in size of the fibroid right upper lobe took place. A fixed diaphragm is not atonic, and the loss of tone and atrophy following evulsion of the phrenic nerve allow of further displacement upward. A diaphragm showing signs of being pulled up at several points by adhesions is evidence that the lung lesions are fibrosing and attempting to contract. It is an indication for phrenic evulsion; and one might expect a big rise of the diaphragm to follow, but this does not always result.

The reduction in lung volume varies with the height to which the diaphragm rises: the reduction has been given as between 400 and 600 c.c., or one-sixth to one-third of the lung volume. The actual reduction in vital capacity is considerably less than this. Wilson[10] found, in cases not complicated by artificial pneumothorax, an average reduction of 311 c.c. or 18 per cent., and the reduction was least where the lung was extensively involved in disease. O'Brien,[11] in discussing artificial pneumothorax, points out that the vital capacity after inflation is greater than the vital capacity before inflation minus the amount of air introduced. The reason is that the pulmonary tissue around tuberculous foci does not frequently participate in the aeration process, and collapse of these areas does not therefore affect the vital capacity; just as in artificial pneumothorax, collapse of a selective nature and not compression

follows paralysis of the diaphragm, so that the degree of compensation required is not proportionate to the reduction in lung volume. Compensation is required for the normal lung tissue collapsed, and this appears to take place without any increase in respiratory labour, probably due to improved circulation and more efficient utilisation of the oxygen in the inspired air. In no case observed was there any shortness of breath or increase of existing dyspnœa as the result of unilateral phrenic evulsion.

Some displacement of the heart to the opposite side usually follows unilateral diaphragmatic paralysis, but this is seldom marked and practically never gives rise to symptoms. Gastric disturbance occasionally follows the operation, but the symptoms are as a rule slight and transient and seldom call for treatment. Only in one case observed—a left phrenic evulsion with a big rise—was there any complaint: the patient suffered from epigastric discomfort and flatulence for ten days and then symptoms ceased. The presence of a large air bubble in the stomach with a high left diaphragm may be sufficient to cause symptoms, but the comparative absence of symptoms following induced paralysis of the diaphragm contrasts markedly with cases of eventration, where the gastric symptoms first call for investigation. There does not seem to be any adequate explanation of this.

The 51 cases comprising the series will be studied in three groups, according to whether the operation was done (1) as a preliminary to thoracoplasty, (2) in conjunction with artificial pneumothorax, or (3) as a sole operative procedure. In assessing the value of the operation, not only the ultimate results must be taken into account: in many cases the outlook was hopeless and in some of these the operation was done merely to alleviate symptoms; while in a few others it was nothing more than an attempt to help a patient who was getting progressively worse and in whom other methods of treatment were contra-indicated. The latter cases occurred early in the series and with experience gained would not now be considered suitable. A truer estimate of the value of phrenic evulsion as a therapeutic measure in the treatment of pulmonary tuberculosis will be arrived at by studying not only the end-results, but also the individual cases as to whether or not the indications for operation were fulfilled.

I. **Phrenic Evulsion Preliminary to Thoracoplasty** (13 *cases*).—This constitutes one of the most frequent indications

for phrenic evulsion and by many is employed as a routine before every thoracoplasty. The literature shows a remarkable uniformity as to the indications, and the advantages claimed for the operation may be summarised as:—(1) It assists in collapsing the base of the lung and in suitable cases may reduce the number of lower ribs to be resected. (2) In a doubtfully suitable case, it may improve the lung condition and the general condition of the patient sufficiently to make thoracoplasty possible. (3) By collapsing the base, it helps to prevent an aspiration infection of the lower lobe in an upper-stage thoracoplasty. (4) It assists in the closure of a tuberculous empyema. (5) It tests the stability of the opposite lung.

In three instances phrenic evulsion was merely preliminary to thoracoplasty, to assist in giving better collapse. All had dense fibro-caseous disease of the whole of one lung, with the other lung relatively healthy, and the only hope lay in thoracoplasty. No improvement was expected from the diaphragmatic paralysis and in no case could it be said that any special benefit was derived. It has been the generally accepted opinion that every thoracoplasty should be preceded by a phrenic evulsion. At a meeting of this Society last year, however, Morriston Davies declared that while he still considered it should be done as a preliminary in cases which were likely to require only a partial upper thoracoplasty, he did not advise it in cases which, from the nature or extent of the lesion, could be suitably dealt with only by the complete operation. In the latter, to paralyse the diaphragm was to produce a sodden, inert, mass of lung; if phrenic evulsion were omitted, the slight diaphragmatic movements promoted a flow of blood and lymph and prevented complete stasis. I have no personal experience of this, all the thoracoplasties having had a preliminary phrenicectomy, but on theoretical grounds there is much to be said for this view.

In six instances the operation was done in the hope that sufficient improvement would take place to allow of thoracoplasty being safely undertaken later. One case, who was acutely ill and had extensive fibro-caseous disease of the left lung, was quite unbenefited; two others benefited sufficiently to have the major operation, but in neither was the result striking. The remaining three derived great benefit from the operation, the result in two exceeding anything that was expected. One of these, a girl with a completely fibroid left

lung with a huge cavity, at the end of three months was afebrile, cough and spit had disappeared, and her general condition was excellent. Thoracoplasty was refused. The other, in which there was extensive active disease of the right lung, showed no dramatic change: she improved slowly but steadily throughout the ensuing months, and the late result was excellent.

Matson declares that the number of patients who benefit sufficiently after phrenic evulsion to do without thoracoplasty alone justifies its use as a routine preliminary. Our experience is not altogether in keeping with this. Certainly most of the cases in this series were very extensively diseased, but it is just on this ground that Matson's view can be disputed. There is a definite type of case in which the tuberculosis is mainly unilateral and where the lung is completely involved in dense disease. It is too much to hope that a paralysis of the diaphragm will produce any marked effect, and it is just in this type of case—if the disease is not too active and the patient's general condition will allow it—that a complete thoracoplasty without preliminary phrenic evulsion may be advocated.

Two other cases, in which phrenic evulsion was done primarily to relieve pain, benefited considerably, and thoracoplasty was ultimately done with an excellent result. Phrenic evulsion undoubtedly plays one of its most useful rôles in preparing a patient for the major operation of thoracoplasty. The added pulmonary rest and relaxation frequently result in a slow but progressive improvement, but it is impossible to forecast the result in any one case if there is any suspicion of activity. The result in one case may exceed anything that was hoped for, and in another the progressive nature of the illness may be quite unaltered.

In only one instance was the operation used to assist in the closure of an empyema cavity: in this case the empyema followed a spontaneous pneumothorax and was secondarily infected. Phrenic evulsion only aggravated the condition, the weight of the pus being sufficient to push the flaccid diaphragm down toward the abdomen. This was seen on one other occasion. Cupping of the diaphragm downward will occur whenever the weight of the fluid in the pleural cavity is sufficient to overcome the positive intra-abdominal pressure. This does not necessarily mean that paralysing the diaphragm cannot aid thoracoplasty in the closure of a tuber-

culous empyema. Aspiration of the pus can be continued after thoracoplasty if necessary.

Only once was the operation used with the sole indication of testing the stability of the opposite lung, in which there was much fine, apparently healed, miliary disease. No change whatever occurred. Phrenic evulsion as a method of testing whether suspicious lesions were active or not, was originally advocated by Sauerbruch, and the indication appears to have passed into the literature. It was pointed out, when discussing vital capacity, that compensation was required only for the normal lung tissue collapsed, and that this took place without any increase in respiratory labour by improved circulation and more efficient utilisation of oxygen. No added burden is placed on the opposite lung. In no case in this series was there any increase in respiratory activity or any dyspnœa in a patient following phrenic evulsion that could not be wholly attributed to the state of the lung disease. It is a commonplace that lesions in the contralateral lung may heal side by side with those in the lung in which collapse, either by artificial pneumothorax or induced paralysis of the diaphragm, is being carried out. It is equally common to see a focus of disease in the healthier lung suddenly light up in a patient who is being treated by rest in bed alone, and should one, in such an instance, be sufficiently unfortunate to have done a phrenic evulsion on the initially diseased side just before this took place, one would be apt to attribute the spread to the operation. The majority of cases in this series had a greater or lesser amount of disease in the contralateral lung, yet in no case was there any fresh activity that could be attributed to the diaphragmatic paralysis. Two cases, in each of which there was an apparently quiescent lesion in the opposite lung at the time of evulsion of the nerve, later developed signs of activity on this side. In neither could it be put down to the operation, as in the first the fresh activity occurred four months later and the patient had been well and leading an active life in the interval, and in the second case it occurred after three months' interval. Had the object in either case been to test the stability of the lesion in the opposite lung, no activity occurring until after a prolonged interval, both would have been considered quiescent.

Alexander[12] suggested that, in using phrenic evulsion as a test operation, any appearance of fresh activity was due to

an excess of toxins (over-tuberculinisation) being pressed out of the more diseased lung by the raised diaphragm. This is not likely to occur. The paralysed diaphragm merely takes up the position of expiration. There is no actual compression of the lung, and the added pulmonary rest would tend to prevent rapid dissemination of toxins, not to cause an excess to enter the circulation. Phrenic evulsion as a test operation for the stability of the opposite lung is probably useless. The behaviour of the contralateral lung after paralysis of the diaphragm is no indication of how it will behave after thoracoplasty.

The use of diaphragmatic paralysis to prevent an aspiration infection of the lower lobe when collapsing a tuberculous or secondarily infected cavity of the upper lobe, is of doubtful value. Lemon[13] showed that unilateral paralysis of the diaphragm in dogs did not prevent iodized oil, introduced into the trachea under ether anæsthesia, being aspirated into both lungs; and he added that "one cannot hope that in such diseases as tuberculosis and bronchiectasis the lungs will be spared the risk of aspiration."

II. **Phrenic Evulsion in Conjunction with Artificial Pneumothorax** (9 *cases*). — When treatment by artificial pneumothorax is completed and the lung is being allowed to expand, a phrenic evulsion should be done. This is probably the most frequent and one of the best indications for the operation. A lung collapsed by artificial pneumothorax over a long period is shrunken and fibrotic and cannot re-expand to fill the hemithorax completely, and there is danger that, in the attempt to do so, incompletely healed foci may be reactivated. Paralysis of the diaphragm helps to adjust the size of the hemithorax to that of the shrunken lung and tends to prevent old, walled-off lesions being torn open.

A very similar condition is seen when progressive pleural symphysis with expansion of the lung tends to take place in the presence of a chronic effusion. Where there is a chronic effusion, which is usually purulent, the pleura is thick and the lung more or less fibroid; the progressive expansion by symphysis results in great contraction of the chest wall, and to paralyse the diaphragm not only reduces the size of the hemithorax but allows further contraction in a lung in which this is tending to take place, and gives the maximum of permanent collapse. Such cases would probably be preferably

treated by thoracoplasty; but if there is any contra-indication to this, considerable benefit may be derived from the minor operation. This was done in four cases. In one case the expansion was very slow, and a year later the artificial pneumothorax was still being kept up with a fair collapse. In the other three, complete obliteration of the artificial pneumothorax space took place; but with the marked contraction of the chest on that side that followed, and the diaphragmatic paralysis, a fair collapse was maintained and the patients remained well.

Phrenic evulsion is also of definite value in aiding collapse in a lung in which this is being hindered by adhesions between the lung and chest wall. The reduction of the inspiratory negative pressure and the abolition of the direct inspiratory tug of the diaphragm on the root of the lung, will increase the rest and collapse of the lung and therefore give a certain amount of benefit, irrespective of the site of the adhesions. It has little direct effect on lateral adhesions, but apical adhesions are slightly relaxed. Its chief value is in cases where collapse is being hindered by adhesions from the base of the lung to the diaphragm. In one case which had multiple adhesions, although collapse was slightly improved, the operation actually appeared to hasten the onset of pleural symphysis. While maintaining that the chief beneficial factor in phrenic evulsion is cessation of movement, the result in cases of artificial pneumothorax with basal adhesions is influenced by the extent to which the diaphragm rises, and this is dependent on the intrapleural pressure. Where the pneumothorax is being maintained at a negative pressure, a good rise can be anticipated; but if the pressure is positive, the beneficial effects are largely annulled by the diaphragm being pushed down and hindering relaxation of the adhesion. In one instance, a pressure of +1, +2 was sufficient largely to undo the benefit derived from the diaphragmatic paralysis.

The statement, first made by Sauerbruch and Zadec, that fewer effusions occur in artificial pneumothorax after paralysing the diaphragm, and that where effusions are present the rate of formation of fluid is slowed up, is frequently encountered. Effusions in artificial pneumothorax are roughly of two types. They may be small, symptomless, and transitory, or they may be large and persistent. The former are due to pleural irritation and tend to disappear spontaneously and may never be seen unless by routine screen examination; the larger effusions,

although occasionally they remain clear, more often become purulent and show little tendency to absorb. These are due to an actual tuberculous involvement of the pleura, and there does not appear to be any reason why a paralysis of the diaphragm should check these effusions. It may possibly check the rate of formation of the fluid by increasing pulmonary rest, but in none of our cases was there any appreciable difference. It must be remembered that, provided the fluid is removed as seldom as possible, the rate of re-accumulation gradually decreases and it is difficult to judge if any change is produced by paralysing the diaphragm. In two instances, in both of which the nerve was evulsed on account of multiple adhesions interfering with collapse, an effusion followed after an interval, with aggravation of symptoms and expansion of the lung.

Many authorities report a satisfactory lengthening of the interval between refills following the operation. This series is not suitable for investigating the question, as the majority of the cases were complicated by an effusion: refills in these cases were small and unaffected. In one case, pleural symphysis was hastened and refills became small and difficult. Of the remaining cases, uncomplicated by an effusion at the time of evulsion of the nerve, in only one was there a satisfactory lengthening of the interval between refills. The others took as big and as frequent refills after the operation as before, without any increase in pressure. Conclusions cannot be drawn from a small number of cases. While it is reasonable to suppose the increased rest will retard the rate of absorption of air and that this, along with, in cases maintained at a negative pressure, the reduction in size of the hemithorax, may allow of spacing of refills, the advantage gained is not sufficient to warrant this alone as a suitable indication for evulsion of the phrenic nerve. It may be necessary later to do an artificial pneumothorax on the opposite side, and while a paralysed diaphragm on the initially diseased side does not absolutely contra-indicate this, it is a disadvantage.

Alexander and Zadec (quoted by Campbell)[14] advised that every artificial pneumothorax should be preceded by phrenic-ectomy on the grounds that more complete rest of the lung was obtained and that it checked effusions and lessened the frequency of refills. The last two points have already been discussed; it does not check effusions and is of doubtful efficacy in reducing the frequency of refills. As regards the third advantage, it

would be better to await the result of the pneumothorax before deciding whether more complete rest was necessary to control the disease and, if so, whether this could be obtained by paralysing the diaphragm. Again an artificial pneumothorax may be necessary for the other lung. No advantage is gained by preceding a pneumothorax by a phrenic evulsion, and it is not a justifiable procedure.

III. **Phrenic Evulsion as a Sole Operative Procedure** (29 *cases*).—The use of phrenic evulsion as a sole operative procedure is as a rule restricted to cases in which an artificial pneumothorax is either contra-indicated or unrealisable on account of pleural adhesions, but cases do occur in which the results are so good that it would almost appear preferable. Controversy has chiefly centred round the question of whether apical lesions derived the same benefit as basal from induced paralysis of the diaphragm ; and while cases might be grouped and discussed according to the type of lesion present, it is probably better to group them according to site. This method will be followed here, together with a final group where the chief indication for operation was the relief of symptoms, and inevitably a few cases in this group will have been included in one of the others.

Lower-lobe Lesions (6 *cases*).—Three of these had advanced bilateral tuberculosis and were very ill, but in each, active disease of a lower lobe was responsible for symptoms and it was hoped to control this by paralysing the diaphragm. One derived no benefit at all; the other two improved temporarily but the progressive nature of the illness was unchecked. These three cases, done early in the series, would not now be considered suitable for phrenic evulsion ; they were too advanced and too active to hope for any real benefit. One other case had fibro-caseous disease limited to the right lower lobe; the lung above and the left lung were healthy. Diaphragmatic paralysis failed to control the disease and did not prevent a big cavity forming; a spread to the lung above and to the left lung eventually took place.

By contrast, the remaining two cases did extremely well. In one, disease was largely fibrotic but a big cavity was present in the right lower lobe; in the other, fibrotic change was in evidence but there was a huge, thin-walled cavity with a fluid level in the right lower lobe. The cavity in the first was greatly reduced in size; and in the second, complete collapse of the

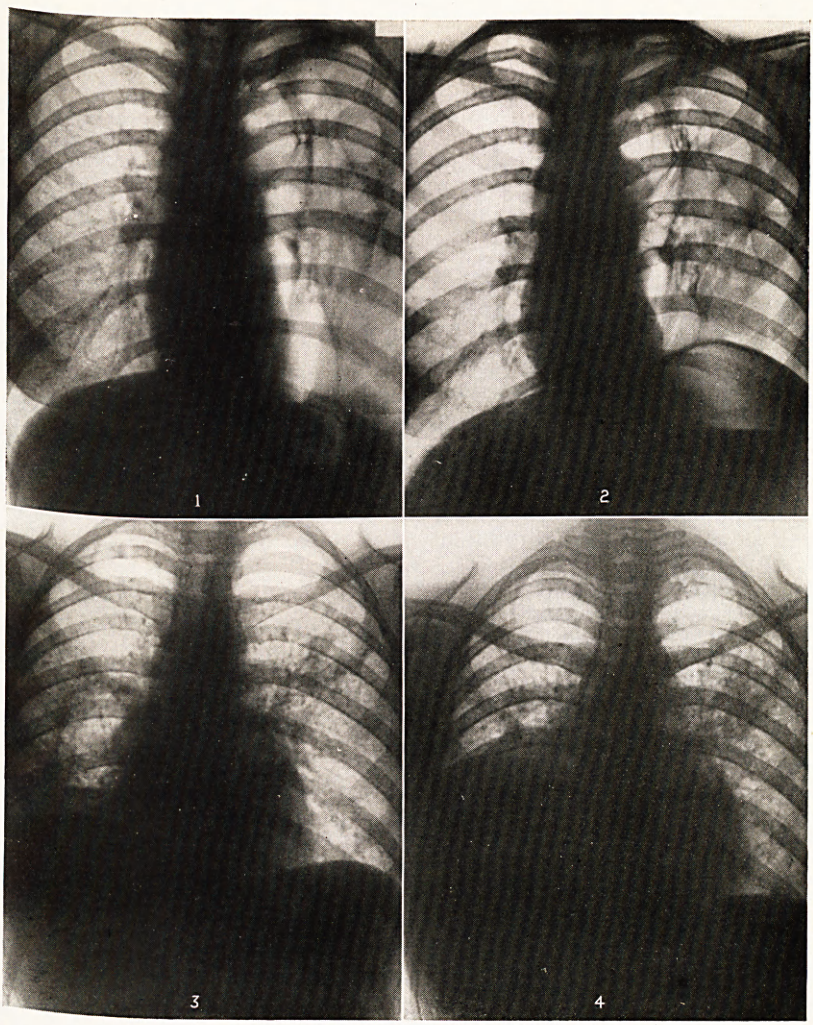

FIG. 1. M. F., 24.10.31.—Irregular left artificial pneumothorax with many adhesions and one big broad adhesion from the base to diaphragm. Phrenic evulsion, 26.10.31.

FIG. 2. M. F., 3.11.31.—Collapse of lung much improved: great shortening of the basal adhesion: diaphragm raised to 9th interspace.

FIG. 3. M. C., 24.2.32.—Extensive infiltration of right lower lobe, with a huge cavity with a fluid level. Light infiltration of left lung. Right diaphragm raised. Phrenic evulsion, 9.3.32.

FIG. 4. M. C., 13.4.32.—Big rise of diaphragm, with complete collapse of the basal disease and obliteration of the cavity.

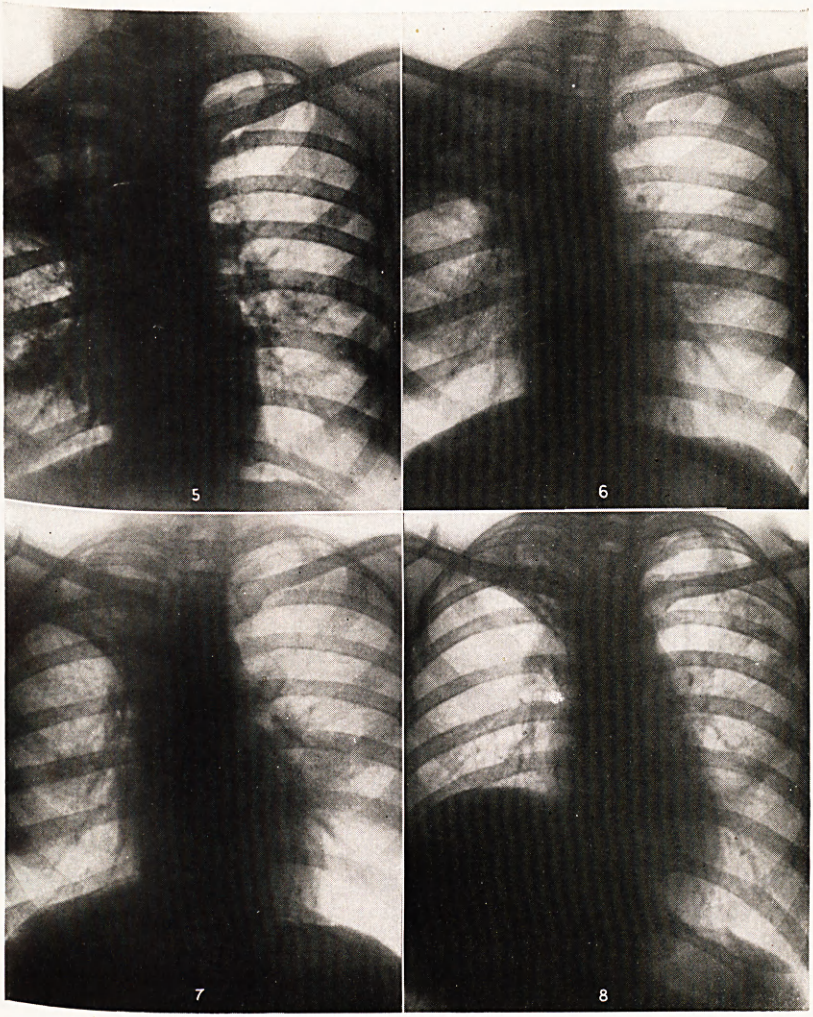

FIG. 5. A. B., 31.12.30.—Dense disease of right upper lobe with thickened interlobar septum. Light disease of lung below and perihilar shadowing on left.

FIG. 6. A. B., 5.3.31.—The upper lobe is contracting and contains several cavities. Lung below clearer.

FIG. 7. A. B., 16.6.31.—Right upper lobe further contracted and fibroid. Cavities contracting. Trachea and heart pulled to right. Phrenic evulsion, 18.6.31.

FIG. 8. A. B., 20.4.32.—Diaphragm high: marked further contraction of right upper lobe. Cavities still visible. Heart in better position.

basal disease and closure of the cavity resulted. While the results in two cases, where fibrotic change was established, exceeded expectations, the operation in the others, where the lesions were active and exudative in character, failed to influence the course of the disease.

Upper-lobe Lesions (11 *cases*).—In the majority of these cases, more than the upper lobe was involved in tuberculous infection, and in most there was some involvement of the contralateral lung; but in each the part it was hoped to influence was situated in the upper lobe. Four of these were very similar. In each there was fairly dense disease of the right upper lobe with cavities, which tended to become increasingly fibrotic, with contraction of the upper lobe and decrease in the size of the cavities. As fibrotic change advanced, the interlobar fissure became well defined and slightly concave downward. In all cases paralysis of the diaphragm was followed by progressive shrinkage of the upper lobe which became small and fibroid; the cavities were greatly reduced in size but never quite disappeared. The results were uniformly good. That in two cases, after the disease was apparently quiescent, active lesions should spring up in the opposite lung, does not negative the value of the operation in these cases, as in both, apparently inactive lesions were present in the contralateral lung at the time of evulsion of the nerve, and a long time elapsed before lighting up of the disease in a fresh area.

In four cases, big upper-lobe cavities were present. Marked reduction in size followed in one and moderate reduction in another; while in the remaining two, in each of which a very big thick-walled cavity lay in the upper lobe, very little change took place. The operation in the latter two cases was primarily for relief of symptoms.

Upper-lobe involvement of a lighter fibrotic nature was present in two others: one had a group of small cavities at the right apex and the other had one large and several small cavities in the middle of the left upper lobe. Paralysis was followed by marked reduction in the size of the cavities in both instances. In all cases so far cited, fibrotic change was either established or in evidence.

The last case of this sub-group indicates the opposite result. There was diffuse infiltration of the upper half of the left lung, which radiographically appeared of good definition and with fibrotic change apparently taking place. Signs of an extension

of the disease in this lung led to an attempt at inducing an artificial pneumothorax; this was unsuccessful and the phrenic nerve was evulsed. The result, however, was disappointing, and beyond a slight temporary improvement, the operation had no effect in controlling the disease and the patient got progressively worse.

Of the eleven cases, the indication for operation was fulfilled in eight, partly in two, and not at all in one.

More Extensive Bilateral Fibrotic or Fibroid Disease (6 *cases*). —Three of these cases were in many ways alike. All were admitted with extensive, bilateral, active tuberculosis, which, after a prolonged period of rest in bed, steadily improved. Radiographically the lesions became of better definition and fibrotic change was in progress, shown by displacement of the trachea to the more extensively involved side and pulling up of the diaphragm. Phrenic evulsion was done to allow of maximum contraction in a lung where the process was already started. No marked immediate change occurred in any: improvement was slow but steady, and the late result in every case excellent.

The remaining three cases were of densely fibroid disease. In one, considerable reduction in the size of cavities at the apex and base followed, but the others derived no special benefit. In this type of case, with very dense lung, shrunken chest, and thickened pleura, it is doubtful if it is worth while evulsing the phrenic nerve. The dense pleura prohibits any immediate further rise of the diaphragm: the diaphragm, being as a rule already pulled up and fixed to pleura, has practically no movement, and paralysing it produces every little change of note.

It has been shown that the diaphragm affects the whole lung to a certain extent and is directly responsible for aeration of the posterior part of the apex of the upper lobe. Again paralysis is followed by over-action of the external intercostal muscles and thus by increased freedom of movement of the lower ribs on the affected side. Taking both these factors into consideration, one might justifiably expect a better result in the treatment of apical than of basal disease, as the upper part of the lung lacks the compensation of increased costal respiration. Increased freedom of costal movement, although present in the majority of cases—apart from those in which marked shrinkage and fixation of the chest has taken place—is, however, seldom sufficient to be of any great consequence.

While admitting that, following diaphragmatic paralysis, pulmonary rest is probably greatest in the upper areas of the lung, it would appear that the type of lesion is much more important than the site. Wherever a lesion is tending to fibrose, the contraction naturally tending to take place around it is hindered by thoracic and diaphragmatic movements. As soon as diaphragmatic movement is abolished, retraction can take place. Cessation of movement is the important factor and not the rise: paralysis is followed by a general relaxation of the lung and selective collapse of the diseased areas. If the disease is of the massive exudative type, it derives some benefit from the added rest but it does not tend to contract.

In assessing the relative value of the operation for apical and basal lesions, it must be remembered that although four out of the six cases of basal disease died, all had advanced active tuberculosis: in three the outlook was hopeless. The remaining two did extremely well, one of them being the best result in the series. A much bigger percentage of the cases of upper-lobe tuberculosis did well, but in only one was the disease of any activity. The result appears to depend not on the location of the lesion but almost solely on its ability for spontaneous contraction. With one exception, active lesions—whether apical or basal—did badly.

The results in apical cavitation, while good, were not so good as claimed by certain of the French workers—Wolf,[15] Tapie[16] and Bérard.[17] The first of those got complete closure of cavities in five of eighteen cases within one year. In no case in this series was there complete closure of upper-lobe cavities, and big thick-walled cavities were practically unaffected.

The question of how far adhesions interfere with the efficacy of phrenic evulsion is one on which there is great difference of opinion. Alexander, and Yates and Raine think phrenic evulsion useless for upper-lobe lesions if there are adhesions over the middle or lower lobes. Head,[18] basing his opinion on the views of Hoover, states that, in cases where the diaphragm is adherent to the lateral chest wall, phrenic evulsion may actually do harm by increasing the movement of the lower ribs and allowing increased lung expansion. According to him, in such instances the diaphragm is already raised to the position of expiration and more or less fixed, and any movement it does have is in a medianward direction which decreases lung volume. To paralyse it is to free the lower ribs without

compensating by any rise, and he quotes two cases where the vital capacity was actually increased after sectioning the phrenic nerve. It is doubtful if Head's observation is of much value. Increased movement of the lower ribs after paralysis of the diaphragm is seldom sufficient to be of any importance and is not likely to be so if adhesions, of such a nature as to prevent any further rise of the diaphragm, exist. As has already been pointed out, that the diaphragm is already raised and relatively fixed does not necessarily mean that it cannot rise higher. Should great pleural thickening be present, however, little change can be expected. Adhesions over the lower lobe do not necessarily interfere with the effect of diaphragmatic paralysis on the upper lobe. The abolition of the inspiratory tug and the general relaxation are appreciated in the upper lobe whether the lower is adherent or not. In several cases of upper-lobe disease, an artificial pneumothorax had been attempted and several punctures had been made, not only over the upper but over the lower lobe, and no free space found, showing that the lower was adherent. Yet in every case phrenic evulsion was followed by a good rise, with, in the majority of cases, a very good result. Similarly, an adherent and thickened interlobar septum does not prevent paralysis of the diaphragm exercising a beneficial effect on the upper lobe. When this occurs, as was seen in several cases, the retraction of the upper lobe results in a deformity of the septum: it becomes pulled up in the centre, forming an arc, concave downward. Following phrenic evulsion, further contraction of the upper lobe does take place, the deformity of the septum increasing, and a good result can be obtained in spite of this pleural symphysis.

In cases of unilateral tuberculosis, the instances in which phrenic evulsion is preferable to artificial pneumothorax are limited. In cases of the type shown in Figs. 7 and 8, where there is dense disease of the upper lobe becoming fibroid and shown by progressive contraction of the lobe, as much benefit is likely to be derived from phrenic evulsion as artificial pneumothorax. If an artificial pneumothorax were induced, the upper lobe would almost certainly be adherent and efficient collapse impossible, and phrenic evulsion is probably preferable. In cases where an active lesion has cleared up and left some small cavities, a phrenic evulsion may be all that is required to procure closure of the cavities. Where there is any suspicion

of activity, the results of diaphragmatic paralysis are too uncertain to warrant its use instead of artificial pneumothorax. It is then to be used only when artificial pneumothorax has failed or is contra-indicated, as it is almost impossible to say in any one case what the result will be. Bezançon's description (quoted by Bard[19]) that "phrenic evulsion has as its unique end, the object of allowing pulmonary lesions to follow the retraction already commenced," just about limits the scope of the operation as a primary choice.

Effect of Phrenic Evulsion on Symptoms.—A careful note was kept of the effect of the operation on cough, ease of expectoration, amount of sputum, and temperature, in every case. It was found that there was expectation of improving cough and expectoration in about 65 per cent. of those in whom it was troublesome. Easier expectoration is usually appreciated immediately in the majority of cases, and cough may be less even if there is a temporary increase in the amount of sputum. A period when the patient experiences little change then ensues. In a favourable case, as the weeks pass and the lung condition improves, temperature, if previously raised, falls, the amount of sputum decreases, and consequently cough and expectoration become less. Cases which did badly showed either no change or a rise in temperature, and an increase in the amount of sputum. The change in character of the sputum, by the decrease of the purulent element, is probably a better index of the progress of the case. In cases treated by phrenic evulsion alone the operation did not appear to have any effect on the presence or absence of tubercle bacilli in the sputum.

In twelve cases the primary indication for the operation was for relief of symptoms. The uses of phrenic evulsion in this connection are many, but probably the commonest is to relieve difficult expectoration and troublesome cough. The abolition of the normal diaphragmatic resistance allows the powerful expulsive efforts of the abdominal muscles to be transmitted directly to the lung and easier expectoration results. In eight of the cases this was the end in view. All had advanced, fairly chronic, fibro-caseous disease with cavities; in all, cough was severe and distressing; and in four instances the effort to empty the cavities in the morning almost invariably caused vomiting. After evulsion of the phrenic nerve, cough was less and expectoration easier in every case and vomiting ceased. The amount of ease derived from the operation in cases in which

vomiting is associated with a harassing cough, justifies it even in a patient in whom there is no hope of arresting the disease.

In two cases the operation was for relief of phrenic pain: pain ceased in both, and thoracoplasty was done later with excellent results.

The remaining two cases had paralysis of the diaphragm induced in an attempt to control hæmorrhage. One patient, who was extremely ill, had active disease of the whole of the left lung, with a huge upper-lobe cavity. Phrenic evulsion was done only after an attempt at inducing an artificial pneumothorax had failed, but it had no effect in controlling the bleeding. In the other patient, disease was more chronic, with a big cavity occupying practically the whole of the right upper lobe. She had been bringing up small quantities of blood for two days when the phrenic nerve was evulsed: bleeding stopped more or less at once and considerable reduction in the size of the cavity followed. Many workers have reported success in controlling hæmoptysis by this method: it is not possible to offer any opinion where only two cases have been done, but where artificial pneumothorax has failed and hæmorrhage is not ceasing, it is certainly a reasonable procedure.

End-Results.—Of the 51 cases, when last heard of in October 1932, 23 were alive and well, 12 others were alive but in those the outlook was still doubtful, and 16 were dead. If the series is viewed from the point of view as to whether or not the indication for operation was fulfilled, it is found that the indication was fulfilled in 36, doubtfully fulfilled in 4, and not at all in 11. Where no definite indication for operation existed, no change took place.

Conclusion.—Phrenic evulsion, whether used as a sole operative procedure or in conjunction with other methods of pulmonary collapse, has a limited, but still definite and valuable, place in the treatment of pulmonary tuberculosis.

REFERENCES.

[1] Keith, Sir Arthur, "Man's Posture: Its Evolution and Disorders," *Brit. Med. Journ.*, 31st March 1923.

Keith, Sir Arthur, "Contribution to the Mechanism of Respiration," *Journ. of Anat. and Physiol.*, 1903, vol. xxxvii.

Keith, Sir Arthur, "Mechanism of Respiration," *Further Advances in Physiology*, 1909.

Keith, Sir Arthur, *Engines of the Human Body*, 1925.

[2] Briscoe, Sir Charlton, "Mechanism of Post-Operative Massive Collapse of the Lungs," *Quart. Journ. Med.*, 1919-20, vol. xiii.
[3] Dally, J. F. Halls, "Diaphragm in Man," *St Bart. Hosp. Rep.*, 1908, vol. xliv.
[4] Hoover, C. F., "The Functions of the Diaphragm and their Diagnostic Significance," *Arch. Intern. Med.*, 1913, vol. xii.
[5] Davies, H. Morriston, "An Endeavour to assess the Value of Hemidiaphragmatic Paralysis by Evulsion of the Phrenic Nerve in the Treatment of Pulmonary Tuberculosis and Bronchiectasis," *Tubercle*, 1928, vol. ix., No. 5.
[6] Moore, J. A., "Phrenicectomy in the Treatment of Pulmonary Disease," *Arch. of Surg.*, 1930, vol. xx.
[7] Matson, R. W., "Exairesis of the Phrenic Nerve in the Treatment of Pulmonary Tuberculosis," *Amer. Rev. Tuberc.*, 1930, vol. xxii., No. 1.
[8] Yates, J. L., and Forrester Raine, "Induced Paralysis of the Diaphragm," *Arch. of Surg.*, 1930, vol. xxi.
[9] Aycock, T. B., and Habliston, C. C., "Radical Phrenicotomy," *Amer. Rev. Tuberc.*, 1930, vol. xxii., No. 6.
[10] Wilson, H., "Unilateral Paralysis of the Diaphragm by Evulsion of the Phrenic Nerve," *Med. Journ. of Australia*, 11th October 1930.
[11] O'Brien, E. J., "Mechanics of Collapse Therapy and its Indications," *Arch. of Surg.*, 1930, vol. xxi.
[12] Alexander, J., "Total Paralysis of the Hemidiaphragm for Early Pulmonary Tuberculosis," *Amer. Rev. Tuberc.*, September 1924.
[13] Lemon, W. S., "The Functions of the Diaphragm and their Diagnostic Significance," *Arch. of Surg.*, 1928, vol. xvii.
[14] Campbell, A. J., "Diaphragmatic Paralysis as a Therapeutic Measure in Intrathoracic Disease," *Quart. Journ. of Med.*, 1928, p. 84.
[15] Wolf, J. E., "La phrenicectomie dans le traitement des cavernes tuberculeuses à localisation apicale," *Ann. de Méd.*, 1928, vol. xxiv., No. 3.
[16] Tapie, Jean, "Action de la phrenicotomie sur les lésions tuberculeuses du lobe supérieur," *Bull. et Mém. des Hôp. de Paris*, 1927.
[17] Bérard et Guilleminet, *Bull. Acad. de Méd.*, 25th June 1929.
[18] Head, J. R., "Diaphragmatic Adhesions," *Arch. of Surg.*, 1928, vol. xvii.
[19] Bard, M., *Bull. et Mém. Soc. Méd. des Hôp. de Paris*, 1927.