Neurol Med Chir (Tokyo) 50, 538～544, 2010

Effects and Complications of Stereotactic Aspiration for Spontaneous Intracerebral Hemorrhage

Daisuke UMEBAYASHI, Ayako MANDAI, Yasuhiko OSAKA, Yoshikazu NAKAHARA, and Hiroshi TENJIN

Department of Neurosurgery, Kyoto Second Red Cross Hospital, Kyoto

Abstract

Stereotactic aspiration of intracerebral hemorrhage (ICH) improves the general condition of patients, promotes improvement of consciousness, and decreases the incidence of pneumonia, but may induce rebleeding. The present study investigated the effects of stereotactic aspiration and factors that inhibit rebleeding in 70 consecutive patients who underwent stereotactic aspiration for ICH. Consciousness was significantly improved after surgery. Of patients who underwent surgery on day 0 or 1, 5 patients developed pneumonia and 29 patients did not. Of patients who underwent surgery on day 2 or later, 14 patients developed pneumonia and 22 patients did not. Early surgery within 2 days significantly reduced the rate of aspiration pneumonia. Patients with rebleeding tended to have liver dysfunction and hemorrhagic tendency. Early stereotactic aspiration of ICH facilitates better patient management than conservative treatment in patients with moderate consciousness disturbance. Patients with liver dysfunction and hemorrhagic tendency should be identified.

Key words: stereotactic aspiration, intracerebral hemorrhage, aspiration pneumonia, liver dysfunction, hemorrhagic tendency

Introduction

Spontaneous intracerebral hematoma (ICH) remains a serious neurosurgical condition requiring highly intensive care, but the clinical effectiveness of surgery remains unclear.[9,12] One randomized trial (International Surgical Trial in Intracerebral Haemorrhage: STICH) found no favorable outcome with early surgery (503 patients) compared with initial conservative treatment (530 patients).[12] However, 140 patients (26%) of the initial conservative treatment group underwent later surgery due to neurological deterioration in 82 patients and clinical deterioration in 20 patients. Therefore, the clinical usefulness of surgery for ICH remains uncertain. In Japan, hematoma evacuation improved both mortality and morbidity compared with conservative treatment.[8] Mortality was significantly better in the surgical group than in the conservative group and morbidity was better in the surgical group (78%) than in the conservative group (69%) in patients who were stuporous or semicomatose without herniation.[9]

Hematoma evacuation will improve the neurological and general condition, but surgery may cause brain damage. Minimally invasive hematoma evacuation, such as stereotactic aspiration,[11] would be preferable to avoid iatrogenic brain damage. The clinical use of stereotactic aspiration for ICH remains controversial.[3,6,12,13] Hematoma evacuation reduces morbidity, shortens hospitalization, promotes the return to activities of daily life, and reduces medical costs.[5] Furthermore, the mortality rate at one month is lower after surgical treatment than after conservative treatment in patients with ICH.[13] We think that reducing the volume of ICH can contribute to improvement of the general condition in selected patients. Aspiration pneumonia is a frequent complication of ICH, and causes severe problems in patient management, and we believe that stereotactic aspiration of ICH is helpful in the prevention of pneumonia. Complications must be avoided to improve outcomes. Rebleeding is one of the most severe complications of stereotactic aspiration. The most important factors for enlargement of ICH may be liver dysfunction and hemorrhagic tendency.[4,15] Patients with rebleeding after stereotactic aspiration of ICH tend to have liver dysfunction,[15] as highlighted by a few recent reports.[2,6]

The present study evaluated the effects and com-

Received July 27, 2009; Accepted December 11, 2009

plications of stereotactic aspiration for the treatment of ICH, particularly aspiration pneumonia and rebleeding.

Materials and Methods

This retrospective study included 70 consecutive patients (36 men and 34 women) aged 37 to 87 years (mean age, 68.1 ± 11.9 years) who underwent stereotactic aspiration for spontaneous ICH between January 2004 and December 2007 at our hospital. The site of bleeding was the putamen in 39 patients, thalamus in 21, lobular in 4, and multiple areas in 6 (putamen-thalamus in 5 and putamen-lobular in 1). Consciousness disturbance was evaluated using the Japan Coma Scale[16] (JCS) as follows, with the value in [ ] used for numerical analyses: 1-digit codes: the patient is awake without any stimuli, and is 1 [1] almost fully conscious, 2 [2] unable to recognize time, place, and person, and 3 [3] unable to recall name or date of birth; 2-digit codes: the patient can be aroused 10 [4] easily by being spoken to, 20 [5] by a loud voice or shaking of the shoulders, and 30 [6] only by repeated mechanical stimuli; and 3-digit codes: the patient cannot be aroused with any forceful mechanical stimuli, and 100 [7] responds with movements to avoid the stimulus, 200 [8] responds with slight movements including decerebrate and decorticate posture, and 300 [9] does not respond at all. The mean maximum diameter of the hematoma was 4.1 ± 1.0 cm. All patients were admitted on the day of onset. The median time from onset to surgery was 1.9 ± 1.3 days. Surgery was performed at least 12 hours after onset in all cases. Nine patients received antiplatelet therapy, and 1 patient received anticoagulation therapy.

Our indications for stereotactic aspiration were the presence of moderate or severe neurological dysfunction, i.e. JCS more than 10, or maximum diameter of the hematoma on computed tomography (CT) of more than 3.0 cm. Patients with severe ICH was excluded from this study. Emergency craniotomy was performed in patients with impending cerebral herniation, as indicated by abnormal pupil response (anisocoria, etc.), abnormal posture (decorticate posture), or CT findings of absence of ambient cistern or severe midline shift. Surgery was not indicated if the disturbance of consciousness was expected to be irreversible, in the absence of bilateral light reflexes and decerebrate posture. Hematomas that were difficult to aspirate using the stereotactic apparatus, that is lobular hemorrhage in temporal or occipital lobe, were also excluded from this study. Patients with aneurysm, arteriovenous malformation, cavernous angioma, and moyamoya disease were excluded from this study. Magnetic resonance (MR) imaging and MR angiography, and sometimes conventional angiography, were performed to identify these conditions.

The following factors were evaluated in all patients: rate of hematoma evacuation (hematoma volume calculated as length × width × height/2 as measured on CT before surgery and after drainage removal), JCS score before and after surgery, relationship between waiting time for surgery after onset and aspiration pneumonia, and relationships between rebleeding and liver dysfunction, hemorrhagic tendency, anticoagulant or antiplatelet therapy, and mean arterial blood pressure on admission.

The preoperative state of consciousness was investigated on the morning of the day of surgery and the postoperative state of consciousness on the day after drainage removal. Pneumonia was diagnosed by chest radiography and blood inflammatory reactions. The timing of chest radiography and blood tests was determined based on the results of physical examination. General blood tests were performed including alanine aminotransferase (ALT) and aspartate aminotransferase (AST), blood coagulation test using prothrombin time (PT) or activated partial thromboplastin time, fibrinogen, and platelet count. High ALT or AST level was defined as at least twice the normal value for either ALT or AST (ALT >70 units or AST >80 units). Prolonged PT-international normalized ratio (INR) was defined as 1.2 times or more, based on general standards. Platelet counts of $13.9 \times 10^4/mm^3$ and fibrinogen concentrations of 170 mg/dl were considered to be the lower limits of the normal ranges. Liver dysfunction and hemorrhagic tendency were identified based on high ALT or AST levels, prolonged PT-INR, low platelet counts, and low fibrinogen concentrations.

Informed consent was obtained from the patient or the patient's family for the procedures described in this study. Perioperative management used the following protocol. Not all patients had a history of hypertension, but all patients were hypertensive on admission and received antihypertensive therapy after admission. Immediately after admission, efforts were made to maintain systolic blood pressure between 100 and 140 mmHg using antihypertensive therapy.[7] All patients were given intravenous antibiotics during surgery and for 2 to 3 days after surgery. Respiratory management with endotracheal intubation or tracheostomy was performed as needed.

Patients were sedated (diazepam, pentazocine) or given local anesthesia. The stereotactic apparatus was placed on the patient's skull and CT was performed (Asteion 2-slice, Aqulion 16-slice, or Aqulion

Table 1 Summary of cases

	No. of cases	Mean age (yrs)	Sex (male/female)	Location (putamen/thalamus/subcortex/mixed)	Mean maximum diameter of hematoma (cm)	Median interval between onset and surgery (days)	No. of patients receiving anticoagulation or antiplatelet therapy
All cases	70	68.1 ± 11.9	36/34	39/20/4/6	4.2 ± 1.0	1.9 ± 1.3	10
Pneumonia	19	72.4 ± 9.0	13/6	11/7/1/0	4.5 ± 0.9	2.4 ± 1.2	4
Rebleeding	5	67.2 ± 15.7	4/1	3/2/0/0	4.7 ± 0.9	1.6 ± 0.9	1

64-slice: Toshiba Medial Systems Corp., Otawara, Tochigi) before the patient was sent to the operating room. The target point for the stereotactic coordinate system was measured with CT software. All patients underwent surgical intervention, including the creation of a burr hole. Hematoma was aspirated through a silicone tube inserted to the target point, and then the remaining hematoma was drained through the tube with the aid of urokinase administration, usually using 10000 IU of urokinase (Mitsubishi Pharma Corporation, Osaka) in 3 ml of normal saline injected twice through the drainage tube every 2 hours and drained after 1 hour. The drainage tube was usually left in place for 1 day after the surgery to drain the hematoma until CT showed that the size of the residual hematoma had decreased sufficiently. The interval between onset and surgery was determined by the individual circumstances, but was at least 12 hours after onset.[3,13]

Statistical analyses were performed as follows. Differences in consecutive variables between groups were assessed by the Wilcoxon signed rank test, i.e., change in consciousness level after surgery. Differences in the distribution of numbers between groups were assessed by Fisher's exact test, for the relationship between pneumonia and the interval between onset and surgery, and the relationship between the incidence of rebleeding and liver dysfunction or hemorrhagic tendency. Differences in measured values between groups were assessed with the Mann-Whitney U test, for comparison of the interval between onset and surgery in patients with and without pneumonia.

Results

Patient characteristics are shown in Table 1. After surgery, 19 patients developed pneumonia, and 5 patients developed rebleeding. Stereotactic aspiration resulted in a mean rate of hematoma evacuation including drainage after surgery of 80.1 ± 15.0%.

JCS before and after surgery are shown in Table 2 and postoperative changes in JCS score are shown in Table 3. The JCS score fell by 3 points in 3 patients and by 2 points in one patient. No change occurred in 30 patients. The JCS score improved by 1 point in 22 patients, by 2 points in 8 patients, by 3 points in 3 patients, and by 4 points in 3 patients. The state of consciousness improved significantly after the surgery (Wilcoxon signed rank test, $p < 0.01$). Eleven

Table 2 State of consciousness before and after surgery by the Japan Coma Scale

	Preoperative state	Postoperative state
1-Digit code		
alert [0]	0	3
1 [1]	8	9
2 [2]	3	3
3 [3]	4	10
2-Digit code		
10 [4]	19	19
20 [5]	15	11
30 [6]	7	9
3-Digit code		
100 [7]	11	4
200 [8]	3	2
300 [9]	0	0
Total	70	70

Values in [ ] are used for analyses.

Table 3 Improvement of consciousness after surgery

	Improvement of JCS score rank							
	−3	−2	−1	0	1	2	3	4
No. of patients*	3	1	0	30	22	8	3	3
No. of patients with pneumonia	0	0	0	8	8	3	0	0

Improvement of the Japan Coma Scale (JCS) score rank indicates the change in JCS score after surgery compared with that before surgery. "Plus" indicates improvement of the JCS score, and "minus" indicates worsening of the JCS score. For example, a patient whose condition was JCS 100 [7] before surgery and JCS 20 [5] after surgery was defined as showing +2 improvement of JCS score rank. *Wilcoxon signed rank test, $p < 0.01$.

Table 4 Summary of rebleeding cases

Case No.	Age (yrs)/ Sex	Platelet ($\times 10^4$/mm^3)	Fibrinogen (mg/dl)	PT-INR	ALT (IU/l)	AST (IU/l)	Anticoagulation or antiplatelet therapy	Blood pressure on admission (mmHg)
1	78/M	16.1	285	1.00	63	96 (high)	aspirin 81 mg	194/105
2	55/M	30.8	164 (low)	0.99	31	106 (high)		207/147
3	81/F	19.0	318	1.13	37	19		141/75
4	76/M	10.5 (low)	132 (low)	1.45 (high)	13	5		161/107
5	46/M	7.6 (low)	145 (low)	1.49 (high)	71	31		184/104
Normal values		13.9–36.3	170–350		10–35	5–40		

ALT: alanine aminotransferase, AST: aspartate aminotransferase, PT-INR: prothrombin time-international normalized ratio.

Table 5 Characteristics of patients with rebleeding

	Patients with rebleeding	Patients without rebleeding	p Value (Fisher's exact test)
Total number	5	65	
A: high ALT or AST	2/5	3/65	<0.01
B: platelet counts of $<13.9\times10^4$/mm^3	2/5	6/65	
C: prolonged PT-INR of >1.2	2/5	6/65	
D: fibrinogen concentrations of <170 mg/dl	3/5	0/65	<0.01
A or B or C or D	4/5	11/65	<0.01

High alanine aminotransferase (ALT) or aspartate aminotransferase (AST) was defined as ALT or AST levels at least twice the normal value, and prolonged prothrombin time-international normalized ratio (PT-INR) was defined 1.2 times or more the normal value. Platelet count of 13.9×10^4/mm^3 and a fibrinogen concentrations of 170 mg/dl were the lower limits of the normal range. Low platelet count and low fibrinogen level were defined as the lower limits of the normal range. Patients with liver dysfunction or hemorrhagic tendency developed rebleeding significantly more frequently than patients without those complications.

patients with pneumonia showed improved consciousness.

Prevention of pneumonia is shown. Among the patients undergoing surgery on day 0 or 1, 5 patients developed pneumonia and 29 patients did not. Among the patients undergoing surgery on day 2 or later, 14 patients developed pneumonia and 22 patients did not. The incidence of pneumonia in patients who underwent surgery on day 2 or later was significantly higher than that in patients who underwent surgery on day 0 or 1 (Fisher's exact test, $p < 0.05$). A longer interval between onset and surgery significantly increased the incidence of pneumonia. (Mann Whitney U test, $p < 0.05$).

Rebleeding occurred in 5 of 70 patients, 4 men and 1 woman, who underwent stereotactic aspiration (Table 4). Two patients with rebleeding after stereotactic surgery showed high ALT or AST level. Two patients with rebleeding after stereotactic aspiration had low platelet concentrations, low fibrinogen, and high PT-INR. The incidence of rebleeding in patients with high ALT or AST, low platelet concentrations, low fibrinogen, or high PT-INR was significantly higher than that in patients with normal liver function or no hemorrhagic tendency (Fisher's exact test, $p < 0.01$) (Table 5). One patient with rebleeding had received antiplatelet therapy. That is, one of nine patients, who showed high AST level, developed rebleeding among the patients who had been medicated with antiplatelet agent. Mean arterial blood pressure on admission of all patients was 133 ± 26 mmHg, but that of patients with rebleeding was 130 ± 25 mmHg.

Representative Case

A 58-year-old male suddenly developed consciousness disturbance. On admission, neurological examination determined JCS was 10 and identified left hemiparesis. Laboratory data did not show liver dysfunction or hemorrhagic tendency. CT showed right putaminal hemorrhage measuring 4×5 cm. Stereotactic aspiration was performed one day after admission (Fig. 1A, B). His consciousness improved to JCS 1. CT showed that the hematoma size had decreased (Fig. 1C). No pneumonia or complication

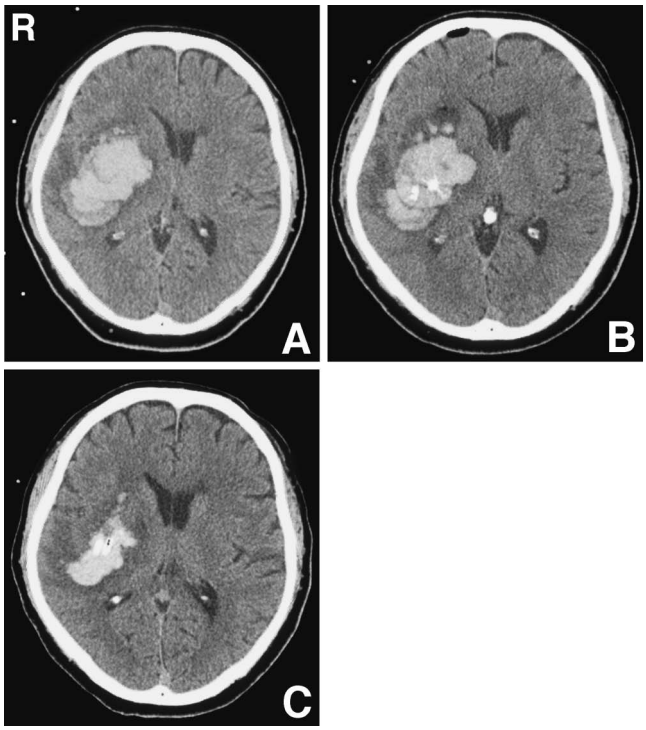

Fig. 1 Computed tomography scans showing (A) right putaminal hemorrhage of 4 × 5 cm before stereotactic aspiration, (B) reduced size of the hematoma immediately after stereotactic aspiration, with the two catheter tips, and (C) decreased size of the hematoma after administration of urokinase.

occurred. He was discharged from hospital with left hemiparesis 17 days after stereotactic aspiration.

Discussion

The present study showed improvement of consciousness and decreased incidence of pneumonia following early stereotactic aspiration for ICH. The present findings also indicate that risk factors for rebleeding are high AST or ALT levels, and low fibrinogen levels. These findings are important to clarify the indications for stereotactic aspiration in patients with ICH.

The state of consciousness improved after surgery. Consciousness disturbance is a clear indicator for aspiration. Prolonged interval between onset and surgery was characteristic of the pneumonia group. This study showed that longer interval between onset and surgery was significantly associated with higher rate of pneumonia. Initially, we thought that an improvement in consciousness simply reduced the incidence of aspiration pneumonia. However, pneumonia developed in 11 patients showing consciousness improvement and in 8 patients without consciousness improvement, indicating no direct relationship between consciousness improvement and reduction of aspiration pneumonia. We suppose that pneumonia had already developed in some patients before consciousness was improved by surgery. Surgery may also improve other aspects, such as improvement of general condition, intracranial pressure, and sympathetic hypertonia associated with Cushing response.[1] Improvement of those factors by early surgery may prevent aspiration pneumonia. A study of mortality following stroke found that 43 patients died of transtentorial herniation and 3 patients of aspiration pneumonia among 180 patients with supratentorial hemorrhage.[17] Reduction in the incidence of pneumonia following early stereotactic aspiration may improve overall mortality. However, surgery may also induce aspiration pneumonia. Sedation and the restricted position of placement during surgery may contribute to the development of pneumonia. We suggest the use of endotracheal intubation during surgery for patients with severe consciousness disturbance, which will reduce the risk of pneumonia due to surgery.

Stereotactic aspiration tends to lower the medical costs for patient care compared with conservative therapy.[5] The STICH study also showed that the mean total cost for early surgery was lower than that for initial conservative treatment during the first 6 months, although this difference was not significant.[12]

Rebleeding is one of the most severe complications, occurring in 5% of patients who underwent stereotactic aspiration.[12,13] The rebleeding rate associated with aspiration without thrombolytic agents ranges from 0% to 16% with a mean of 5% among 896 cases. However, the rebleeding rate associated with aspiration with thrombolytic agents ranges from 0% to 10% with a mean of 4% among 392 cases.[10,12] Rebleeding of ICH with conservative therapy ranges from about 6% to 14.3%.[4,14] In our series of 70 consecutive patients who underwent stereotactic aspiration, rebleeding occurred in 5 patients (7.1%), which is comparable. Performing stereotactic aspiration too early might increase the rebleeding rate, as most rebleeding occurs within 6 hours after onset.[3,13] Our waiting time of 12 hours until surgery agreed with this recommendation. The incidence of rebleeding in patients with liver dysfunction is approximately three times greater than that in patients with normal liver function.[2,4,6,15] Fibrinogen is a product of the liver, and liver dysfunction also affects the platelet count and prolonged PT or activated partial thromboplastin time. These factors can be indicators of liver function and hemorrhagic tendency. Therefore, patients with liver dysfunction or

hemorrhagic tendency must be distinguished from patients with ICH but without those conditions, since the cause of bleeding differs from that of hypertensive ICH. No relationship was found between blood pressure on admission and rebleeding if blood pressure was controlled adequately after admission. In the present study, no other complications and comorbidities occurred. Infection occurred only on the surface of the skin, and no meningitis or brain abscess, and no seizures were encountered.

Stereotactic aspiration significantly improved consciousness in patients with ICH, and significantly reduced pneumonia in patients who received stereotactic aspiration on day 0 or 1 compared to after day 2. Patients with liver dysfunction or hemorrhagic tendency had a significantly higher rate of rebleeding after surgery. Patients with liver dysfunction or hemorrhagic tendency must be identified. Early stereotactic aspiration of ICH with attention to liver dysfunction or hemorrhagic tendency is an effective and safe treatment for patients with ICH. Early stereotactic aspiration of ICH will provide better management than conservative treatment for patients with ICH and moderate consciousness disturbance.

References

1) Atkinson JLD, Wilberger JE: Multiple organ system injuries resulting from and critical care of isolated sever central nervous system trauma, *in* Layon AJ, Gabrielli A, Friedman WA (*eds*): *Textbook of Neurointensive Care*. Philadelphia, Saunders, 2004, pp 215–233
2) Broderick JP, Adams HP Jr, Barsan W, Feinberg W, Feldmann E, Grotta J, Kase C, Krieger D, Mayberg M, Tilley B, Zabramski JM, Zuccarello M: Guidelines for the management of spontaneous intracerebral hemorrhage: A statement for healthcare professionals from a special writing group of the Stroke Council, American Heart Association. *Stroke* 30: 905–915, 1999
3) Cho DY, Chen CC, Chang CS, Lee WY, Tso M: Endoscopic surgery for spontaneous basal ganglia hemorrhage: comparing endoscopic surgery, stereotactic aspiration, and craniotomy in noncomatose patients. *Surg Neurol* 65: 547–556, 2006
4) Fujii Y, Tanaka R, Takeuchi S, Koike T, Minakawa T, Sasaki O: Hematoma enlargement in spontaneous intracerebral hemorrhage. *J Neurosurg* 80: 51–57, 1994
5) Hattori N, Katayama Y, Maya Y, Gatherer A: Impact of stereotactic hematoma evacuation on medical costs during the chronic period in patients with spontaneous putaminal hemorrhage: a randomized study. *Surg Neurol* 65: 522–524, 2006
6) Hokama M, Tanizaki Y, Mastuo K, Hongo K, Kobayashi S: Indications and limitation for CT-guided stereotaxic surgery of hypertensive intracerebral haemorrhage, based on the analysis of postoperative complications and poor ability of daily living in 158 cases. *Acta Neurochir (Wien)* 125: 27–33, 1993
7) Itabashi R, Toyoda K, Yasaka M, Kueashiro T, Nakagomi H, Miyashita F, Okada Y, Naritomi H, Minematsu K: The impact of hyperacute blood pressure lowering on the early clinical outcome following intracerebral hemorrhage. *J Hypertens* 26: 2016–2021, 2008
8) Ito Z: [Hypertensive intracerebral hemorrhage—It's diagnosis and operative indication]. *No To Shinkei* 28: 227–244, 1976 (Japanese)
9) Kanaya H, Kuroda K: Development in neurosurgical approaches to hypertensive intracerebral hemorrhage in Japan, *in* Kaufman HH (*ed*): *Intracerebral Hematomas*. New York, Raven Press, 1992, pp 197–209
10) Little KM, Alexander MJ: Medical versus surgical therapy for spontaneous intracranial hemorrhage. *Neurosurg Clin N Am* 13: 339–347, 2002
11) Matsumoto K, Honda H: CT-guided stereotactic evacuation of hypertensive intracerebral hematomas. *J Neurosurg* 61: 440–448, 1984
12) Mendelow AD, Gregson BA, Fernandes HM, Murray GD, Teasdale GM, Hope DT, Karimi A, Shaw MD, Barer DH: Early surgery versus initial conservative treatment in patients with spontaneous supratentorial intracerebral haematomas in the International Surgical Trial in Intracerebral Haemorrhage (S.T.I.C.H.): a randomized trial. *Lancet* 365: 387–397, 2005
13) Morgenstern LB, Frankowski RF, Shedden P, Pasteur W, Grotta JC: Surgical treatment for intracerebral hemorrhage (STICH): a single-center, randomized clinical trial. *Neurology* 51: 1359–1363, 1998
14) Niizuma H, Shimizu Y, Yonemitsu T, Nakazato N, Suzuki J: Results of stereotactic aspiration in 175 cases of putaminal hemorrhage. *Neurosurgery* 24: 814–819, 1989
15) Niizuma H, Suzuki J, Yonemitsu T, Otuki T: Spontaneous intracerebral hemorrhage and liver dysfunction. *Stroke* 19: 852–856, 1988
16) Ohta T, Kikuchi H, Hashi K, Kudo Y: Nizofenone admission in the acute stage following subarachnoid hemorrhage. Results of a multi-center controlled double-blind clinical study. *J Neurosurg* 64: 420–426, 1986
17) Sliver EL, Norris JW, Lewis AJ, Hachinskki VC: Early mortality following stroke: A prospective review. *Stroke* 15: 492–496, 1984

Address reprint requests to: Hiroshi Tenjin, M.D., Department of Neurosurgery, Kyoto Second Red Cross Hospital, Kamanza-Marutamachi, Kamigyo-ku, Kyoto 602-8026, Japan.
e-mail: htenjin@nn.iij4u.or.jp

Commentary

This article written by Umebayashi et al. is a retrospective analysis that investigates the advantages of early intervention in spontaneous intracerebral hemorrhage. In 70 consecutive patients this treatment was performed within 12 hours of admission. The indication for surgery was based on clinical deterioration or, moderate or severe, neurological dysfunction. It is known that early hematoma evacuation can reduce morbidity, shorten hospitalization and may promote return to daily life activities. The authors have nicely demonstrated that early decompression also reduces the rate of aspiration pneumonia. Furthermore, patients who experienced rebleeding tended to have liver dysfunction. We agree with the authors' management and we have learned now that risk of pneumonia can also be reduced if early intervention is possible. What we miss in this article is the control group. It would be interesting to see the results in direct comparison to a patient group treated without any surgical intervention, with emphasis placed on pneumonia and rebleeding rates. In summary, this article is an important contribution to promoting early minimal invasive interventions in deep-seated intracerebral hemorrhages, and the authors should be congratulated for their good results.

Oliver Bozinov, *M.D.*
and Helmut Bertalanffy, *M.D.*
Department of Neurosurgery
University Hospital of Zurich
Zurich, Switzerland

Spontaneous intracerebral hemorrhage (ICH) is associated with high morbidity and mortality, and the results of conventional surgery have generally been disappointing in comparison with the medical management. Stereotactic clot aspiration is gaining credibility as a promising minimally invasive surgical technique. The authors retrospectively reviewed 70 consecutive patients who underwent stereotactic aspiration for spontaneous ICH. The mean rate of hematoma evacuation including drainage with administration of urokinase was 80.1 ± 15.0%. After the surgery, improvement of consciousness and decreased incidence of pneumonia reached significant difference. The present study also indicated that rebleeding was related with high AST or ALT levels, and low fibrinogen levels. The incidence of rebleeding in patients with liver dysfunction was approximately three times greater than that in patients with normal liver function.

There has been controversy regarding on the association between ICH volume and perihematomal edema. Some reports suggested that when thrombolytic agents were administered within the clot, lysis rate accelerates at the expense of increased risk of worsening edema. Therefore, it would be meaningful if authors provide the association between reduction in ICH volume and edema volume in this research.

Liang Chen, *M.D.*
and Liang-fu Zhou, *M.D.*
Department of Neurosurgery
HuaShan Hospital, S.M.C., F.D.U.
Shanghai, P.R.C.