

# Endovascular Treatment of Renal Artery Aneurysms

Current data demonstrate the safety of devices and prostheses used for treating RAAs.

BY SANJEEVA P. KALVA, MD; STEVEN WU, MD; AND ZUBIN IRANI, MD

**T** rue renal artery aneurysms (RAAs) are uncommon, and their actual prevalence is unknown. Initial autopsy studies revealed an incidence of one per 8,000 to one per 10,000;<sup>1,2</sup> however, further careful autopsy studies revealed a prevalence of 9.7%.<sup>3</sup> The angiographic prevalence of RAAs varies between 0.3% and 0.7% in the general population;<sup>4-6</sup> a higher prevalence of 2.5% and 9.2% was reported in subjects with hypertension and fibromuscular dysplasia, respectively.<sup>7,8</sup> The prevalence of false RAAs is unknown, but an increasing incidence has been reported with the advent of minimally invasive kidney procedures such as biopsy, nephrostomy, and percutaneous stone removal.

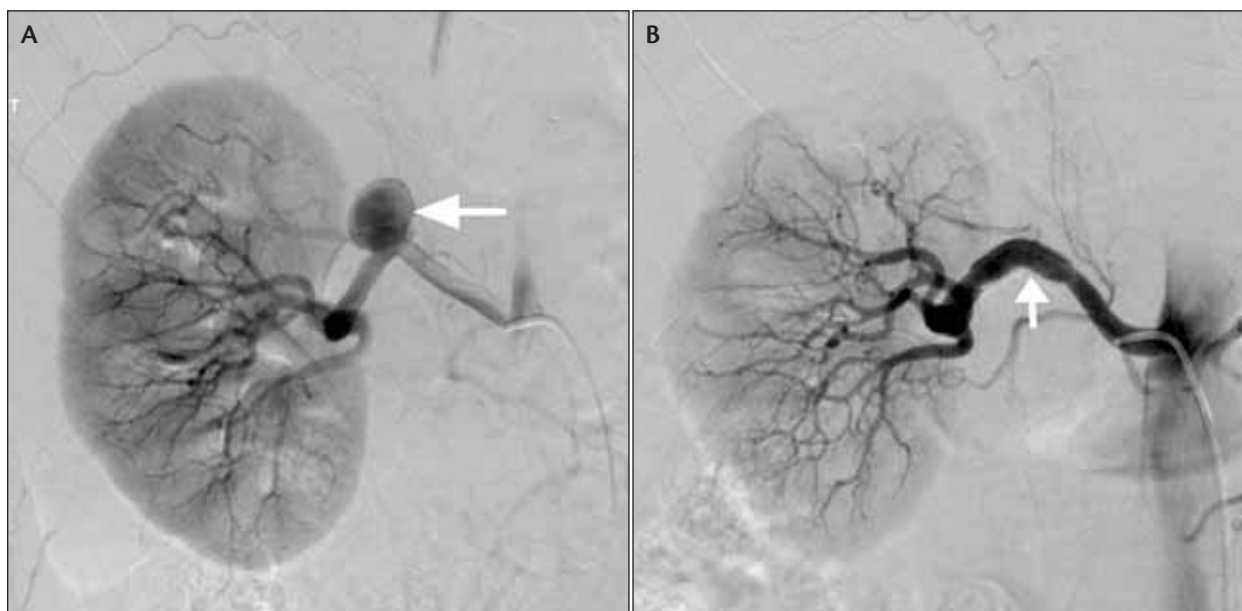The most common etiology of true RAAs is fibromuscular dysplasia and atherosclerosis. False aneurysms are usually secondary to iatrogenic and noniatrogenic trauma and infection. True aneurysms usually involve the main renal artery and its bifurcation, whereas traumatic and inflammatory aneurysms tend to involve the intrarenal parenchymal arteries. Based on the location and morphology, RAAs have been classified as saccular, fusiform, aneurysmal dissection, and intrarenal microaneurysms.<sup>9</sup> The size of the aneurysms vary from a few millimeters to 8 cm. Calcification of RAAs may be apparent on plain radiography in 27% to 50%.<sup>2,10,11</sup>

Symptoms occur in < 50% of patients and include high blood pressure, hematuria, abdominal pain from expansion of the aneurysm, decreasing renal function, and rarely, acute hemodynamic collapse secondary to rupture. The pathophysiology of hypertension in patients with RAAs is not well understood but may be related to localized ischemia secondary to kinking of

“The angiographic prevalence of RAAs varies between 0.3% and 0.7% in the general population . . .”

the renal artery branch, turbulence in the aneurysm, distal embolization from the aneurysm, or coexisting renal artery stenosis. Several studies reported improvement of hypertension after treatment of the aneurysm.<sup>12,13</sup> Progressive renal dysfunction may occur secondary to distal embolization of thrombus in the aneurysm. Rupture of the aneurysm is rare. The reported incidence of aneurysm rupture varies from 0% to 10%.<sup>12,14,15</sup> The incidence of rupture appears to be high in large aneurysms (> 2 cm) and in pregnant women. The mortality secondary to rupture is high during pregnancy, with a reported maternal mortality of 50% and a fetal mortality of 80%;<sup>16-19</sup> however, the mortality in nonpregnant patients is < 10%.<sup>12</sup>

The indications for treating RAAs include symptomatic aneurysms, large (> 2 cm) or enlarging aneurysms on serial angiography, aneurysms in patients anticipating pregnancy or in pregnant women, ruptured aneurysms, false aneurysms, and aneurysms associated with arteriovenous fistulas or dissection.<sup>13</sup> Small (< 2 cm) aneurysms in nonpregnant patients may be followed with serial imaging. Traditionally, RAAs are treated with surgery either through aneurysmorrhaphy, resection and bypass grafting, ex vivo repair, or nephrectomy. Currently, most



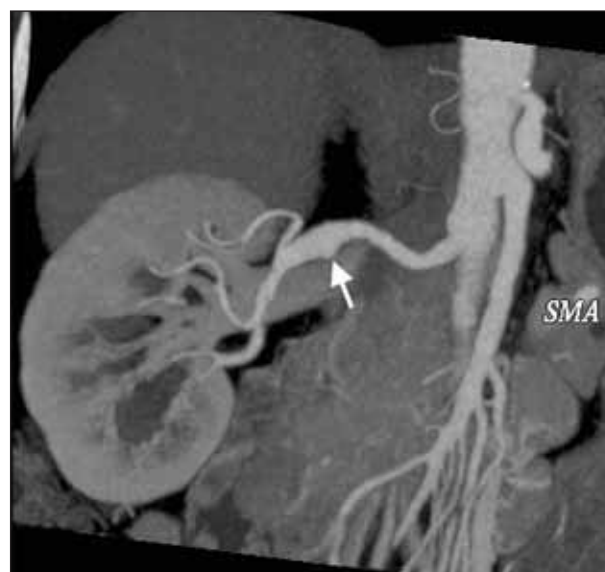**Figure 1.** A 54-year-old woman with an enlarging right main artery aneurysm that was treated with a stent graft. A right renal angiogram shows a large aneurysm (arrow) arising from the main renal artery. A small segmental branch arises from the aneurysm (A). The aneurysm was successfully excluded with a stent graft (iCast, Atrium Medical Corporation, Hudson, NH) (arrow) (B).

RAAs are treated via an endovascular approach due to its minimal invasiveness and reduced morbidity.

### ENDOVASCULAR THERAPY

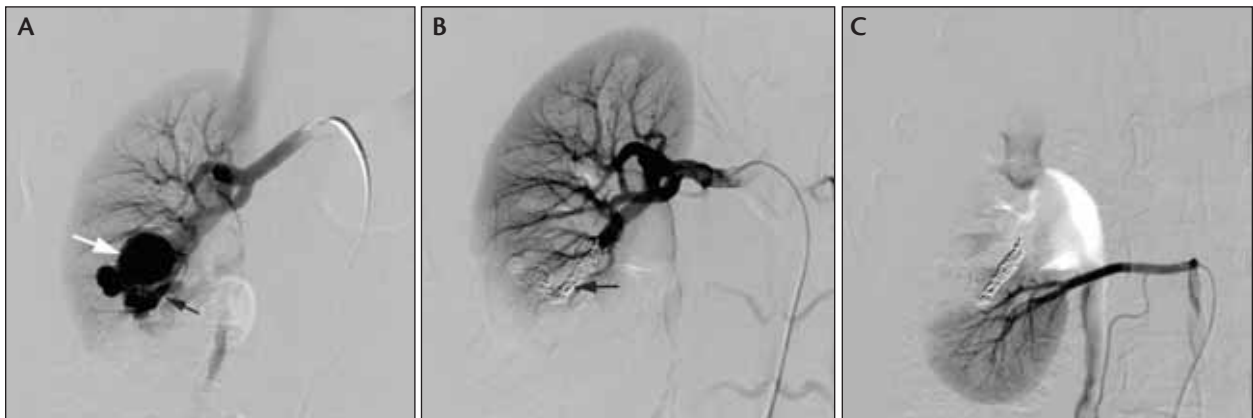
Various endovascular therapeutic options exist for treatment of RAAs. These options fall into two categories—embolization with metallic or liquid embolic materials and exclusion through stent grafts. Based on the treatment options for RAA, Rundback et al proposed an angiographic classification system.<sup>13</sup> Type I RAAs are saccular and arise from either the main renal artery trunk or proximally from a large segmental artery. These can be successfully treated with stent grafts or stent/balloon-assisted coil embolization (Figure 1). Type II RAAs are fusiform, occur at the main renal artery or proximal segmental arteries, and are best treated surgically (Figure 2). Type III RAAs refer to intraparenchymal aneurysms affecting the small segmental or accessory arteries. These are best treated with coil embolization with minimal loss of parenchyma (Figure 3). Successful embolization of the aneurysm while preserving the distal perfusion of the normal parenchyma is preferable to prevent kidney dysfunction.

Because the renal arteries are end arteries, it is unlikely that the intraparenchymal aneurysms would reperfuse with embolization of the feeding arteries. This often results in infarction of distal renal parenchyma supplied by the feeding artery. Embolization of intraparenchymal

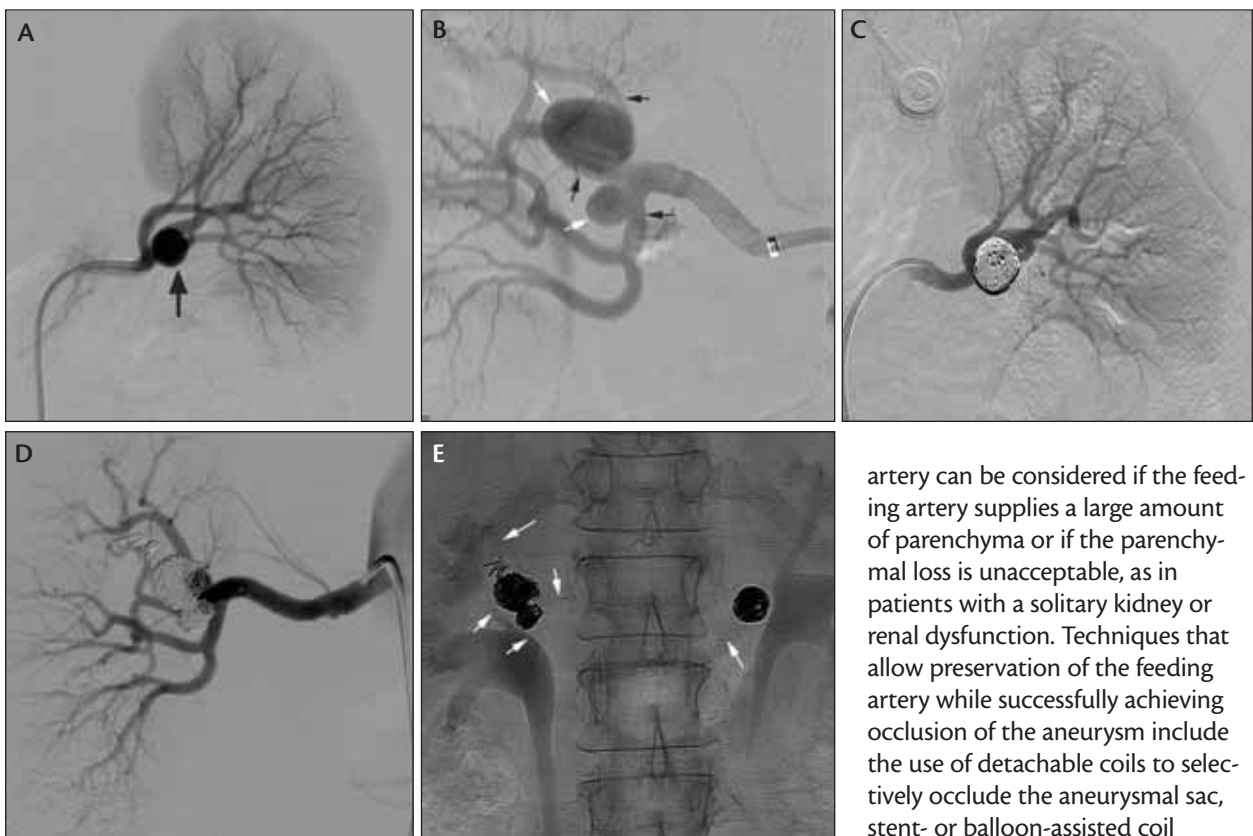


**Figure 2.** Oblique subvolume maximum-intensity projection of computed tomographic angiography data showing a fusiform aneurysm (arrow) of the right renal artery in a 55-year-old woman.

aneurysms can be achieved with regular nondetachable coils, detachable coils (Figure 3),<sup>20</sup> N-butyl cyanoacrylate, ethylene vinyl copolymer (Onyx, ev3 Inc., Plymouth, MN),<sup>21</sup> or gelfoam. Selective embolization of the intraparenchymal aneurysm without occlusion of the feeding



**Figure 3.** Embolization of an intraparenchymal RAA associated with an arteriovenous fistula in 27-year-old woman. A renal angiogram shows an arteriovenous fistula (black arrow) and an aneurysm (white arrow) affecting an intraparenchymal artery (A). Successful embolization was achieved with detachable coils (Azur, Terumo Interventional Systems, Somerset, NJ) and minimal loss of parenchyma (B). The lower pole is supplied by an accessory renal artery (C).



**Figure 4.** Stent-assisted coil embolization of bilateral hilar RAAs in a 38-year-old woman. Left renal angiogram shows a large aneurysm (arrow) from the first-order branch of the main renal artery (A). Right renal angiogram shows two aneurysms (white arrows) at the trifurcation point of the right main artery, and there are three first-order branches (black arrows) off the main renal artery (B). The aneurysms were treated with stent-assisted coil embolization (C and D). The arrows outline the bare stents in the first-order branches extending into the main renal artery on either side; three stents were used on the right and one on the left (E).

artery can be considered if the feeding artery supplies a large amount of parenchyma or if the parenchymal loss is unacceptable, as in patients with a solitary kidney or renal dysfunction. Techniques that allow preservation of the feeding artery while successfully achieving occlusion of the aneurysmal sac, stent- or balloon-assisted coil embolization of the aneurysm,<sup>22</sup> and stent graft placement across the neck of the aneurysm.<sup>23</sup> Exclusion of intraparenchymal aneurysms with stent grafts is often technically challenging due to the small size and tortuosity of the intraparenchymal arteries and rigid

“If the neck of the aneurysm is narrow, selective embolization of the aneurysmal sac can be safely achieved with detachable coils.”

stent structure. However, a few case reports indicated successful use of stent grafts for these aneurysms.<sup>23</sup>

Treatment of the proximal segmental and main renal arteries is best achieved with stent grafts (Figure 1), which allow successful exclusion of the aneurysm while preserving flow through the arteries.<sup>13</sup> If the neck of the aneurysm is narrow, selective embolization of the aneurysmal sac can be safely achieved with detachable coils.<sup>20</sup> Wide-necked aneurysms are treated either with stent grafts or stent-assisted coiling of the aneurysm.<sup>24</sup> Three-dimensional computed tomography and three-dimensional angiography are very helpful in assessing the neck and size of the aneurysm.<sup>24</sup> However, when the aneurysms involve the bifurcation points of the main or segmental renal arteries, the use of stent grafts may result in occlusion of some of the branches. Small segmental branches can be sacrificed, but if the branch vessels supply a significant portion of the renal parenchyma, alternate techniques may be employed. One of the approaches is selective stenting of the branch vessels with bare-metal stents while embolizing the aneurysm with coils through a microcatheter that is positioned within the aneurysmal sac through the interstices of the stent (Figure 4).<sup>25</sup> Another approach is the use of multiple stent grafts across the aneurysm neck into the branch vessels. Often, surgical therapy may be required if the aneurysm is complex and involves multiple branch vessels.

## CONCLUSION

Data on the long-term efficacy of endovascular therapy for RAAs are lacking, but current data support the high safety of the devices and prosthesis used for treatment. Short-term data demonstrate successful exclusion of the aneurysm and improvement of hypertension and renal dysfunction.<sup>26</sup> Further technological advances in stent graft technology may allow successful use of these devices for intrarenal aneurysms. ■

*Sanjeeva P. Kalva, MD, is with the Division of Vascular Imaging & Intervention, Department of Imaging at Massachusetts General Hospital, and the Department of Radiology, Harvard Medical School, in Boston, Massachusetts. He has disclosed that he holds no financial interest in any product or manufacturer mentioned herein.*

*Dr. Kalva may be reached at (617) 726-8315; skalva@partners.org.*

*Steven Wu, MD, is with Division of Vascular Imaging & Intervention, Department of Imaging, and the Division of Interventional Nephrology, Department of Medicine, at Massachusetts General Hospital; and the Department of Medicine, Harvard Medical School in Boston, Massachusetts. He has disclosed that he holds no financial interest in any product or manufacturer mentioned herein.*

*Zubin Irani, MD, is with the Division of Vascular Imaging & Intervention, Department of Imaging at Massachusetts General Hospital, and the Department of Radiology, Harvard Medical School, in Boston, Massachusetts. He has disclosed that he holds no financial interest in any product or manufacturer mentioned herein.*

1. Begner JA. Aortography in renal aneurysm. *J Urol.* 1955;73:720-725.
2. Ippolito JJ, LeVein HH. Treatment of renal artery aneurysms. *J Urol.* 1960;83:1-10.
3. Schwartz CJ, White TA. Aneurysm of the renal artery. *J Pathol Bacteriol.* 1965;89:349-356.
4. Edsman G. Angiography and suprarenal angiography. A roentgenologic study of the normal kidney. Expansive renal and suprarenal lesions and renal aneurysms. *Acta Radiol.* 1957;155(suppl):104-116.
5. De Bakay ME, Lefrak EA, Garcia-Rinaldi R, Noon GP. Aneurysm of the renal artery. *Arch Surg.* 1973;106:438-443.
6. Hageman JH, Smith RF, Szilagyi DM, Elliott JP. Aneurysms of the renal artery; problems of prognosis and surgical management. *Surgery.* 1978;84:563-572.
7. Browne RFJ, Riordan EO, Roberts JA, et al. Renal artery aneurysms: diagnosis and surveillance with 3D contrast-enhanced magnetic resonance angiography. *Eur Radiol.* 2004;14:1807-1812.
8. Porcaro A, Migliorini F, Pianon R, et al. Intraparenchymal renal artery aneurysms. Case report with review and update of the literature. *Int Urol Nephrol.* 2004;36:409-416.
9. Ortenberg J, Novick AC, Straffon RA, Stewart BH. Surgical treatment of renal artery aneurysms. *Br J Urol.* 1983;55:341-346.
10. McLelland R. Renal artery aneurysms. *Am J Roentgenol Radium Ther Nucl Med.* 1957;78:256-265.
11. Barry WF Jr, Kim SK. Renal artery aneurysms. *Am J Roentgenol Radium Ther Nucl Med.* 1966;98:132-136.
12. Henke PK, Cardneau JD, Welling TH, et al. Renal artery aneurysms: a 35-year clinical experience with 252 aneurysms in 168 patients. *Ann Surg.* 2001;234:454-462.
13. Rundback JH, Rizvi A, Rozenblit GN, et al. Percutaneous stent-graft management of renal artery aneurysms. *J Vasc Interv Radiol.* 2000;11:1189-1193.
14. Tham G, Ekelund L, Herrlin K, et al. Renal artery aneurysms: natural history and prognosis. *Ann Surg.* 1983;197:348-352.
15. Panayiotopoulos YP, Assadpouroam R, Taylor PR. Aneurysms of the visceral and renal arteries. *Ann R Coll Surg Engl.* 1996;78:412-419.
16. Cohen JR, Shamash FS. Ruptured renal artery aneurysms during pregnancy. *J Vasc Surg.* 1987;6:51-59.
17. Riborek A, Van Dick HA, Roex AJM. Rupture of renal artery aneurysm during pregnancy. *Eur J Vasc Surg.* 1994;8:375-376.
18. Dayton B, Helgerson RB, Sollinger HW, Acher CW. Ruptured renal artery aneurysm in a pregnant uninephric patient: successful ex vivo repair and autotransplantation. *Surgery.* 1990;107:708-711.
19. Whiteley MS, Katoch R, Kennedy RH, et al. Ruptured renal artery aneurysm in the first trimester of pregnancy. *Eur J Vasc Surg.* 1994;8:238-239.
20. Klein GE, Szolar DH, Breinl E, et al. Endovascular treatment of renal artery aneurysms with conventional non-detachable microcoils and Guglielmi detachable coils. *Br J Urol.* 1997;79:852-860.
21. Rautio R, Haapanen A. Transcatheter embolization of a renal artery aneurysm using ethylene vinyl alcohol copolymer. *Cardiovasc Intervent Radiol.* 2007;30:300-303.
22. Rabellino M, Garcia-Nielsen L, Zander T, et al. Stent-assisted coil embolization of a mycotic renal artery aneurysm by use of a self expanding neurointerventional stent. *Cardiovasc Intervent Radiol.* 2010. In press.
23. Malacrida G, Dalainas I, Medda M, et al. Endovascular treatment of a renal artery branch aneurysm. *Cardiovasc Intervent Radiol.* 2007;30:118-120.
24. Clark TW, Sankin A, Becske T, et al. Stent-assisted Guglielmi detachable coil repair of wide-necked renal artery aneurysm using 3-D angiography. *Vasc Endovasc Surg.* 2007-2008;41:528-532.
25. Manninen HI, Berg M, Vanninen RL. Stent-assisted coil embolization of wide necked renal artery bifurcation aneurysms. *J Vasc Interv Radiol.* 2008;19:487-492.
26. Tshomba Y, Deleo G, Ferrari S, et al. Renal artery aneurysm: improved renal function after coil embolization. *J Endovasc Ther.* 2002;9:54-58.