**ISSN** 1948-5190 (online)

# World Journal of *Gastrointestinal Endoscopy*

*World J Gastrointest Endosc* 2018 January 16; 10(1): 1-55

Published by Baishideng Publishing Group Inc

WJGE World Journal of Gastrointestinal Endoscopy

Monthly Volume 10 Number 1 January 16, 2018

## Contents

## ABOUT COVER

Editorial Board Member of *World Journal of Gastrointestinal Endoscopy*, Marcela Kopacova, MD, PhD, Professor, 2nd Department of Internal Medicine - Gastroenterology, Charles University Teaching Hospital, Hradec Kralove 500 05, Czech Repoublic

## AIM AND SCOPE

*World Journal of Gastrointestinal Endoscopy* (*World J Gastrointest Endosc*, *WJGE*, online ISSN 1948-5190, DOI: 10.4253) is a peer-reviewed open access (OA) academic journal that aims to guide clinical practice and improve diagnostic and therapeutic skills of clinicians.

*WJGE* covers topics concerning gastroscopy, intestinal endoscopy, colonoscopy, capsule endoscopy, laparoscopy, interventional diagnosis and therapy, as well as advances in technology. Emphasis is placed on the clinical practice of treating gastrointestinal diseases with or under endoscopy.

We encourage authors to submit their manuscripts to *WJGE*. We will give priority to manuscripts that are supported by major national and international foundations and those that are of great clinical significance.

## INDEXING/ABSTRACTING

*World Journal of Gastrointestinal Endoscopy* is now indexed in Emerging Sources Citation Index (Web of Science), PubMed, and PubMed Central.



NAME OF JOURNAL
*World Journal of Gastrointestinal Endoscopy*

ISSN
ISSN 1948-5190 (online)

LAUNCH DATE
October 15, 2009

FREQUENCY
Monthly



EDITORIAL OFFICE
Xiu-Xia Song, Director
*World Journal of Gastrointestinal Endoscopy*
Baishideng Publishing Group Inc
7901 Stoneridge Drive, Suite 501, Pleasanton, CA 94588, USA
Telephone: +1-925-2238242
Fax: +1-925-2238243
E-mail: editorialoffice@wjgnet.com
Help Desk: http://www.f6publishing.com/helpdesk
http://www.wjgnet.com

PUBLISHER
Baishideng Publishing Group Inc
7901 Stoneridge Drive, Suite 501,
Pleasanton, CA 94588, USA
Telephone: +1-925-2238242
Fax: +1-925-2238243
E-mail: bpgoffice@wjgnet.com
Help Desk: http://www.f6publishing.com/helpdesk
http://www.wjgnet.com

PUBLICATION DATE
January 16, 2018



INSTRUCTIONS TO AUTHORS
http://www.wjgnet.com/bpg/gerinfo/204

ONLINE SUBMISSION
http://www.f6publishing.com

World Journal of Gastrointestinal Endoscopy

Submit a Manuscript: http://www.f6publishing.com

*World J Gastrointest Endosc* 2018 January 16; 10(1): 10-15

DOI: 10.4253/wjge.v10.i1.10

ISSN 1948-5190 (online)

MINIREVIEWS

# Imaging of gall bladder by endoscopic ultrasound

Malay Sharma, Piyush Somani, Tagore Sunkara

Malay Sharma, Piyush Somani, Department of Gastroenterology, Jaswant Rai Speciality Hospital, Meerut 25001, Uttar Pradesh, India

Tagore Sunkara, Department of Gastroenterology and Hepatology, the Brooklyn Hospital Center, Clinical Affliate of the Mount Sinai Hospital, Brooklyn, NY 11201, United States

ORCID number: Malay Sharma (0000-0003-2478-9117); Piyush Somani (0000-0002-5473-7265); Tagore Sunkara (0000-0001-9536-9027).

Author contributions: Sharma M and Somani P wrote the manuscript; Sunkara T and Somani P edited the manuscript; Sharma M designed the study.

Conflict-of-interest statement: Authors declare no conflict of interests for this article.



Manuscript source: Invited manuscript

Correspondence to: Malay Sharma, MD, DM, Department of Gastroenterology, Jaswant Rai Speciality Hospital, Saket, Meerut 25001, Uttar Pradesh, India. sharmamalay@hotmail.com
Telephone: +91-983-7031148
Fax: +91-121-2657154

Received: August 2, 2017
Peer-review started: August 4, 2017
First decision: September 25, 2017
Revised: November 13, 2017
Accepted: December 4, 2017
Article in press: December 5, 2017
Published online: January 16, 2018

## Abstract

Endoscopic ultrasonography (EUS) is considered a superior investigation when compared to conventional ultrasonography for imaging gall bladder (GB) lesions as it can provide high-resolution images of small lesions with higher ultrasound frequencies. Examination of GB is frequently the primary indication of EUS imaging. Imaging during EUS may not remain restricted to one station and multi-station imaging may provide useful information. This review describes the techniques of imaging of GB by linear EUS from three different stations. The basic difference of imaging between the three stations is that effective imaging from station 1 is done above the neck of GB, from station 2 at the level of the neck of GB and from station 3 below the level of the neck of GB.

**Key words:** Gallbladder; Gallbladder cancer; Gallstones; Biliary sludge; Antrum; Duodenal bulb; Endoscopic ultrasound



**Core tip:** Endoscopic ultrasonography (EUS) is superior investigation than ultrasonography for imaging gall bladder (GB). Different techniques of imaging of GB by EUS have been described by different authors but a standard technique has not been specifically described. We herein discuss the techniques of imaging of GB by linear EUS from three different stations.

Sharma M, Somani P, Sunkara T. Imaging of gall bladder by endoscopic ultrasound. *World J Gastrointest Endosc* 2018; 10(1): 10-15 Available from: URL: http://www.wjgnet.com/1948-5190/full/v10/i1/10.htm DOI: http://dx.doi.org/10.4253/wjge.v10.i1.10

**Table 1 Imaging of gall bladder from three stations**

| Station | Home base structure | Main position where gall bladder is seen | Part of biliary tract seen on clockwise rotation | Part of biliary tract seen on anti-clockwise rotation |
|---|---|---|---|---|
| Station - 1: OG junction | Joining of right branch of portal vein with left branch of portal vein | Beyond the curving part of portal vein between 6-8 o'clock position | Upper 1/3rd of CBD | Neck of Gall Bladder, Fundus |
| Station - 2: Antrum of stomach/ duodenal bulb | Portal vein, superior mesenteric vein | Between 2-4 o'clock position | Lower 1/3rd of CBD | Upper 1/3rd of CBD, neck of Gall Bladder and Fundus, left and right hepatic duct union |
| Station - 3: Descending duodenum | Superior mesenteric vein | Between 9-11 o'clock position | Pancreatic duct | Middle and upper 1/3rd of CBD, neck of gall bladder and fundus, left and right hepatic duct union |

CBD: Common bile duct.

## INTRODUCTION

Imaging modalities used in evaluating gall bladder (GB) diseases include transabdominal ultrasonography (USG), endoscopic ultrasonography (EUS), computerized tomography, and magnetic resonance imaging[1,2]. Although USG is considered the gold standard for GB imaging, in view of providing high resolution images; EUS has been found to be better than USG for GB lesions imaging[3-6]. Different techniques of imaging by EUS have been described by different authors for GB imaging but a standardized technique has not been mentioned[7-10]. In view of close proximity of GB to the duodenum, usually EUS imaging is restricted to duodenum[11]. Usually, endosonographers performs GB imaging from multiple stations and the initial station of imaging differs among different endosonographers[12,13]. The present review elaborates the various methods of GB imaging by linear EUS.

## APPLIED ANATOMY OF GB

The GB lies on the visceral surface of the liver. The non-peritoneal upper surface of the GB is attached by connective tissue to a shallow fossa on the liver located between the right lobe and the quadrate lobe. The GB has three segments: The fundus, the body, and the left segment which is the infundibulum or neck. The fundus projects beyond the inferior margin of the liver, is covered completely in peritoneum and is in contact with the anterior abdominal wall. The body tapers towards the neck, which lies in the porta hepatis. The neck or infundibulum is hook-shaped and may show a pouch like dilation toward the right (Hartmann's pouch). The neck turns sharply downward as it becomes continuous with the cystic duct. The mucous membrane of the cystic duct is raised up into a spiral fold that consists of five to ten irregular turns; it is continuous with a similar fold in the neck of the GB.

## TECHNIQUES OF IMAGING

The images included in this review were obtained utilizing the linear echoendoscope EG-3830 UT (Pentax, Tokyo, Japan), along with a Hitachi Avius processor (Hitachi, Tokyo, Japan). The EUS image orientation on screen was as follows: Monitor's right side corresponds to the cranial and left to the caudal end of the patient. Rotation of the echo endoscope is the most crucial aspect to GB imaging. Majority of the movements are performed in a straight position of the echo endoscope, except during EUS imaging from first part of duodenum when the scope is in a J-shaped position. Proper right/left knobs movements along with in/out movement of the echo endoscope are utilized for adequate contact with the gastrointestinal wall for proper EUS imaging.

## STATIONS OF IMAGING

EUS of the GB can be done from the fundus of stomach, duodenal bulb, descending duodenum and antrum. The imaging from duodenal bulb and antrum are almost similar in appearance hence the description is restricted to three stations (Figure 1 and Table 1): (1) the fundus of stomach; (2) duodenal bulb and antrum; and (3) descending duodenum.

### *Imaging from fundus of stomach/esophagogastric junction*

The GB lies on the far side of screen between 6 to 9 o'clock position. Movements near esophagogastric junction (40 cm) should be performed under direct vision to avoid the possibility of perforation. Initially, segment 2 and 3 portal vein tributaries are identified within the left lobe of liver. A clockwise rotation follows the tributaries which form the left branch of portal vein (PV). Further clockwise rotation traces the left branch of PV towards the liver hilum where it is joined by the right branch of PV. After the union the supraduodenal part of PV is seen as a curving vessel going from 9/11 o'clock position to 4/6 o'clock position (Figure 2). The common bile duct (CBD) and GB are seen in the area beyond the curving part of PV in the left lower quadrant of screen (Figure 3). Initially, the CBD and neck of GB are identified just beyond the PV (Figure 4). Imaging of remaining part of GB can be done by following GB down from the fundic part of stomach. This follow down of GB is possible due to EUS probe movement along

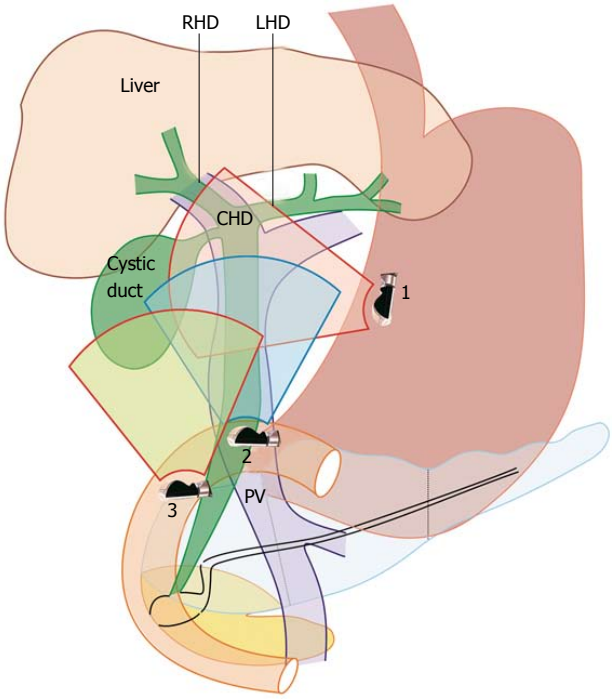


**Figure 1 Station 1 shows the gall bladder at around 6 o'clock position; station 2 shows the gall bladder at around 3 o'clock position; and station 3 shows the gall bladder at around 9 o'clock position.** RHD: Right hepatic duct; LHD: Left hepatic duct; CHD: Common hepatic duct; PV: Portal vein.

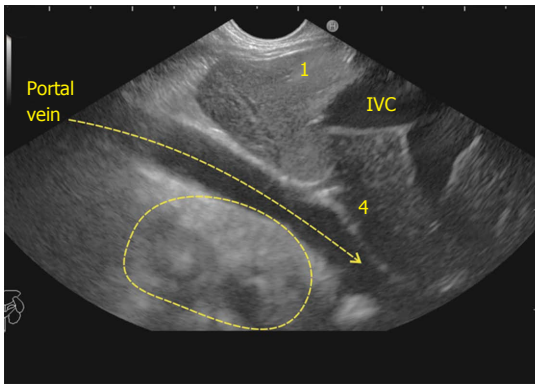


**Figure 2 The supraduodenal part of portal vein is seen as a curving vessel going from 5/6 o'clock position to 9/10 o'clock position.** The yellow arrow points to the curving part of portal vein. The area marked with yellow outline shows the area in which the CBD and Gall Bladder can be seen. 1: Segment 1; 4: Segment 4; IVC: Inferior vena cava; CBD: Common bile duct.

the lesser curvature along with combination of three smooth movements: (1) Pushing around 25 to 30 cm; (2) 90 degree clockwise rotation; and (3) up movement of up/down knob on echo endoscope for about 90 degree. This combination of movements allows smooth pathway of EUS transducer along the lesser curvature and follows down the GB from neck towards the fundus of GB.

### *Imaging from antrum and duodenal bulb*

The GB lies close to the probe between 2 to 4 o'clock position. The imaging from the antrum is sometimes

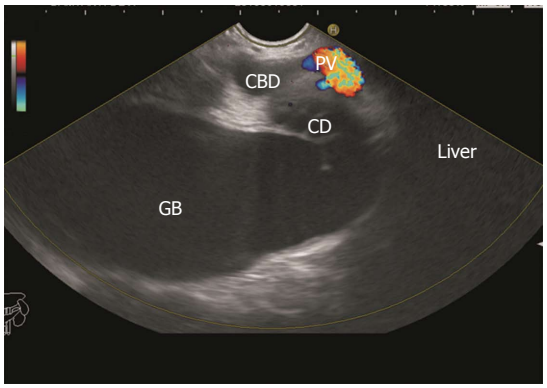


**Figure 3 The upper part of common bile duct is first identified beyond the curving part of portal vein.** With slight rotation of the scope the cystic duct and gall bladder can be traced in the area beyond the portal vein between 5 o'clock position to 10 o'clock position. CBD: Common bile duct; GB: Gall bladder.

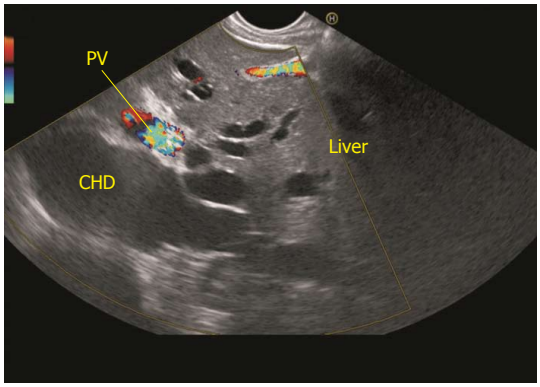


**Figure 4 The dilated ducts of segment 2 and 3 can be followed to formation of left hepatic duct.** The left hepatic duct joins the right hepatic duct to form common hepatic duct. The common hepatic duct (CHD) lies beyond the supraduodenal part of portal vein. PV: Portal vein.

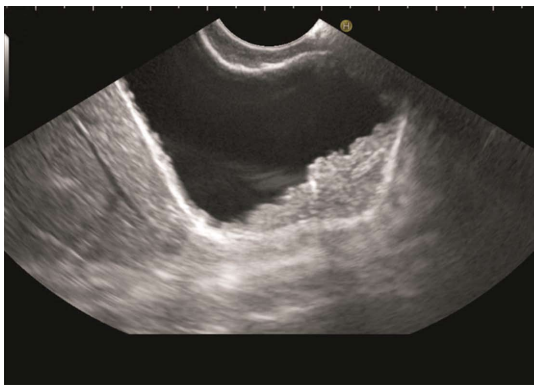

**Figure 5 The gall bladder imaging is done from duodenal bulb.** The layers of GB can be seen. The irregular polypoidal mass occupying the lumen is due to adenomyomatosis of GB. GB: Gall bladder.

best done by pushing the echo endoscope from the body of stomach towards the pylorus with a hyperinflated balloon (Figure 5). The imaging from duodenum can be done without a balloon by passing the scope beyond the pylorus and pushing it into the duodenal bulb apex. The contact with the superior and anterior duodenal

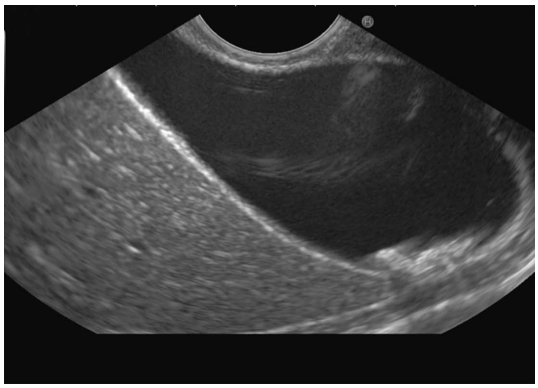

**Figure 6 Gall bladder imaging from the duodenal bulb.** The stones are present in the lumen of GB. The neck of the Gall Bladder is present at 11 o'clock position and the fundus is present at 3 o'clock position. GB: Gall bladder.

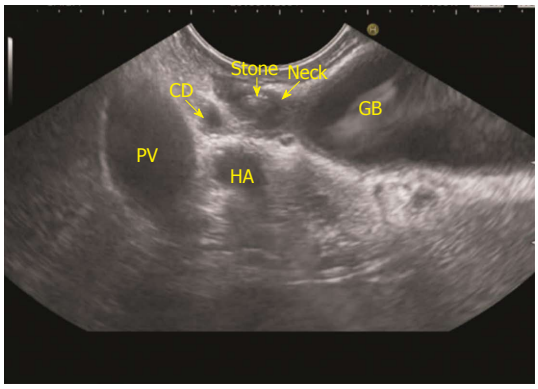


**Figure 7 A stone is seen in the neck of gall bladder.** These stones can be missed by routine abdominal ultrasound. The neck of the gall bladder is present just below the probe and the fundus is present at 3 o'clock position. PV: Portal vein; GB: Gall bladder.

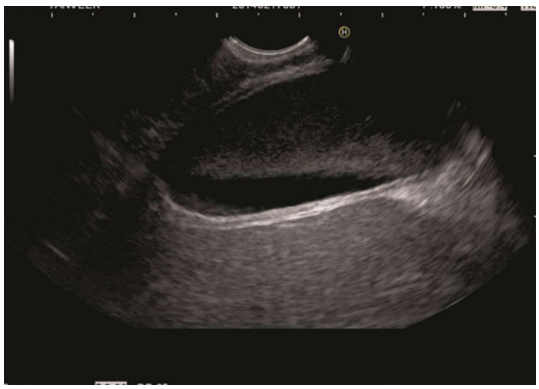

**Figure 8 The segment 5 of liver is seen beyond the gall bladder.** A layer of gall bladder (GB) sludge is seen in the lumen of GB.

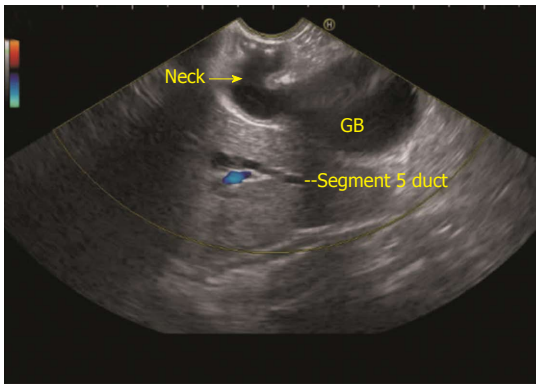


**Figure 9 The neck of the gall bladder is present just below the probe and the fundus is present at 3 o'clock position.** The segment 5 duct is seen beyond the GB. GB: Gall bladder.

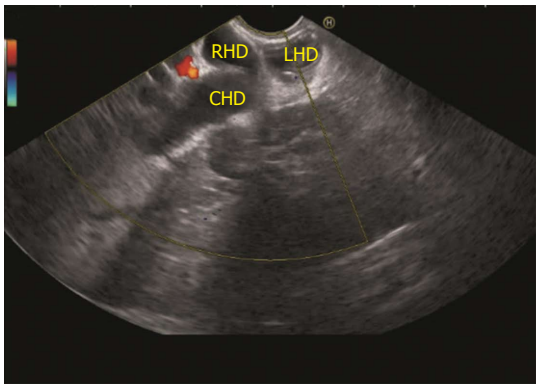


**Figure 10 Once the gall bladder imaging is done from duodenal bulb an anticlockwise rotation can trace the common bile duct towards the hilum of liver.** The CHD is seen to be dividing into right and left hepatic duct. RHD: Right hepatic duct; LHD: Left hepatic duct; CHD: Common hepatic duct.

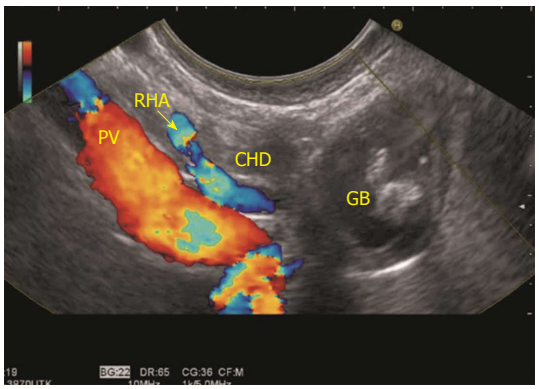


**Figure 11 The imaging is done from duodenal bulb and the portal vein is identified going from 5 o'clock position to 10 o'clock position in a long axis.** The CHD is identified between the probe and portal vein. The CHD is followed up by anticlockwise rotation and the remnant of gall bladder is seen in continuity with CHD. CHD: Common hepatic duct; GB: Gall bladder; PV: Portal vein.

wall is established after sucking the air out of the lumen of duodenum, by turning in an anticlockwise direction and by moving the up and down knobs generally in a downward direction (Figures 6-10). Home base position is identified with adequate rotation and minor adjustments of both knobs, where the portal vein is seen on the far side of the screen in a long axis (Figure 11). Clockwise rotation follows the CBD towards the papilla and anticlockwise rotation makes the scanning towards the liver hilum, the upper part of CBD, the cystic duct and GB (Figures 7-9). The CBD and GB are seen in the area between the probe and portal vein and

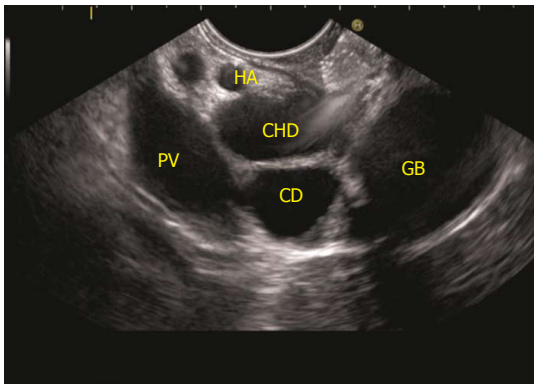


**Figure 12 The imaging is done from duodenal bulb and the portal vein is identified going from 5 o'clock position to 10 o'clock position in a long axis.** The CHD is identified between the probe and portal vein. The CHD is followed up by anticlockwise rotation and the continuity into cystic duct and gall bladder is seen. CHD: Common hepatic duct; PV: Portal vein; GB: Gall bladder.

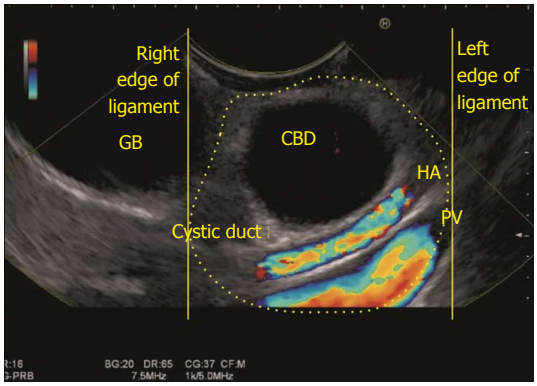


**Figure 13 The gall bladder imaging is done from descending duodenum with up deflection and anti-clockwise rotation.** The hepatoduodenal ligament is identified as a bean shaped structure between the probe and liver (shown in dotted yellow area). The CBD can be traced along the cystic duct and the gall bladder which lies outside the right edge of hepatoduodenal ligament. CBD: Common bile duct; GB: Gall bladder.

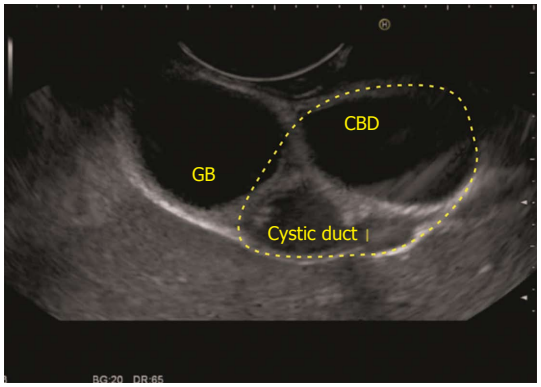


**Figure 14 The gall bladder imaging is done from descending duodenum.** The hepatoduodenal ligament is identified between the probe and liver (shown in dotted yellow area). The CBD, the cystic duct and the gall bladder are visualized on the under surface of liver. CBD: Common bile duct; GB: Gall bladder.

higher up between the probe and liver (Figure 12).

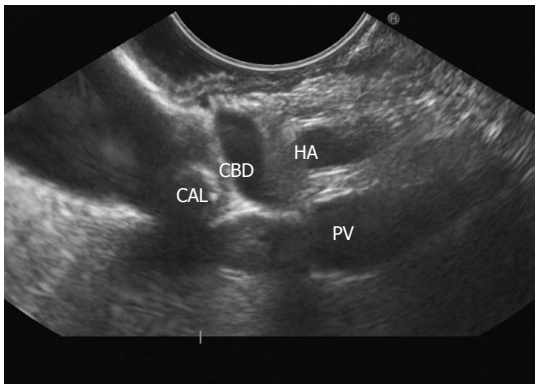


**Figure 15 The gall bladder imaging is done from descending duodenum with up deflection and anti-clockwise rotation.** The CBD can be traced and a stone is seen in the Cystic duct. The distended gall bladder is also visualized. PV: Portal vein; CBD: Common bile duct.

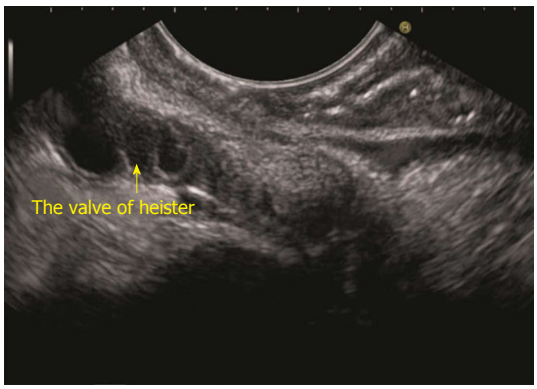


**Figure 16 The gall bladder imaging is done from descending duodenum with up deflection and anti-clockwise rotation.** The tortuous cystic duct with a spiral valve of Heister is seen.

### *Imaging from descending duodenum*

The GB lies close to the probe between 8 to 11 o'clock position. Imaging from descending duodenum requires the entry into 2nd part of duodenum followed by shortening of scope. After entry, multiple times pushing the scope in/out is required to place the echo endoscope into the descending duodenum (3rd part of duodenum). By combining three movements, *i.e.*, slow withdrawal up to the duodenal bulb, clockwise/anticlockwise torque and upward movement of the up/down knobs in third part of duodenum, there is better visualization of lower one third of CBD. The combination of three movements should be done with a main emphasis on anticlockwise rotation. During this rotation the superior mesenteric vein can be followed all the way towards the hilum where the portal vein is seen in a rounded axis within the hepatoduodenal ligament. The anechoic bile duct can be identified and followed all the way to the liver hilum (Figures 13-15). The continuity of CBD can be seen with the cystic duct and GB. Sometimes the valve of heister can be visualized within the cystic duct (Figure 16).

## CONCLUSION

The techniques described in the present paper are likely to provide the images as discussed in most of the cases and from majority of the stations. However, the reproducibility of the images may be compromised in the duodenal bulb due to the variability of the scope position and due to the balloon use. The basic concept of GB imaging by linear EUS is simple: Station 1 shows the GB at around 6 o'clock position, station 2 shows the GB at around 3 o'clock position and station 3 shows the GB at around 9 o'clock position. The difference between the three imaging is that effective imaging in station 1 lies above the neck of GB, in station 2 lies at the level of the neck of GB and station 3 lies below the level of the neck of GB. These techniques will be useful for evaluation of different kind of pathologies of GB by EUS[14-22].

## ACKNOWLEDGMENTS

Pran Prakash (Graphic designer) for his contribution in making figures and table.

## REFERENCES


1 **Dietrich CF**. Endoscopic Ultrasound: An Introductory manual and Atlas. New York: Thieme, 2006 [DOI: 10.1055/b-002-52057]

2 **Van Dam S**, Sivak MV. Gastrointestinal Endosonography. Philadelphia, Pennsylvania: Saunders, 1999

3 **Rosch T**, Will U, Chang KJ. Logitudianl Endosonography: Atlas and Manual for Use in the Upper Gastrointestinal Tract. Germany, 2001

4 **Gress FG**, Ishan B. Endoscopic Ultrasonography. Massachusetts: Wiley-Blackwell, 2001

5 **Al-Haddad M**. EUS in Bile Duct, Gallbladder, and Ampullary Lesions. In: Robert H. Hawes, Paul Fockens, Shyam Varadarajulu. Endosonography. Philadelphia: Saunders, 2015: 226-255. Available from: URL: https://www.us.elsevierhealth.com/endosonography-9780323221511.html

6 **Rameshbabu CS**, Wani ZA, Rai P, Abdulqader A, Garg S, Sharma M. Standard imaging techniques for assessment of portal venous system and its tributaries by linear endoscopic ultrasound: a pictorial essay. *Endosc Ultrasound* 2013; **2**: 16-34 [PMID: 24949362 DOI: 10.7178/eus.04.005]

7 **Sharma M**, Rai P, Rameshbabu CS, Arya S. Imaging of the pancreatic duct by linear endoscopic ultrasound. *Endosc Ultrasound* 2015; **4**: 198-207 [PMID: 26374577 DOI: 10.4103/2303-9027.162997]

8 **Sharma M**, Pathak A, Rameshbabu CS, Rai P, Kirnake V, Shoukat A. Imaging of pancreas divisum by linear-array endoscopic ultrasonography. *Endosc Ultrasound* 2016; **5**: 21-29 [PMID: 26879163 DOI: 10.4103/2303-9027.175878]

9 **Sharma M**, Rai P, Rameshbabu CS, Senadhipan B. Imaging of peritoneal ligaments by endoscopic ultrasound (with videos). *Endosc Ultrasound* 2015; **4**: 15-27 [PMID: 25789280 DOI: 10.4103/2303-9027.151317]

10 **Sharma M**, Rai P, Mehta V, Rameshbabu CS. Techniques of imaging of the aorta and its first order branches by endoscopic ultrasound (with videos). *Endosc Ultrasound* 2015; **4**: 98-108 [PMID: 26020043 DOI: 10.4103/2303-9027.156722]

11 **Sharma M**, Rameshbabu CS, Dietrich CF, Rai P, Bansal R. Endoscopic ultrasound of the hepatoduodenal ligament and liver hilum. *Endosc Ultrasound* 2016; Epub ahead of print [PMID: 27824022 DOI: 10.4103/2303]

12 **Pathak A**, Shoukat A, Thomas NS, Mehta D, Sharma M. Seagulls of endoscopic ultrasound. *Endosc Ultrasound* 2017; **6**: 231-234 [PMID: 28663526 DOI: 10.4103/2303-9027.190919]

13 **Owen CC**, Bilhartz LE. Gallbladder polyps, cholesterolosis, adenomyomatosis, and acute acalculous cholecystitis. *Semin Gastrointest Dis* 2003; **14**: 178-188 [PMID: 14719768]

14 **Sun XJ**, Shi JS, Han Y, Wang JS, Ren H. Diagnosis and treatment of polypoid lesions of the gallbladder: report of 194 cases. *Hepatobiliary Pancreat Dis Int* 2004; **3**: 591-594 [PMID: 15567752]

15 **Mitake M**, Nakazawa S, Naitoh Y, Kimoto E, Tsukamoto Y, Asai T, Yamao K, Inui K, Morita K, Hayashi Y. Endoscopic ultrasonography in diagnosis of the extent of gallbladder carcinoma. *Gastrointest Endosc* 1990; **36**: 562-566 [PMID: 2279643 DOI: 10.1016/S0016-5107(90)71164-9]

16 **Vijayakumar A**, Vijayakumar A, Patil V, Mallikarjuna MN, Shivaswamy BS. Early diagnosis of gallbladder carcinoma: an algorithm approach. *ISRN Radiol* 2012; **2013**: 239424 [PMID: 24959553 DOI: 10.5402/2013/239424]

17 **Kapoor A**, Kapoor A, Mahajan G. Differentiating malignant from benign thickening of the gallbladder wall by the use of acoustic radiation force impulse elastography. *J Ultrasound Med* 2011; **30**: 1499-1507 [PMID: 22039022 DOI: 10.7863/jum.2011.30.11.1499]

18 **Sugiyama M**, Atomi Y, Yamato T. Endoscopic ultrasonography for differential diagnosis of polypoid gall bladder lesions: analysis in surgical and follow up series. *Gut* 2000; **46**: 250-254 [PMID: 10644321 DOI: 10.1136/gut.46.2.250]

19 **Azuma T**, Yoshikawa T, Araida T, Takasaki K. Differential diagnosis of polypoid lesions of the gallbladder by endoscopic ultrasonography. *Am J Surg* 2001; **181**: 65-70 [PMID: 11248179 DOI: 10.1016/S0002-9610(00)00526-2]

20 **Yang HL**, Sun YG, Wang Z. Polypoid lesions of the gallbladder: diagnosis and indications for surgery. *Br J Surg* 1992; **79**: 227-229 [PMID: 1555088 DOI: 10.1002/bjs.1800790312]

21 **Gallahan WC**, Conway JD. Diagnosis and management of gallbladder polyps. *Gastroenterol Clin North Am* 2010; **39**: 359-367, x [PMID: 20478491 DOI: 10.1016/j.gtc.2010.02.001]

22 **Yang LP**, Yang ZL, Tan XG, Miao XY. [Expression of annexin A1 (ANXA1) and A2 (ANXA2) and its significance in benign and malignant lesions of gallbladder]. *Zhonghua Zhongliu Zazhi* 2010; **32**: 595-599 [PMID: 21122411]


**P- Reviewer**: Kikuyama M, Souza JLS, Yan SL **S- Editor**: Ji FF
**L- Editor**: A **E- Editor**: Li D

Published by **Baishideng Publishing Group Inc**
7901 Stoneridge Drive, Suite 501, Pleasanton, CA 94588, USA
Telephone: +1-925-223-8242
Fax: +1-925-223-8243
E-mail: bpgoffice@wjgnet.com
Help Desk: http://www.f6publishing.com/helpdesk
http://www.wjgnet.com