

Cronkhite-Canada syndrome with adenomatous polyposis

Radha Krishna Y, Ghoshal UC, Kumari N¹, Pandey R¹, Choudhuri G

Departments of
Gastroenterology and
¹Pathology, Sanjay Gandhi
Postgraduate Institute
of Medical Sciences,
Lucknow - 226 014, India

Correspondence:

Radha Krishna
E-mail: radhayellapu@
yahoo.co.in

Received : 31-01-08
Review completed : 28-02-08
Accepted : 17-04-08
PubMed ID : 18480533
J Postgrad Med 2008;54:144-6

A 20-year-old man with no prior complaints presented with progressive hyper pigmentation for 8 months, intermittent loose stools, hematochezia and vague abdominal pain. He also had anorexia and weight loss of 8 kg over last 8-mo. There was no family history of polyposis. On physical examination, he was lean, pale, had generalized hyperpigmentation, onychodystrophy [Figure 1] and alopecia. Initial evaluation ruled out Addison's disease as cortisol levels were normal. Lab tests revealed decreased Hb 113 g/L (normal 140-160), total protein 46 g/L (normal 55-85) and serum albumin 20 g/L (normal 35-55).

Esophagogastroduodenoscopy revealed polyps at gastro - esophageal junction, stomach was carpeted with multiple sessile polyps extending to duodenum [Figure 2]. Colonoscopy upto cecum showed multiple polyps (measuring 1-1.5 cm), mostly sessile, in the rectum, sigmoid colon, splenic flexure and cecum; a few polyps in the proximal colon were pedunculated [Figure 3] with erythematous intervening mucosa. Rectal polyps were removed at endoscopy and sent for histopathology. Histopathology revealed branching glands with pleomorphic nuclei and prominent nucleoli suggestive of adenomatous polyp. [Figure 4] Computed tomography of the abdomen detected multiple small bowel polyps.

On subsequent follow-up, he presented with severe abdominal pain, distension, vomiting and constipation Erect abdominal radiographs revealed dilated small bowel loops and multiple air fluid levels suggestive of acute intestinal obstruction. Exploratory laprotomy was done at this stage. Multiple polyps of variable sizes involving stomach, duodenum, jejunum, ileum and colon were found. Abdominal colectomy and ileo - rectal anastomosis was done. Histopathology of the colonic polyps revealed intact surface epithelium and cystically dilated tortuous glands containing polymorphonuclear leukocytic infiltrate within the lumen. The stroma between these glands was edematous and showed abundant mixed inflammatory cell

infiltrate suggestive of hamartomatous polyps. Many glands within the ileal and proximal colon polyps showed adenomatous change with moderate dysplasia [Figures 4,5]. During follow up over 5-months he remained well.

Discussion

CCS is an acquired polyposis syndrome that features hamartomatous polyps, similar to those of juvenile polyps, and epidermal changes. Cronkhite and Canada described the first 2 cases in 1955. Many case reports and several series reported about 400 patients in the English language literature.^[1-4] Approximately two thirds of reported cases occur in individuals of Japanese descent.^[3] Current understanding of the disease is based on small series and anecdotal reports. Commonly seen in adults, between 31-80 years.^[3] Youngest case reported ever was 17 years.^[5]

The cardinal features are adult onset, absence of a family history, multiple hamartomatous polyps, ectodermal changes consisting of alopecia, onychodystrophy, hyperpigmentation and eventually development of diarrhea and weight loss.

The etiology and factors leading to progression or spontaneous remission have not been established.^[6] In particular disturbances in two discrete epithelia, either concurrently or sequentially, is yet an unexplained phenomenon. Mental suffering or family problems, and physical fatigue are the most frequent precipitating factors for Japanese patients.^[3] Unlike many other

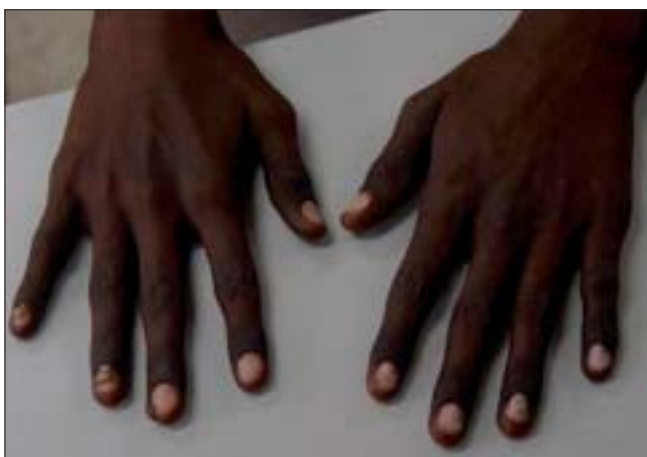

Figure 1: Hyperpigmentation and onychodystrophy of both hands

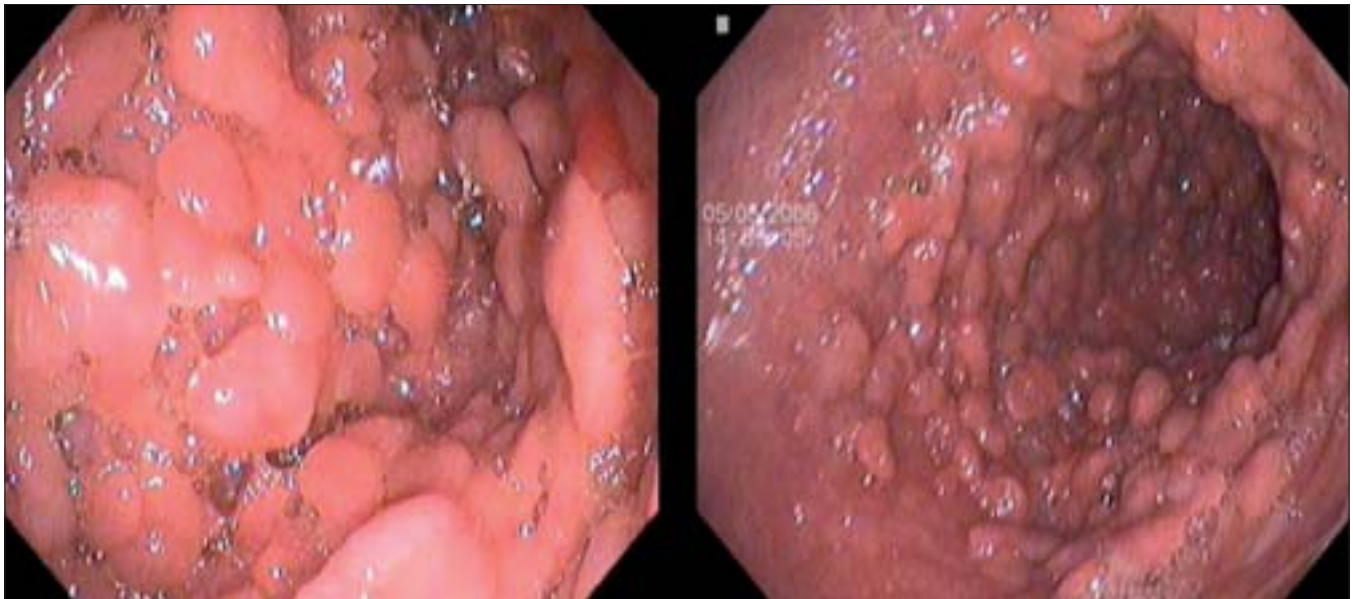


Figure 2: Gastric body and antrum carpeted with multiple sessile polyps

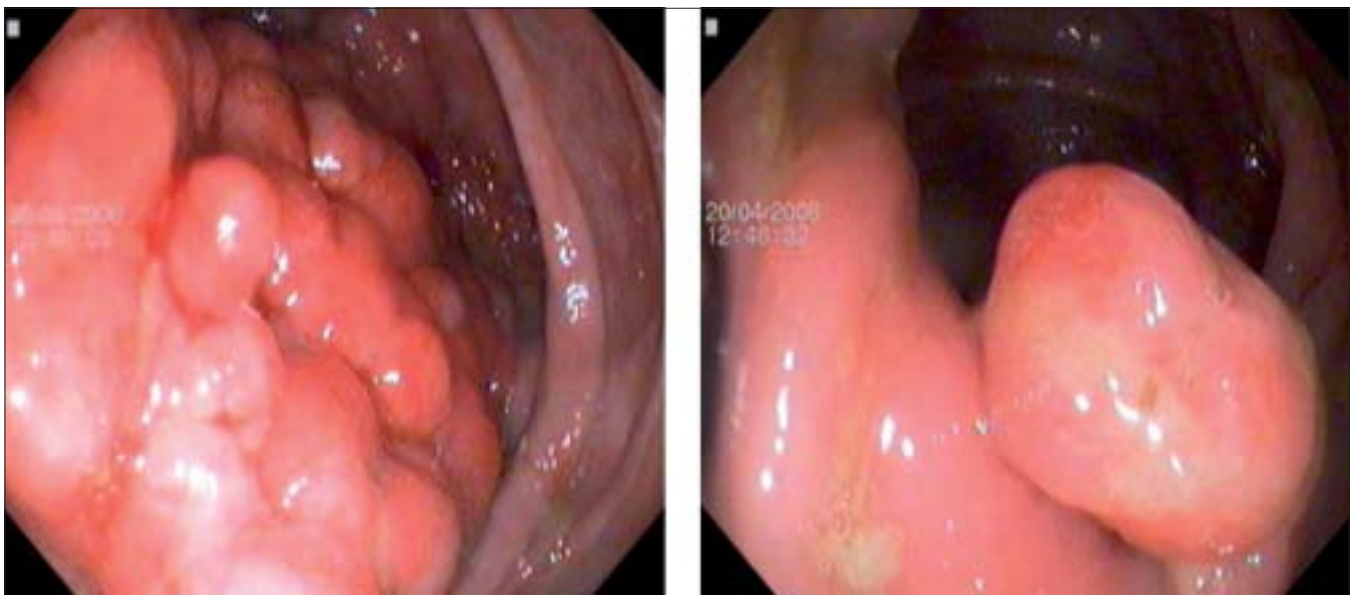


Figure 3: Colonic polyps: Sessile colonic polyps in transverse colon and splenic flexure, with erythematous intervening mucosa

GI polyposis syndromes, familial patterns of inheritance have not been identified.

The universal finding is hamartomatous polyps similar to the juvenile (retention) type throughout the GI tract without typically involving the esophagus.^[4] Mucosal changes are characterized by intact surface epithelium, edematous chronically inflamed lamina propria, and proliferated tortuous glands, some of which are cystically dilated and filled with proteinaceous fluid or inspissated mucus. The mucosa often contains engorged vascular channels, surface erosions, and prominent eosinophilic infiltration.

Although it was generally assumed that juvenile polyps did not undergo malignant transformation, numerous case reports have suggested that CCS is associated with colorectal carcinoma. Adenomatous and malignant transformation of polyps in CCS has been reported, but whether CCS is a risk factor for malignancy remains controversial. A group from Japan found a 40% prevalence of serrated adenomatous polyps in CCS patients compared with a 1% incidence of this histology in all GI polyps.^[2] Furthermore, the same group described a patient with microsatellite instability and over expression of the p53 protein in the cancer and serrated adenoma. They proposed the possibility of a serrated adenoma - carcinoma sequence

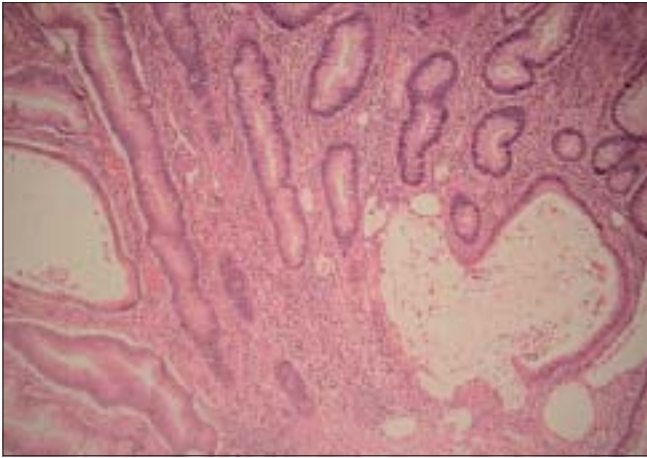


Figure 4: Low power photomicrograph of hamartomas polyp showing cystically dilated and tortuous glands containing polymorphonuclear leukocytic infiltrate in the glandular lumen

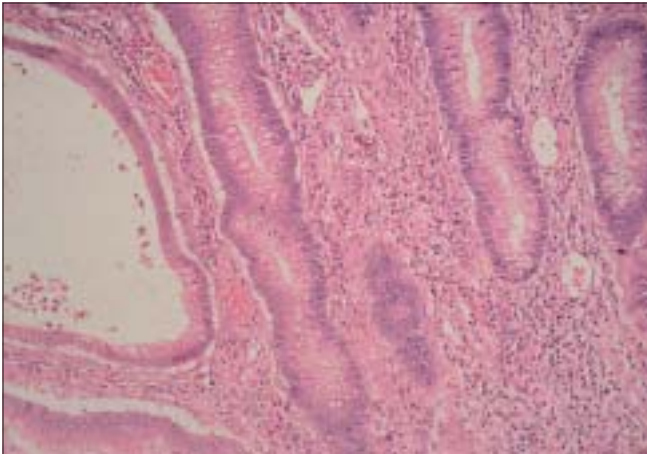


Figure 5: High power photomicrograph showing adenomatous change in the glandular epithelium

underlying some CCS GI malignancy. Adenomatous and carcinomatous transformation of colonic polyp was reported in only one other patient from India apart from the index case.^[6]

Despite therapy, mortality rate approaches 60%; there are, however, long-term survivors and some individuals undergo spontaneous remission.^[7] In patients with fulminant disease, treatment is directed toward supportive care. Management of fluids and electrolytes, nutrition, and transfusion are important considerations. There is no effective medical therapy for this condition, although the use of systemic anabolic steroids has been reported. Resection of stomach and colorectum may be indicated if heavily carpeted with polyps or the source of excessive bleeding, bowel obstruction, or cancer.

References

1. Daniel ES, Ludwig SL, Lewin KJ, Ruprecht RM, Rajacich GM, Schwabe AD. The Cronkhite-Canada Syndrome: An analysis of clinical and pathologic features and therapy in 55 patients. *Medicine (Baltimore)* 1982;61:293-309.
2. Samoha S, Arber N. Cronkhite-Canada syndrome. *Digestion* 2005;71:199-200.
3. Goto A. Cronkhite-Canada syndrome: Epidemiological study of 110 cases reported in Japan. *Nippon Geka Hokan* 1995;64:3-14.
4. Nonomura A, Ohta G, Ibata T, Shinozaki K, Nishino T. Cronkhite-Canada syndrome associated with sigmoid cancer case report and review of 54 cases with the syndrome. *Acta Pathol Jpn* 1980;30:825-45.
5. Vernia P, Marcheggiano A, Marinaro V, Morabito S, Guzzo I, Pierucci A. Is Cronkhite-Canada syndrome necessarily a late-onset disease? *Eur J Gastroenterol Hepatol* 2005;17:1139-41.
6. Jain A, Nanda S, Chakraborty P, Kundra A, Anuradha S, Reddy BS, *et al.* Cronkhite-Canada syndrome with adenomatous and carcinomatous transformation of colonic polyp. *Indian J Gastroenterol* 2003;22:189-90.
7. Ward EM, Wolfsen HC. Pharmacological management of Cronkhite-Canada syndrome. *Exp Opin Pharmacother* 2003;4:385-9.

Source of Support: Nil, **Conflict of Interest:** Not declared.