

# THE HISTOCHEMICAL DEMONSTRATION OF GLYCERALDEHYDE-3-PHOSPHATE DEHYDROGENASE ACTIVITY

S. RALPH HIMMELHOCH and MORRIS J. KARNOVSKY, M.B.B.Ch.

From the Department of Pathology, Harvard Medical School, Boston

## ABSTRACT

A histochemical method for demonstration of glyceraldehyde-3-phosphate dehydrogenation by tissues is described. The method utilizes Nitro BT as an indicator, glyceraldehyde-3-phosphate obtained from hydrolysis of commercially obtainable glyceraldehyde-3-phosphate diethylacetal (monobarium salt) as substrate, and (ethylenediamine)tetraacetic acid disodium as an activating agent in a medium buffered to pH 7.2 by 0.2 M sodium phosphate. The heat lability, substrate and coenzyme specificity, and sulfhydryl and phosphate dependence of the tissue component catalyzing this reaction indicate that glyceraldehyde-3-phosphate dehydrogenase activity is being demonstrated. The disparity between the known pH optimum of this enzyme and that determined histochemically, and the anomalous histochemical localization to mitochondria of this enzyme which has been found in the soluble fraction by differential centrifugation, are thought to result from the diaphorase dependence of the tetrazolium methods and to emphasize the need for caution in the interpretation of histochemically determined intracellular localization of dehydrogenating enzymes. The evidence gathered by previous workers concerning the feasibility of demonstrating specific dehydrogenases with Nitro BT, and the correspondence of the distribution of glyceraldehyde-3-phosphate dehydrogenase determined histochemically with available quantitative data, suggest that at the cellular level the histochemical results accurately reflect the distribution of this enzyme.

The synthesis of Nitro BT (2,2'-di-*p*-nitrophenyl-5,5' - diphenyl - 3,3' - (3,3' - dimethoxy - 4,4' - biphenylene)ditetrazolium chloride) (21) and its introduction as a histochemical reagent (9) made possible the specific and sensitive histochemical demonstration of many dehydrogenase activities. Histochemical methods for the demonstration of activities of every dehydrogenating component of the Krebs cycle except alpha-ketoglutaric dehydrogenase (9-11, 15) and of both dehydrogenating enzymes of the hexose-monophosphate shunt (11, 15) are now available.

Although histochemistry is thus evolving into a powerful tool in the precise definition of the various metabolic potentials of different cells

within the same tissue, there remain major gaps in the spectrum of methods, which hinder complete study of the known major pathways of carbohydrate metabolism. One of the chief of these gaps is the absence of a histochemical method for the direct demonstration of glycolytic activity. Activity of lactic dehydrogenase, a peripheral enzyme insofar as glycolysis is concerned, is at present the only demonstrable indication of the Embden-Meyerhof pathway.

This paper describes a method for the histochemical demonstration of glyceraldehyde-3-phosphate dehydrogenase activity. Evidence is presented supporting the specificity of the method, and a description is given of the distribution in

several tissues of the rat, embryonic hamster, and *Necturus*. This enzyme is of interest not only because it is of central importance to glycolysis, but also because it is the first histochemically demonstrable enzyme which catalyzes a reaction that produces "energy rich" phosphate at the substrate level.

## MATERIALS AND METHODS

### 1. Preparation of Substrate

Substrate was prepared from glyceraldehyde-3-phosphate diethylacetal (monobarium salt),<sup>1</sup> which is commercially available, by converting the barium salt to the free acid, hydrolyzing the acetal bond, and distilling off the ethanol liberated by hydrolysis. Preparative procedures were modifications of those recommended to the manufacturer by E. Racker.<sup>2</sup>

250 mg. of glyceraldehyde-3-phosphate diethylacetal (monobarium salt) were placed in a glass centrifuge tube with 0.8 gm. of Dowex 50 resin in the hydrogen form and 2.0 ml. of distilled water. The contents were then mixed thoroughly and the tube was placed for 3 minutes in a boiling water bath. Thorough mixing of the contents of the tube was assured by passing a continuous stream of oxygen-free nitrogen through the tube as long as it was in the water bath. At the end of 3 minutes the tube was immediately placed in a crushed ice bath and its sides and the walls of the bubbling pipette were washed down with a few drops of distilled water. It was then centrifuged for 10 minutes and the supernatant fluid carefully pipetted off and transferred to another container. The resin was then washed with 1 ml. of distilled water, which was collected after centrifugation for 10 minutes and added to the initial supernatant solution. Usually the total amount of solution collected after all the washings was about 3 ml.

The glyceraldehyde-3-phosphate now present was titrated to pH 7.2 with 2.0 M sodium hydroxide. Usually this required 0.6 ml. of base. Suitable dilutions were now prepared for incubation, and an aliquot was reserved for assays.

### 2. Assay of Substrate Concentration

Assay of substrate concentration was performed by measurement of alkali-labile phosphate in the following manner: A suitable aliquot of the substrate obtained as described above was made 1 N to sodium

<sup>1</sup>The samples used in these experiments were obtained from Schwarz Bioresearch, Mount Vernon, New York, and Nutritional Biochemical Corporation, Cleveland.

<sup>2</sup>"Specifications Sheet" supplied by Schwarz Bioresearch, Mount Vernon, New York.

hydroxide and allowed to stand at room temperature for 10 minutes.<sup>2</sup> It was then titrated back to neutrality with concentrated hydrochloric acid, and the inorganic phosphate concentration of the sample was analyzed by the method of SubbaRow and Fiske as modified by King (7). This value was compared with that obtained from another aliquot which had not been treated with alkali, and the difference was taken to be an estimate of the glyceraldehyde-3-phosphate present.

Ethanol concentration in the substrate solution was measured enzymatically (20), to be sure that none of the alcohol liberated by hydrolysis of the acetal bond remained in the final substrate solution.

### 3. Incubating Medium

The optimal incubating medium was found to consist of:<sup>3</sup>

Substrate solution	0.30 ml.
Diphosphopyridine nucleotide (5.0 mg./ml.)	0.25 ml.
Nitro BT (5.0 mg./ml.)	0.20 ml.
Buffer (0.2 M phosphate, pH 7.2)	0.50 ml.
(Ethylenediamine)tetraacetic acid disodium salt (6.0 mg./ml.)	0.10 ml.
Distilled water	0.25 ml.

This solution (preferably with the DPN omitted) could be stored at  $-20^{\circ}\text{C}$ . for at least one month with no loss of usefulness.

Experiments by which this optimum medium was determined included: (a) variation of the substrate concentration from  $7 \times 10^{-3}$  M to  $50 \times 10^{-3}$  M; (b) variation of the pH from 5.0 to 8.0; (c) incorporation of  $1 \times 10^{-3}$  M sodium cyanide or  $1 \times 10^{-3}$  M sodium azide into the medium (to block transfer of electrons to the cytochrome system rather than the tetrazolium); this was attempted in spite of the failure of Nachlas *et al.* (9-11) to find improvement of reactions with cyanide or anaerobic incubation conditions, since cyanide and azide were found by Pearse to produce increased intensity of reactions even employing Nitro BT (15); (d) incorporation of  $1 \times 10^{-3}$  M adenosine diphosphate into the medium (to promote the breakdown of 1,3-diphosphoglyceric acid and thus produce more favorable equilibrium conditions for the reaction).

### 4. Preparation of Tissues

For optimum results the reaction was always performed on tissue removed immediately from the

<sup>3</sup>Diphosphopyridine nucleotide was obtained from Sigma, St. Louis; Nitro BT was obtained from Dajac Laboratories, Philadelphia; (ethylenediamine)tetraacetic acid disodium salt was obtained from Eastman Organic Chemicals, Rochester, New York.

decapitated animal and quenched within 30 seconds of removal in isopentane cooled to  $-70^{\circ}\text{C}$ . by an acetone dry ice bath. Sections 8 to 10 microns in thickness were cut at  $-20^{\circ}\text{C}$ . in a cryostat, mounted on half-coverslips, finger-thawed, allowed to dry for 3 minutes at room temperature, and then fixed in acetone at  $4^{\circ}\text{C}$ . for 20 minutes (14). Following fixation the sections were quickly rinsed in 0.85 per cent saline and placed in 1 ml. of incubation medium at  $37^{\circ}\text{C}$ . for periods of time ranging from 3 to 20 minutes. Anaerobic incubation was attempted but was found to be completely unnecessary, as was shown by Nachlas *et al.* (9) when Nitro BT served as electron acceptor from succinate. Following incubation the sections were rinsed briefly in saline, fixed for 20 minutes in Baker's formol calcium fixative<sup>4</sup> at  $4^{\circ}\text{C}$ ., rinsed again in saline, and mounted in gelatin.

Tissue blocks could be stored for as long as 2 months at  $-70^{\circ}\text{C}$ . with little or no loss of activity.

### 5. Control Experiments; Tests of Specificity

Standard controls consisted of (a) boiling the section before incubation; (b) incubation of sections in medium without substrate; and (c) incubation of sections in medium without coenzyme. In addition, the effects of preincubation of sections in  $1 \times 10^{-2}$  M sodium iodoacetate and  $1 \times 10^{-3}$  M *p*-chloromercuribenzoate, as well as the effects of actually incorporating these poisons into the incubation medium, were examined. Specificity was further tested first by incubating sections in a medium in which glyceraldehyde-3-phosphate was replaced by the product (glyceraldehyde) obtained from its alkaline hydrolysis, and finally by incubation in media which contained no phosphate ion, phosphate buffer being replaced by 0.2 M tris(hydroxymethyl)amino-methane.

## RESULTS

### 1. Yield of Substrate, Effects of Varying Substrate Concentration

The SubbaRow-Fiske determinations indicated that a 60 to 80 per cent yield of glyceraldehyde-3-phosphate could be expected when hydrolysis of the starting material was carefully carried out. The optimum substrate concentration for the histochemical method was found to be  $3.6 \times 10^{-2}$  M. Above this level no additional increase in staining could be obtained. Indeed, when a concentration above  $4.5 \times 10^{-2}$  M was used considerable inhibition of the reaction occurred. Adequate

<sup>4</sup> 10 per cent formalin, 2 per cent calcium chloride.

reaction could be obtained with concentrations as low as  $1.5 \times 10^{-2}$  M.

### 2. Degree of Ethanol Contamination

No ethanol could be detected in the final substrate solution. The method for ethanol would have detected as little as  $1 \times 10^{-4}$  M ethanol in the substrate solution. Consequently the ethanol concentration in the incubation medium was certainly less than  $3 \times 10^{-5}$  M.

### 3. Effects of Possible Activating Factors

Cyanide, azide, magnesium, fluoride, adenosine diphosphate, and anaerobic incubation did not improve the reaction. (Ethylenediamine)tetraacetate produced marked activation, probably because of the removal of contaminating heavy metal ions.

### 4. Controls

None of the controls showed any reaction, except that when short preincubations (less than 15 minutes) in iodoacetate or *p*-chloromercuribenzoate were carried out inactivation was not quite complete.

### 5. Effects of pH and Phosphate Ion on Activity

Maximal activity was observed at pH 7.2. Activity fell off sharply both above and below this level of hydrogen ion concentration. At pH 7.8 activity was very faint. At pH 5.9 no activity could be demonstrated.

No reaction was observed in the absence of phosphate ion. Maximal activity was obtained in 0.2 M phosphate solutions.

### 6. Localization in the Tissues

(a) *Nervous System:* PERIPHERAL NERVE. Formazan was deposited only in the Schwann cells and the cells of the perineurium.

SPINAL CORD. The anterior horn cells of the spinal cord were intensely stained over the entire soma and in the cell processes (Fig. 1). Small fibers traversing the gray matter also stained intensely. The white matter showed slight, if any, formazan deposition.

CEREBELLUM. The Purkinje cells reacted intensely, as did the basket cells of the granular layer (Fig. 2). The axones of the Purkinje cells

could not be visualized. Formazan deposition occurred in the soma of the cells as small dots with mitochondrial dimensions. The molecular layer showed formazan deposition confined to glial fibers. The white matter gave only very slight reaction.

**CEREBRAL CORTEX.** All layers of the gray matter reacted well. The white matter was almost completely inactive.

(b) *Cardiovascular System:* **HEART.** Cardiac muscle was one of the most active tissues studied (Fig. 3). Sites of formazan deposition were arranged in rows of dots of mitochondrial dimensions along the length of the fibers (not illustrated) and in a laminated pattern in cross section (Fig. 3).

**ARTERIES.** The smooth muscle cells in the media of arteries of all sizes were intensely active.

(c) *Gastrointestinal Tract:* **ESOPHAGUS.** The mucosa of the esophagus was divided into three layers; a basal layer (stratum germinativum) of intense, a middle layer of moderate, and a super-

ficial layer of no formazan deposition. Strong reaction was given, in addition, by the muscularis externa, the smooth muscle cells of the muscularis mucosae, and the fibroblasts of the lamina propria (Fig. 4).

**SMALL BOWEL.** The surface lining epithelium was intensely stained, but the epithelial cells lining the crypts showed only moderate formazan deposition. The smooth muscle cells of all the muscular coats were intensely stained (Fig. 5).

**LARGE BOWEL.** The surface lining epithelium was, again, quite darkly stained although the glandular epithelium was only moderately so. The smooth muscle cells both of the muscularis mucosae and of the muscularis externa and the ganglion cells of Auerbach's plexus reacted intensely.

**LIVER.** All the parenchymal cells of the liver showed intense formazan deposition. In the portal triads only the radicles of the hepatic artery were stained; the central vein did not react (Fig. 6).

**PANCREAS.** The pancreatic acini and ducts

---

**FIGURE 1**

Spinal cord of rat. Anterior horn cells with their cell processes show formazan deposition.  $\times 160$ .

**FIGURE 2**

Cerebellum of rat. Both the Purkinje cells (below) and the cells of the granular layer (above) are strongly stained. In the Purkinje cells the formazan is localized in granules of mitochondrial dimensions.  $\times 832$ .

**FIGURE 3**

Heart muscle of rat. In transverse section the strong reaction can be seen to be organized in a laminated pattern.  $\times 640$ .

**FIGURE 4**

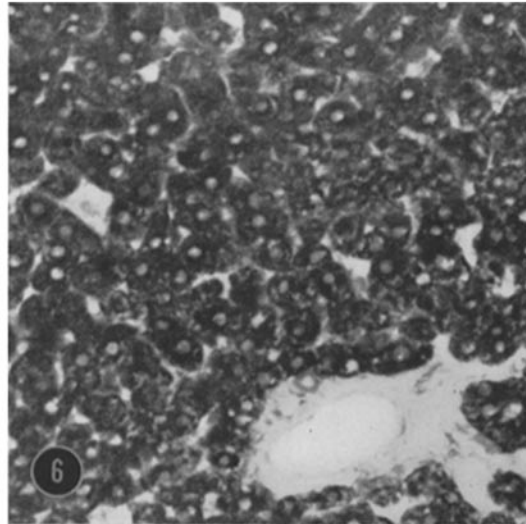
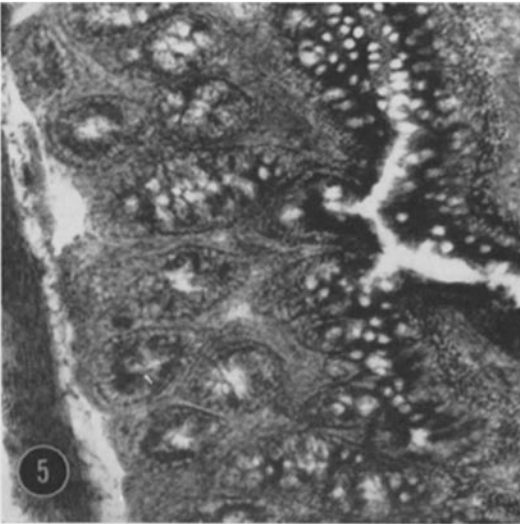
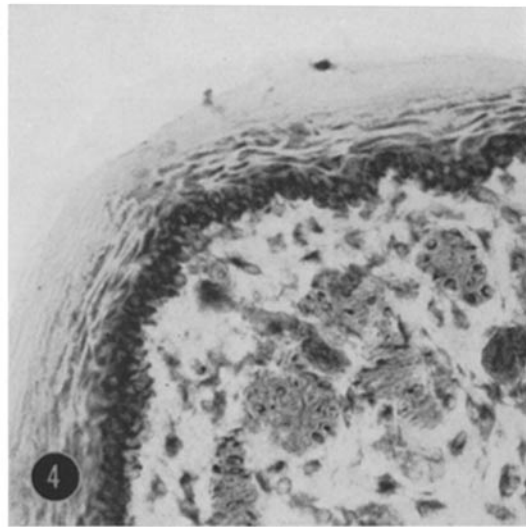
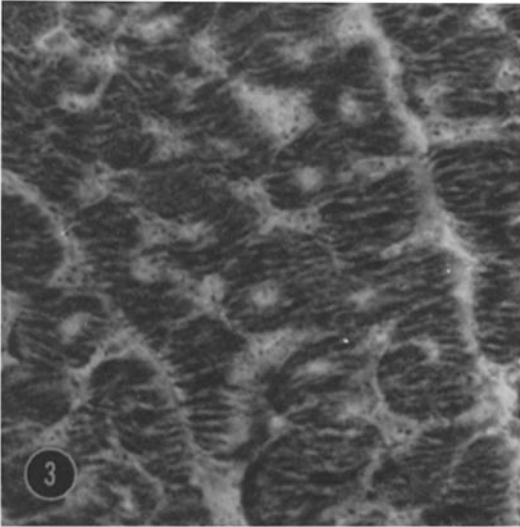
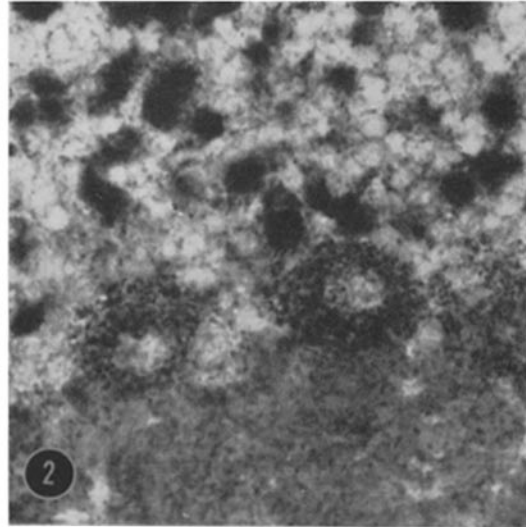
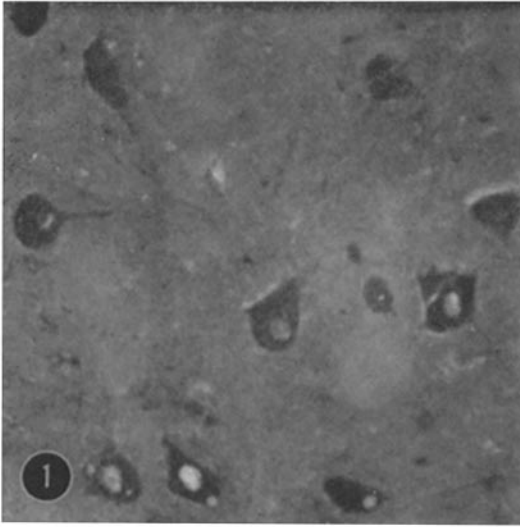
Esophagus of rat. The mucosa is clearly divided into three zones, the stratum germinativum showing the highest and the superficial stratum the lowest degree of formazan deposition. Stromal cells are moderately active.  $\times 160$ .

**FIGURE 5**

Small intestine of rat. The superficial lining cells of the mucosa (right) are much more active than the cells lining the crypts (middle). The muscularis (left) is intensely active. The stromal cells of the submucosa are seen to give a moderate reaction.  $\times 160$ .

**FIGURE 6**

Liver of rat. The cells of the hepatic parenchyma show intense activity. Except for the smooth muscle cells in the media of the radicle of the hepatic artery, which is not conspicuous, the portal triad is completely negative (lower right), as are the central veins.  $\times 160$ .



showed moderate formazan deposition; all the cells of the islets of Langerhans were very darkly stained (Fig. 7).

(d) *Genito-Urinary System: KIDNEY.* Cells located in the glomerular tuft which did not have the arrangement of endothelium and were presumably epithelial were moderately darkly stained. Both the proximal and distal tubules were intensely stained (Fig. 8). About one-half of the thin limbs reacted; the others were completely negative. Collecting ducts showed only slight formazan deposition.

(e) *Endocrine System: THYROID GLAND.* The follicular epithelium reacted moderately.

*ADRENAL GLAND.* The zona fascicularis and zona reticularis of the adrenal were the most darkly stained of the tissues studied, whereas the zona glomerulosa was completely negative (Fig. 9). The chromaffin cells of the adrenal medulla were negative, but the ganglion cells showed intense formazan deposition.

*TESTIS.* Both Leydig cells and fibroblasts in the interstitium of the testis were intensely stained. A single row of cells around the basement membrane of the tubules, presumably the spermatogonia, showed moderate formazan deposition, but the cells closer to the lumen, presumably primary and secondary spermatocytes, were only very faintly stained. A segment of the sperms, presumably the mid-piece, extending from the caudal extremity of the head but ending considerably short of the end of the tail, was intensely stained.

*OVARY.* In early follicles the ovum was faintly positive and the follicular epithelium only slightly more so. In more mature follicles the basal layer of follicular epithelium became quite darkly stained, but the remainder of the epithelial cells remained only faintly stained. The thecae reacted but faintly. Both the stroma of the ovary and its peritoneal cover were extremely reactive.

(f) *Musculoskeletal Tissues: STRIATED MUSCLE.* In a mixed muscle, red and white fibers could be

---

**FIGURE 7**

Pancreas of rat. The islet of Langerhans (upper left) shows intense activity in all its cells. The activity of the acinar tissue and ducts is more moderate.  $\times 160$ .

**FIGURE 8**

Kidney of rat. Both distal and proximal tubules give intense reactions. Some cells in the glomerular tuft (upper left) are seen to be quite active.  $\times 256$ .

**FIGURE 9**

Adrenal cortex of rat. The zones of the cortex are intensely active except for the zona glomerulosa (above), which shows little activity.  $\times 160$ .

**FIGURE 10**

Rectus abdominis muscle of rat. The large (white) fibers can easily be seen to have far less activity than the small (red) fibers.  $\times 160$ .

**FIGURE 11**

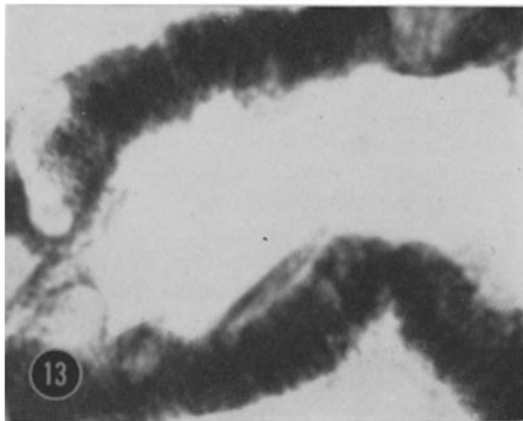
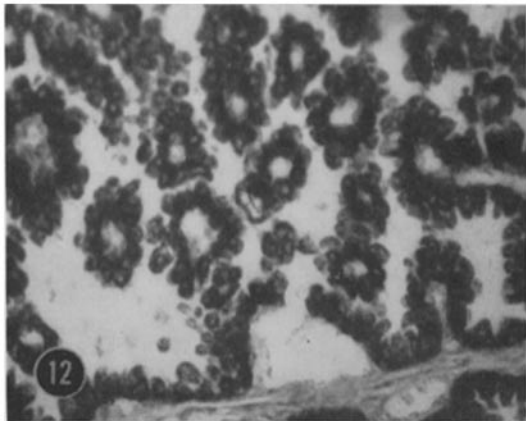
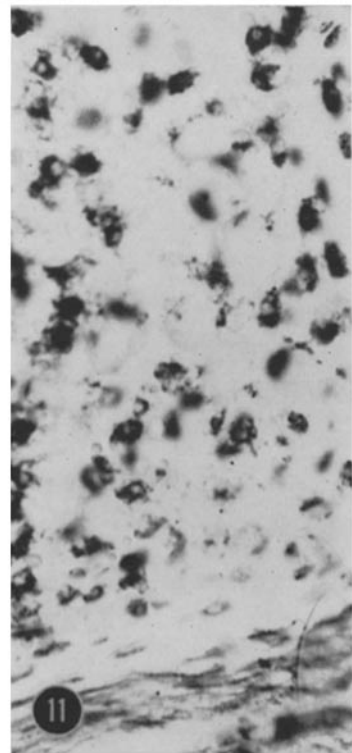
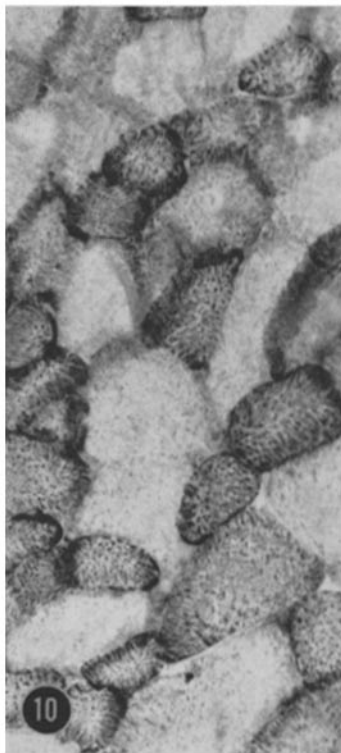

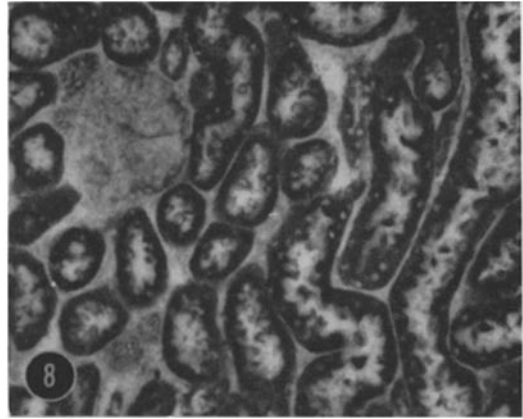
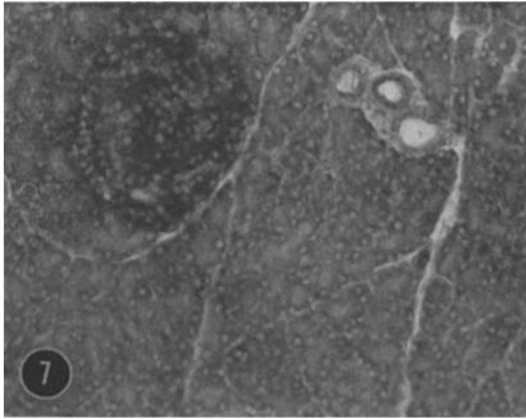
Tracheal cartilage of rat. The chondrocytes lying near the perichondrium (below) are far less active than the hypertrophied cells (above).  $\times 256$ .

**FIGURE 12**

Placenta of hamster on the eleventh day. The cells of the yolk sac are strongly active.  $\times 160$ .

**FIGURE 13**

Renal distal tubule of *Necturus maculosus*. Strong formazan deposition is seen to be arranged in the form of striae which correspond in size, shape, and position to the prominent mitochondria of this tubular segment.  $\times 832$ .



clearly distinguished by virtue of the stronger staining of the red fibers (Fig. 10). The arrangement of formazan was as in cardiac muscle (Fig. 3).

**CARTILAGE.** Both in epiphyseal cartilage and in tracheal cartilage chondrocytes were stained. Cells deep in the cartilage were much darker than those lying closer to the perichondrium (Fig. 11).

(g) *Embryonic and Related Tissues:* Eleventh-day hamster placenta and eleventh-day hamster embryo were studied. All layers of the placenta and the yolk sac were sites of great formazan deposition (Fig. 12). In particular, the giant cells and the spongy layer were among the most darkly staining tissues studied.

Strongly stained embryonic tissues included central nervous system, myotomal cells, cardiac muscle, bowel epithelium, and cartilage.

## DISCUSSION

Mammalian glyceraldehyde-3-phosphate dehydrogenase is known to be a protein which catalyzes the oxidation of glyceraldehyde-3-phosphate to 1,3-diphosphoglyceric acid by a reaction which depends on sulfhydryl groups, requires diphosphopyridine nucleotide specifically as coenzyme, and utilizes inorganic phosphate as an additional substrate (19).

Since the reaction studied in these experiments proved to depend on a heat-labile tissue component, to require glyceraldehyde-3-phosphate, inorganic phosphate, and diphosphopyridine nucleotide, and to be reversibly inhibited by low concentrations of substances known to react with sulfhydryl groups, there is little doubt that glyceraldehyde-3-phosphate dehydrogenase activity was being demonstrated.

The possibility that ethanol liberated from the diethylacetal present initially was producing a spurious reaction for ethanol dehydrogenase was eliminated by the proved absence of ethanol from the incubation medium. When glyceraldehyde was substituted for glyceraldehyde-3-phosphate in the reaction medium, no reaction was obtained. This excludes the possibility that glyceraldehyde inadvertently released by the hydrolysis procedure was giving a false positive reaction by acting as a substrate for aldehyde dehydrogenase.

Before Nitro BT was introduced, there was no available tetrazolium salt whose histochemical characteristics (ease of reduction, substantivity, etc.) were favorable enough to permit the demon-

stration of specific pyridine nucleotide-linked dehydrogenases. Farber and his coworkers showed in a classical series of papers (3-5, 18) that this was because the tetrazolium salts are not reduced directly by pyridine nucleotide-linked dehydrogenases but, rather, by DPN or TPN diaphorase. These latter enzymes catalyze the reduction of tetrazolium salts by DPNH or TPNH, whether these be added to the medium directly, or produced from DPN or TPN by the action of some DPN- or TPN-linked dehydrogenase on its substrate. When unfavorable tetrazolium salts are used with various exogenous substrates, but the same coenzyme, only one staining pattern is produced, although different staining patterns are obtained with one coenzyme from those obtained with the other. This is presumably because if reduction of the tetrazolium by the diaphorase does not occur very rapidly and easily, and if capture of the formazan is not rapid and complete, reduced coenzymes produced in one tissue site can diffuse away to others which, although they possess no dehydrogenase activity themselves, now give a false positive reaction by virtue of their diaphorase activity.

Nachlas *et al.* (10, 11) showed that this was not a problem with Nitro BT, even though Nitro BT like other tetrazoliums is dependent upon the diaphorases for its final reduction in a pyridine nucleotide-linked dehydrogenase system. Thus, specific patterns could be obtained with different substrates using the same coenzyme when Nitro BT was employed. This seems to establish beyond reasonable doubt the possibility of demonstrating specific pyridine nucleotide-linked dehydrogenases *at the cellular level*. This is to say, the Nitro BT methods will accurately indicate within their sensitivity which cells possess activity of specific pyridine nucleotide-linked dehydrogenases, provided the appropriate diaphorase is present.

The present method, as would be expected from these earlier results, demonstrates a cellular pattern which is distinct from that obtained for the diaphorase. For example, the adrenal zona glomerulosa possesses high diaphorase but low or absent glyceraldehyde-3-phosphate dehydrogenase activity. Thus, at the cellular level the method may be presumed to demonstrate the pattern of glyceraldehyde-3-phosphate dehydrogenase activity, rather than the pattern of diaphorase activity. This presumption is strengthened by the fact that there is substantial agreement



between our histochemical data and quantitative data available on the distribution of glycolytic enzymes (1, 2, 6, 8, 12, 19).

It is an entirely different question whether the *intracellular* localization of enzyme activities by the Nitro BT methods is accurate. By "intracellular" localization we mean the determination of which structures within the cell (mitochondria, nuclei, cytoplasmic sap, etc.) possess enzyme activity. Nachlas *et al.* (10) point out that further evidence must be accumulated on this point. Pearse goes so far as to suggest that the structures resembling mitochondria which he sees in his preparations demonstrating glucose-6-phosphate dehydrogenase activity contradict the localization of this enzyme to the supernatant fraction by differential centrifugation studies (15). Novikoff, on the other hand, thinks that crystallization artifacts could well be responsible for the "mitochondria" observed in histochemical sections (13).

We have no conclusive evidence to offer on this point. However, since glyceraldehyde-3-

phosphate dehydrogenase is the second enzyme activity previously presumed to be found exclusively in the supernatant fraction (16, 17) but histochemically present in structures resembling mitochondria (see Figs. 2, 3, 10, and 13), we would suggest that an artifact may be involved in the histochemical results. Thus, although the superior qualities of Nitro BT avoid artifactual localization of formazan at the cellular level, it is still possible that at the intracellular level the distribution of the formazan corresponds to the localization of the diaphorase rather than to that of the dehydrogenase in question.

This investigation was supported by grants from the William F. Milton Fund and the William W. Wellington Fund of Harvard University, and by Training Grant 2G-113 from the United States Public Health Service.

The authors are indebted to Miss Katharina Hug for skilled technical assistance.

Received for publication, September 9, 1960.

#### REFERENCES

1. BOYD, E. S., and NEUMAN, W. F., *Arch. Biochem. and Biophys.*, 1954, **51**, 475.
2. DAVSON, H., *A Textbook of General Physiology*, Boston, Little, Brown and Co., 1959, 645.
3. FARBER, E., STERNBERG, W. H., and DUNLAP, C. E., *J. Histochem. and Cytochem.*, 1956, **4**, 254.
4. FARBER, E., STERNBERG, W. H., and DUNLAP, C. E., *J. Histochem. and Cytochem.*, 1956, **4**, 284.
5. FARBER, E., STERNBERG, W. H., and DUNLAP, C. E., *J. Histochem. and Cytochem.*, 1956, **4**, 347.
6. GREENSTEIN, J. P., and MEISTER, A., in *The Enzymes*, (J. B. Sumner and K. Myrbäck, editors), New York, Academic Press, Inc., 1952, **2**, 2, 1131.
7. KING, E. J., *Biochem. J.*, 1932, **26**, 292.
8. LYNEN, F., HARTMANN, G., NETTER, K. F., and SCHUEGRAF, A., in *Ciba Symposium on the Regulation of Cell Metabolism*, (G. E. W. Wolstenholme and C. M. O'Connor, editors), 1958, 256.
9. NACHLAS, M. M., TSOU, K.-C., DE SOUZA, E., CHENG, C.-S., and SELIGMAN, A. M., *J. Histochem. and Cytochem.*, 1957, **5**, 420.
10. NACHLAS, M. M., WALKER, D. G., and SELIGMAN, A. M., *J. Biophysic. and Biochem. Cytol.*, 1958, **4**, 29.
11. NACHLAS, M. M., WALKER, D. G., and SELIGMAN, A. M., *J. Biophysic. and Biochem. Cytol.*, 1958, **4**, 169.
12. NACHMIAS, V. T., and PADYKULA, H. A., *J. Biophysic. and Biochem. Cytol.*, 1958, **4**, 47.
13. NOVIKOFF, A. B., and MASEK, B., *J. Histochem. and Cytochem.*, 1958, **6**, 217.
14. NOVIKOFF, A. B., SHIN, W. Y., and DRUCKER, J., *J. Histochem. and Cytochem.*, 1960, **8**, 37.
15. PEARSE, A. G. E., *Histochemistry: Theoretical and Applied*, Boston, Little, Brown and Co., 1960.
16. RACKER, E. and Wu, R., in *Ciba Symposium on the Regulation of Cell Metabolism*, (G. E. W. Wolstenholme and C. M. O'Connor, editors) 1959, 205.
17. ROODYN, D. B., *Internat. Rev. Cytol.*, 1959, **8**, 279.
18. STERNBERG, W. H., FARBER, E., and DUNLAP, C. E., *J. Histochem. and Cytochem.*, 1956, **4**, 266.
19. STUMPF, P. K., in *Chemical Pathways of Metabolism*, (D. M. Greenberg, editor), New York, Academic Press, Inc., 1954, 67.
20. THEORELL, H., and BONNICHSEN, R. K., *Acta Chem. Scand.*, 1951, **5**, 1105.
21. TSOU, K.-C., CHENG, C.-S., NACHLAS, M. M., and SELIGMAN, A. M., *J. Am. Chem. Soc.*, 1956, **78**, 6139.