MALUNION IN A FRACTURED TIBIA, DUE TO THE TENDON OF THE TIBIALIS ANTICUS.

BY D. J. HARRIES, M.D., F.R.C.S.,

CAPTAIN, R.A.M.C.,

Surgical Specialist, Ambala Brigade.

IN a thesis on "The growth and repair of bone in the human subject," submitted to the London University in March 1918, I endeavoured to lay stress on the influence of the surrounding tissues in determining the position and the amount of the callus formed at the site of a fracture. I also pointed out that the surrounding tissues are largely responsible for malunion, non-union, or the formation of a false joint between the fragments.

The case I am quoting in this article illustrates the truth of the above statements.

The history of the case is briefly as follows :—

The patient, Captain L. . . . m, aged 32, while motor-cycling on Armistice Night, 11th November, 1918, ran into a tree which had fallen across a part of the road. He was admitted into L. . . . e Station Hospital, where the usual methods of treatment with splints and extension were tried for about two months. On 19th January, 1919, I was asked to see the case. It was obvious, on examination of the leg, that in addition to considerable deformity, there was also no union between the tibial fragments. I decided that further non-operative measures were useless and had the patient transferred, on 24th January, 1919, to the Station Hospital at Ambala for operation.

Plate No. 1, taken on 26th January, 1919, shows—

(*a*) Gross displacement of the tibial fragments,

(*b*) Cross union between the lower tibial fragment and the fibular fragments,

(*c*) Defective callus formation from the upper tibial fragment.

On 28th January, 1919, the leg was operated on and the fractured area exposed. I found the upper end of the lower tibial fragment feebly united to the fibular fragments. The fractured surface of the upper tibial fragment was completely covered over by the tendon of the tibialis anticus, which was firmly united to it by dense fibrous tissue. A spur of bone, shown in the first plate, arched over the tendon in front, and was probably instrumental in holding it down before firm union by fibrous tissue had been established between it and the bone.

I freed the tibialis anticus, excised all the fibrous tissue in the vicinity, together with the tibial periosteum, for about an inch on each side of the fracture, chiselled off about a quarter inch of the fractured ends of the tibial fragments, brought the ends into apposition and then screwed on two steel plates, one on the external and one on the anterior surface of the bone. (*See* plate No. 2.) The incision was closed in the ordinary way and the limb bandaged and put up on a back-splint with a foot piece and two side pieces. Healing took place without any complications.

It is reasonable to assume that in this case the tendon of the tibialis anticus had got caught under the spur of bone mentioned above, and this had rendered the correction of the deformity by extension impossible unless the tendon had succeeded in slipping out from under the spur. The union of the tendon to the spur and the fractured surface soon did away with this possibility.

This union produced another interesting result, *viz.*, the complete prevention of callus formation from the upper fragment; and this occurred in spite of the fact that the main nutrient artery enters the upper fragment a few inches above the site of the fracture.

Plate No. 2, taken on 17th February, 1919, shows the bone in good position. There is commencing callus formation between the fractured ends.

Plate No. 3, taken on 5th March, 1919, shows a slightly more advanced stage, but there is still ensheathing callus visible.

Plate No. 4, taken on 25th March, 1919, shows a layer of ensheathing callus on the external surface of the tibia and also a certain amount of bone formation in the region of the interosseous membrane, extending from the tibial to the fibular fractured surfaces. A faint outline of this can be made out in plate No. 3.

On 27th March, 1919, the patient was discharged on two months' leave. He was then able to bear a fair amount of weight on the limb, although he was not allowed to walk about without the aid of a crutch.

I wish to thank Lieutenant-Colonel Brian Watts, D.S.O., for permission to report this case, and Major Pierpoint, I.M.S., for kindly supplying me with the prints of the X-ray plates.

HOW A SNAKE CATCHES HIS PREY.

BY K. ARDESHIR DARUKHANEWALA,

CAPTAIN, I.M.S.,

Medical Officer, War Hospital, Datia.

THE first of the accompanying photographs is of a common Brown Tree Snake (*Dipsadomorphus trigonatus*). The snake was seen at Indore running after a chameleon on a tree. As he approached his prey, he turned round as if to catch hold of it by the face and not from the opposite end. It took him about 18 minutes to swallow the whole thing. The snake was left undisturbed for half an hour. At the end of that time he was dropped down the tree and killed by means of chloroform. A post-mortem dissection shows how his prey was lying in the stomach. Mark that the digestion has already commenced at its head and part of it has been absorbed even in half an hour's time.

The second photograph shows how a snake catches hold of his prey and his mode of swallowing it. Mark the narrow ventrals, which clearly show the specimen to be a non-poisonous one, an *Eryx conicus* or a Russell's earth snake.

MALUNION IN A FRACTURED TIBIA, DUE TO THE TENDON OF THE TIBIALIS ANTICUS.

By Captain D. J. HARRIES, M.D., F.R.C.S. R.A.M.C,

Surgical Specialist, Ambala Brigade.



Position of tendon of tibialis anticus in the reversed print.

As seen in the right leg of the patient.

PLATE I.

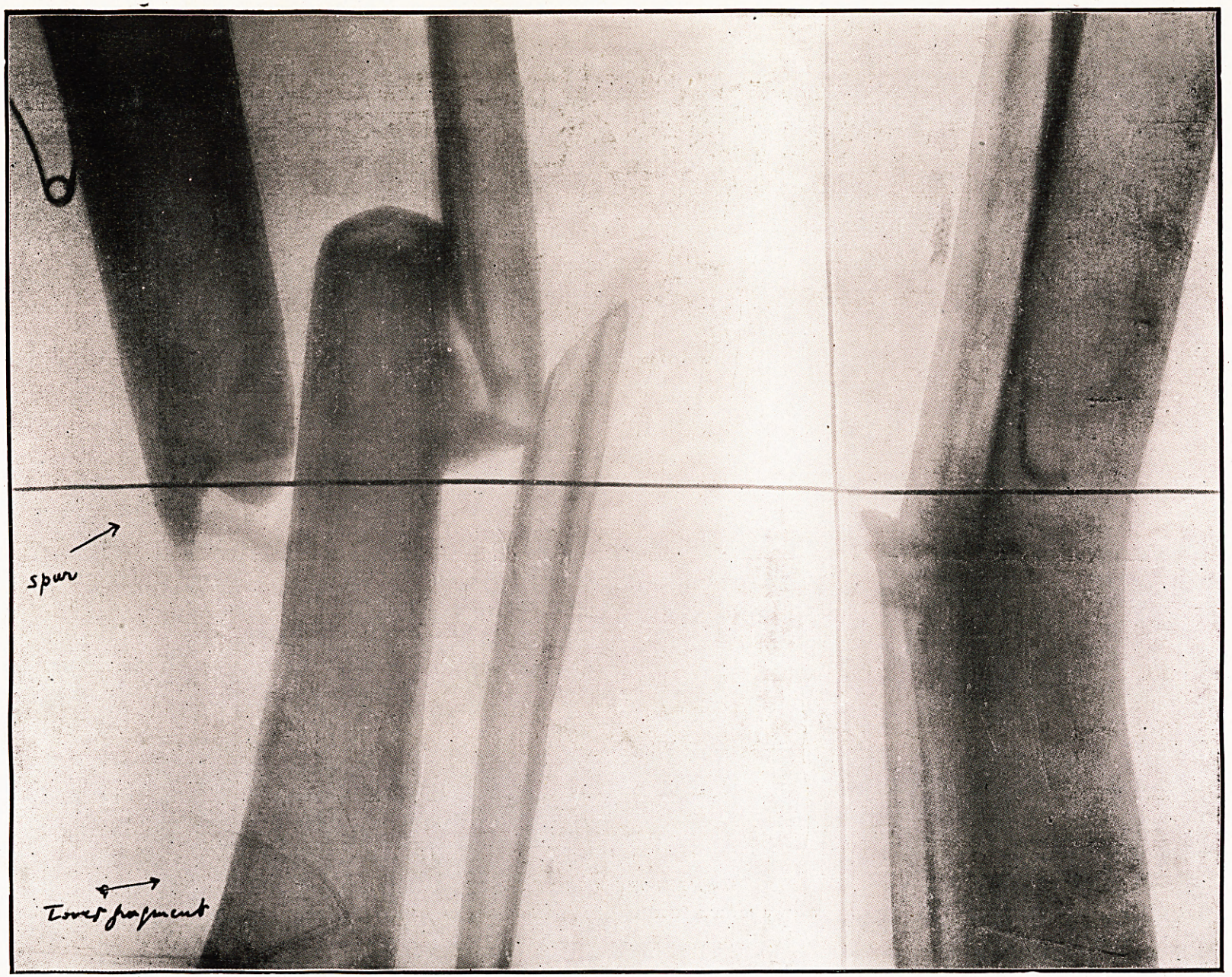

ANT.-POST. LATERAL.

Showing the deformity present before the operation.
The prints are reversed, and so appearing to be L. sided.

PLATE II.

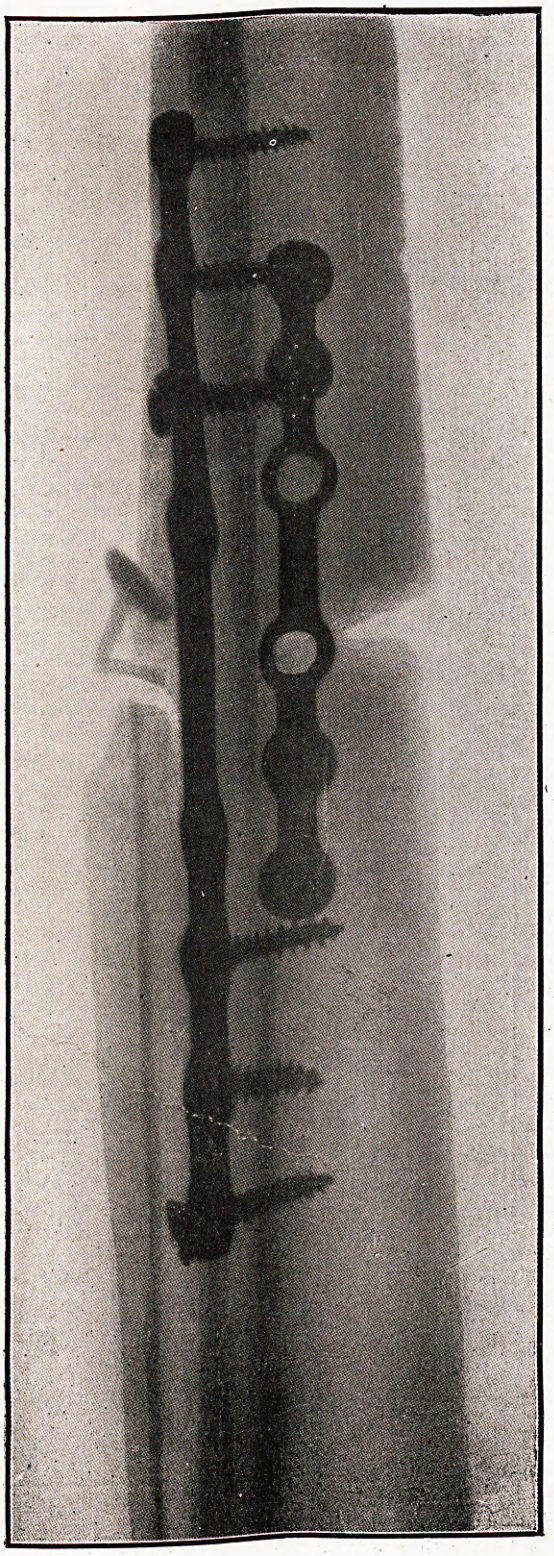

Taken on 17th February, 1919.

PLATE III.

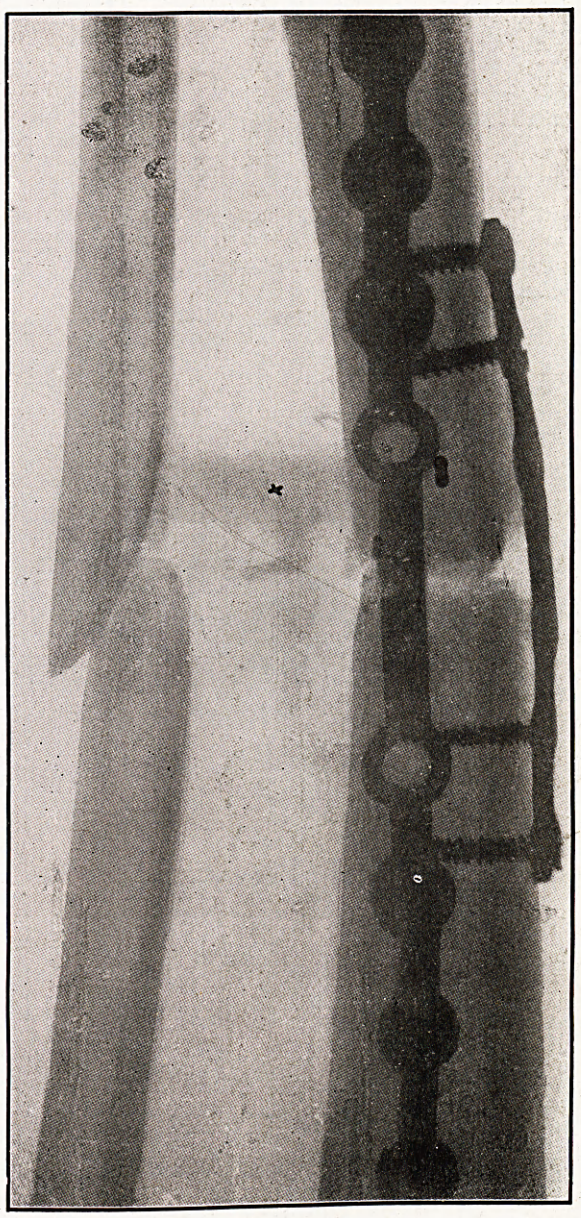

Taken on 5th March, 1919.

New bone formation.

PLATES IV.

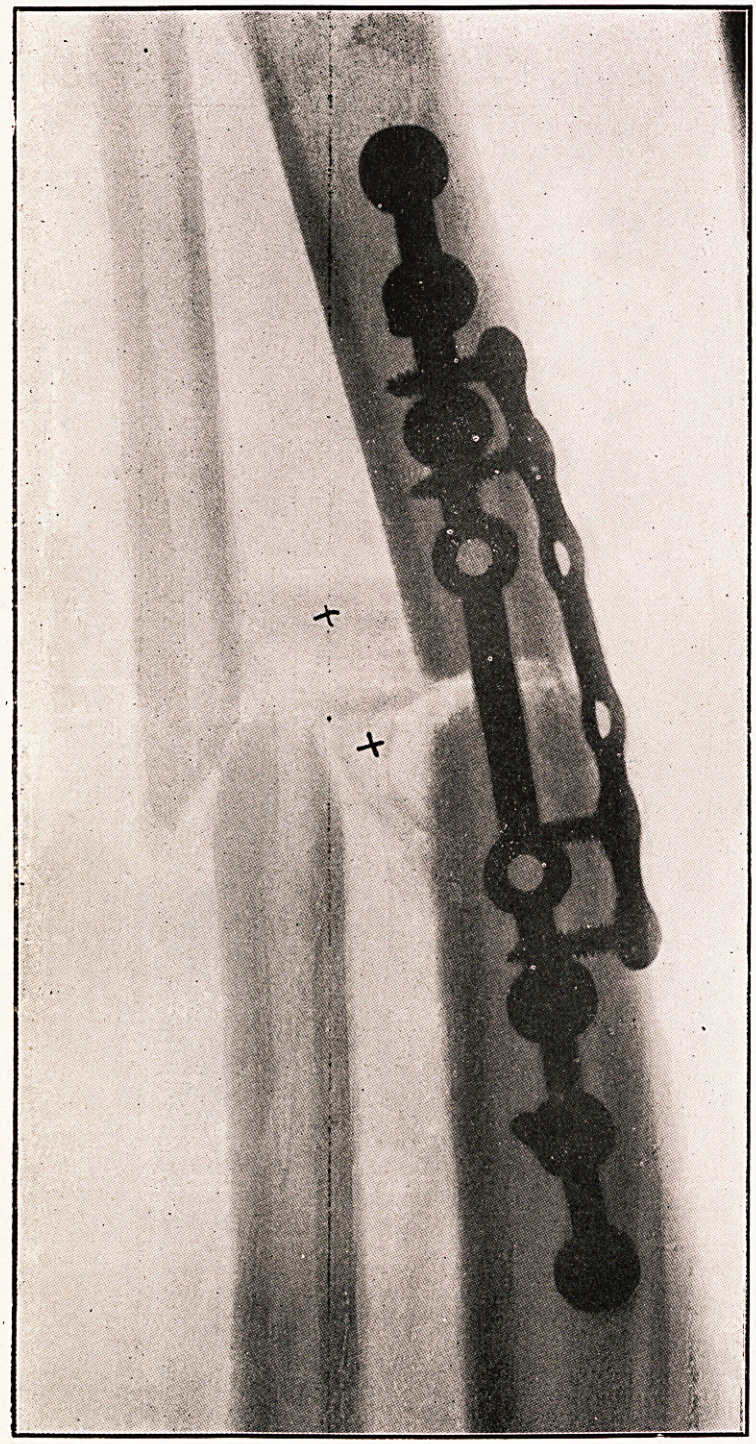

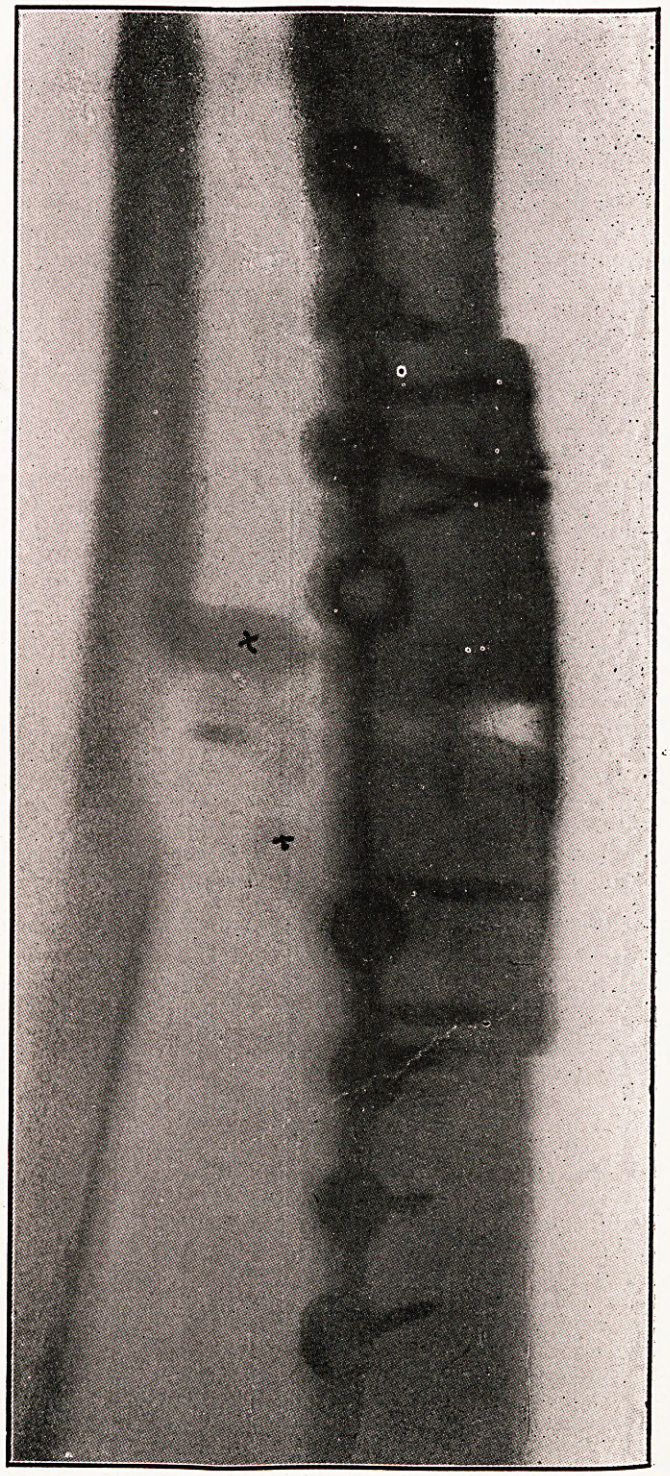

Taken on 25th March, 1919.
Showing position of new bone and ensheathing callus.