Received: 09th September 2014 Accepted: 28th December 2014 Conflicts of Interest: None

Source of Support: Nil

Original Research

Implant Supported Distal Extension over Denture Retained by Two Types of Attachments. A Comparative Radiographic Study by Cone Beam Computed Tomography

Ahmed I Mahrous[1], Hussien A Aldawash[1], Tarek A Soliman[1], Fahad H Banasr[2], Ahmed Abdelwahed[3]

Contributors:

[1]Assistance Professor, Department of Restorative Dentistry, Al Farabi Collages, KSA; [2]Associate Professor, Department of Oral & Maxillofacial Prosthodontics, Faculty of Dentistry KAU, KSA; [3]Lecturer, Department of Removable Prosthodontics, Faculty of Dental Medicine, Future Uni, Egypt.

Correspondence:

Dr. Mahrous AI. Al-Farabi Collages, Haramain Road, P.O Box 21512-Jeddah, Kingdom of Saudi Arabia. Tel: 0545744417-0545494447. Fax: 920009112. Email: drahmedimahrous@gmail.com

How to cite the article:

Mahrous AI, Aldawash HA, Soliman TA, Banasr FH, Abdelwahed A. Implant supported distal extension over denture retained by two types of attachments. A comparative radiographic study by cone beam computed tomography. J Int Oral Health 2015;7(5):5-10.

Abstract:

Background: This study was conducted to compare and evaluate the effect of two different attachments (locator attachment and ball and socket [B&S] attachment) on implants and natural abutments supporting structures, in cases of limited inter-arch spaces in mandibular Kennedy Class I implant supported removable partial over dentures by measuring the bone height changes through the cone beam radiographic technology.

Materials and Methods: Two implants were positioned in the first or second molar area following the two-stage surgical protocol. Two equal groups were divided ten for each: Group I: Sides were the placed implants restored by the locator attachment. Group II: The other sides, implants were restored by B&S attachment. Evaluation of the implants and main abutments supporting structures of each group was done at the time of removable partial over denture insertion, 6, 12 and 18 months by measuring the bone height changes using cone beam computed tomography.

Results: Implants with locator attachment showed marginal bone height better effects on implants and main abutments supporting structures.

Conclusion: Implants restored by locator attachment shows better effects on bone of both main natural abutments and implant than those restored with ball and socket.

Key Words: Implant supported partial over denture, limited inter-arch space, locator attachment

Introduction

Loss of posterior teeth may result in loss of neuromuscular stability of the mandible, reduced masticatory efficiency, loss of vertical dimension of occlusion and attrition of the anterior teeth.[1] Kennedy classified those patients suffering from bilateral missing posterior teeth as Kennedy Class I removable partial dentures, which considered a very special and thought-provoking situation.[2] The main problem associated with bilateral distal extension base removable partial dentures is support. The problem of support is mainly due to the composite nature of supporting structures, which arises from the loss of the posterior abutment and viscoelastic behavior of the mucosa and periodontal ligament.[3]

Due to extraction of teeth due to carious lesions without any periodontal diseases or minimal bone loss,[4] extraction of the lower teeth without proper or delayed restoration of the edentulous area for long time, which usually cause over eruption of the antagonist teeth directly affecting the inter-arch space between the upper and lower arches thus directing the treatment plane to cretin types of attachments to avoid the alteration in the occlusal plane and the vertical dimension of occlusion.[5]

Evaluation of space limitation after implant surgery also allows for the selection of the appropriate attachment.[5,6] Problems such as fractured or over contoured prosthesis may occur because of inappropriate planning. This can result in the need for replacement of the implant over denture attachment, late modification of the treatment plan, or even failure of the definitive prosthesis.[6] Hence that a special group of attachments to fit within the available limited inter-arch space was introduced known as the low profile attachments.[7,8] Low profile attachments are especial type of dental attachments characterized by low or reduced abutment height in the vertical dimension, to accommodate the narrow or limited space between the dental arches.[9-11] The low profile feature enables the technician to utilize more space for an enhanced esthetic denture set-up. The additional space also provides more room for denture acrylic, which will in turn strengthen the denture.[12]

One of the recently applied low profile attachments is the locator attachment. It is a Universal hinge, resilient attachment for end osseous implants or natural root abutments, locator abutment has the smallest vertical profile available.[13] The standard locator male (white nylon liner) will permit up to 10° of divergence for a single implant and 20° between implants.[14] It was found that the relation between the bone resorption around both the dental implant and the used principle abutment is directly affecting the survival and success of the implant supported partial over denture.

Evaluation of the supporting structures and bone height by using the cone-beam computed tomography (CBCT) as it seems to be one of the most advanced and promising resources in this field.[15-17]

Aim of this study

Was to compare and evaluate the effect of two different types of attachments (locator attachment and ball and socket [B&S] attachment) which were used in cases of limited inter-arch space in mandibular Kennedy Class I implant supported removable partial over dentures on the supporting structures through measuring the marginal bone height changes around both implants and main abutments by using the cone beam technology.

Materials and Methods

Twenty partially edentulous patients with Kennedy Class I lower partially edentulous ridges with the first or second premolars were the last standing abutments, remaining teeth had good periodontal condition were selected, with no signs of attrition or gingival recession, the remaining residual ridges had enough bone height and width and covered with firm mucosa, showing no signs of inflammation or ulceration, all patients should have inadequate inter-arch space distance as determined by tentative diagnostic jaw relation records, Age of the patients ranged between 30 and 60 years, the maxillary arch was dentulous or partially edentulous that was restored with a fixed restoration, patients had skeletal Angle's Class I maxillo-mandibular relationship, had good oral hygiene and low caries index, patients having abnormal habits or parafunctional habits as bruxism or clenching were not included in the study, patients were free from temporomandibular joint disorders and also patients having anemia, nutritional deficiency, under chemo or radiotherapy or hormonal disorders as diabetes, thyroid or parathyroid hormonal diseases were not included. Consent forms were signed by all patients selected for this work before the treatment.

The entire selected patient were informed about the procedure and motivated to the treatment. They agreed to co-operate and follow the instruction. After both laboratory investigations and preoperative intra-oral examinations with radiographic evaluation of each case, a diagnostic casts were obtained surveyed and mounted on a semi-adjustable articulator by intra-oral face-bow record and occlusal record for correction of any occlusal disharmonies and evaluation of the occlusal plane and the limitation of the inter-arch space, Several methods were produced to evaluate the amount of available inter-arch space for both partially or completely edentulous patients for better selection of the attachment of the implant supported overdenture.[7] One of those methods is by using a sectioned silicone mold over the area of the anticipated implant position and the selected attachment can be tried – in to fit within the available space.[18]

Another method is by using a graded periodontal probe or ruler to evaluate inters-arch space over a mounted casts on an articulator.[18] We selected to use an endodontic plugger with stopper and a ruler for identifying the limitation in the inter-arch space (Figure 1).

Mouth preparations were carried out and 1:1 magnification pre-surgical panoramic X-ray were done followed by ridge mapping on the diagnostic casts for determination and selection of the implant site, size and diameter. Construction of a transparent acrylic surgical stent was done for instillation of 3.75 mm and 10 mm Pitt Easy V-TPS implant system to be placed at the first-second mandibular molar area of the free end saddle.

After the second stage surgery the placed dental implants were divided and grouped into 2 equal groups according to the attachment for rehabilitation into Group I (locator attachment) and Group II (B&S attachment). The partial over denture metal framework design for all the cases was the same as using RPI as a direct retainer and the lingual bar as a major connector and an auxiliary rest on the second abutment as indirect retention.

Final impression was done using medium body consistency rubber base impression material and master cast was obtained and then duplicated to obtain the refractory cast for metal framework casting, try in was carried out for any occlusal adjustment followed by setting of the artificial cross linked acrylic artificial teeth and denture processing and the removable partial over denture is then finished and polished.

For Group I (locator attachment)

Placement of the locator attachment intraorally over the integrated implant using the locator tool, fixing the locator female housing into the fitting surface of the removable partial over denture was carried out using the pick-up technique and placing and securing the over denture in its position until the acrylic resin is set followed by finishing and polishing of the over denture and placement of the selected nylon cap. Into locator attachment female housing (Figure 2).

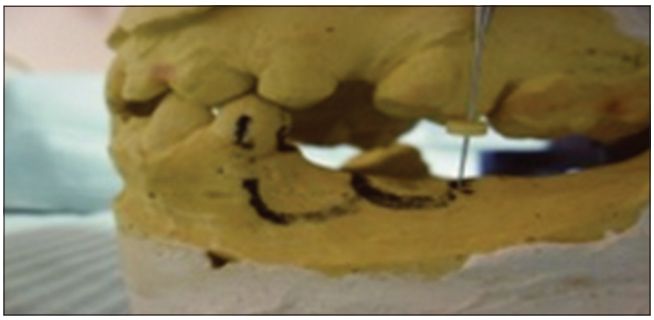

Figure 1: Mounted casts on articulator for identifying the inter-arch space.

For Group II (B&S)

The same procedures were carried out for fixing the attachment female part in the removable partial over denture fitting surface (Figure 3).

The finished removable partial over denture for both groups were inserted and delivered to the patients after occlusal adjustment for radiographic evaluation after 6, 12 and 18 months.

Radiographic evaluation

Evaluation of the marginal bone level around both the implants and the main abutment using the linear measurement system supplied by the -CBCT (K.V.P.85, M.A.16, Field of view 7 cm × 14.5 cm × 14.5 cm) this was done after 6, 12 and 18 months post-insertion.

Image analysis

The marginal bone height around the distal, buccal and lingual surfaces of the anterior natural abutments and the mesial, distal, buccal and lingual surfaces of the posterior implants were evaluated for both groups (locator attachment and B&S attachment), using the linear measurement system of the software (Ondemand 3D) with flat panel detector supplied by the CBCT.

Figure 2: Evaluation of inter arch space after locator attachment placement.

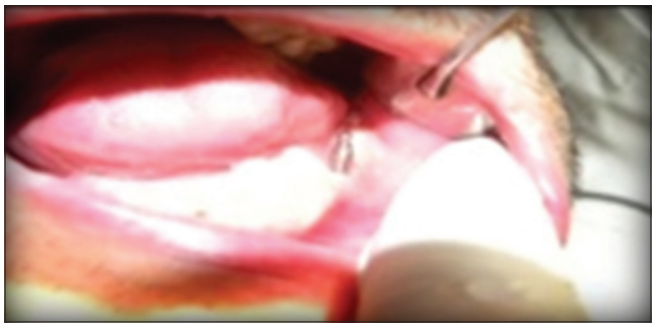

Figure 3: Placed ball and socket attachment male potion intraorally.

From the sagittal plane, distal marginal bone height around natural abutments and mesial and distal marginal bone height around posterior implants could be evaluated. First a line was drawn horizontally tangential to the apex of the tooth and perpendicular to its long axis. Three lines were then drawn tangential to the distal surface of the tooth, parallel to each other and extended from the highest level of the alveolar crest to the horizontal line. The same is done for the frontal plane.

For each plane lengths of three lines was obtained and divided by three to obtain the average of bone height. The procedure was repeated for the lingual surfaces of other abutments and for the implants (Figures 4 and 5).

The measurements were carried out at (6, 12 months and 18 months post insertion). The marginal bone changes at different intervals were obtained by calculating the difference in bone height at that interval from the base line measurement.

Figure 4: Mesial and distal marginal boneheight measurments around implants.

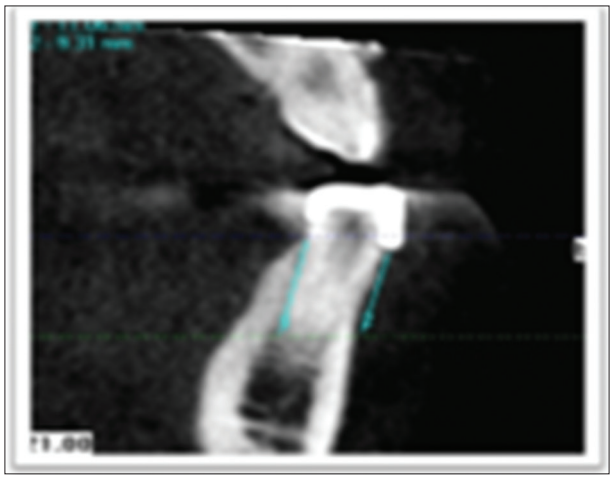

Figure 5: Buccal and lingual marginal bone height measurements around the main abutment.

Statistical analysis

Statistical analysis of the results was done with the analysis of variance followed by Bonferroni multiple comparison test within subgroups for parametric variables. Chi-square test for non-parametric variables were made.

Statistical analysis was performed using software Graphpad prism-4 statistic for windows. $P < 0.05$ are considered to be statistically significant in all tests.

Results

Around implant

Bone height results for both attachment groups around implant at the different intervals of the follow-up period are summarized in Table 1.

Group I (locator) versus Group II (B&S): Comparison of the mean percentage changes of bone loss showed that locator group recorded statistically significant lower bone loss than B&S group at the different intervals of the follow-up period ($P < 0.05$) (Graph 1).

Around the main abutment

locator versus B&S group: Comparison of the mean percentage changes of bone loss showed that locator group recorded statistically significant lower bone loss than B&S group at 12 m and 18 m intervals of the follow-up period ($P < 0.05$) while non-significant after 6 m ($P > 0.05$) (Graph 2).

Table 1: Comparisons of bone height change for both attachment groups around implant from the baseline values at the different intervals of the follow-up period.

Attachment	Variable	6 m-BL	12 m-BL	18 m-BL
Locator	Bone loss	−0.63	−1.062	−1.23
	Mean % change	−6.86649	−11.5749	−13.406
	Paired *t* value	15.6	14.6	16.2
	P value	0.0006*	0.0007*	0.0005*
B&S	Bone loss	−1.225	−2.005	−2.177
	Mean % change	−15.5952	−25.5251	−27.7148
	Paired *t* value	4.9	9.1	10.9
	P value	0.0165*	0.0028*	0.0017*
Locator versus B & S				
Unpaired *t*-test	*t* value	2.3	4.1	4.4
	P value	0.0286*	0.0066*	0.0044*

*Significant ($P<0.05$) ns: Non-significant ($P>0.05$). Statistical analysis of the mean percentage change in bone loss from the baseline value (time of denture insertion) for locator group revealed significant difference at the different intervals of the follow-up period ($P<0.05$)

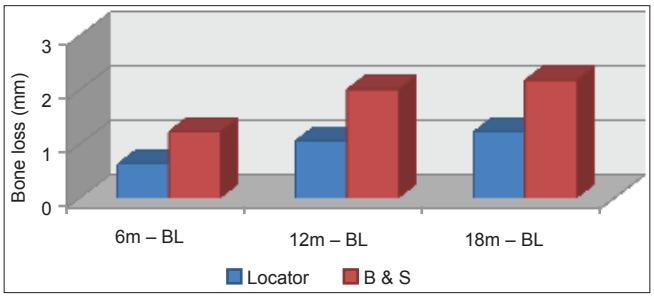

Graph 1: A column chart of the mean values of bone loss in both groups around implant at the different intervals of the follow-up period.

Discussion

Kennedy Class I partially edentulous patients were selected in this study because this category represents the most frequently partially edentulous cases, also most of the problems are present in such cases due to nature of the mucosa that provides different support to the denture and limited denture bearing area for the partial denture.[19]

Determination of the inter-arch limitation was achieved through mounting the upper and lower casts on an articulator.[8] The opposing arch was either dentulous or partially edentulous that was restored with fixed restoration, to standardize the amount of occlusal forces transmitted to the lower arch, since the type of opposing occlusion is among the important factors that influence the magnitude of forces transmitted to the lower arch.

Two distally positioned implants in the area of the first or second molars would effectively transform the Kennedy Class I configuration into a more favorable Kennedy Class III. In this study the dental implants were placed distally in the first or second molar area. Theoretically, the implants should be located as distally as possible to provide maximum support.[20,21]

For Group I the selection of the attachment wad based on the attachment height to fit in the limited inter-arch space between the upper and lower arches. With high resiliency, for better forces distribution over the dental implant and for increasing the support in general for the mandibular removable partial overdenture.[22,23] One of the low profile attachments that can be used in some cases of reduced and limited inter arch space.[24,25,15] For Group II (rehabilitated

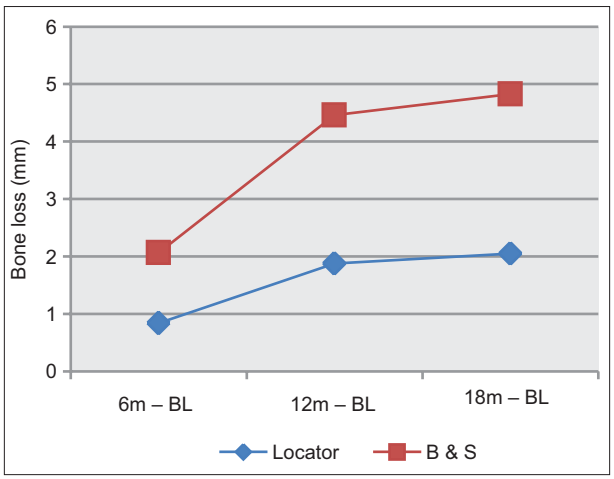

Graph 2: A linear curve of the mean values of bone loss in both groups around abutment at the different intervals of the follow-up period.

with B&S attachment) the selection of the attachment was based on that the B&S attachment is one of the most commonly used dental attachment with implant supported partial over dentures, as the attachment is considered.

Evaluation of the bone height was done by using the CBCT as it seems to be one of the most advanced and promising resources in this field.[16,17,26] CBCT was used in the field of dentomaxillofacial radiology CBCT imaging, CBCT offers a promising alternative approach since it provides sub-millimeter resolution images of high diagnostic quality, with short scanning time and reduced radiation dose up to 15 times lower than multi-slice CT scans (MSCT).[27]

Discussion of Results

Regarding the crestal bone loss around the implant, the results for the two groups showed that a significant amount of bone loss around the implant after 18 months follow up of denture insertion. The amount of peri-implant bone loss agrees with the findings obtained by Albrektsson *et al.*,[28] who proposed criteria for implant survival and success, in which marginal bone level changes in the 1st year should be <1-1.5 mm, and ongoing annual bone loss should be <0.2 mm. Using the Branemark System, Adell *et al.*,[29] reported a bone loss of 1.2 mm for the 1st year in their 15 years study. It was suggested that the initial marginal bone level change occurred as an adaptation of the peri-implant bone to the occlusal load. Numerous studies that had investigated the marginal bone loss that occurs around Branemark implants after the 1st year of service found a range from 0.4 to 1.6 mm. This crestal bone loss may be due to the periosteal reflection, implant osteotomy and the stress factors from bone strain at the implant insertion and stresses applied by the prosthesis.[28-32,25]

Comparison of the mean percentage changes of bone loss around the dental implants showed that Group I (locator attachment) recorded statistically significant lower bone loss than Group II (B&S attachment) at the different intervals of the follow-up period ($P < 0.05$). That was found to be in agreement with a study carried out by Schneider.[22] who recommended the use of locator attachment in implant supported removable partial over dentures as a resilient attachment for better force distribution. Also, this study was in agreement with Chikunov *et al.*[33] in a study showed that the locator attachment is recommended as a resilient attachment and correcting the divergence between the placed dental implants carrying an over denture.

Comparison of the mean percentage changes of bone loss around the main abutments showed that Group I (locator attachment) recorded statistically significant lower bone loss than Group II (B&S attachment) at 12 m and 18 m intervals of the follow-up period ($P < 0.05$) while non-significant after 6 m ($P > 0.05$). This is because that the locator attachment has better force distribution over the edentulous ridge and the main abutments due to its resiliency which is higher than that of the ball & socket attachment and that was in agreement with Kratochvil *et al.*,[34] whom examined three types of attachment, resilient, semi precision and rigid-precision attachments, and they reported that the resilient attachment produced the most force on the edentulous regions and the least force on the abutment teeth. And also was in agreement with the study done by Chikunov *et al.*[33] that showed that the locator attachment has a better effect on the abutment teeth as a resilient attachment than other resilient attachments did.

The result of this study was in agreement with Fu *et al.*[35,36] who reported that dental implants with attachment designs incorporated into removable partial denture can improve denture retention, stability, and support, as they reduces the stresses applied on the abutment teeth and eliminate the need for un-esthetic clasp. And also this was found to be in agreement with Siato *et al.*[37] that showed that using rigid attachments tend to concentrate more stresses at the terminal abutment teeth.

Conclusion

Within the limitation of the results of this study, it could be concluded that: The side of the implant-supported partial over denture restored with the locator attachment showed better effect on bone health around both the placed dental implant and the main natural abutment as compared with the other side of the implant supported partial over denture with the B&S attachment.

References

1. Budtz-Jörgensen E. Restoration of the partially edentulous mouth – A comparison of overdentures, removable partial dentures, fixed partial dentures and implant treatment. J Dent 1996;24(4):237-44.
2. Amin H, Mahmoud M, Mohie-Eldin H. The effect of two titanium and chrome cobalt clasp assemblies on abutment teeth and their supporting structures in distal extension cases. Egypt Dent J 2001;47:843-50.
3. Grasso JE, Miller EL. Removable Partial Prosthodontics, 3rd ed. St. Louis: Mosby; 1991. p. 205-8.
4. Krol AJ. Clasp design for extension-base removable partial dentures. J Prosthet Dent 1973;29(4):408-15.
5. McCartney JW, Thompson GA, Goheen KL. Silicone putty diagnostic casts for edentulous patients wearing complete dentures. J Prosthet Dent 1994;71(2):220-1.
6. Kinderknecht KE, Dominici JT, Clark EP. Preliminary silicone putty casts: Diagnosis to final impression for complete dentures. J Prosthet Dent 1996;75(4):453-6.
7. AbuJamra NF, Stavridakis MM, Miller RB. Evaluation of interarch space for implant restorations in edentulous patients: A laboratory technique. J Prosthodont 2000;9(2):102-5.
8. Pasciuta M, Grossmann Y, Finger IM. A prosthetic solution to restoring the edentulous mandible with limited interarch

space using an implant-tissue-supported overdenture: A clinical report. J Prosthet Dent 2005;93(2):116-20.
9. Jacobs R, van Steenberghe D, Nys M, Naert I. Maxillary bone resorption in patients with mandibular implant-supported overdentures or fixed prostheses. J Prosthet Dent 1993;70(2):135-40.
10. Batenburg RH, Meijer HJ, Raghoebar GM, Vissink A. Treatment concept for mandibular overdentures supported by endosseous implants: A literature review. Int J Oral Maxillofac Implants 1998;13(4):539-45.
11. Staubli P. Attachments and Implants Reference Manual, 6th ed. San Mateo, CA: Attachments International; 1996.
12. Schneider AL, Kurtzman GM. Bar overdentures utilizing the Locator attachment. Gen Dent 2001;49(2):210-4.
13. Mohie-Eldin HA. Load distribution with different superstructure design on osseointegrated implants Ph.D. Thesis Faculty of Oral and Dental Medicine, Cairo Uni.; 1992.
14. Choy E, Reimer D. Laboratory processing of housing-retained attachments for implant-supported overdentures. J Prosthet Dent 2001;85(5):516-8.
15. Mischkowski RA, Pulsfort R, Ritter L, Neugebauer J, Brochhagen HG, Keeve E, *et al*. Geometric accuracy of a newly developed cone-beam device for maxillofacial imaging. Oral Surg Oral Med Oral Pathol Oral Radiol Endod 2007;104(4):551-9.
16. Moreira CR, Sales MA, Lopes PM, Cavalcanti MG. Assessment of linear and angular measurements on three-dimensional cone-beam computed tomographic images. Oral Surg Oral Med Oral Pathol Oral Radiol Endod 2009;108(3):430-6.
17. Kamburoglu K, Kiliç C, Ozen T, Yüksel SP. Measurements of mandibular canal region obtained by cone-beam computed tomography: A cadaveric study. Oral Surg Oral Med Oral Pathol Oral Radiol Endod 2009;107(2):e34-42.
18. Chaimattayompol N, Arbree NS. Assessing the space limitation inside a complete denture for implant attachments. J Prosthet Dent 2003;89(1):82-5.
19. Lammi GA, Laird WR. Osborne and Lammie's Partial Dentures, 5th ed. Oxford, London: Blackwell Scientific Publications; 1986. p. 289.
20. Jacobs R, Schotte A, van Steenberghe D, Quirynen M, Naert I. Posterior jaw bone resorption in osseointegrated implant-supported overdentures. Clin Oral Implants Res 1992;3(2):63-70.
21. Schneider AL. Restoring implants with an overdenture using the Locator Implant Attachment from Zest Anchors, Inc. Dent Prod Rep Tech Guide, 2000.
22. Schneider AL. The use of a self-aligning, low-maintenance overdenture attachment. Dent Today 2000;19(4):24, 26.
23. Preiskel HW. Overdentures Made Easy, London: Quintessence Publishing Co. Ltd.; 1996.
24. Zitzmann NU, Marinello CP. Implant-supported removable overdentures in the edentulous maxilla: Clinical and technical aspects. Int J Prosthodont 1999;12(5):385-90.
25. Lee MW, Baum L, Pence B Sr, Hererra W. O-ring coping attachments for removable partial dentures. J Prosthet Dent 1995;74(3):235-41.
26. Scarfe WC, Farman AG, Sukovic P. Clinical applications of cone-beam computed tomography in dental practice. J Can Dent Assoc 2006;72(1):75-80.
27. Loubele M, Van Assche N, Carpentier K, Maes F, Jacobs R, van Steenberghe D, *et al*. Comparative localized linear accuracy of small-field cone-beam CT and multislice CT for alveolar bone measurements. Oral Surg Oral Med Oral Pathol Oral Radiol Endod 2008;105(4):512-8.
28. Albrektsson T, Zarb G, Worthington P, Eriksson AR. The long-term efficacy of currently used dental implants: A review and proposed criteria of success. Int J Oral Maxillofac Implants 1986;1(1):11-25.
29. Adell R, Lekholm U, Rockler B, Brånemark PI. A 15-year study of osseointegrated implants in the treatment of the edentulous jaw. Int J Oral Surg 1981;10(6):387-416.
30. Goodacre CJ, Kan JY, Rungcharassaeng K. Clinical complications of osseointegrated implants. J Prosthet Dent 1999;81(5):537-52.
31. Oh TJ, Yoon J, Misch CE, Wang HL. The causes of early implant bone loss: Myth or science? J Periodontal 2002;73(3):322-33.
32. Jung YC, Han CH, Lee KW. A 1-year radiographic evaluation of marginal bone around dental implants. Int J Oral Maxillofac Implants 1996;11(6):811-8.
33. Chikunov I, Doan P, Vahidi F. Implant-retained partial overdenture with resilient attachments. J Prosthodont 2008;17(2):141-8.
34. Kratochvil FJ, Thompson WD, Caputo AA. Photoelastic analysis of stress patterns on teeth and bone with attachment retainers for removable partial dentures. J Prosthet Dent 1981;46(1):21-8.
35. Fu MC, Shen YW, Fuh LJ. Clinical application of implant-supported bilateral distal extension removable partial denture. Case report. J Dent Sci 2007;12(2):52-8.
36. Levin L. Dealing with dental implant failures. J Appl Oral Sci 2008;16(3):171-5.
37. Saito M, Miura Y, Notani K, Kawasaki T. Stress distribution of abutments and base displacement with precision attachment- and telescopic crown-retained removable partial dentures. J Oral Rehabil 2003;30(5):482-7.