

# The Mid-term Results of Ventricular Containment (ACORN WRAP) for End-stage Ischemic Cardiomyopathy

Jai S. Raman, MBBS, MMed, FRACS, Mitsumasa Hata, MD, PhD, Meg Storer, BN (Hons), John M. Power, BrSe, PhD, Brian F. Buxton, MB, MS, FRACS, Clif Alferness, BSEE, and David Hare, MBBS, DPM, FRACP

**The Acorn Cardiac Support Device (ACSD) is a device designed to treat heart failure by containing the heart to prevent further dilation. Six patients with symptomatic heart failure due to ischemic cardiomyopathy were treated surgically with the ACSD. All patients simultaneously underwent coronary artery bypass grafting (CABG). Ventricular reconstruction was also performed in 5 of the 6 patients. We followed up the patients for 12 months postoperatively, monitoring the left ventricular ejection fraction (LVEF), left ventricular end-diastolic diameter (LVEDD), left ventricular end-systolic diameter (LVESD), mitral regurgitation, and the New York Heart Association (NYHA) classification. Both the LVEDD and LVESD were significantly improved one month postoperatively (from 63.2 to 50.6 mm,  $p=0.004$ , and from 51.6 to 39.5 mm,  $p=0.025$ , respectively). These dimensions did not change significantly over the next 11 months. The NYHA functional class improved significantly from a mean of 3 to 1.4 at 12 months ( $p=0.012$ ). Mitral regurgitation improved from a mean of 2.7 preoperatively to 1.4 at 12 months and the average LVEF also improved from 27% preoperatively to 35.9% at 12 months after surgery. However these latter two results were not statistically significant. There were no late deaths and no readmissions for heart failure. Repeat coronary angiography at 6 months revealed patent grafts in all patients. The mid-term results of the ACSD for patients with symptomatic heart failure suggest that ventricular containment may be useful for preventing further cardiac dilation in patients with ischemic cardiomyopathy. Randomized, long-term studies are needed to assess the efficacy and possible role of the ACSD in the future management of heart failure. (Ann Thorac Cardiovasc Surg 2001; 7: 278–81)**

**Key words:** heart failure, ventricular containment, ventricular remodeling

## Introduction

Heart transplantation is an accepted therapy for end-stage heart failure in patients in whom medical therapy is not effective in reaching therapeutic goals.<sup>1)</sup> However, it is

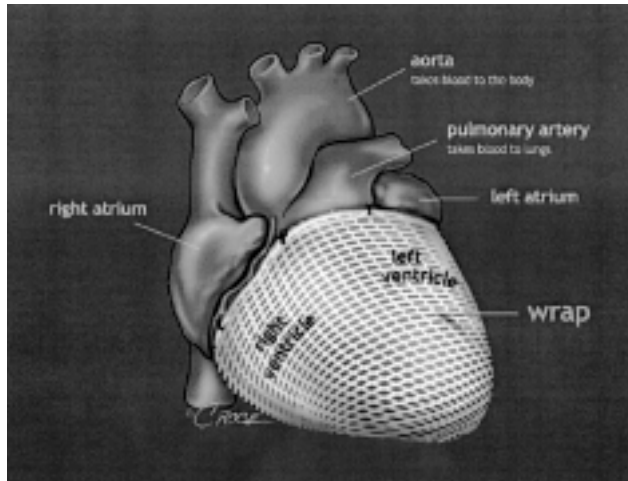
limited by donor organ shortages, selection criteria, cost, and limited prospects for long-term survival.<sup>2)</sup> Recently, some promising results have been reported using left ventricular reduction surgery and endoventricular circular patch plasty for end-stage cardiomyopathy.<sup>3,4)</sup> However, a recent study has shown that many of the patients who undergo left ventricular reduction surgery still eventually require a heart transplant.<sup>5)</sup> We previously reported the efficacy of geometric end-ventricular repair and the early results of using ventricular containment to treat end-stage heart failure.<sup>6,7)</sup> In this article, we report the mid-term results of ventricular containment for symptomatic heart failure due to ischemic cardiomyopathy.

---

*From the Department of Cardiac Surgery, Austin & Repatriation Medical Centre, University of Melbourne, Melbourne, Australia*

Received January 25, 2001; accepted for publication May 23, 2001.

Correspondence to Jai S. Raman, FRACS: Department of Cardiac Surgery, Austin & Repatriation Medical Centre, Austin Campus, Studley Road, Heidelberg, Vic 3084, Australia.



**Fig. 1.** Schematic drawing of Acorn cardiac support device (ACSD).

The ACSD is placed around the ventricles and anchored along the atrioventricular groove posteriorly.

## Patients and Methods

The Acorn cardiac support device (ACSD; Acorn Cardiovascular, St. Paul, MN) is a proprietary device designed to treat heart failure (HF) by constraining the heart to prevent further dilation. It is constructed using a knitted polyester fabric similar to material found in vascular grafts and is designed to optimize circumferential support while minimizing fibrosis.

From July 1999 to October 2000, 6 patients with symptomatic heart failure due to ischemic cardiomyopathy who were undergoing coronary artery bypass grafting (CABG) were also surgically treated with an ACSD. Informed consent was obtained from each patient and the study was approved by the Austin & Repatriation Medical Centre Ethics Committee. The group consisted of 5 males and 1 female with a mean age of  $64.7 \pm 7.1$  years. Five patients had additional ventricular geometric reconstruction of a large myocardial scar, a method which we have reported previously.<sup>6)</sup> Patients were enrolled in this series based on a combination of entry criteria, namely: a left ventricular ejection fraction (LVEF) of less than 35% on radionuclide ventriculogram (RNVG); symptomatic heart failure; left ventricular end-diastolic dimensions (LVEDD) of more than  $30 \text{ mm/m}^2$  body surface area; and coronary artery disease amenable to CABG. Patients that required emergent or urgent surgical intervention were excluded. Other exclusions were repeat operations, major malignancy, or significant renal impair-

ment with a serum creatinine concentration of greater than  $160 \text{ mmol/L}$ .

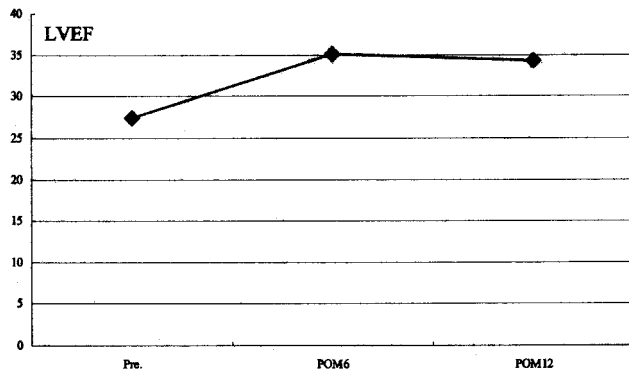
Before the patient was connected to cardiopulmonary bypass (CPB), the circumference of the base of the ventricles was measured along with the apex to base length. The ACSD comes in 5 sizes and the size of the mesh is elected based on the pre-CPB measurement. Any large aneurismal or akinetic left ventricular scar was then excised and the underlying ventricle reconstructed using the geometric endoventricular repair technique. The ACSD was then selected, placed around the ventricles and anchored along the atrioventricular groove posteriorly (Fig. 1). Both ante and retrograde warm blood cardioplegia were concomitantly employed for myocardial protection. The distal anastomoses were then constructed with small windows created in the mesh to allow suturing. The edges of the windows were sutured down to the epicardium to prevent encroachment of the anastomoses or grafts. The cross-clamp was removed and the patient weaned off CPB. At this stage, with the filling pressures similar to those before CPB, excess mesh was excised anteriorly from apex to base. The cut edges of the mesh were then approximated with 4-0 polypropylene sutures in such a way that the ACSD covered the ventricles in a snug fashion. Implantation and tailoring of the mesh took approximately 25 minutes.

We followed up the patients for 1, 6, and 12 months postoperatively, monitoring the LVEF with RNVG, LVEDD, left ventricular end-systolic diameter (LVESD), mitral regurgitation (MR) with echocardiography, and the New York Heart Association (NYHA) classification. Coronary angiography was carried out 6 months after the operation.

Statistical analysis was made by ANOVA using Scheffe's method. Significance was defined as a *p* value of less than 0.05. The Mann-Whitney U test was also used to compare abnormally distributed data.

## Results

The average number of grafts was  $3.5 \pm 1.0$  with a range of 2 to 5. There were no early deaths. One patient had a septic episode postoperatively and another had their sternum re-explored on the ninth postoperative day for a suspected wound infection. One patient required intra aortic balloon pumping for 2 days postoperatively. There were no late deaths and no readmissions for heart failure. The average LVEF improved from 27% preoperatively to 35.9% at 12 months postoperatively. However,



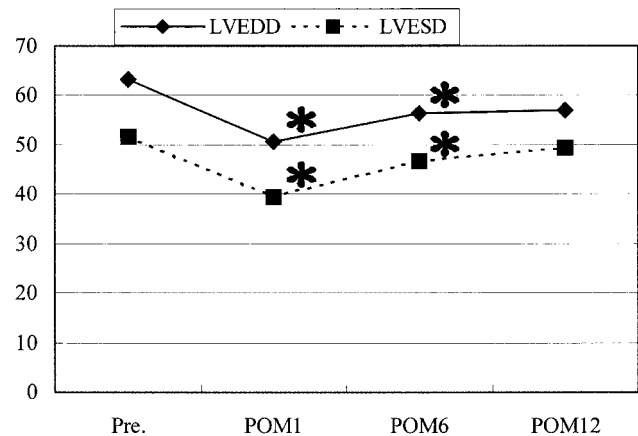
**Fig. 2.** Left ventricular ejection fraction (LVEF; %).

Average LVEF was improved from 27% preoperatively to 34.3% in postoperative 12 months. No significant difference. POM6: 6 months postoperatively, POM12: 12 months postoperatively.

this was not statistically significant (Fig. 2). Both the LVEDD and LVESD were significantly improved 1 month after surgery (from 63.2 to 50.6 mm,  $p=0.004$ , and from 51.6 to 39.5 mm,  $p=0.025$ , respectively). However, there was no further improvement over the next 11 months (Fig. 3). The MR also improved from a mean of 2.7 preoperatively to 1.4 at 12 months postoperatively. However, this was not statistically significant. All patients were in the NYHA class I or II at the time of review (the mean duration of follow-up was 465 days with a range from 60 to 605 days). The NYHA status significantly improved from 3.2 to 1.4 in 12 months ( $p=0.012$ ). Repeat coronary angiography at 6 months revealed patent grafts in all patients.

## Discussion

In spite of a symptomatic improvement, progression of heart failure has been demonstrated in trials among patients receiving the best currently available drug therapy.<sup>1)</sup> ACSD is a newly developed device to avoid the deleterious effects of heart failure, in particular the phenomenon of ventricular remodeling. Ventricular containment with a modified polyester mesh was first performed as an adjunct to CABG on the 21st April 1999, on a patient with symptomatic heart failure due to ischemic heart disease.<sup>7)</sup> The ventricular containment device is intended to limit the dilation of the heart that occurs with heart failure. It may also reduce MR resulting from dilation of the left ventricle. In this series, the etiology of MR was presumably from mild dilatation of the cardiac base and hence the mitral annulus. There was no instance of severe MR.



**Fig. 3.** Left ventricular end-diastolic (LVEDD; mm) and end-systolic dimension (LVESD; mm).

Both of them were significantly improved postoperatively at 1 month. Since then, they have not changed for postoperative 12 months. POM1: 1 month postoperatively.

No specific mitral valve intervention was performed. The MR presumably decreased partly due to stabilization of the cardiac base. The ACSD is a permanent implant that has been successful in preventing the continual dilation of the left ventricle in two heart failure animal models.<sup>8)</sup> Pervaiz and colleagues<sup>9)</sup> also reported in an animal model that the ACSD showed the effects of ameliorating myocyte hypertrophy and attenuating interstitial fibrosis. In our patients, LVEF, measured by a gated blood pool scan using RNVG, improved from 27.0% preoperatively to 35.9% 12 months postoperatively, but did not reach statistical significance because of the small number of patients. However, both LVEDD and LVESD were significantly decreased in the early postoperative phase and these effects were maintained in the 12 months after surgery. Patients' symptoms were also significantly improved in terms of the NYHA functional class. The ventricular containment seemed to prevent the development of ventricular remodeling in the medium term.

Recent studies have suggested that increased left ventricular size is a risk factor for perioperative mortality in patients with low LVEF undergoing bypass surgery.<sup>10)</sup> We previously presented a new method of geometric left ventricular reconstruction as representing a more physiologically effective repair.<sup>6)</sup> Suma and colleagues also reported that surgical restoration produced a better outcome than CABG alone.<sup>4)</sup> The goal of left ventricular reconstruction is to reshape and reorganize the ventricle, while reducing the volume. However, the long-term results of this technique are not yet known. Another im-

portant problem is the return of intractable heart failure due to progressive dilatation. Though the reduced ventricular geometric dimensions may be sustained for up to 12 months, pump function begins to deteriorate after 6 months. The discrepancy between geometry and sustainability of mechanical function is attributed to the fact that mass reduction causes changes in diastolic compliance.<sup>11)</sup> In our patients, the echoes were reviewed and reported by the core lab at Mayo Clinic with no evidence of diastolic dysfunction or pericardial constriction. From a therapeutic standpoint, then, the surgical procedure targeted to inhibiting or reversing some aspects of this remodeling process of heart failure appears to be a particularly attractive one. We consider that the goal of the surgical reversal of remodeling is to reshape the LV from a globular to an elliptical shape without critically reducing the cavity volume and allowing further dilation. In this respect, ventricular containment with a customized polyester mesh such as that represented by the ACSD seems like a logical surgical approach to heart failure.

## Conclusions

The mid-term results of ventricular containment with a customized polyester cardiac support device for patients with symptomatic heart failure are promising. This device may be useful in preventing the further development of ventricular remodeling in ischemic cardiomyopathy. However, randomized, long-term studies are needed to further assess the efficacy of ventricular containment and to define its possible future role in the surgical management of heart failure.

## References

1. Bocchi EA, Bellotti G, Moreira LF, et al. Mid-term results of heart transplantation, cardiomyoplasty, and medical treatment of refractory heart failure caused by idiopathic dilated cardiomyopathy. *J Heart Lung Transplant* 1996; **15**: 736–45.
2. Hosenpud JD, Bennett LE, Keck BM, Fiol B, Boucek MM, Novick RJ. The registry of the international society for heart and lung transplantation: fifteenth official report—1998. *J Heart Lung Transplant* 1998; **17**: 656–68.
3. Konertz W, Khoynzhad A, Sidiropoulos A, Borak V, Baumann G. Early and intermediate results of left ventricular reduction surgery. *Eur J Cardiothorac Surg* 1999; **15** (suppl 1): 26–30.
4. Suma H, Isomura T, Horii T, et al. Nontransplant cardiac surgery for end-stage cardiomyopathy. *J Thorac Cardiovasc Surg* 2000; **119**: 1233–44.
5. Etoch SW, Koenig SC, Laureano MA, et al. Results after partial left ventriculectomy versus heart transplantation for idiopathic cardiomyopathy. *J Thorac Cardiovasc Surg* 1999; **117**: 952–9.
6. Raman JS, Sakaguchi G, Buxton BF. Outcome of geometric endoventricular repair in impaired left ventricular function. *Ann Thorac Surg* 2000; **70**: 1127–9.
7. Raman JS, Power JM, Buxton BF, Alferness C, Hare D. Ventricular containment as an adjunctive procedure in ischemic cardiomyopathy: early results. *Ann Thorac Surg* 2000; **70**: 1124–6.
8. Power JM, Raman J, Dornom A, et al. Passive ventricular constraint amends the course of heart failure: a study in an ovine model of dilated cardiomyopathy. *Cardiovasc Res* 1999; **44**: 549–55.
9. Pervaiz AC, Mishima T, Sharov VG, et al. Passive epicardial containment prevents ventricular remodeling in heart failure. *Ann Thorac Surg* 2000; **70**: 1275–80.
10. Kawachi K, Kitamura S, Hasegawa J, et al. Increased risk of coronary artery bypass grafting for left ventricular dysfunction with dilated left ventricle. *J Cardiovasc Surg* 1997; **38**: 501–5.
11. Westaby S. Non-transplant surgery for heart failure. *Heart* 2000; **83**: 603–10.