NOTE *Anatomy*

Histological Analysis of Ovine Compact Bone Tissue

Monika MARTINIAKOVÁ[1)], Birgit GROSSKOPF[2)], Radoslav OMELKA[3)], Mária VONDRÁKOVÁ[1)] and Mária BAUEROVÁ[3)]

[1)]*Departments of Zoology and Anthropology and* [3)]*Botany and Genetics, Constantine The Philosopher University, 949 74 Nitra, Slovak Republic and* [2)]*Institute of Zoology and Anthropology, Georg-August University, 37–073 Göttingen, Germany*

(Received 12 July 2006/Accepted 17 November 2006)

ABSTRACT. Histological sections of femoral diaphysis from adult sheep were investigated in this study. The qualitative characteristics in microstructure of the compact bone were examined in anterior, posterior, medial and lateral views; the quantitative ones were assessed using the software Scion Image. Areas, perimeters, minimum and maximum diameters of the Haversian canals, the Haversian systems and the primary osteons' vascular canals were measured. Our results indicate that ovine diaphysis of the *femur* is occupied mainly with primary vascular plexiform (laminar, fibrolamellar) tissue. In addition, irregular and dense Haversian bone tissues were observed. All measured variables disposed lower values in comparison with other artiodactyls (cattle and pig).

KEY WORDS: compact bone, histomorphometry, sheep.

J. Vet. Med. Sci. 69(4): 409–411, 2007

It is generally accepted that plexiform (laminar, fibrolamellar) bone tissue is the most prevalent bone structure in artiodactyls. It has been reported in *Canis* (dog), *Ovis* (sheep), *Sus* (pig), *Bison* (buffalo), and *Bos* (cattle), and also in fossil bones including *Pharahippus blackburgi* (primitive horse), *Kannemeyeria* (herbivorous mammal-like reptiles), and *Brachiosaurus* and *Plateosaurus* (extinct herbivorous dinosaurs) [4, 10]. This tissue is also considered to be an important indicator of non-human bone. According to Mulhern and Ubelaker [11], other bone tissue types are more difficult to distinguish between human and animal bones. In our previous study [9] femoral bone microstructure of cows and pigs were analysed. Using histomorphometric characteristics of the compact bone tissue we found differences sufficient for determination of animals studied. In general, the smallest differences in these characteristics are observed in species from uniform animal order. Therefore, the aim of this study was to present a detailed analysis of the femoral bone microstructure in adult sheep with an emphasis to successful identify this species from artiodactyls mentioned above.

Femoral midshaft sections from four clinically healthy female sheep (Merino breed), 12–15 months of age at death, were analysed. The animals were obtained from an experimental farm of the Slovak Agricultural Research Authority in Nitra (Slovakia). They were kept under standard conditions. None of the animals was pregnant or in a lactation stage. In total, 8 transversal sections of the *femur* diaphysis were cut. The obtained segments were macerated and degreased [8]. Later the samples were embedded in epoxy resin Biodur [5]. Histological sections (80–100 μm) were prepared with a sawing microtome (Leitz 1600) and mounted on glass slides with Eukitt (Merck). The qualitative characteristics of analysed microstructure were determined according to the classification systems by Enlow and Brown [3] and Ricqlès *et al.* [14] in anterior, posterior, medial and lateral views of the sections, the quantitative ones were assessed using the specific computer software Scion Image (Scion Corporation, U.S.A.). The following variables were measured: area, perimeter, and the minimum and maximum diameter of 100 Haversian canals, 100 Haversian systems and 160 vascular canals of primary osteons. Measurements were taken on all mature osteons, which were not in a resorption phase and which could clearly be outlined, using the software Scion Image.

According to our results ovine diaphysis of the *femur* was occupied mainly with primary vascular plexiform bone tissue (Fig. 1). This type of bone tissue, localized especially at bone surfaces, consists of primary vascular canals organized into a regular, well defined plexus. In addition, dense Haversian bone tissue with a dense concentration of secondary osteons was identified in the middle parts of *substantia compacta*, especially in medial and lateral sides (Fig. 2). In antero-lateral sides, irregular Haversian bone tissue with scattered, isolated, and relatively few Haversian systems

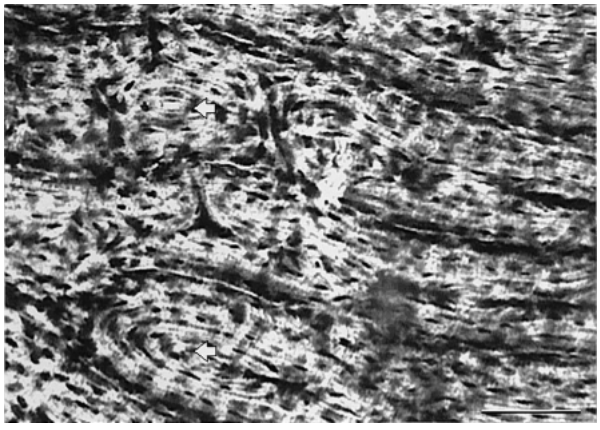

Fig. 1. Primary vascular plexiform bone tissue at the endosteal border (lateral view). Arrow: primary vascular canal. Bar=100 μm.

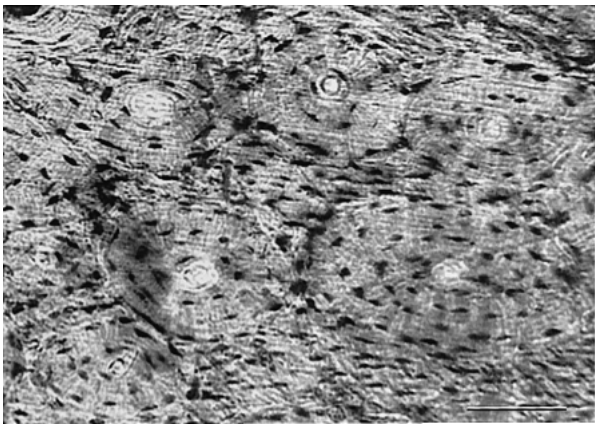

Fig. 2. Dense Haversian bone tissue in the middle part of *substantia compacta* (medial view). Bar=100 μm.



Fig. 3. Irregular Haversian bone tissue at the periosteal border (antero-lateral view). Bar=100 μm.

(Fig. 3) was observed. Periosteal border (except for antero-lateral sides where irregular Haversian tissue outstays) was created by primary vascular plexiform bone tissue with scattered secondary osteons. Finally, 100 Haversian canals, 100 Haversian systems and 160 primary osteons' vascular canals were measured. The results are shown in Table 1.

Histological analysis showed that the sections had mixed microstructure, with plexiform bone towards surfaces of the specimens and Haversian bone mostly in the centre. These results correspond with Enlow and Brown's [4], Mulhern and Ubelaker's [11], Currey's [8], Locke's [7] and Mori's *et al.* [10] studies. However, a presence of irregular Haversian bone tissue was mentioned in antero-lateral sides only in our study. According to Newman *et al.* [13] Haversian remodeling takes place in bones of adult sheep notably in the diaphysis of the *radius*. Therefore, irregular Haversian tissue could be found in our *femora*. In cows and pigs, this type of bone tissue was not identified in the sides mentioned above [9]. For this aim, finding of irregular Haversian tissue in the antero-lateral sides could means that the bone comes from sheep.

The measured value of mean diameter of ovine Haversian canals (counted in arithmetic mean of their minimum and maximum diameter) was lower than the one reported by Müller and Demarez [12]. However, the authors did not mention which bone was investigated in their study. Comparing values of all measured Haversian canals' and Haversian systems' variables with the ones found by Urbanová and Novotný [15] indicated that area, maximum diameter of the canals were higher in our study. These authors used for measurement *femur* and also *tibia* bones. Therefore, similar discrepancies with the latter work were observed. We also compared our results with those from Dittmann's [2] study. We found measured variables of the Haversian canals and the Haversian systems were higher in our study (except for mimimum diameter). That author, however, analysed histological sections from proximal *metacarpi* or *radii*. Finally, all measured variables (including primary osteons' vascular canals) disposed lower values in comparison with other artiodactyls which were investigated in previous study [9]. On the basis of these findings, it is possible to distinguish sheep's femora from those of cow's and pig's.

In general, the measured values of basic structural units in compact bone tissue change with the age of the individual and vary with the skeletal part studied. On the other hand, these values are relatively constant between adult individuals of the same species for the same skeletal element [8]. Therefore, femoral bone microstructure of adult animals was analysed and/or compared in our study. Also, it is known that very active bone resorption occurs in late gestation and early lactation in goats and sheep. This causes changes in histomorphometric parameters of the bone [6]. For this aim, such animals were excluded from our experiments.

In conclusion, the number of bone samples investigated in the study was limited. Further research in this direction will need to extend the number of analysed skeletal elements and to verify the results that were obtained from our samples at successive ontogenetic stages of animals studied. It is a subject of current research. The results of our work

Table 1. Results of quantitative histological analysis in sheep

Measured structures	Area (μm^2)	Perimeter (μm)	Max. diameter (μm)	Min. diameter (μm)
Haversian canals	618.78 ± 255.21	69.88 ± 15.06	33.62 ± 8.97	11.60 ± 3.36
Haversian systems	21553.67 ± 8360.50	424.11 ± 95.22	207.94 ± 69.37	66.57 ± 17.49
Primary osteons' vascular canals	224.06 ± 95.58	43.36 ± 9.91	21.66 ± 6.35	6.64 ± 2.27

could be applied especially in archaeozoology for taxonomic identification of the selected species of adult artiodactyls from heavily degraded and/or cremated bone remnants where genetic information (DNA) is not sufficiently present.

ACKNOWLEDGMENT. This study was supported by the grant CGA VI/6/2004 (Constantine the Philosopher University in Nitra, Slovak Republic).

REFERENCES

1. Currey, J. D. 2002: Bones: Structure and Mechanics, 1st ed., Princeton University Press, New Jersey.
2. Dittmann, K. 2003. *Anthrop. Anz.* **61**: 175–188.
3. Enlow, D. H. and Brown, S. O. 1956. *Texas J. Sci.* **8**: 405–412.
4. Enlow, D. H. and Brown, S. O. 1958. *Texas J. Sci.* **10**: 187–230.
5. Herrmann, B., Grupe, G., Hummel, S., Piepenbrink, H. and Schutkowski, H. 1990. Prähistorische Anthropologie. Leitfaden der Feld- und Labormethoden, 1st ed., Springer Verlag, Heidelberg.
6. Liesegang, A., Risteli, J. and Wanner, M. 2006. *Bone* **38**: 794–802.
7. Locke, M. 2004. *J. Morphol.* **262**: 546–565.
8. Martiniaková, M., Omelka, R., Chrenek, P., Vondráková, M. and Bauerovš, M. 2005. *Bull. Vet. Inst. Pulawy* **49**: 227–230.
9. Martiniaková, M., Grosskopf, B., Vondráková, M., Omelka, R. and Fabiš, M. 2006. *Anat. Histol. Embryol.* **35**: 167–170.
10. Mori, R., Kodata, T., Soeta, S., Sato, J., Kakino, J., Hamato, S., Takaki, H. and Naito, Y. 2005. *J. Vet. Med. Sci.* **67**: 1223–1229.
11. Mulhern, D. M. and Ubelaker, D. H. 2001. *J. Forens. Sci. 46*: 220–222.
12. Müller, M. and Demarez, R. 1934. *Med. Leg.* **14**: 498–560.
13. Newman, E., Turner, A. S. and Wark, J. D. 1995. *Bone* **16**: 277–284.
14. Ricqlès, A. J. de, Meunier, F. J., Castanet, J. and Francillon-Vieillot, H. 1991. pp. 1–78. *In*: Bone 3, Bone Matrix and Bone Specific Products, 1st ed. (Hall B. K. ed.), CRC Press, Boca Raton.
15. Urbanová, P. and Novotný, V. 2005. *Anthropologie* **43**: 77–85.