NOTE *Anatomy*

Polymelia with Two Extra Forelimbs at the Right Scapular Region in a Male Korean Native Calf

Chong-sup KIM[1)], Seong-chan YEON[1)], Gyu-hyen CHO[1)], Joung-hwan LEE[2)], Min-cheol CHOI[3)], Chung-gil WON[4)], Jin-gu KIM[1)] and Sang-rae LEE[5)]

[1)]Institute of Animal Medicine, College of Veterinary Medicine, Gyeongsang National University, 900, Gazwa-Dong, Chinju, [2)]College of Veterinary Medicine, Chonnam National University, [3)]College of Veterinary Medicine, Seoul National University, [4)]Department of Pharmacology, College of Medicine, Korea University and [5)]Experimental Animal Center, College of Medicine, Hallym University, Korea

(Received 1 February 2001/Accepted 1 July 2001)

ABSTRACT. In a male Korean native calf 14 days of age, polymelia (notomelia) was observed macroscopically and radiographically. External features included two normal forelimbs, two normal hindlimbs and two undeveloped extra forelimbs. The extra forelimbs were attached to the caudal regions of the right scapula and devoid of muscular tissues. In the extra forelimbs, a scapula-like bone formed a joint with the incompletely duplicated humerus. The humerus fused with the incompletely duplicated radius. The ulna, carpal bones, metacarpal bones and phalanges were completely duplicated. But one set of the duplicated carpal bones consisted of five bones: radial, accessory, fourth carpal, fused second and third carpal, and fused ulnar and intermediate carpal bones. The hoof and the rudimentary hoof of accessory digit were duplicated.

KEY WORDS: extra forelimb, Korean native calf, polymelia.

J. Vet. Med. Sci. 63(10): 1161–1164, 2001

Polymelia of symmetrical twins in cattle displays the presence of six [2, 10] or eight [1] legs according to the degree of their attachment. Heterotopic polymelia has one or two supernumerary legs attached to the various body region and is classified as notomelia, cephalomelia, thoracomelia and pygomelia [11].

Leipold and Denis [10] reported cases of *Dicephalus dipus dibrachius* and *Dicephalus tetrapus tribrachius*. Hiraga *et al.* [4, 5] reported a calf with seven legs and five cases of heterotopic polymelia among the 223 calves with congenital abnormalities. Ueshima and Uehara [14] reported a calf with ulnar dimelia.

Seo *et al.*[13] reported a Korean native calf with five legs, and Kim *et al.* [6–9] reported five legs and two tails in a Holstein calf, polymelia attached to thoracic region, notomelia with polydactyly, and polymelia with two extra forelimbs at the region of the neck in Korean native calves.

This article aims to describe a Korean native male calf with extra forelimbs attached to the caudal region of the right scapula.

A 14-day-old Korean native male calf with extra forelimbs was observed by physical and radiographic examination, and the abnormal limb was dissected thereafter. Macroscopic examinations were conducted with skeletal preparation.

The male calf, born at the Kyeong Nam, Sachon, was sent to our department as an object of study. It showed heterotopic polymelia and notomelia. The appearance of the calf was normal except underdeveloped, abnormally malformed two extra forelimbs. The extra forelimbs were attached to the spine of the right scapula of normal right forelimb (Figs. 1, 6, and 7). The skin of the extra forelim developed well, and the hoof and rudimentary hoof of the accessory digits were duplicated. But, the extra forelimbs were devoid of muscle tissues (Fig. 2) and suspended downward. The humerus and antebrachial skeleton, carpus, metacarpus and digits were arranged as V-shape, so that the palmar surface was turned upward (Figs. 1 and 2).

The distal extremity of the humerus and the head of the radius were duplicated incompletely, and fused. The ulna was completely duplicated (Figs. 3 and 4).

The carpal bones of the extra forelimbs were duplicated, but one set of the duplicated carpal bones consisted of five bones: radial, accessory, fourth carpal, fused second and third carpal, and fused ulnar and intermediate carpal bones (Fig. 5).

The metacarpal bones were completely duplicated. The phalanges were completely duplicated and consisted of the proximal, middle, and distal phalanx. The hoof and rudimentary hoof of the accessory digit were duplicated (Figs. 1, 2 and 5).

Polymelia of symmetrical twins in cattle refers to the presence of six [2, 10] or eight [1] legs according to their attachment. Heterotopic polymelia refers to the presence of one or two more legs which can be attached to various regions of the body, and classified according to the area of attachment as notomelia, cephalomelia, or thoracomelia [6].

Abe *et al.* [1] reported a calf with extra limbs attached to the underdeveloped pelvic area and nominated them as Dipygus parasiticus because of their coxal bone-like appearance. Leipold *et al.* [11] reported the six legs of a calf with extra limbs. Among them, four were normal and two were accessory hind legs, and attached to the normal pelvic area. Wacker and Glasser [15] reported a case of dipygus including two heads, three forelimbs, and four hindlimbs. Hiraga *et al.* [4, 5] reported dipygus in a calf extra seven forelimbs attached to the pelvic area.

Ueshima and Uehara [14] reported the ulnar dimelia in a

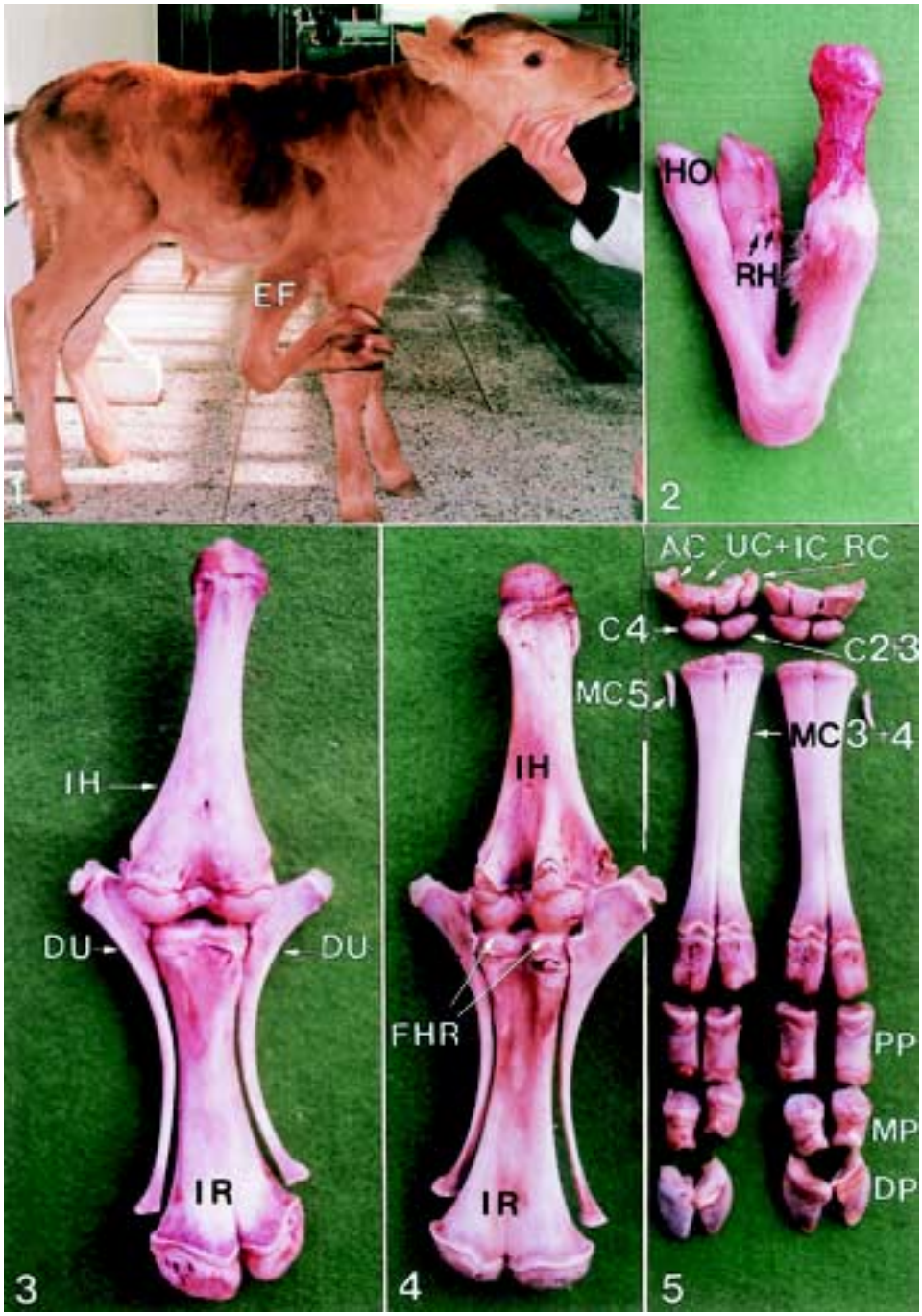

Fig. 1. Polymelia with two extra forelimbs at the caudal region of the normal right scapula. EF: extra forelimbs

Fig. 2. Extra forelimbs. The hoof and rudimentary hoof of accessory digit were duplicated. HO: hoof, RH: rudimentary hoof of accessory digit (dewclaw)

Fig. 3. Incompletely duplicated humerus and radius are fused with each other. The ulna is completely duplicated; anterior view. IR: incompletely duplicated radius, IH: incompletely duplicated humerus, DU: duplicated ulnae

Fig. 4. Posterior view of Fig. 3. FHR: parts of fused humerus and radius.

Fig. 5. The carpal bones, metacarpal bones and phalanges were duplicated completely; anterior view. RC: radial carpal bone, PP: proximal phalanx, MP: middle phalanx, DP: distal phalanx, AC: accessory carpal bone, C4: fourth carpal bone, MC5: fifth metacarpal bone, MC3+4: fused third and fourth metacarpal bone, UC+IC: ulnar and intermediate carpal bone, C2+C3: second and third carpal bone.

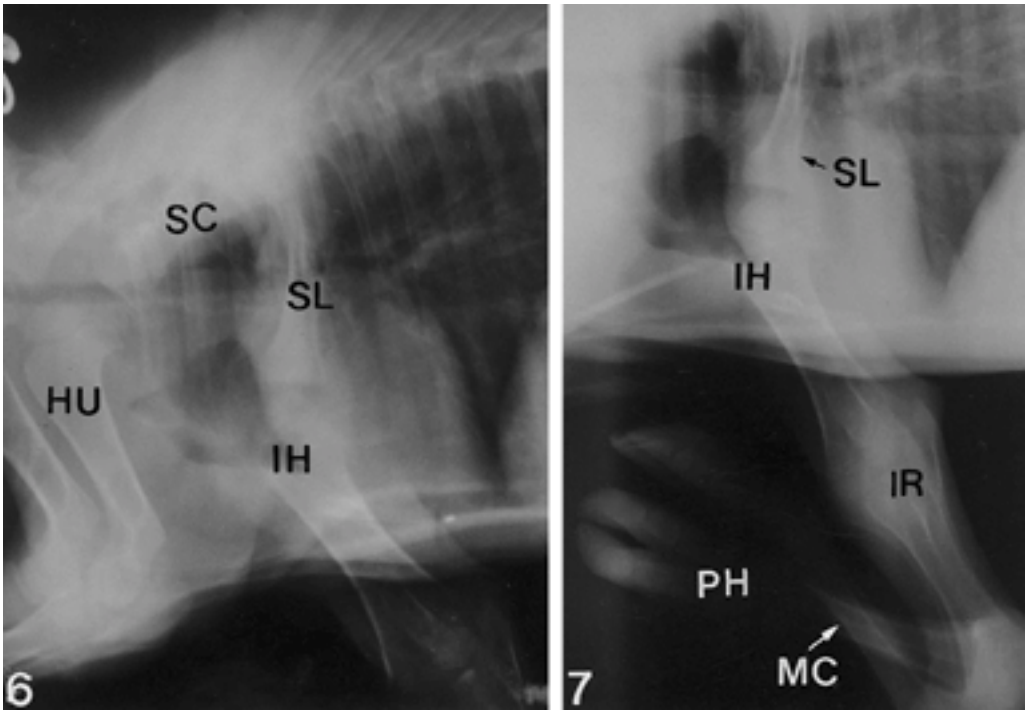

Figs. 6, 7. Radiographs of normal and extra forelimbs. HU: normal right humerus, SC: normal right scapula, SL: scapula-like bone, MC: metacarpal bones, PH: phalanges.

calf whose duplicated ulnae of the left limb were arranged in mirror-image of each other in the anconeous processes. The radius appearing in hemimelia and symmelia was divided into proximal and distal parts and located between ulnae. The distal part fused with ulnar distal portions, and no osseous substance was found in the part corresponding to the shaft. In the duplicated and fused carpal bones, defects of the radial and accessory carpal bones were found. The fused digits were polydactylious.

In the present case, the deformed scapula of extra limb was attached to the spine of the normal right scapula. It was articulated with a incompletely duplicated humerus, and its mobility was limited.

The joints of the ectopic limb are usually fused [12]. In the present case, the incompletely duplicated distal extremity of the humerus fused with the head of the incompletely duplicated radius with no mobility at the elbow joint. The ulna was completely duplicated.

The carpal bones of a normal ruminant consist of six bones, four in the proximal row (radial, intermediate, ulnar and accessory carpal bones) and two in the distal (fused second and third, and fourth carpal bones) [3]. In the present case, carpal bones were duplicated, but one set of the duplicated carpal bones consisted of five bones: radial, accessory, fourth, fused ulnar and intermediate, and fused second and third carpal bones. Metacarpal bones and digits were duplicated. The hoof and rudimentary hoof of the accessory digit were duplicated as well.

Ueshima and Uehara [14] reported that the ulnar dimelia was very rare. The present case is the first case of the ulnar dimelia of a Korean native calf reported.

Seo *et al*. [13] reported a Korean native cow with an extra limb, and Kim *et al*.[7] reported a case of Korean native cow with an extra limb which was attached to the sternal region and was devoid of muscle tissues. Kim *et al*.[8, 9] also reported polymelia with two extra forelimbs in the neck region and notomelia with polydactyly in a Korean native cow. The muscle was devoid in these cows. In the present case, muscle tissues was devoid in heterotopic polymelia. Noden and de Lahunta [12] reported that the ectopic limbs were usually devoid of muscle tissues, but they were uncertain whether this was due to an early absence of myotome-derived cells or a secondary muscle degeneration caused by a lack of innervation.

Hiraga *et al*. [4] reported 223 cases of congenital deformities in cattle and found five cases of notomelia in the female. Similarly, it has also been reported that the occurrance of notomelia linked with sex, and found mostly in females [11]. This has been confirmed by Kim *et al*. [6–9]. To our best knowledge, the present study is the first report on notomelia (ulnar dimelia) in a male Korean native calf.

REFERENCES

1. Abe, M., Hiraga, T. and Iwasa, K. 1978. *J. Coll. Dairying* **7**: 331–336.

2. Bhattacharya, M. M. 1964. *Ind. Vet. J.* **41**: 739.
3. Getty, R. 1975. pp. 741–786. *In*: Sisson and Grossman's The Anatomy of The Domestic Animals, 5th ed., W. B. Saunders, Philadelphia.
4. Hiraga, T., Abe. M., Iwasa, K. and Takehana, K. 1987. *J. Coll. Dairying* **12**: 257–268.
5. Hiraga, T., Abe, M., Iwasa, K., Takehana, K. and Tetsuka, M. 1989. *Jpn. J. Vet. Sci.* **51**: 1011–1015.
6. Kim, C. S., Ahn, D. W., Jung, S. H. and Kim, J. S. 1990. *Korean J. Vet. Sci.* **30**: 401–408.
7. Kim, C. S., Huh, C. K. and Chung, H. S. 1993. *Korean J. Vet. Sci.* **33**: 1–5.
8. Kim, C. S., Lee, J. H., Song, C. W., Chung, K. T. and Kim, J, H. 1995. *Korean J. Vet. Res.* **35**: 651–657.
9. Kim, C. S., Lee, J. H., Kim, E. H., Chung, K. T. and Kim, J. H. 1995. *Korean J. Vet. Res.* **35**: 643–649.
10. Leipold, H. W. and Dennis, S. M. 1972. *Am. J. Vet. Res.* **33**: 421–423.
11. Leipold, H. W., Huston, K. and Dennis, S. M. 1983. *Adv. Vet. Sci. Comp. Med.* **27**: 197–271.
12. Noden, D. M. and DeLahunta, A. 1985. pp. 196–210. *In*: The Embryology of Domestic Animals, Willians and Wilkins, Baltimore.
13. Seo, D. S., Park, J. Y. and Kwon, N. S. 1990. *Korean Vet. Med. Assoc.* **30**: 401–408.
14. Ueshima, T. and Uehara, M. 1981. *Jpn. J. Vet. Sci.* **43**: 351–357.
15. Wacker, R. and Glasser, H. 1988. *Tiemerzil. Umsch.* **43**: 248–252.