

Case Study

Two Cases of Mediastinal Gray Zone Lymphoma

Jiro Minami,¹⁾ Nobuaki Dobashi,¹⁾ Osamu Asai,¹⁾ Shingo Yano,¹⁾ Hiroshi Osawa,¹⁾ Yutaka Takei,¹⁾
Yuichi Yahagi,¹⁾ Shinobu Takahara,¹⁾ Yoji Ogasawara,¹⁾ Yuko Yamaguchi,¹⁾
Tatsunosuke Kobayashi,¹⁾ Noriyuki Morikawa,¹⁾ Takashi Nikaido,²⁾ Keisuke Aiba,¹⁾
and Noriko Usui¹⁾

Mediastinal gray zone lymphoma (MGZL) represents a range of tumors possessing characteristics of both nodular sclerosis classical Hodgkin lymphoma (NSHL) and mediastinal large B-cell lymphoma (MLBCL). Here we report two patients with MGZL. Patient 1 was a 30-year-old woman and patient 2 was a 22-year-old man. Both patients had a mediastinal mass, were initially diagnosed with NSHL and exhibited resistance to first-line chemotherapy. Re-biopsy of the relapsed tumors or the residual lesion was performed and based on the findings the tumors were diagnosed as MGZL. In patient 1, the morphological features of the tumor resembled those of NSHL, but the immunophenotypic features indicated MLBCL. In patient 2, the tumor was a composite lymphoma with both NSHL and MLBCL components. Both the patients received high-dose chemotherapy followed by autologous peripheral-blood stem-cell transplantation. Although there is an overlap in the biological and morphological features between NSHL and MLBCL, the therapeutic approaches to NSHL and MLBCL are quite different. The development of effective therapies for MGZL is therefore extremely critical. [*J Clin Exp Hematopathol* 50(2) : 143-149, 2010]

Keywords: mediastinal gray zone lymphoma, composite lymphoma, nodular sclerosis classical Hodgkin lymphoma, mediastinal large B-cell lymphoma, autologous peripheral blood stem cell transplantation

INTRODUCTION

In recent years, an overlap in the biological and morphological features has been identified between classical Hodgkin lymphoma (cHL) and B-cell non-Hodgkin lymphoma. In particular, nodular sclerosis classical Hodgkin lymphoma (NSHL) and mediastinal large B-cell lymphoma (MLBCL) share a number of common features.¹⁻⁴ Both types occur in young adults and have a high frequency of anterior mediastinal mass with the involvement of the thymus gland and supraclavicular lymph nodes.¹

The term “gray zone lymphoma” for borderline cases of Hodgkin lymphoma was introduced for the first time in the proceedings of the “Workshop on Hodgkin’s disease and

related diseases” in 1998.⁵ Mediastinal gray zone lymphoma (MGZL) represents a range of tumors possessing characteristics of both NSHL and MLBCL.^{2,6} In cases where morphological features suggested MLBCL, the immunophenotype was often more typical of NSHL (Table 1). In cases where morphological features suggested NSHL, the immunophenotype was often more typical of NSHL (Table 1). Another type of MGZL, which also may present as a composite lymphoma, involves both MLBCL and NSHL (Table 1). Clinicians often call for pathologists to render a definitive diagnosis of NSHL or MLBCL, because the treatment regimens differ between NSHL and MLBCL.

Here, we present two cases of MGZL and consider how to treat this new entity of lymphoma.

PATIENTS AND METHODS

Two patients with a diagnosis of MGZL admitted at our hospital for application of chemotherapy were described here. The clinical diagnosis of MGZL was based on the criteria proposed by Jaffe *et al.*¹ ABVd regimen (adriamycin, bleomycin, vincristine and dacarbazine) was administered as previously described.⁷ EPOCH-R regimen consisted of rituximab, 375 mg/m² (i.v.) on day 1; etoposide, 50 mg/m² as a

Received : August 7, 2009

Revised : November 26, 2009

Accepted : November 28, 2009

¹⁾Division of Clinical Oncology and Hematology, Department of Internal Medicine, Jikei University School of Medicine, Tokyo, Japan

²⁾Department of Pathology, Jikei University School of Medicine, Tokyo, Japan
Address correspondence and reprint request to Noriko Usui, M.D., Division of Clinical Hematology and Oncology, Department of Internal Medicine, Jikei University School of Medicine, 3-25-8, Nishishinbashi, Minato-ku, Tokyo 105-8461, Japan.

E-mail : usuin@jikei.ac.jp

Table 1. Comparison of clinical and pathological features of MLBCL, NSHL and MGZL

Feature	MLBCL	NSHL	MGZL
Age distribution	Third to fourth decade	Peak at 15-34 years	Peak at 20-40 years
Gender	Female predominance	Similar in males and females	Male predominance
Site of disease	Anterior mediastinum	Anterior mediastinum	Anterior mediastinum
Pathology	Medium sized to large cells, Fibrosis	Reed-Sternberg cells, Fibrosis	Sheet-like growth of pleomorphic tumor cells, Fibrosis
Immunophenotype	CD20 ⁺ , CD30 ⁺ (more than 80%, usually weak), Surface immunoglobulin ⁻	CD15 ⁺ (75-85%), CD30 ⁺ (nearly all cases), CD20 (30-40%, present only on a minority of the neoplastic cells), Surface immunoglobulin ⁻	Morphologically resemble NSHL: CD20 ⁺ , CD15 ⁻ Morphologically resemble MLBCL: CD20 ⁻ , CD15 ⁺ Composite lymphoma: exhibit a phenotype, either NSHL or MLBCL Surface immunoglobulin ⁻

MLBCL, mediastinal gray zone lymphoma ; NSHL, nodular sclerosis classical Hodgkin lymphoma ; MGZL, mediastinal large B-cell lymphoma

continuous i.v. infusion (c.i.v.) over days 2 to 5 ; prednisolone, 100 mg/kg body weight over days 2 to 6 ; doxorubicin, 10 mg/m² (c.i.v.) over days 2 and 5 ; vincristine, 0.4 mg/m² (c.i.v.) over days 2 and 5 ; and cyclophosphamide, 750 mg/m² (i.v.) on day 6. ESHAP-R regimen consisted of rituximab, 375 mg/m² (i.v.) on day 1 ; etoposide, 40 mg/m² (i.v.) over days 2 to 5 ; cisplatin, 25 mg/m² (c.i.v.) over days 2 to 5 ; cytosine arabinoside (Ara-C), 2 g/m² (i.v.) on day 6 ; and methylprednisolone, 500 mg/kg body weight (i.v.) over days 2 to 6. The high-dose chemotherapy followed by autologous peripheral-blood stem-cell transplantation (autologous PBSCT) was administered as published before.⁸

Material of the biopsy and the resection was fixed in formalin, routinely processed and embedded in paraffin ; 4 μ m-thick sections were stained with hematoxylin and eosin. For immunohistochemical studies paraffin-embedded sections were used. Immunoperoxidase staining was carried out using the streptavidin-biotin peroxidase complex method. Antibodies against CD30 (1:20, Dako, Glostrup, Denmark), CD15 (1:50, Dako), CD20 (1:250, Dako), CD79a (1:50, Dako), OCT-2 (1:500, Santa Cruz Biotechnology, Santa Cruz, CA), BOB. 1 (B cell Oct binding protein 1, Sc-955, 1:2,000, Santa Cruz), EBV-LMP (Epstein-Barr Virus Latent Membrane Protein-1, CS1-4, 1:50, Dako), and MUM1 (1:50, Dako) were used. The antigen retrieval procedure was done with a microwave oven in citrate buffer pH6.0 for the paraffin-embedded sections in order to efficiently stain for CD30, CD79a, Oct-2, and BOB. 1. Appropriate positive and negative controls were used in each case.

For *in situ* hybridization, formalin-fixed and paraffin-embedded sections were used with a digoxigenin-labeled oligonucleotide probe complementary to an EBV-encoded RNA (EBER) using the Rambrant RNA *in situ* hybridization and detection kit (Nichirei, Tokyo, Japan). Hybridization was detected using the procedure described by Chang *et al.*⁹

CASE REPORT

Patient 1

A 30-year-old female presented with a cough. Chest X-ray films and computed tomography (CT) images revealed a large mediastinal mass (Fig. 1A, B). The mass was diagnosed as NSHL by the biopsy analysis of the mediastinal mass, and the clinical stage of the disease was stage IIB according to the Ann Arbor classification. She received 6 courses of chemotherapy with ABVd.⁷ She was subsequently treated with involved-field irradiation therapy to the mediastinum at a total dose of 25 Gy (Fig. 1C). Complete response unconfirmed (CRu) was achieved after the irradiation therapy. Two months after completing irradiation, the first relapse occurred at the left supraclavicular lymph nodes and an apical portion of the left lung. Re-biopsy was performed and the biopsy specimens were examined (Fig. 2). The microscopic morphological appearance indicated NSHL. However, the immunophenotype was more suggestive of MLBCL. CD20, CD30 and MUM1 were positive in nearly all tumor cells examined, and CD15 was negative in immunohistochemical staining analysis (Table 2). In addition, BOB. 1 was positive in nearly all tumor cells, and Oct-2 was positive in partial tumor cells. Thus, a final diagnosis of MGZL was obtained. The tumor cells were also partially positive for EBER but negative for EBV-LMP. She received 2 courses of chemotherapy with EPOCH-R. After the EPOCH-R treatment, partial response (PR) was achieved. Next, she received high-dose chemotherapy followed by autologous PBSCT.⁸ She has been free from disease for 15 months after transplantation without recurrence.

Patient 2

A 22-year-old male presented with left shoulder pain and

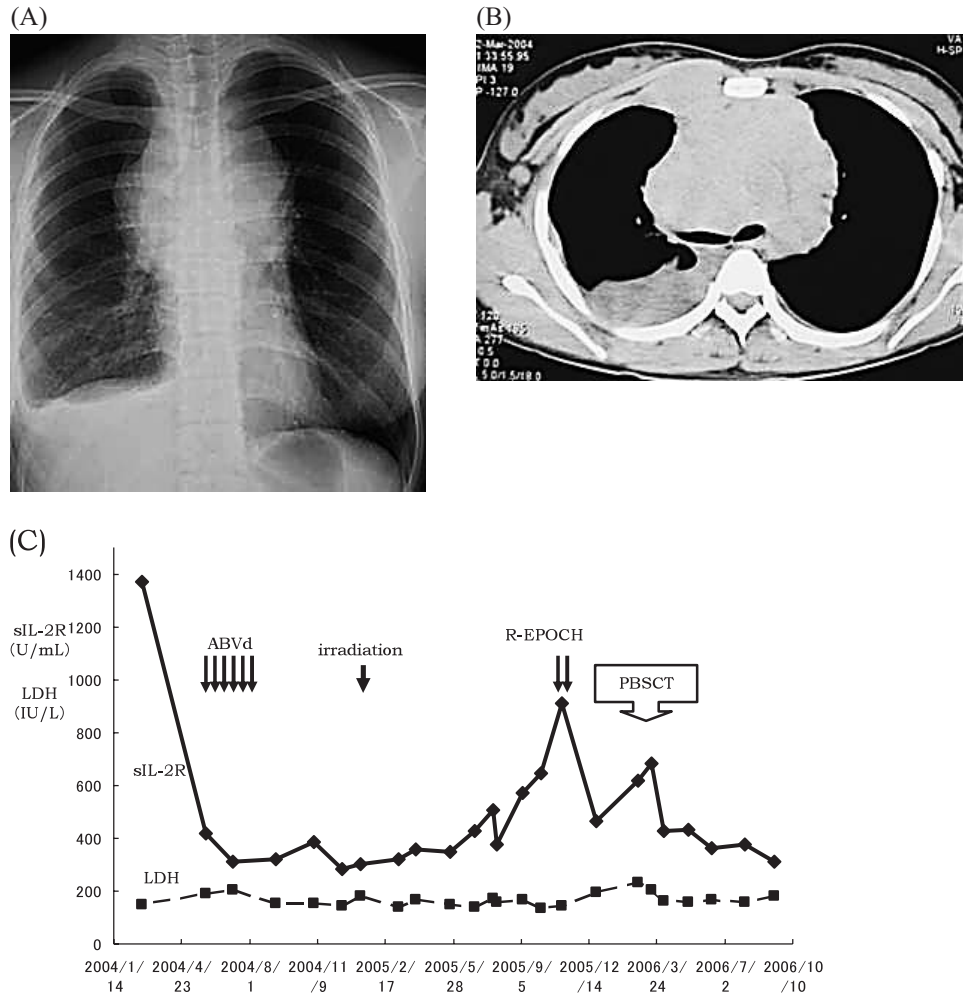


Fig. 1. Radiographic images when patient 1 was admitted at our hospital. *(IA)* Chest x-ray film showing mediastinal mass. *(IB)* A bulky mass at the anterior mediastinum is observed on the computed tomography image. *(IC)* Clinical course of patient 1. sIL-2R, soluble interleukin-2 receptor; LDH, lactate dehydrogenase; ABVd, adriamycin, bleomycin, vincristine and dacarbazine; R-EPOCH, rituximab, etoposide, prednisolone, doxorubicin, vincristine, and cyclophosphamide; PBSCT, peripheral-blood stem-cell transplantation

swelling of left neck lymph nodes. Chest X-ray films and CT images revealed a mediastinal mass (Fig. 3A, B). The mass was diagnosed as NSHL (Fig. 4) by the biopsy analysis of the left neck lymph nodes.

In addition to Reed-Sternberg cells being present, nearly all tumor cells were positive for CD15 and negative for CD20 and CD30 (Table 2). The clinical stage of the disease was stage IIB, and he received 4 courses of chemotherapy with ABVd; however, no therapeutic effect was observed (Fig. 3C). Therefore, a re-biopsy of the mediastinal tumor was performed (Fig. 4). The morphological and immunophenotypic features of the tumor closely resembled the features of diffuse large B-cell lymphoma (DLBCL) (Table 2). The

tumor cells were uniformly positive for CD20 and MUM1, but negative for CD15, CD30, EBER and EBV-LMP. He was treated with 2 courses of EPOCH-R chemotherapy; however, the disease progressed further. Therefore, he was administered with ESHAP-R. After having PR by 1 course of ESHAP-R, he then received high-dose chemotherapy followed by autologous PBSCT.⁸ CRu was achieved after the autologous PBSCT. He was subsequently treated with involved-field irradiation to the mediastinum at a dose of 25 Gy. Five months after the autologous PBSCT, the first relapse occurred at the anterior mediastinal region. High-dose methotrexate and high-dose Ara-C [methotrexate, 1 g/m² (i.v.) on day 1 and Ara-C, 2 g/m² (i.v.) on days 2 and 3] were

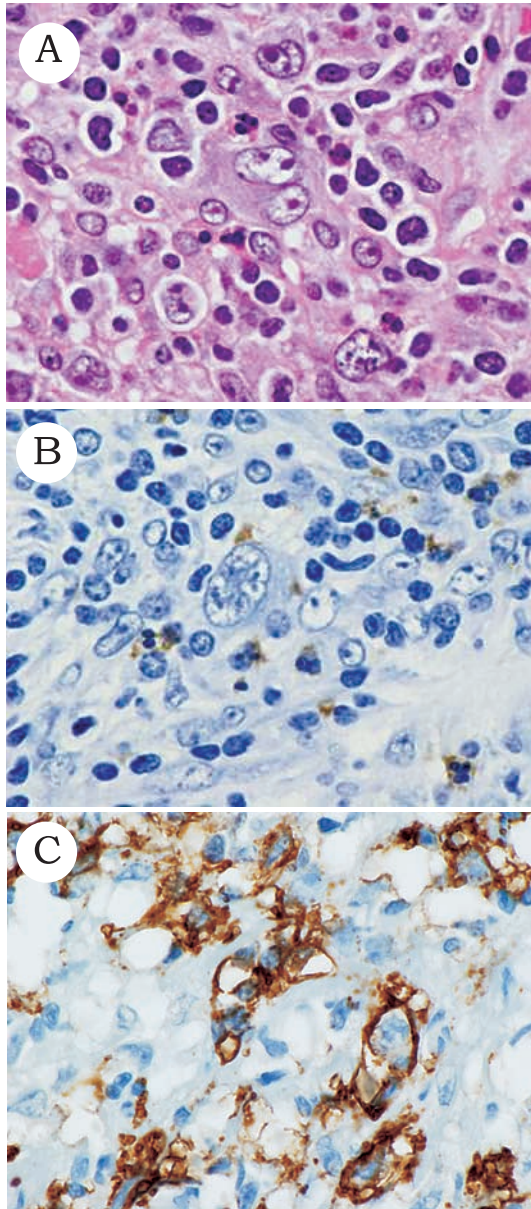


Fig. 2. Morphological and immunohistochemical features of recurrent mediastinal gray zone lymphoma with nodular sclerosis classical Hodgkin lymphoma in the left neck lymph node (patient 1). (2A) Tumor cells with large nuclei enclosing clear nucleoli are present. H&E stain, $\times 400$. (2B) Nearly all tumor cells are CD15 negative. CD15 immunostaining, Counterstained with hematoxylin, $\times 400$. (2C) Most tumor cells are CD20 positive. CD20 immunostaining, Counterstained with hematoxylin, $\times 400$.

administered, but the disease progressed. Surgery was performed to remove the mediastinal tumor together with a part of pericardium and the lingular segment of the left lung partially. He is scheduled to receive the irradiation therapy to the mediastinum.

DISCUSSION

In the present study, we described the two patients with MGZL that exhibited different histological features. MGZL is a relatively new disease entity of lymphoma, and there are only a few previous reports on this entity.^{1,2,5} Jaffe *et al.* reported 36 cases of MGZL over two decades.¹ Of the 36 patients, 21 patients had a lymphoma showing features of both NSHL and MLBCL (i.e., NSHL with features of MLBCL or vice versa). Further, 6 of the 36 patients had mediastinal composite or synchronous lymphoma with both NSHL and MLBCL components, and 9 patients had mediastinal sequential lymphoma (NSHL that relapsed as MLBCL or vice versa). In our study, both the patients were similar to those mentioned in this previous report.¹ In patient 1, the tumor cells were positive for Oct-2 and BOB. 1. Oct-2 is a B-cell specific transcription factor and BOB. 1 is a B-cell specific transcriptional co-activator. It is generally considered that Oct-2 and BOB. 1 are not expressed in Reed-Sternberg cells.⁶ Therefore, our results indicate that case 1 would be classified as MGZL.

A recent study has also reported that BOB. 1 is expressed in cHL;¹⁰ the authors advocated that the strong expression of BOB. 1 in Reed-Sternberg cells was due to the biological similarity between cHL and MLBCL. The etiology of MGZL is unknown, and Epstein-Barr virus infection has been identified in 20% or fewer cases.⁶ In the present study, EBER was positive in patient 1, but not in patient 2.

Adequate therapeutic approaches for MGZL are yet to be established. There has been only a single report concerning the treatment result of MGZL.¹ It was reported that 4 patients with MGZL were treated with dose-adjusted EPOCH-R and all these patients achieved a radiological CR, although one patient required 2 separate courses of mediastinal irradiation to eradicate a small PET-positive area. Further, at a median follow-up period of 34 months, all the patients are still in CR. On the other hand, the 2 patients we described in our report exhibited resistance to the first-line chemotherapy. Only patient 1 achieved PR after EPOCH-R therapy, and she has maintained CRu after the autologous PBSCT. In patient 2, the disease was chemorefractory because there was an early relapse after the autologous PBSCT, which was administered after high-dose chemotherapy. Therefore, establishment of a standard therapy for MGZL is extremely critical.

In summary, we reported 2 cases of MGZL. Both the patients exhibited resistance to the first-line chemotherapy. Further clinical studies are required to establish the optimal

Table 2. Morphological and immunophenotypic features of patient 1 and patient 2

Feature	Morphology	CD20	CD15	CD30
Patient 1	NSHL	+	-	-
Patient 2	NSHL			
Neck	NSHL	-	+	-
Mediastinum	MLBCL	+	-	-

NSHL, nodular sclerosis classical Hodgkin lymphoma ; MLBCL, mediastinal large B-cell lymphoma

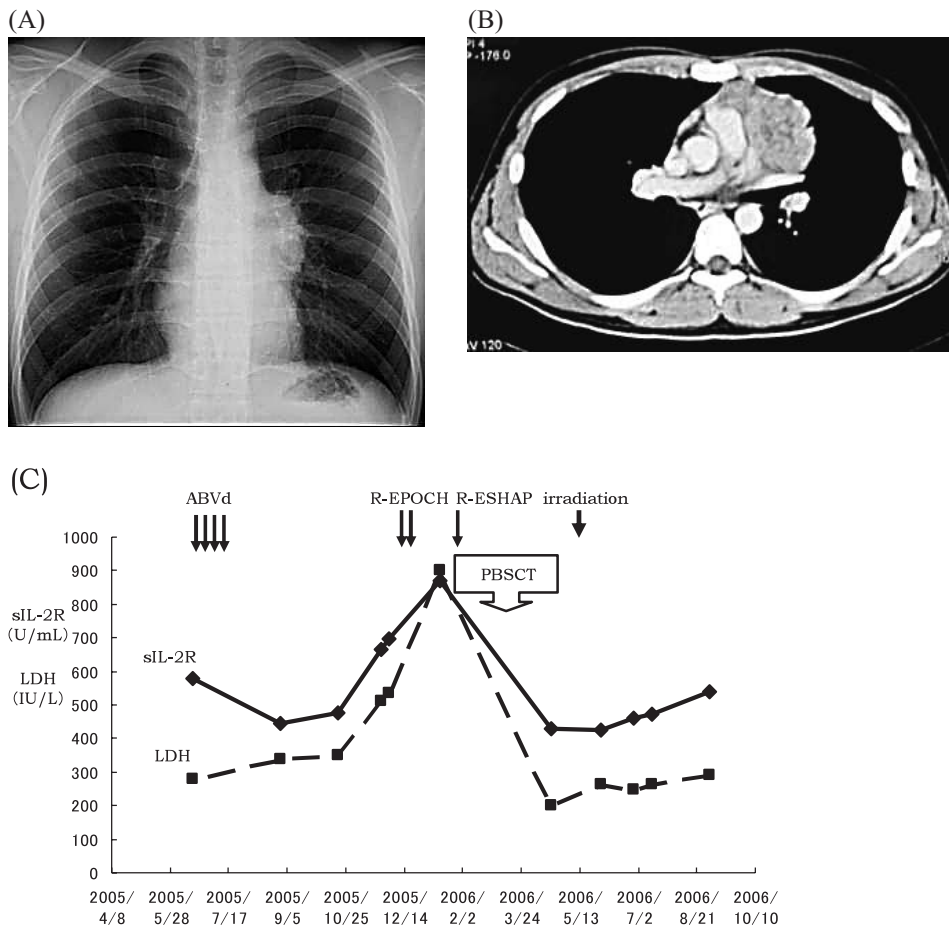


Fig. 3. Radiographic images when patient 2 was admitted at our hospital. (3A) Chest x-ray film shows the mediastinal mass. (3B) A large mass at the anterior mediastinum is observed on the computed tomography image. (3C) Clinical course of patient 2. sIL-2R, soluble interleukin-2 receptor ; LDH, lactate dehydrogenase ; ABVd, adriamycin, bleomycin, vincristine and dacarbazine ; R-EPOCH, rituximab, etoposide, prednisolone, doxorubicin, vincristine, and cyclophosphamide ; R-ESHAP, rituximab, etoposide, cisplatin, cytosine arabinoside and methylprednisolone ; PBSCT, peripheral-blood stem-cell transplantation

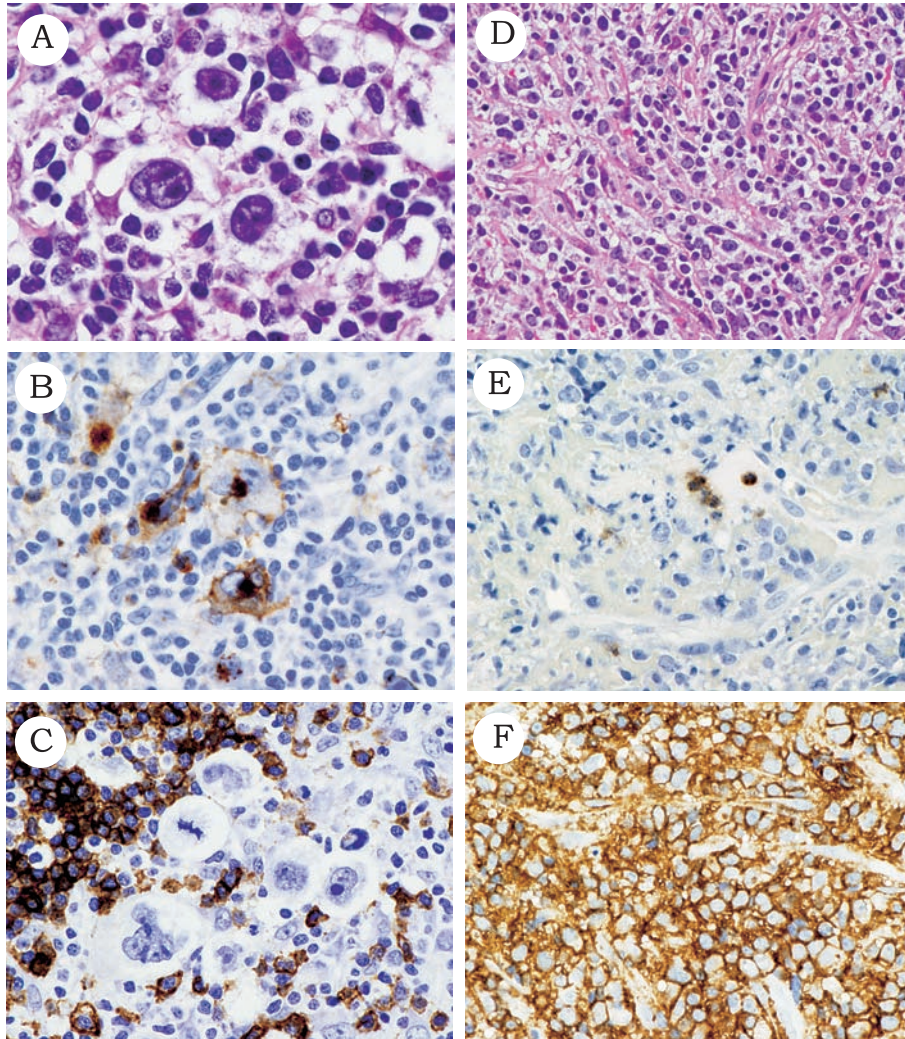


Fig. 4. Morphological and immunohistochemical features of mediastinal gray zone lymphoma (patient 2). (**4A-C**) show the histological findings that led to the first diagnosis of nodular sclerosis classical Hodgkin lymphoma in the left neck lymph node. (**4D-F**) depict the histological findings of the tumor specimen obtained from re-biopsy of the anterior mediastinal mass. (**4A**) Reed-Sternberg cells and lacunar cells are present. H&E staining, $\times 400$. (**4B**) Nearly all tumor cells are CD15 positive. CD15 immunostaining, Counterstained with hematoxylin, $\times 400$. (**4C**) All tumor cells are CD20 negative. CD20 immunostaining, Counterstained with hematoxylin, $\times 400$. (**4D**) The tumor comprises sheets of large cells with clear cytoplasm. H&E staining, $\times 400$. (**4E**) All tumor cells are CD15 negative. CD15 immunostaining, Counterstained with hematoxylin, $\times 400$. (**4F**) All tumor cells are CD20 positive. CD20 immunostaining, Counterstained with hematoxylin, $\times 400$.

therapy for this type of disease.

ACKNOWLEDGEMENTS

We are very grateful to Dr. Junichi Tamaru, Department of Pathology, Saitama Medical Center, Saitama Medical School, for conducting histological review and providing helpful advice. We also thank Dr. Kengo Takeuchi,

Department of Pathology, Cancer Institute, Japanese Foundation for Cancer Research, for performing PCR analysis.

REFERENCES

- 1 Traverse-Glehen A, Pittaluga S, Gaulard P, Sorbara L, Alonso MA, *et al.*: Mediastinal gray zone lymphoma: the missing link

- between classic Hodgkin's lymphoma and mediastinal large B-cell lymphoma. *Am J Surg Pathol* 29 : 1411-1421, 2005
- 2 Calvo KR, Traverse-Glehen A, Pittaluga S, Jaffe ES : Molecular profiling provides evidence of primary mediastinal large B-cell lymphoma as a distinct entity related to classic Hodgkin lymphoma : implications for mediastinal gray zone lymphomas as an intermediate form of B-cell lymphoma. *Adv Anat Pathol* 11 : 227-238, 2004
 - 3 Rosenwald A, Wright G, Leroy K, Yu X, Gaulard P, *et al.* : Molecular diagnosis of primary mediastinal B cell lymphoma identifies a clinically favorable subgroup of diffuse large B cell lymphoma related to Hodgkin lymphoma. *J Exp Med* 198 : 851-862, 2003
 - 4 Savage KJ, Monti S, Kutok JL, Cattoretti G, Neuberg D, *et al.* : The molecular signature of mediastinal large B-cell lymphoma differs from that of other diffuse large B-cell lymphomas and shares features with classical Hodgkin lymphoma. *Blood* 102 : 3871-3879, 2003
 - 5 Rudiger T, Jaffe ES, Delsol G, deWolf-Peeters C, Gascoyne RD, *et al.* : Workshop report on Hodgkin's disease and related diseases ('grey zone' lymphoma). *Ann Oncol* 9 (Suppl 5) : S31-38, 1998
 - 6 WHO Classification of Tumours, Tumours of Haematopoietic and Lymphoid Tissues, Swerdlow SH, Campo E, Harris NL, Jaffe ES, Pileri SA, *et al.* (eds) : 4th ed, Lyon, IARC, 2008
 - 7 Takenaka T, Mikuni C, Miura A, Sasaki T, Suzuki H, *et al.* : Alternating combination chemotherapy C-MOPP (cyclophosphamide, vincristine, procarbazine, prednisone) and ABVd (adriamycin, bleomycin, vinblastine, dacarbazine) in clinical stage II-IV Hodgkin's disease : a multicenter phase II study (JCOG 8905). The Lymphoma Study Group of the Japan Clinical Oncology Group. *Jpn J Clin Oncol* 30 : 146-152, 2000
 - 8 Usui N, Yano S, Asai O, Dobashi N, Osawa H, *et al.* : Long-term follow-up high-dose chemotherapy (drug-only program) followed by autologous stem cell transplantation for aggressive non-Hodgkin's lymphomas. *Clin Lymphoma* 6 : 31-36, 2005
 - 9 Chang KL, Chen YY, Shibata D, Weiss LM. : Description of an *in situ* hybridization methodology for detection of Epstein-Barr virus RNA in paraffin-embedded tissues, with a survey of normal and neoplastic tissues. *Diag Mol Pathol* 1 : 246-225, 1992
 - 10 Abd El All HS : Bob-1 is expressed in classic Hodgkin lymphoma. *Diagn Pathol* 2 : 10, 2007 [doi : 10.1186/1746-1596-2-10]